

 बैंक ऑफ़ बड़ौदा
Bank of Baroda




नाम - नीरू
Name - NEERU

कर्मचारी कूट क्र - 101168
E.C. No. - 101168

जारीकर्ता प्राधिकारी

Issuing Authority




धारक के हस्ताक्षर
Signature of Holder

*For Me health check up
only
One Plus ultrasound*



Dr. NITIN AGARWAL
MBBS, MD
Regn. No. DMC-R-1436

ONEPLUS ULTRASOUND LAB
47, Harsh Vihar, Pitam Pura,
Delhi-110034
Ph. 011-42480101, 9599913051
E-mail. oneplusul@gmail.com



ONEPLUS ULTRASOUND LAB

47, HARSH VIHAR, PITAMPURA, DELHI- 110034

Mr. NEERU
 Age : 33M
 Ref. by : MEDIWHEEL
 Indication1 :
 Indication2 :
 Indication3 :
 COMMENTS : Normal ECG.

ID : 1818
 HWT : 168/87
 Recorded : 19-11-2021 10:29
 Medication1 :
 Medication2 :
 Medication3 :

BPM : 94
 BP : 126/80
 P Axis : 66 deg
 QRS Axis : 44 deg
 T Axis : 44 deg

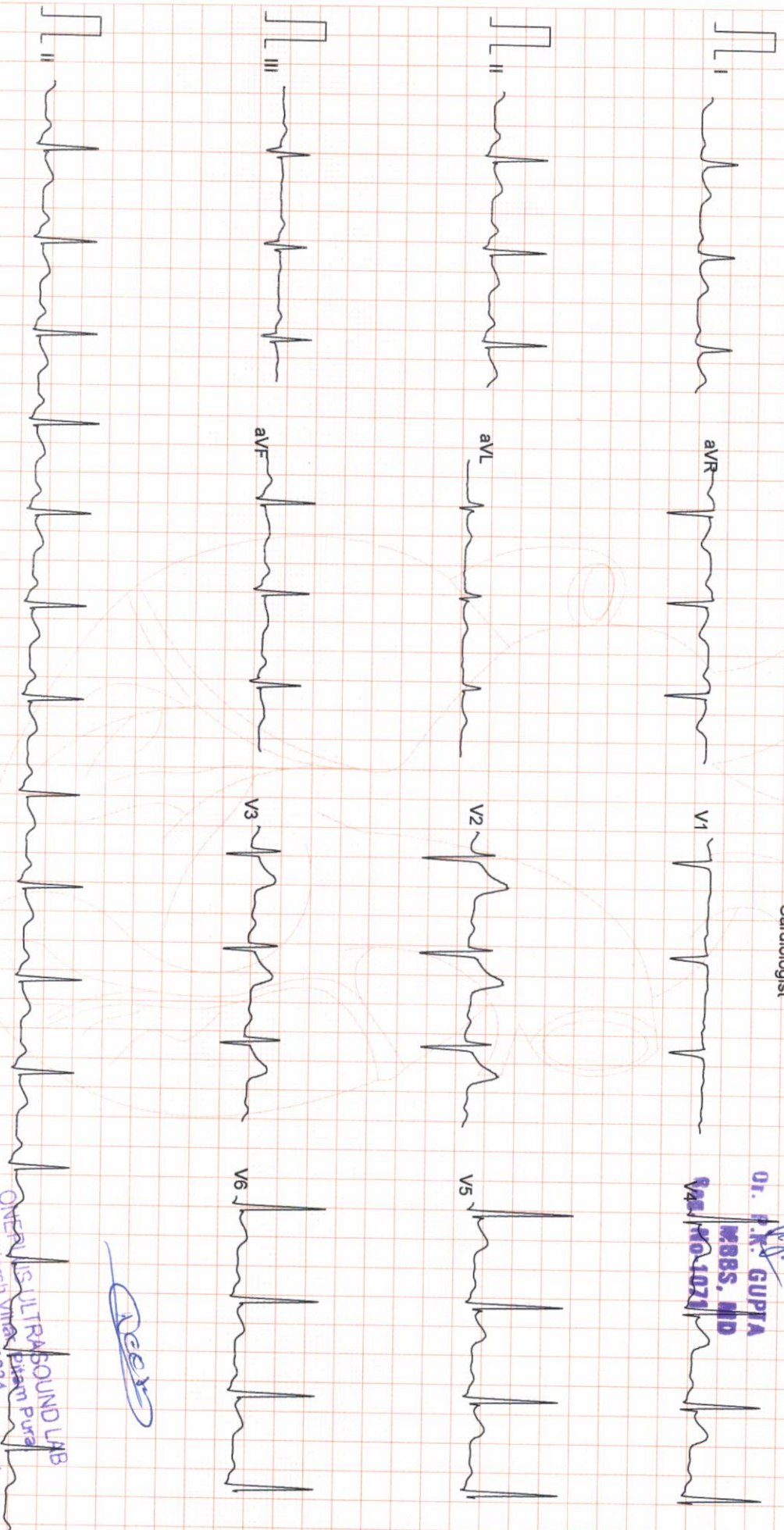
P duration : 100 msec
 PR duration : 163 msec
 QRS duration : 100 msec
 QT interval : 296 msec
 QTc interval : 355 msec

Unconfirmed Report Reviewed By:

Cardiologist

Dr. P.K. GUPTA
MBBS, MD
 No. 101021

Raw E.C.G. (Seq)



Filtered

25mm/sec 10mm/mV

www.oneplusultrasoundlab.com

CardiCom, INDIA

ONEPLUS ULTRASOUND LAB
 47, Harsh Vihar, Pitampura
 Delhi-110034
 Ph: 011-42480101, 9599913051
 E-mail: oneplusul@gmail.com

ONEPLUS ULTRASOUND LAB

47, HARSH VIHAR PITAMPURA DELHI 110034

ID : 998
 HI/Wt : 168/87
 Recorded : 19-11-2021 10:31

Mr. NEERU
 Age/Sex : 33/M
 Ref. by : MEDIWHEEL

Indication1 :
 Indication2 :
 Indication3 :

TREADMILL TEST SUMMARY REPORT
 Protocol: BRUCE

History :
 Medication1 :
 Medication2 :
 Medication3 :

PHASE	PHASE TIME	STAGE TIME	SPEED (Km./Hr.)	GRADE (%)	H.R. (BPM)	B.P. (mmHg)	RPP X100	II	ST LEVEL (mm) V2	V5	METS
STANDING SUPINE					92	126/80	115	1.1	2.8	1.5	
STAGE 1	2:59	2:59	2.70	10.00	108	136/82	146	1.0	2.5	1.2	4.80
STAGE 2	5:59	2:59	4.00	12.00	121	148/86	179	0.6	2.3	1.0	7.10
STAGE 3	8:59	2:59	5.40	14.00	137	160/88	219	0.5	1.9	0.6	10.00
STAGE 4	9:59	0:59	6.70	16.00	158	160/88	252	0.2	1.9	0.2	11.32
PEAK EXER	10:12	1:12			165	172/90	283	0.1	1.8	0.3	
RECOVERY	2:59	2:59	0.00	0.00	106	130/82	137	0.8	1.5	0.6	11.61

RESULTS

Exercise Duration : 10:12 Minutes
 Max Heart Rate : 165 bpm 88 % of target heart rate 187 bpm
 Max Blood Pressure : 172/90 mmHg
 Max Work Load : 11.61 METS
 Reason of Termination :

Negative for ischaemic ST-T



Cardiologist
Dr. P.K. GUPTA
 M.B.B.S, MD
 Reg. No-1071



ONEPLUS ULTRASOUND LAB
 47, Harsh Vihar, Pitampura,
 Delhi-110034
 Ph: 011-42480101, 9559913051
 Email: onepusul@gmail.com

ONEPLUS ULTRASOUND LAB

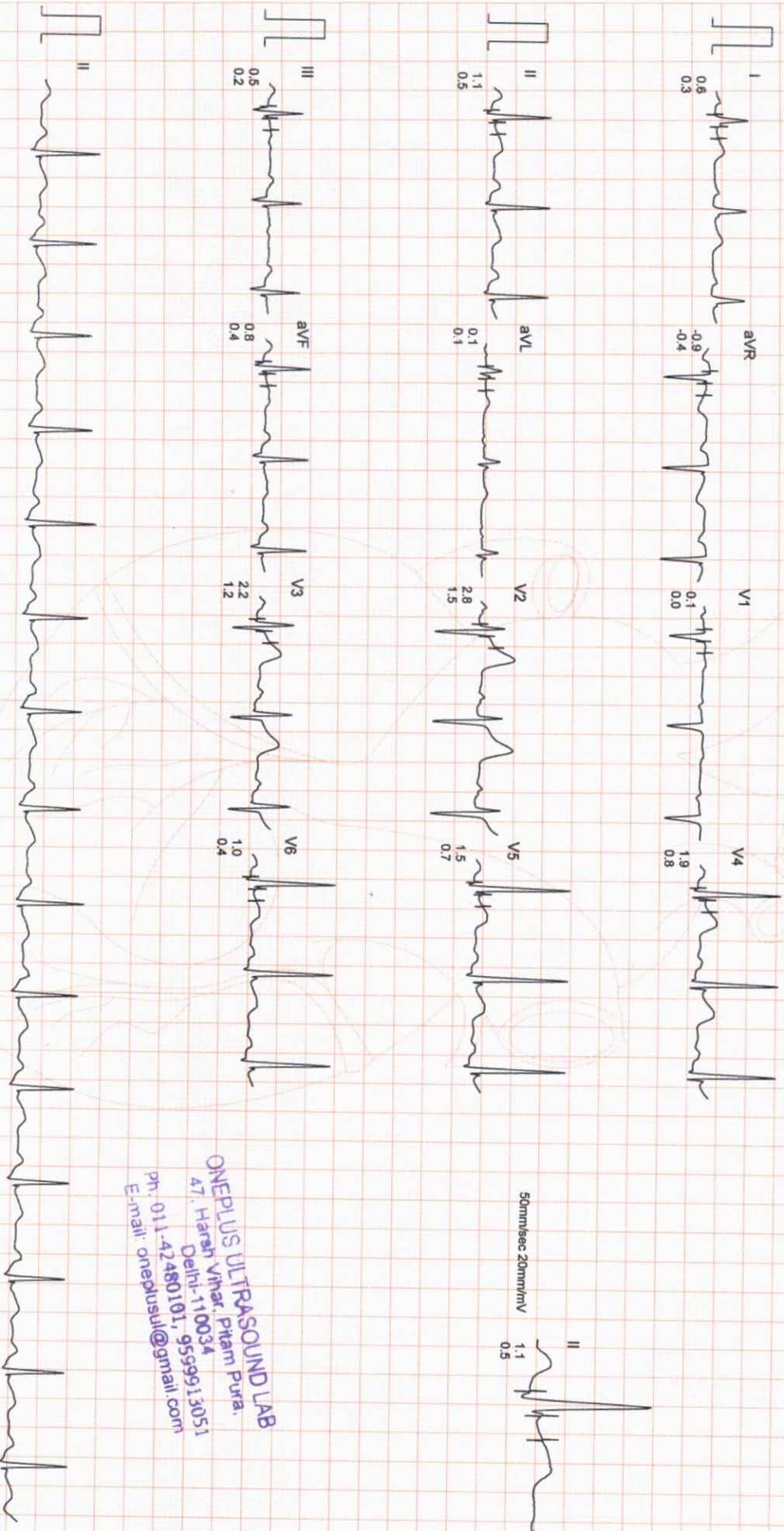
STANDING
PRETEST

ST @ 10mm/mV
80ms PostJ

Mr. NEERU
I.D. : 998
AGE/SEX : 33/M
RECORDED : 19-11-2021 10:31

RATE : 92 BPM
B.P. : 126/80 mmHg

LINKED MEDIAN



ONEPLUS ULTRASOUND LAB
47, Harsh Vihar, Pitam Pura,
Delhi-110034
Ph: 011-42480101, 9599913051
E-mail: oneplusul@gmail.com

Filtered

Computer Corrected Baseline

25mm/sec 10mm/mV

ARROW

CardiCom, INDIA Ph.:091-731-2620740, Telefax:091-731-2431214

Mr. NEERU
I.D. : 998
AGE/SEX : 33/M
RECORDED : 19-11-2021 10:31

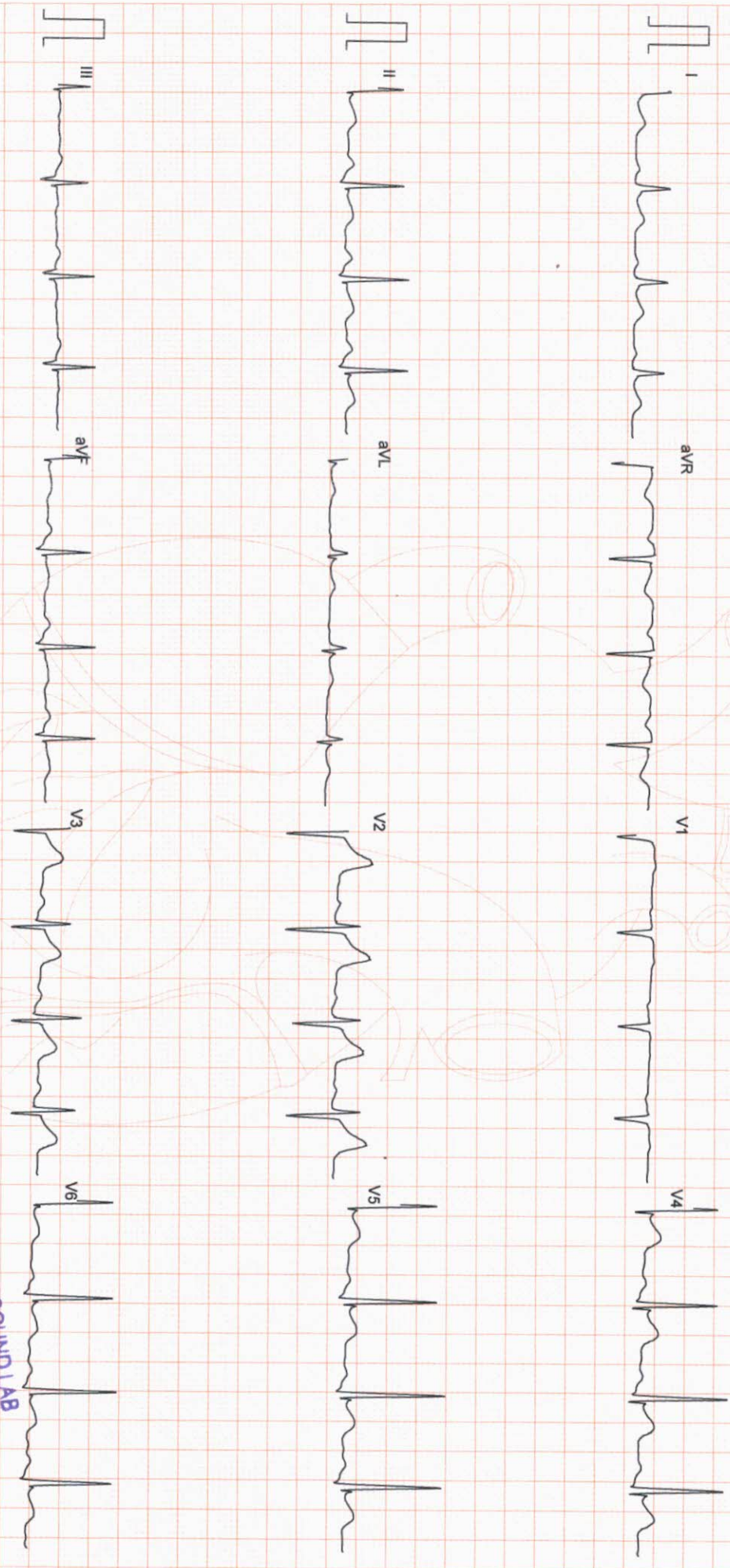
RATE : 94 BPM
B.P. : 126/80 mmHg

ONEPLUS ULTRASOUND LAB

SUPINE
PRETEST

ST @ 10mm/mV
80ms PostJ

RAW E.C.G.



Filtered

25mm/sec 10mm/mV

ARCIV

CardiCom, INDIA Ph.:091-731-2620740 Tele/Fax:091-731-2431214

ONEPLUS ULTRASOUND LAB
47, Harsh Vihar, Pitam Pura,
Delhi-110034
Ph. 011-42480101, 9599913051
E-mail: onepusul@gmail.com

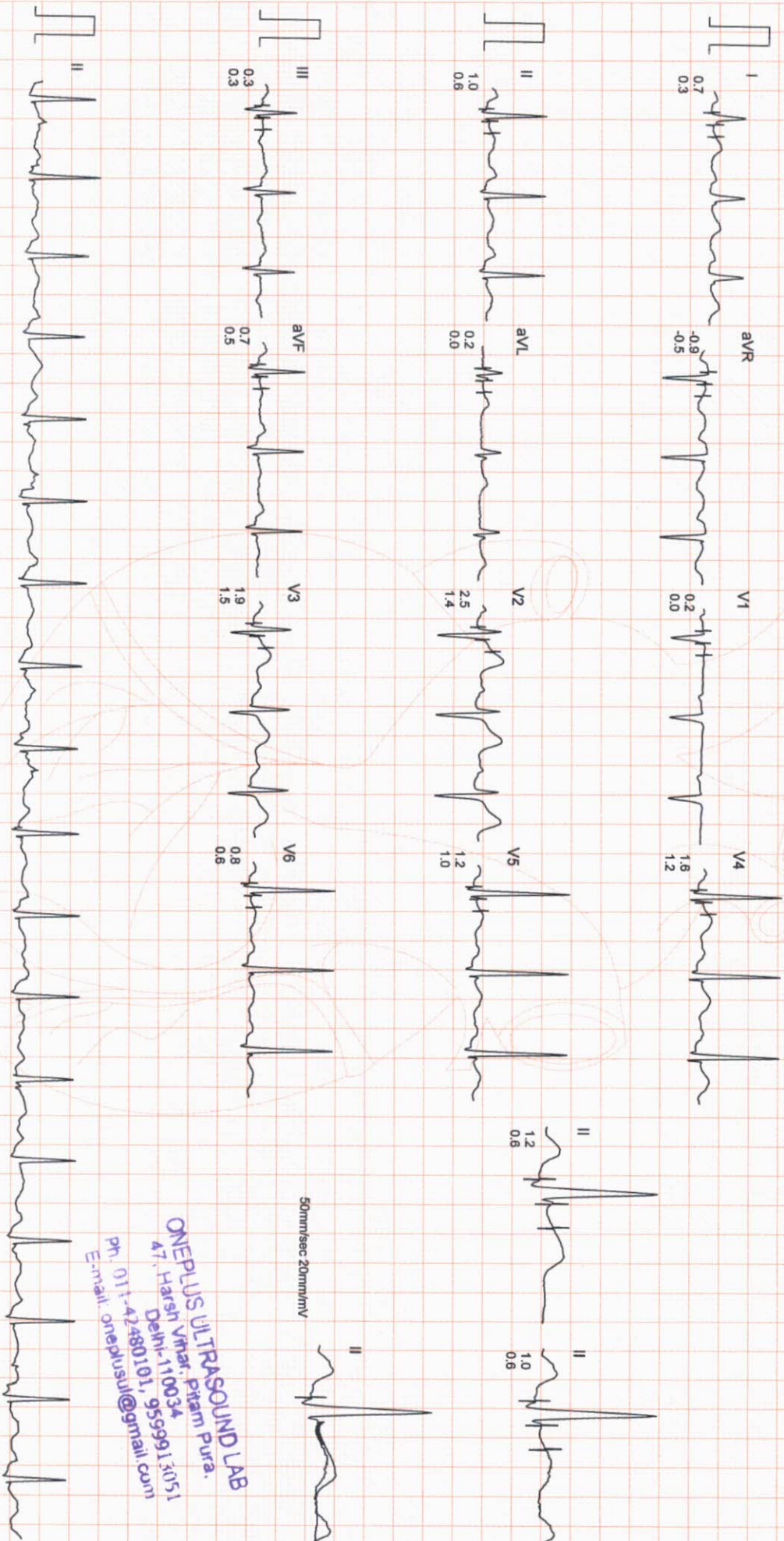
ONEPLUS ULTRASOUND LAB

Mr. NEERU
I.D. : 998
AGE/SEX : 33/M
RECORDED : 19-11-2021 10:31

BRUCE
EXERCISE 1
PHASE TIME : 2:59
STAGE TIME : 2:59

ST @ 10mm/mV
80ms PostJ
SPEED : 2.7 Km./Hr.
GRADE : 10.0 %

LINKED MEDIAN



Filtered

Computer Corrected Baseline

25mm/sec 10mm/mV

CardiCom, JINDIA Ph.:091-731-2620740, TeleFax:091-731-2431214

ONEPLUS ULTRASOUND LAB
47, Harsh Vihar, Pitam Pura,
Delhi-110034
Ph. 011-42480101, 95599913051
E-mail: oneplusul@gmail.com

ARCAV

ONEPLUS ULTRASOUND LAB

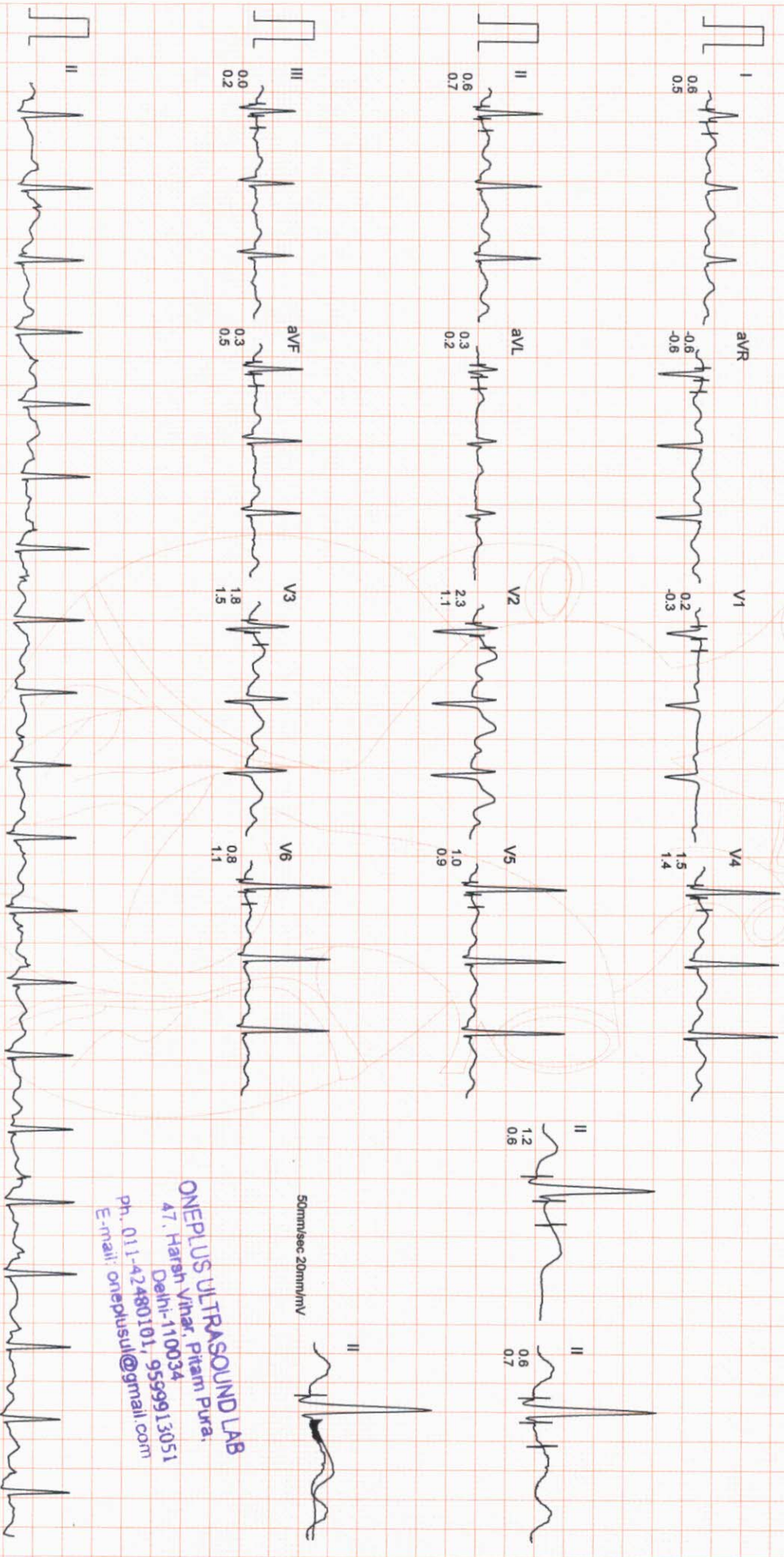
Mr. NEERU
 I.D. : 998
 AGE/SEX : 33/M
 RECORDED : 19-11-2021 10:31

BRUCE
 EXERCISE 2
 PHASE TIME : 5:59
 STAGE TIME : 2:59

ST @ 10mm/mV
 80ms PostJ
 SPEED : 4.0 Km./Hr.
 GRADE : 12.0 %

RATE : 121 BPM
 B.P. : 148/86 mmHg

LINKED MEDIAN



50mm/sec 20mm/mV

ONEPLUS ULTRASOUND LAB
 47, Harsh Vihar, Pitam Pura,
 Delhi-110034
 Ph. 011-42480101, 9599913051
 E-mail: oneplusul@gmail.com

Filtered

Computer Corrected Baseline

25mm/sec 10mm/mV

AVC

CardiCom, INDIA Ph.:091-731-2620740, TeleFax:091-731-2431214

ONEPLUS ULTRASOUND LAB

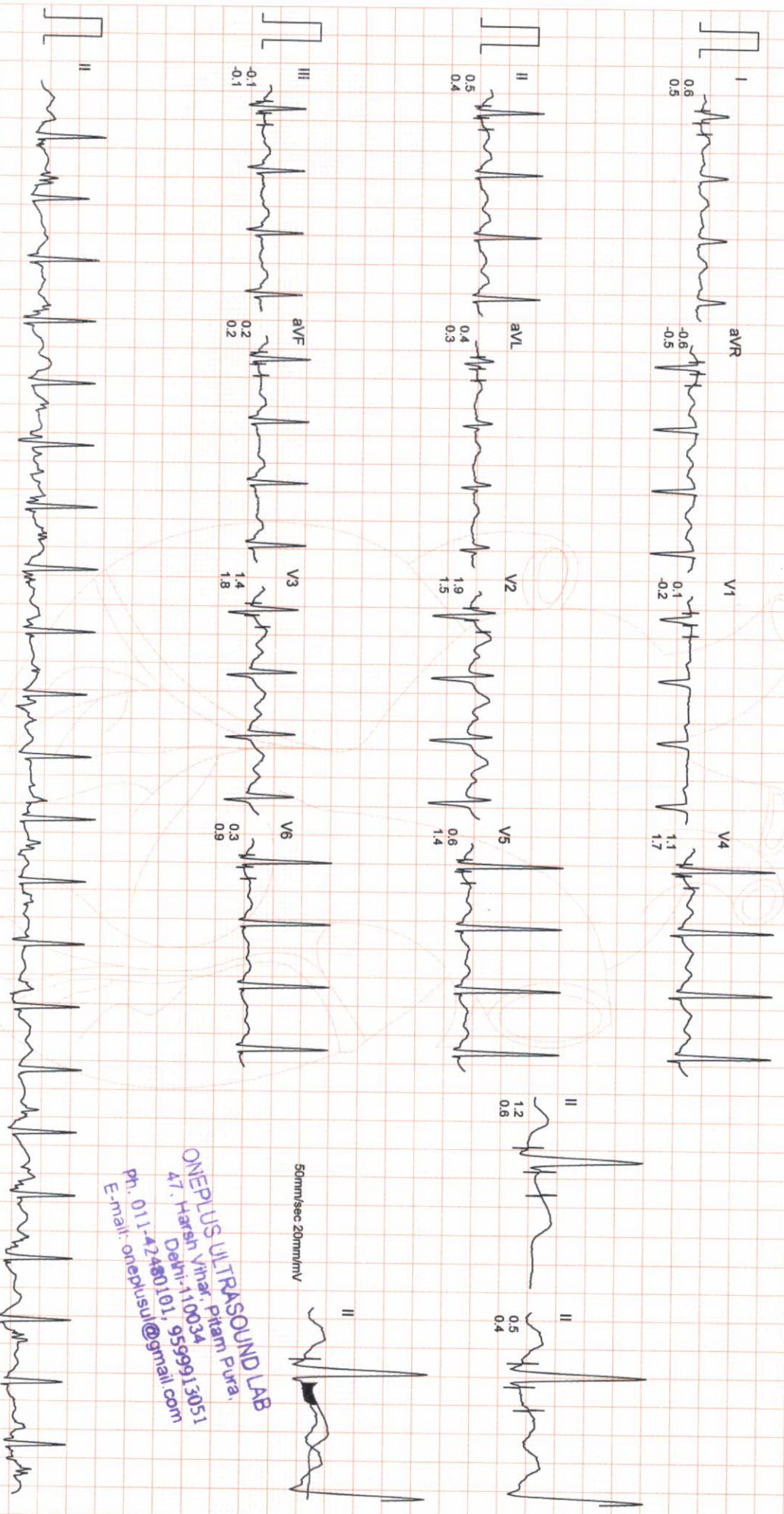
Mr. NEERU
 I.D. : 998
 AGE/SEX : 33/M
 RECORDED : 19-11-2021 10:31

RATE : 137 BPM
 B.P. : 160/88 mmHg

BRUCE
 EXERCISE 3
 PHASE TIME : 8:59
 STAGE TIME : 2:59

ST @ 10mm/mV
 80ms PostJ
 SPEED : 5.4 Km/Hr.
 GRADE : 14.0 %

LINKED MEDIAN



50mm/sec 20mm/mV

ONEPLUS ULTRASOUND LAB
 47, Harsh Vihar, Pitampura,
 Delhi-110034
 Ph. 011-42480101, 9599913051
 E-mail: onepusul@gmail.com

ONEPLUS ULTRASOUND LAB

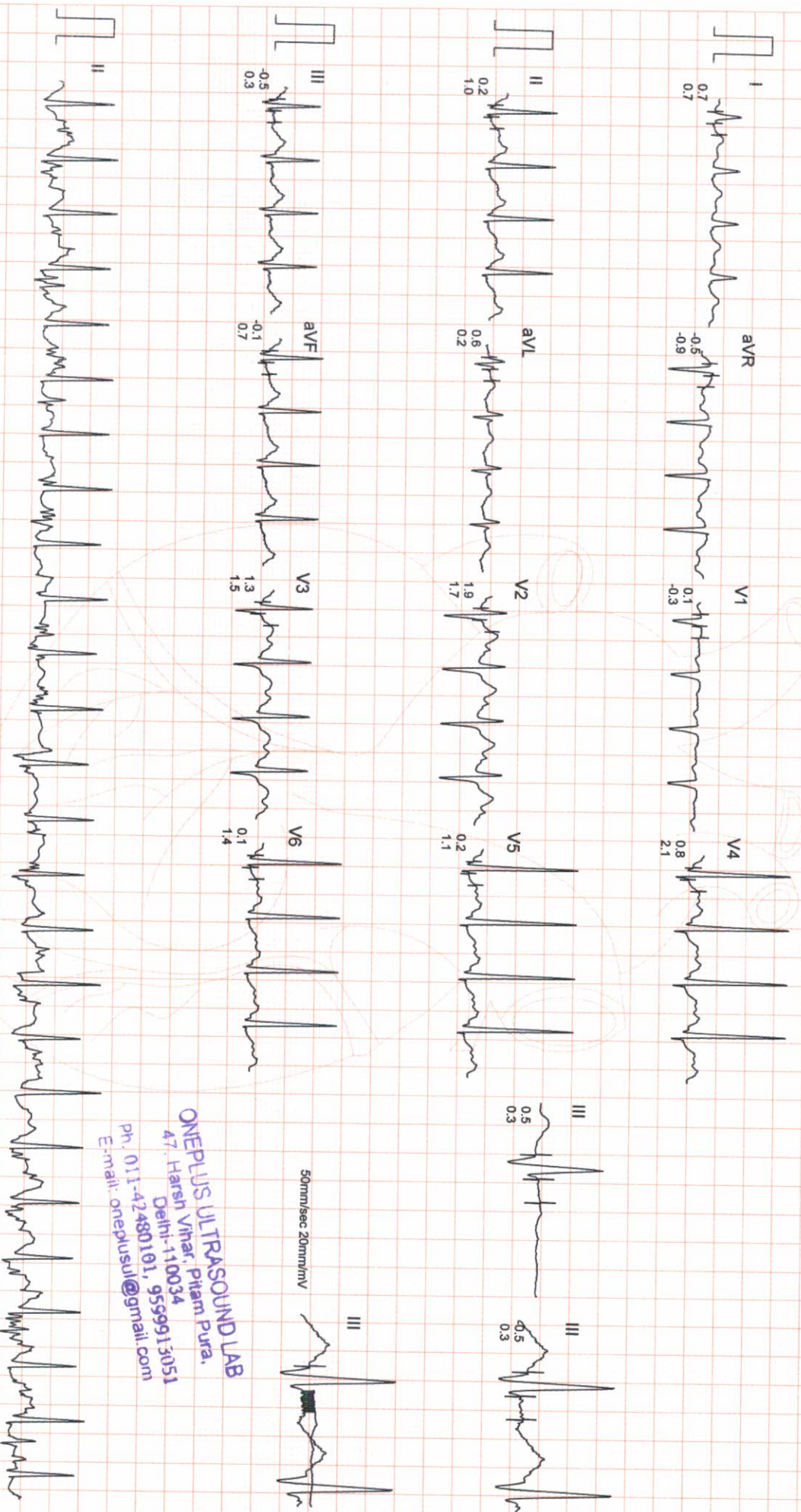
Mr. NEERU
I.D. : 998
AGE/SEX : 33/M
RECORDED : 19-11-2021 10:31

RATE : 158 BPM
B.P. : 160/88 mmHg

BRUCE
EXERCISE 4
PHASE TIME : 9:59
STAGE TIME : 0:59

ST @ 10mm/mV
80ms PostJ
SPEED : 6.7 Km./Hr.
GRADE : 16.0 %

LINKED MEDIAN



50mm/sec 20mm/mV

ONEPLUS ULTRASOUND LAB
47, Harsh Vihar, Pitam Pura,
Delhi-110034
Ph. 011-42480101, 9559913051
E-mail: oneplusul@gmail.com

ONEPLUS ULTRASOUND LAB

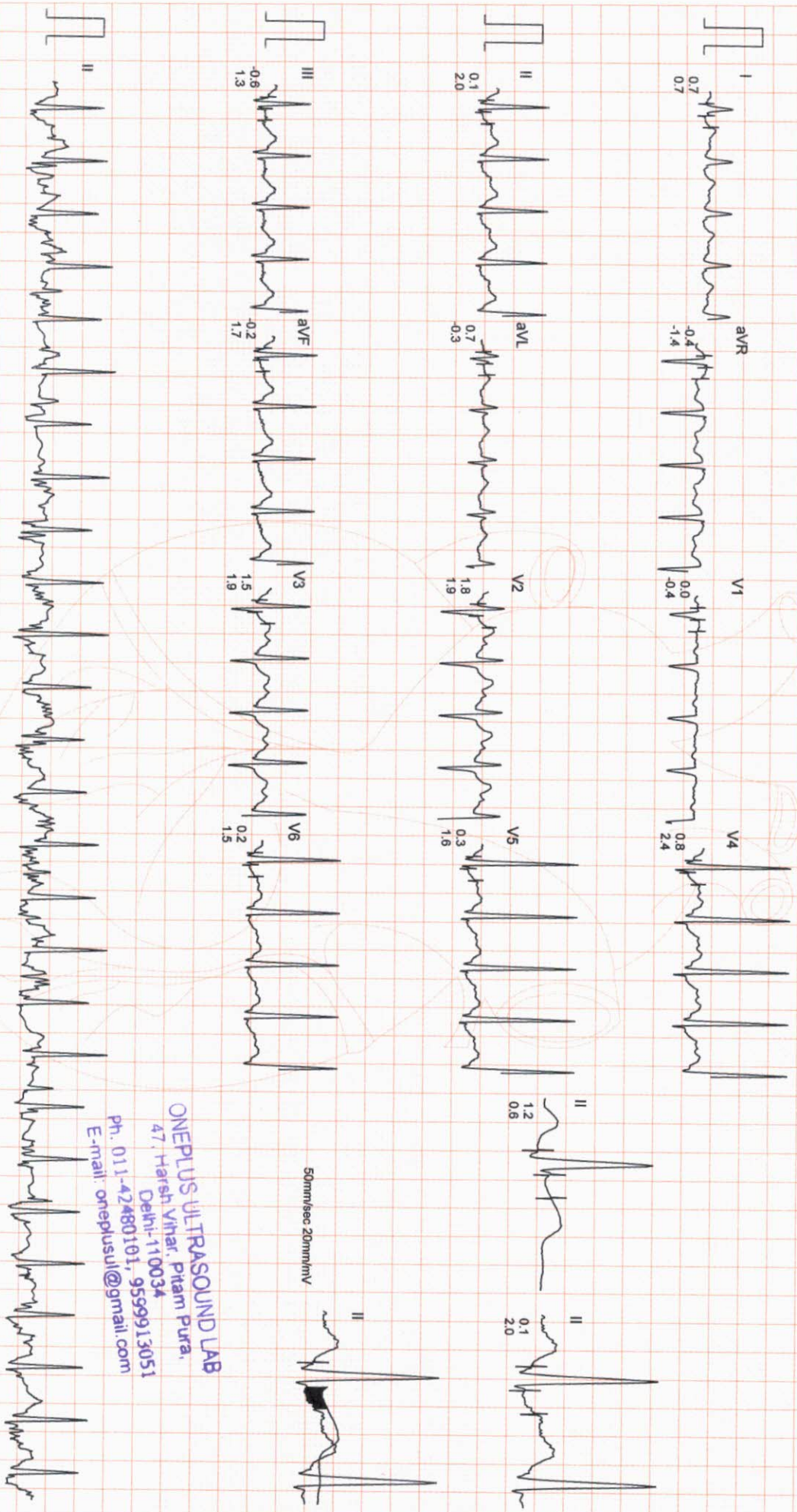
Mr. NEERU
I.D. : 998
AGE/SEX : 33M
RECORDED : 19-11-2021 10:31

RATE : 165 BPM
B.P. : 172/90 mmHg

BRUCE
PEAK EXER
PHASE TIME : 10:12
STAGE TIME : 1:12

ST @ 10mm/mV
80ms PostJ
SPEED : 6.7 Km./Hr.
GRADE : 16.0 %

LINKED MEDIAN



Filtered Computer Corrected Baseline

25mm/sec 10mm/mV

CardiCom, INDIA Ph.:091-731-2620740, TeleFax:091-731-2431214

ONEPLUS ULTRASOUND LAB
47, Harsh Vihar, Pitam Pura,
Delhi-110034
Ph. 011-42480101, 9599913051
E-mail: oneplusul@gmail.com

ONEPLUS ULTRASOUND LAB

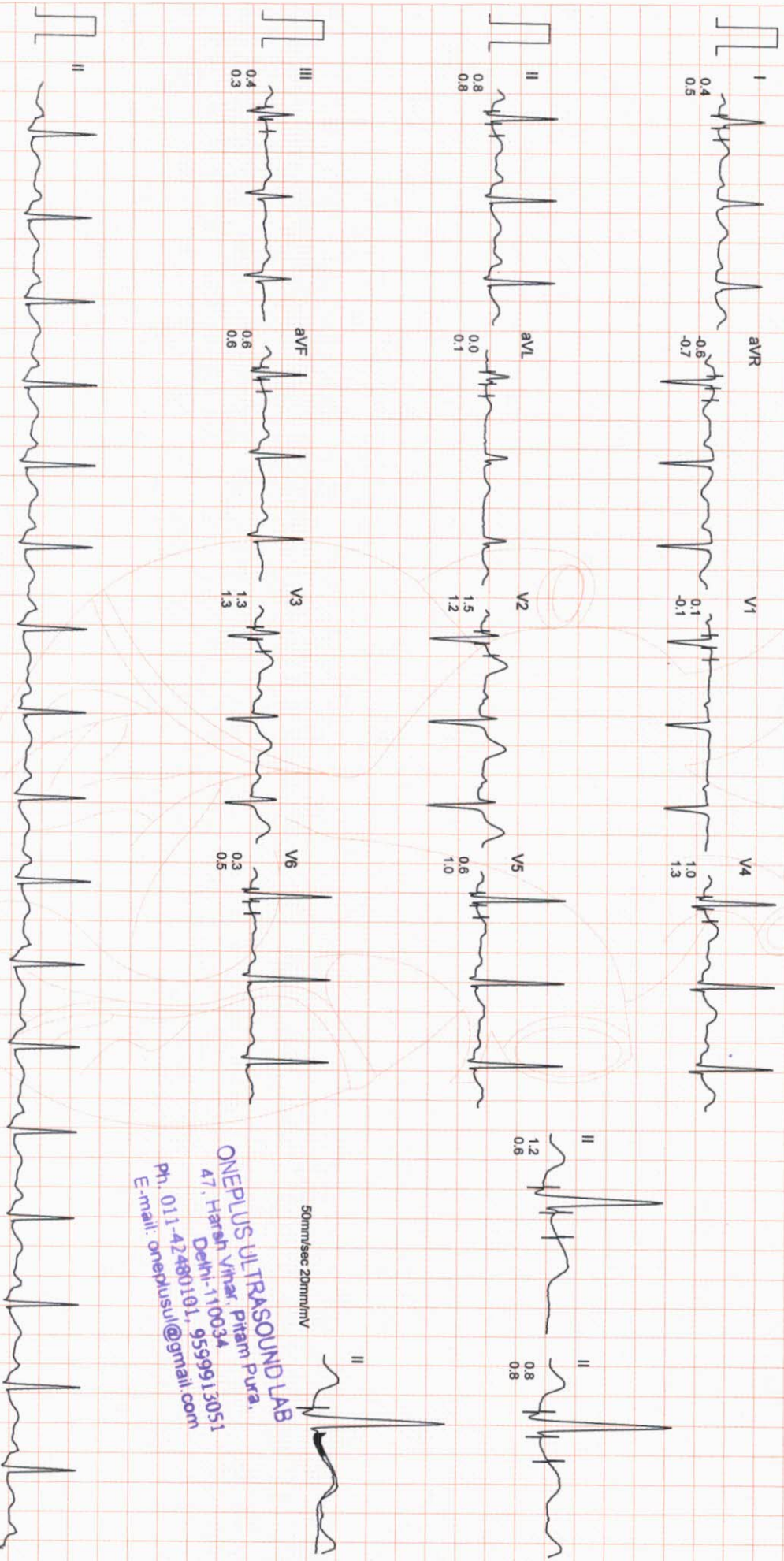
Mr. NEERU
I.D. : 998
AGE/SEX : 33/M
RECORDED : 19-11-2021 10:31

RATE : 106 BPM
B.P. : 130/82 mmHg

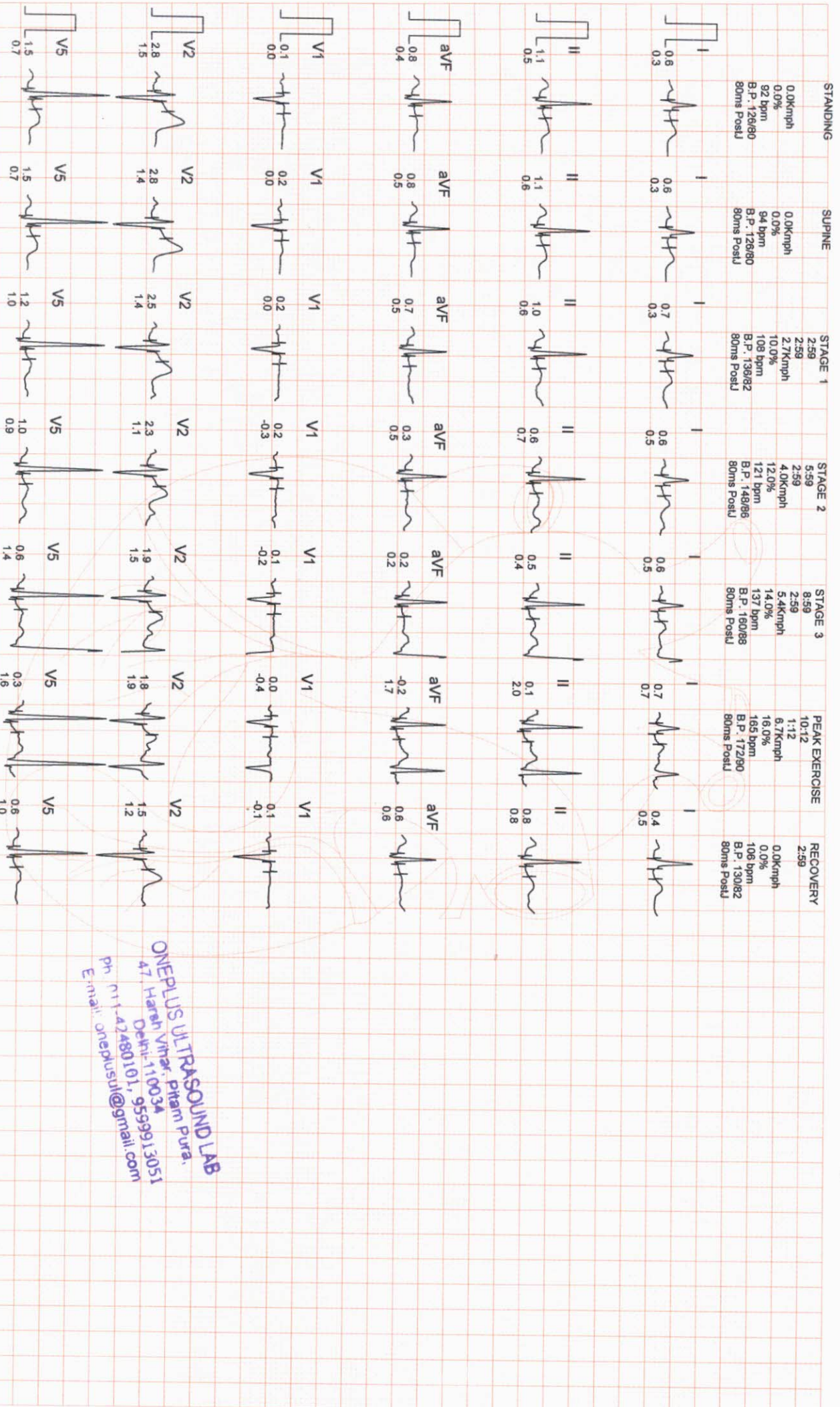
BRUCE
RECOVERY
PHASE TIME : 2:59

ST @ 10mm/mV
80ms PostJ
SPEED : 0.0 Km./Hr.
GRADE : 0.0 %

LINKED MEDIAN



50mm/sec 20mm/mV
ONEPLUS ULTRASOUND LAB
47, Harsh Vihar, Pitam Pura,
Delhi-110034
Ph. 011-42480101, 9559913051
E-mail: oneplusul@gmail.com




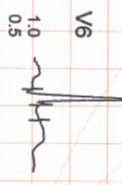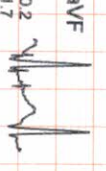





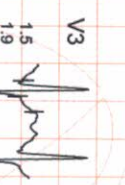

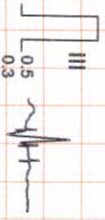





ONEPLUS ULTRASOUND LAB
 47, Hareh Vihar, Pitam Pura,
 Delhi-110034
 Ph: 111-42480101, 9559913051
 E-mail: oneplusul@gmail.com

SUPINE
 0.0kmph
 0.0%
 94 bpm
 B.P. 126/80
 80ms Postu

PEAK EXERCISE
 10:12
 1:12
 6.7kmph
 16.0%
 165 bpm
 B.P. 172/90
 80ms Postu

SUPINE
 0.0kmph
 0.0%
 94 bpm
 B.P. 126/80
 80ms Postu

PEAK EXERCISE
 10:12
 1:12
 6.7kmph
 16.0%
 165 bpm
 B.P. 172/90
 80ms Postu



ONEPLUS ULTRASOUND LAB
 47, Harsh Vihar, Pitam Pura,
 Delhi-110034
 Ph. 011-42480101, 9559913051
 E-mail: oneplusul@gmail.com



OnePLUS
Ultrasound Lab
— QUALITY FIRST... ALWAYS! —

Dr. Nitin Agarwal
Pathologist & Director
Ex. Sr. Res. MAMC
& Lok Nayak Hospital
Ex. Chief of Lab Dr. Lal Path Labs.

Dr. Pooja (Garg) Agarwal
Radiologist & Director
MAMC & Lok Nayak Hospital

Name	: Mr. NEERU	Age/Sex	: 33 YRS/Male
Ref. By	: Dr. MEDIWHEEL	Lab No	: 012111190014
Date	: 19-Nov-2021	Patient ID	: LSHHI87414

ULTRASOUND EXAMINATION---WHOLE ABDOMEN

Liver is **enlarged** in size (16.4 cm) and normal in outline with **altered echopattern**. **Diffuse increase in echogenicity of liver parenchyma is noted, suggestive of fatty infiltration (grade II)**. **Intrahepatic biliary radicles are not dilated**. No abscess or mass lesion seen. Hepatic veins, portal vein, IVC and aorta are normal. CBD is normal in caliber.

Gall bladder is well distended with anechoic lumen. Wall thickness is normal.

Both kidneys are normal in size, shape, position, outline and echopattern. Corticomedullary differentiation is maintained. No pelvicalyceal dilation or mass lesion is seen.

Renal measurements are --

Rt. Kidney - 10.5 x 4.2 cm.

Lt. kidney - 10.5 x 4.6 cm

Spleen is normal in size and echotexture. No mass lesion seen.

Pancreas is normal in size, outline and echotexture.

Urinary bladder is normal in shape and position. No evidence of intravesical stone or mass seen.

Prostate is normal in size, shape and echopattern.

Prostate measures 3.1 x 2.8 x 4.1 cm. **Weight of prostate is 18.4 grams**.

No abnormal bowel wall thickening seen in right iliac fossa.
No free fluid seen anywhere in abdomen.

IMPRESSION:

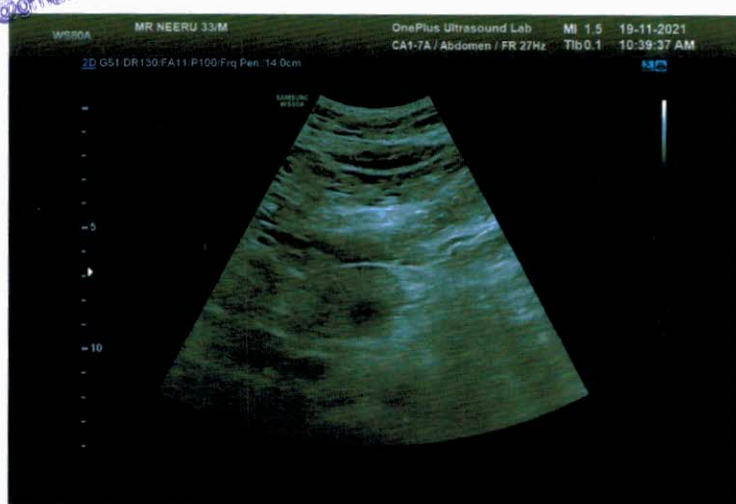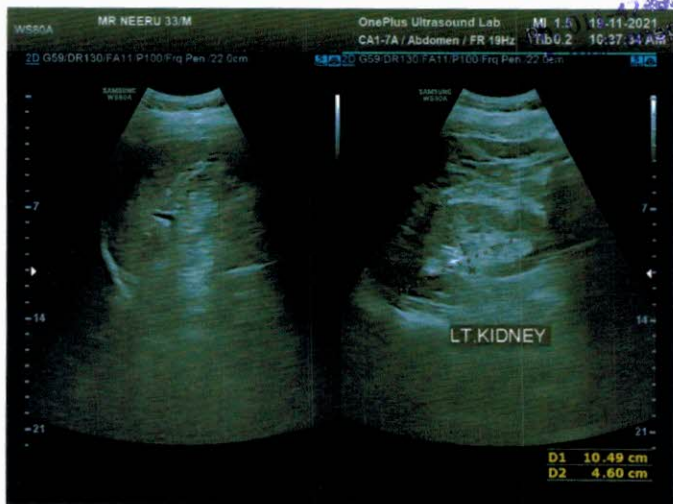
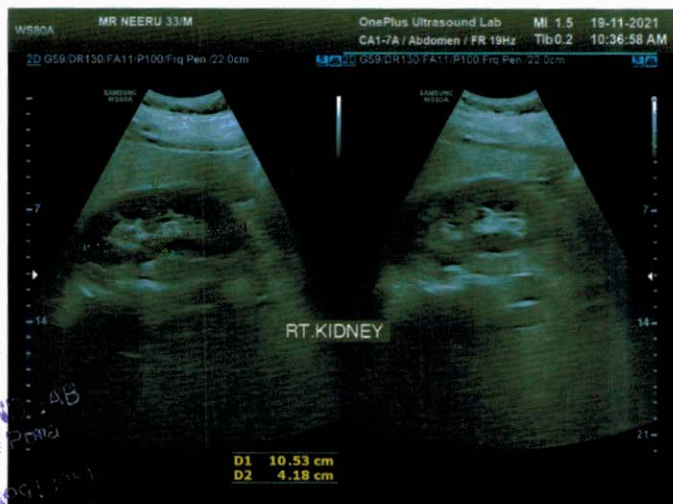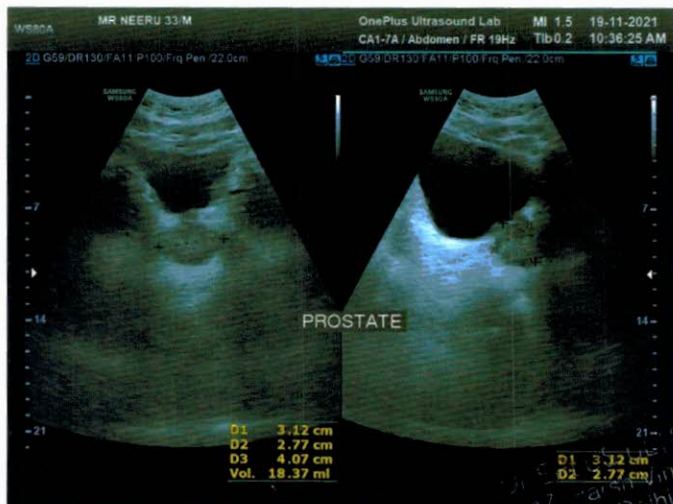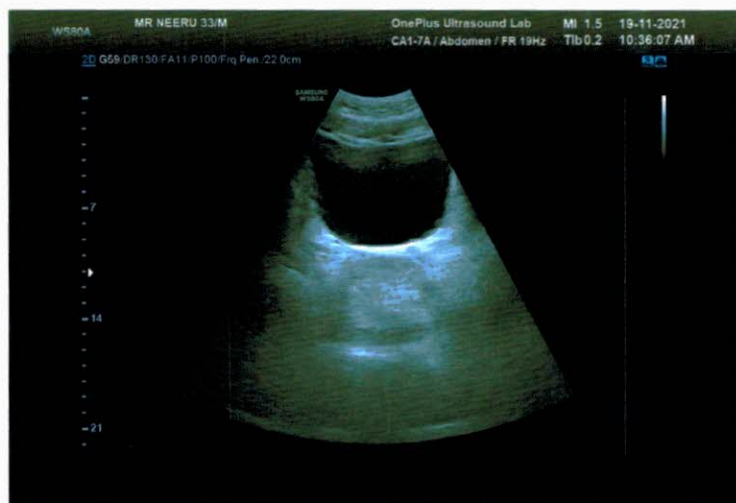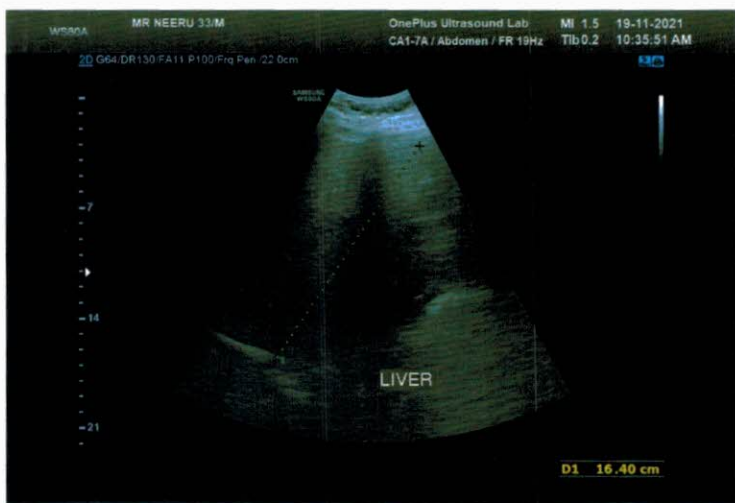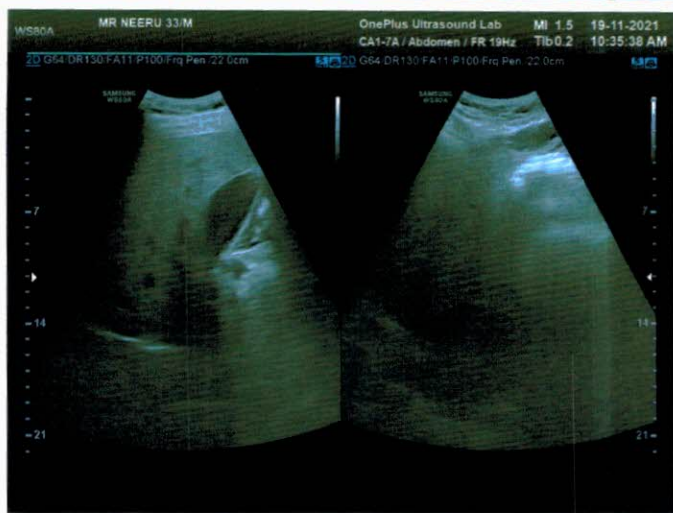
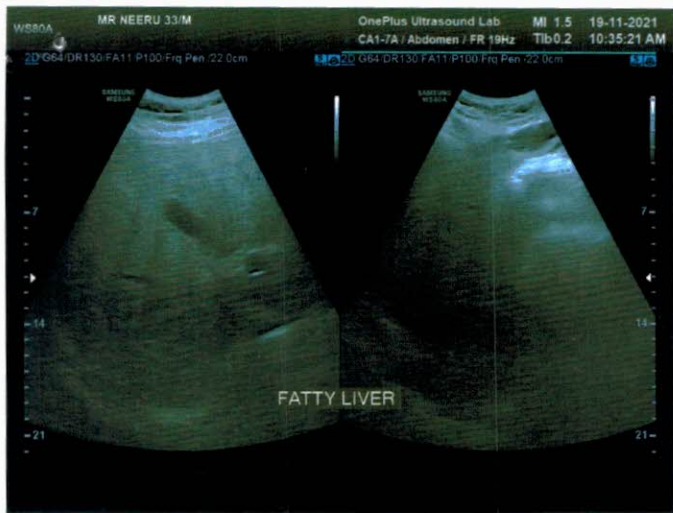- **Fatty infiltration of liver (grade II) with hepatomegaly.**

DR. POOJA GARG
RADIOLOGIST
REG NO- DMC/R/03398

Dr. POOJA GARG
M.B.B.S., D.M.R.D
Reg No. DMC/R/03398
Radiologist

Type By : pooja

47, Harsh Vihar, Pitampura, New Delhi-110034 | Ph.: 011-42480101, 9599913051
E-mail: onepusul@gmail.com | Web.: www.oneplusul.in



AB
SOUND
Pram
Delhi
1003
1001. 9999
@gmail.com



OnePLUS
Ultrasound Lab

— QUALITY FIRST... ALWAYS! —

Dr. Nitin Agarwal

Pathologist & Director
Ex. Sr. Res. MAMC
& Lok Nayak Hospital
Ex. Chief of Lab Dr. Lal Path Labs.

Dr. Pooja (Garg) Agarwal

Radiologist & Director
MAMC & Lok Nayak Hospital

Name	: Mr. NEERU	Age/Sex	: 33 YRS/Male
Ref. By	: Dr. MEDIWHEEL	Lab No	: 012111190014
Date	: 19-Nov-2021	Patient ID	: LSHHI87414

X-ray-Chest PA view

Bony cage and soft tissues are normal.

Cardiothoracic ratio is normal.

Mediastinum is normal.

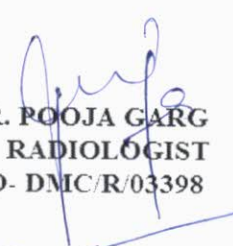
Both hila are normal.

Both costophrenic angles are clear.

Both domes of diaphragm are normal.

Lung fields are clear. No parenchymal lesion seen.

IMPRESSION: Normal Study.


DR. POOJA GARG
RADIOLOGIST
REG NO- DMC/R/03398

Dr. POOJA GARG
M.B.B.S., D.M.R.D.
Reg No. DMC/R/03398
Radiologist

Type By : pooja

47, Harsh Vihar, Pitampura, New Delhi-110034 | Ph.: 011-42480101, 9599913051

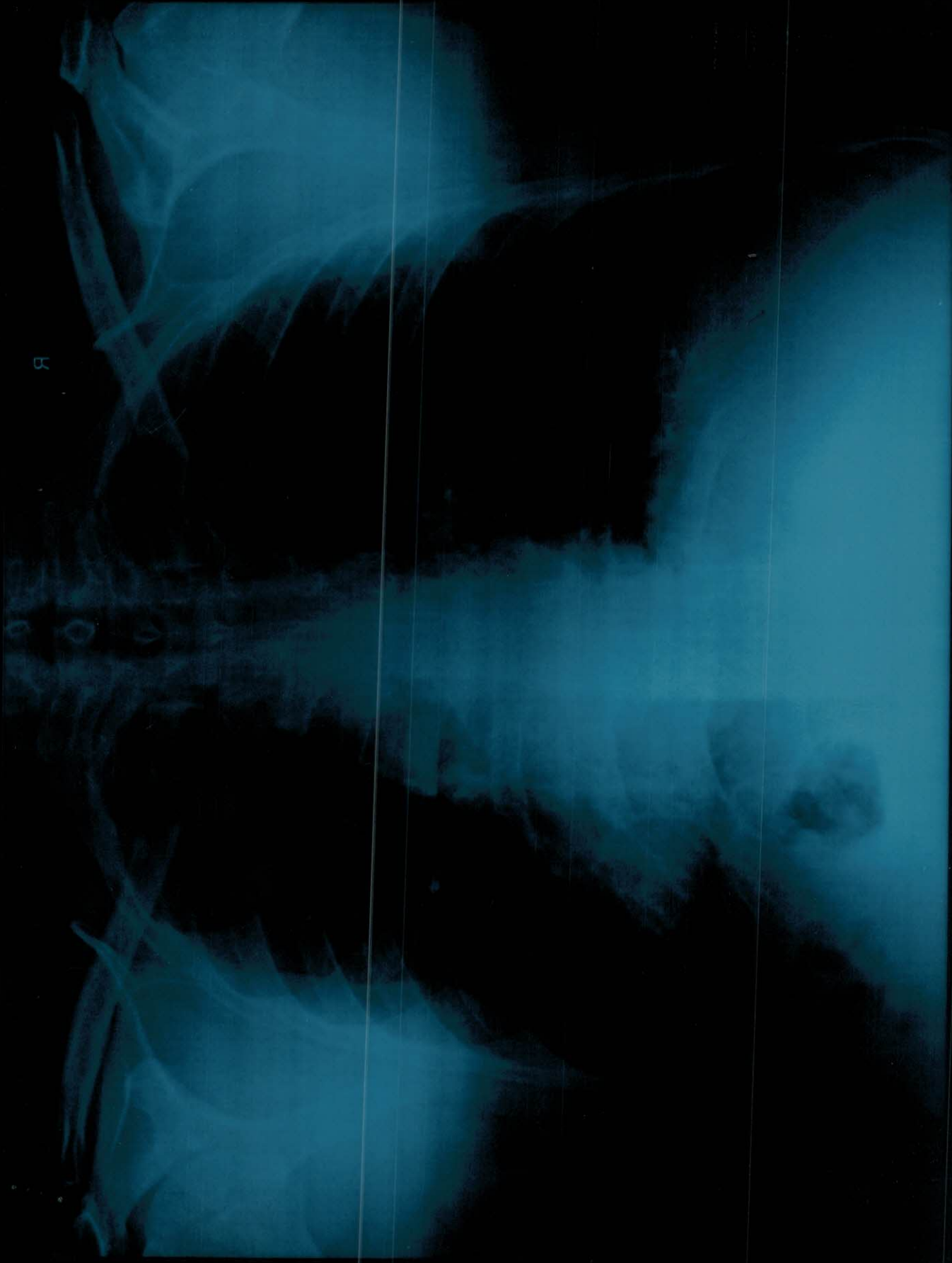
E-mail: oneplusul@gmail.com | Web.: www.oneplusul.in

Clinical correlation is essential for final diagnosis. • If test results are unsatisfactory please contact personally or on phone. • This report is for perusal of doctors only.
• All disputes Subject to Delhi Jurisdiction only. • Not for medicolegal purposes. • All congenital anomalies in a foetus may not be diagnosed in routine obstetric ultrasound.

R

MR NEERU 33 YRS 19/11/2021 M CHEST PA VIEW 11/19/2021
ONEPLUS ULTRASOUND LAB, 47-HARSH VIHAR, PITAMPURA

ONEPLUG ULTRASOUND LAB, 43-HARSH NIHAR, BILAMPURA
MR NEERU 33 YRS 19/11/5051 M CHEST PA VIEW 11/12/5051



R



OnePLUS Ultrasound Lab

Dr. Nitin Agarwal
Pathologist & Director
Ex. Sr. Res. MAMC
& Lok Nayak Hospital
Ex. Chief of Lab Dr. Lal Path Labs.

Dr. Pooja (Garg) Agarwal
Radiologist & Director
MAMC & Lok Nayak Hospital



QUALITY FIRST... ALWAYS!			
NAME	:Mr. NEERU	Barcode No	:10108541
AGE/GENDER	:33 YRS/Male	SPECIMEN DATE	:19/Nov/2021 10:04AM
PATIENT ID	:87414	SPECIMEN RECEIVED	:19/Nov/2021 10:10AM
REFERRED BY	:Dr. MEDIWHEEL	REPORT DATE	:19/Nov/2021 12:20PM
CENTRE NAME	:ONEPLUS ULTRASOUND LAB	LAB NO.	:012111190014

Test Name	Result	Unit	Ref. Range
-----------	--------	------	------------

HAEMATOTOLOGY

Health checkup 2 Male

Glycosylated Hemoglobin (HbA1c)	5.2	%	<6.0%
Estimated average blood glucose (eag)	103		

Reference range (mg/dl):

90 - 120:Excellent control, 121 - 150:Good Control, 151 - 180:Average Control, 181 - 210:Action Suggested
>211:Panic value

REMARKS:-

In vitro quantitative determination of **HbA1C** in whole blood is utilized in long term monitoring of glycemia. The **HbA1C** level correlates with the mean glucose concentration prevailing in the course of the patient's recent history (approx - 6-8 weeks) and therefore provides much more reliable information for glycemia monitoring than do determinations of blood glucose or urinary glucose. It is recommended that the determination of **HbA1C** be performed at intervals of 4-6 weeks during Diabetes Mellitus therapy. On testing of HbA1C by HPLC method the result shows high variant window (93.8%) & no value of HbA1C. Therefore for accurate assay of glycaemic Control Fructosamine assay & for variant analysis Hb electrophoresis should be done.

Assay done by : Bio-Rad : D-10 (HPLC)

BLOOD GROUP (ABO)	B
Rh typing	POSITIVE

NOTE :

- * Apart from major A,B,H antigens which are used for ABO grouping and Rh typing, many minor blood group antigens exist. Agglutination may also vary according to titre of antigen and antibody.
- * So before transfusion, reconfirmation of blood group as well as cross-matching is needed.
- * Presence of maternal antibodies in newborns, may interfere with blood grouping.
- * Auto agglutination (due to cold antibody, falciparum malaria, sepsis, internal malignancy etc.) may also cause erroneous result.

CBC

Haemoglobin	13.6	g/dl	13.0-17.0
Total Leucocyte Count	9390	/cumm	4000-10000

Differential leucocyte count

Checked By.

DR. NITIN AGARWAL
MBBS MD(PATHOLOGIST)

Dr NITIN AGARWAL
MBBS, MD (Path)

47, Harsh Vihar, Pitampura, New Delhi-110034 | Ph.: 011-42480101, 9599113051

E-mail: oneplusul@gmail.com | Web.: www.oneplusul.in

Page 1 of 9

Clinical correlation is essential for final diagnosis. • If test results are unsatisfactory please contact personally or on phone. • This report is for perusal of doctors only. • All disputes Subject to Delhi Jurisdiction only. • Not for medicolegal purposes. • All congenital anomalies in a foetus may not be diagnosed in routine obstetric ultrasound.



OnePLUS Ultrasound Lab

Dr. Nitin Agarwal
Pathologist & Director
Ex. Sr. Res. MAMC
& Lok Nayak Hospital
Ex. Chief of Lab Dr. Lal Path Labs.

Dr. Pooja (Garg) Agarwal
Radiologist & Director
MAMC & Lok Nayak Hospital



QUALITY FIRST... ALWAYS!			
NAME	:Mr. NEERU	Barcode No	:10108541
AGE/GENDER	:33 YRS/Male	SPECIMEN DATE	:19/Nov/2021 10:04AM
PATIENT ID	:87414	SPECIMEN RECEIVED	:19/Nov/2021 10:10AM
REFERRED BY	:Dr. MEDIWHEEL	REPORT DATE	:19/Nov/2021 12:20PM
CENTRE NAME	:ONEPLUS ULTRASOUND LAB	LAB NO.	:012111190014

Test Name	Result	Unit	Ref. Range
Neutrophils	53.9	%	40-80
Lymphocyte	38.90	%	20-40
Monocytes	5.70	%	2-10
Eosinophils	1.2	%	1-6
Basophils	0.3	%	0-2
RBC Count	5.48	million/cumm	4.5 - 5.5
PCV(Hematocrit)	42	%	40-50
MCV	76.5	fL	83-101
MCH	24.7	Pg	27-32
MCHC	32.3	G/dL	32-35
Platelet count	298000	/cumm	150000-450000
RDW-CV	13.6	%	11.4-14.0
ESR(WESTEGRENS METHOD)	14	mm in 1st hr	0-20
BIOCHEMISTRY			
<u>Blood sugar fasting</u>	88	mg/dL	70-110

Checked By.

DR. NITIN AGARWAL
MBBS, MD (PATHOLOGIST)
DMC/R/01436

47, Harsh Vihar, Pitampura, New Delhi-110034 | Ph.: 011-42480101, 9599913051
E-mail: oneplusul@gmail.com | Web.: www.oneplusul.in



OnePLUS Ultrasound Lab

Dr. Nitin Agarwal
Pathologist & Director
Ex. Sr. Res. MAMC
& Lok Nayak Hospital
Ex. Chief of Lab Dr. Lal Path Labs.

Dr. Pooja (Garg) Agarwal
Radiologist & Director
MAMC & Lok Nayak Hospital



QUALITY FIRST... ALWAYS!			
NAME	:Mr. NEERU	Barcode No	:10108541
AGE/GENDER	:33 YRS/Male	SPECIMEN DATE	:19/Nov/2021 10:04AM
PATIENT ID	:87414	SPECIMEN RECEIVED	:19/Nov/2021 03:56PM
REFERRED BY	:Dr. MEDIWHEEL	REPORT DATE	:19/Nov/2021 04:55PM
CENTRE NAME	:ONEPLUS ULTRASOUND LAB	LAB NO.	:012111190014

Test Name	Result	Unit	Ref. Range
BIOCHEMISTRY			
Blood sugar pp	154	mg/dL	70.0-140.0

Checked By.

DR. NITIN AGARWAL
MBBS,MD(PATHOLOGIST)

Dr NITIN AGARWAL
MBBS, MD (Path)
DMC/R/01430

47, Harsh Vihar, Pitampura, New Delhi-110034 | Ph.: 011-42480101, 9599913051

E-mail: oneplusul@gmail.com | Web.: www.oneplusul.in

Page 3 of 9



Dr. Nitin Agarwal

Pathologist & Director

Ex. Sr. Res. MAMC

& Lok Nayak Hospital

Ex. Chief of Lab Dr. Lal Path Labs.

Dr. Pooja (Garg) Agarwal

Radiologist & Director

MAMC & Lok Nayak Hospital

OnePLUS

Ultrasound Lab



QUALITY FIRST... ALWAYS!			
NAME	:Mr. NEERU	Barcode No	:10108541
AGE/GENDER	:33 YRS/Male	SPECIMEN DATE	:19/Nov/2021 10:04AM
PATIENT ID	:87414	SPECIMEN RECEIVED	:19/Nov/2021 10:10AM
REFERRED BY	:Dr. MEDIWHEEL	REPORT DATE	:19/Nov/2021 12:20PM
CENTRE NAME	:ONEPLUS ULTRASOUND LAB	LAB NO.	:012111190014

Test Name	Result	Unit	Ref. Range
-----------	--------	------	------------

BIOCHEMISTRY

<u>Bun (blood urea nitrogen)</u>	12.60	mg/dl	8.9-21.6
<u>Uric acid, serum</u>	4.6	mg/dl	3.4-7.0
<u>Creatinine, serum</u>	0.75	mg/dl	0.60-1.1

LFT(LIVER FUNCTION TEST)

Bilirubin Total	0.68	mg/dl	0.1-1.2
Bilirubin Conjugated	0.24	mg/dl	0-0.4
Bilirubin Unconjugated	0.44	mg/dl	up to 0.7
SGOT (AST)	30	U/L	0-35
SGPT (ALT)	24	U/L	<45.0
Alkaline phosphatase	79	U/L	40-129
Gamma glutamyl transpeptidase	25	U/L	<66
Total Protein	6.8	gm/dl	6.60 - 8.70
Albumin	3.8	g/dL	3.8-5.1
Globulin	3.00	gm/dl	1.8-3.4
Albumin/Globulin Ratio	1.27		1.10 - 2.50

LIPID PROFILE

Cholesterol	209	mg/dl	50-200
Triglycerides	105	mg/dL	25-150
HDL Cholesterol	45	mg/dL	30-70
LDL cholesterol	143	mg/dL	<130
VLDL cholesterol	21.0	mg/dL	5-40
Cholesterol/HDL Ratio	4.6		Low Risk 3.3-4.97 Average Risk 4.4-7.1 Moderate Risk 7.1-11.0 High Risk >11.0
LDL/HDL Ratio	3.2		0 - 3.55

According to ATP III and NCEP guidelines

Checked By.

DR. NITIN AGARWAL
MBBS,MD(PATHOLOGIST)

Dr NITIN AGARWAL
MBBS, MD (Path)
19/11/2021

47, Harsh Vihar, Pitampura, New Delhi-110034 | Ph.: 011-42480101, 9599918051

E-mail: oneplusul@gmail.com | Web.: www.oneplusul.in

Page 4 of 9



OnePLUS Ultrasound Lab

Dr. Nitin Agarwal
Pathologist & Director
Ex. Sr. Res. MAMC
& Lok Nayak Hospital
Ex. Chief of Lab Dr. Lal Path Labs.


Dr. Pooja (Garg) Agarwal
Radiologist & Director
MAMC & Lok Nayak Hospital



QUALITY FIRST... ALWAYS!			
NAME	:Mr. NEERU	Barcode No	:10108541
AGE/GENDER	:33 YRS/Male	SPECIMEN DATE	:19/Nov/2021 10:04AM
PATIENT ID	:87414	SPECIMEN RECEIVED	:19/Nov/2021 10:10AM
REFERRED BY	:Dr. MEDIWHEEL	REPORT DATE	:19/Nov/2021 12:20PM
CENTRE NAME	:ONEPLUS ULTRASOUND LAB	LAB NO.	:012111190014

Test Name	Result			Unit	Ref. Range
	Normal	Desirable	Borderline		
Total cholesterol	<200	200-239			240
Triglycerides	<150	150-199	200-499		500
LDL	Optimal <100 Near Optimal 100-129	130-159	160-180		190
HDL	<40 : LOW 60 : HIGH				

Checked By.


DR. NITIN AGARWAL
MBBS,MD(PATHOLOGIST)

Dr NITIN AGARWAL
MBBS, MD (Path)
DMC/R/01436

47, Harsh Vihar, Pitampura, New Delhi-110034 | Ph.: 011-42480101, 9599913051
E-mail: oneplusul@gmail.com | Web.: www.oneplusul.in



OnePLUS Ultrasound Lab

ITD-ISE INFOSYSTEMS PVT. LTD.

Dr. Nitin Agarwal
Pathologist & Director
Ex. Sr. Res. MAMC
& Lok Nayak Hospital
Ex. Chief of Lab Dr. Lal Path Labs.

Dr. Pooja (Garg) Agarwal
Radiologist & Director
MAMC & Lok Nayak Hospital



QUALITY FIRST... ALWAYS!			
NAME	:Mr. NEERU	Barcode No	:10108541
AGE/GENDER	:33 YRS/Male	SPECIMEN DATE	:19/Nov/2021 10:04AM
PATIENT ID	:87414	SPECIMEN RECEIVED	:19/Nov/2021 10:10AM
REFERRED BY	:Dr. MEDIWHEEL	REPORT DATE	:19/Nov/2021 01:38PM
CENTRE NAME	:ONEPLUS ULTRASOUND LAB	LAB NO.	:012111190014

Test Name	Result	Unit	Ref. Range
-----------	--------	------	------------

ENDOCRINOLOGY

PSA TOTAL


Prostatic specific antigen, Total 1.20 ng/ml <4.0

< 40 years	0.21 to 1.72 ng/ml
40 - 49	0.27 to 2.19 ng/ml
50 - 59	0.27 to 3.42 ng/ml
60 - 69	0.22 to 6.16 ng/ml
> 69	0.21 to 6.77 ng/ml

Notes:

PSA is principally produced by the glandular epithelium of the prostate, and is secreted in the seminal fluid. PSA is also present in urine and blood. PSA acts on seminal fluid to fluidify and increase sperm mobility. PSA levels rise in prostatic pathologies such as benign prostatic hyperplasia (BPH) or prostate cancer.

Checked By.


DR. NITIN AGARWAL
MBBS,MD(PATHOLOGIST)

Dr NITIN AGARWAL

47, Harsh Vihar, Pitampura, New Delhi-110034 | Ph.: 011-42480101, 9599913051

E-mail: oneplusul@gmail.com | Web.: www.oneplusul.in

Page 6 of 9



OnePLUS Ultrasound Lab

Dr. Nitin Agarwal
Pathologist & Director
Ex. Sr. Res. MAMC
& Lok Nayak Hospital
Ex. Chief of Lab Dr. Lal Path Labs.

Dr. Pooja (Garg) Agarwal
Radiologist & Director
MAMC & Lok Nayak Hospital



QUALITY FIRST... ALWAYS!			
NAME	:Mr. NEERU	Barcode No	:10108541
AGE/GENDER	:33 YRS/Male	SPECIMEN DATE	:19/Nov/2021 10:04AM
PATIENT ID	:87414	SPECIMEN RECEIVED	:20/Nov/2021 11:12AM
REFERRED BY	:Dr. MEDIWHEEL	REPORT DATE	:20/Nov/2021 12:33PM
CENTRE NAME	:ONEPLUS ULTRASOUND LAB	LAB NO.	:012111190014

Test Name	Result	Unit	Ref. Range
-----------	--------	------	------------

ENDOCRINOLOGY

THYROID PROFILE(T3,T4,TSH)

Triiodothyronine total [t3]	0.96	ng/dl	0.52-1.9
Thyroxine total [t4]	7.60	µg/dl	4.4 - 10.8
TSH (Thyroid Stimulating Hormone)	2.50	µIU/ml	0.25-5.0

AGE WISE VARIATION IN TSH

AGE	TSH(µIU/ml)	AGE	TSH(µIU/ml)
1-4 weeks	1.00 - 19.0	16-20 yrs	0.25 - 5.0
1-12 mths	1.70 - 9.1	21 - 80 yrs	0.25 - 5.0
1-5 yrs	0.80 - 8.2	I st trimester	0.25 - 5.0
6-10 yrs	0.25 - 5.0	II nd trimester	0.50 - 5.0
11-15 yrs	0.25 - 5.0	III rd trimester	0.4 - 6.0

Reference ranges - Interpretation of Diagnostic tests - (Jacques Wallach)

1. Primary hypothyroidism is accompanied by depressed serum T3 and T4 values and elevated serum TSH level.
2. Primary hyperthyroidism is accompanied by elevated serum T3 and T4 levels along with depressed TSH values.
3. Slightly elevated T3 levels may be found in pregnancy and estrogen therapy, while depressed levels may be encountered in severe illness, renal failure and during therapy with drugs like propranolol and propyl thiouracil.
4. Although elevated TSH levels are nearly always indicative of primary hypothyroidism, and may be seen in secondary thyrotoxicosis

CLINICAL PATHOLOGY

URINE ROUTINE

Physical examination

Quantity	30	ML
Colour	PALE YELLOW	
Transparency	CLEAR	CLEAR
Sp.gravity	1.015	1.010-1.030
pH	6.50	
Reaction	ACIDIC	ACIDIC

Checked By.

DR. NITIN AGARWAL
MBBS,MD(PATHOLOGIST)

Dr NITIN AGARWAL

47, Harsh Vihar, Pitampura, New Delhi-110034 | Ph.: 011-42480101, 9599013054

E-mail: oneplusul@gmail.com | Web.: www.oneplusul.in



OnePLUS Ultrasound Lab

QUALITY FIRST... ALWAYS!

Dr. Nitin Agarwal
Pathologist & Director
Ex. Sr. Res. MAMC
& Lok Nayak Hospital
Ex. Chief of Lab Dr. Lal Path Labs.

Dr. Pooja (Garg) Agarwal
Radiologist & Director
MAMC & Lok Nayak Hospital



NAME	:Mr. NEERU	Barcode No	:10108541
AGE/GENDER	:33 YRS/Male	SPECIMEN DATE	:19/Nov/2021 10:04AM
PATIENT ID	:87414	SPECIMEN RECEIVED	:20/Nov/2021 11:12AM
REFERRED BY	:Dr. MEDIWHEEL	REPORT DATE	:20/Nov/2021 12:33PM
CENTRE NAME	:ONEPLUS ULTRASOUND LAB	LAB NO.	:012111190014

Test Name	Result	Unit	Ref. Range
<u>Chemical examination</u>			
Urine protein	NIL		NIL
Urine sugar	NIL		NIL
Bilirubin, urine	NEGATIVE		NEGATIVE
Urobilinogen	NORMAL		NORMAL
Ketones	NEGATIVE		NEGATIVE
<u>Microscopic examination</u>			
Pus cells.	1-2	/HPF	0-2
Epithelial cells	1-2	/HPF	NIL
R.B.C.	NIL	/HPF	NIL
Casts	NIL	/HPF	NIL
Crystals	NIL	/HPF	NIL
Bacteria	NIL	/HPF	NIL
Others	NIL	NIL	NIL
STOOL ROUTINE			
<u>Physical examination</u>			
Colour	BROWNISH		
Consistency	SEMI FORMED		Semi Formed
Blood	ABSENT		Absent
Mucus	ABSENT		Absent
<u>Chemical examination, stool</u>			
pH	6.00		
<u>Microscopic examination</u>			
Pus cells	0-1	/HPF	
Red blood cells	NIL	/HPF	NIL
Ova	NIL		NIL
Cysts	NIL		NIL
Bacteria	NIL	/HPF	NIL
Others	NIL		

Checked By.

DR. NITIN AGARWAL
MBBS, MD (PATHOLOGIST)

Dr NITIN AGARWAL
M B B S , MD (Path)

47, Harsh Vihar, Pitampura, New Delhi-110034 | Ph.: 011-42480101, 9599913051

E-mail: oneplusul@gmail.com | Web.: www.oneplusul.in

Page 8 of 9



OnePLUS Ultrasound Lab

Dr. Nitin Agarwal
Pathologist & Director
Ex. Sr. Res. MAMC
& Lok Nayak Hospital
Ex. Chief of Lab Dr. Lal Path Labs.

Dr. Pooja (Garg) Agarwal
Radiologist & Director
MAMC & Lok Nayak Hospital



QUALITY FIRST... ALWAYS!			
NAME	:Mr. NEERU	Barcode No	:10108541
AGE/GENDER	:33 YRS/Male	SPECIMEN DATE	:19/Nov/2021 10:04AM
PATIENT ID	:87414	SPECIMEN RECEIVED	:20/Nov/2021 11:12AM
REFERRED BY	:Dr. MEDIWHEEL	REPORT DATE	:20/Nov/2021 12:33PM
CENTRE NAME	:ONEPLUS ULTRASOUND LAB	LAB NO.	:012111190014

Test Name	Result	Unit	Ref. Range
*** End Of Report ***			

Checked By.

DR. NITIN AGARWAL
MBBS, MD (PATHOLOGIST)
DMC/R/01436

47, Harsh Vihar, Pitampura, New Delhi-110034 | Ph.: 011-42480101, 9599913051

E-mail: oneplusul@gmail.com | Web.: www.oneplusul.in

Page 9 of 9