



Dr. B. M. Agarwal
MBBS, DCP
Consultant Pathologist

Self extracted for test from the body
Amr Singh

आकाश सोनी
Akash Soni
जन्म तारीख/DOB: 13/04/1990
पुरुष/ MALE
Mobile No: 8888710177

2050 4064 7620

मेरा आधार, मेरी पहचान

डिवाकर डायग्नोस्टिक सेंटर



E-7/636, पंजाब वीरवारन ब्लॉक के पास, धन रोड, अयो कालीजी अंधाल (म.प.)
 फोन: 0755-2465288, 0755-3520545 फा: 9826340190

Pt.Name :-	Mr. Akash Soni
Age :-	31y/M
Refd. By :-	BOB
Lab.No.:-	197
Date :-	11/12/2021

EXAMINATION OF BLOOD

TEST	RESULT	NORMAL VALUE
Haemoglobin	16.1mg%	Female 12-16gms%, Male 14-18gms%
Red Cell count	5.0	4.5-5.6 million /cumm
Platelet Count	2.52	1.5-5.6 Lac/cumm
Leucocytes per.cu.mm	8200/cumm	5000-11000/cumm
Neutrophils	60%	50-70%
Lymphocytes	32%	20-40%
Eosinophils	05%	0-7%
Monocytes	03%	2-8%
PCV	41.5	37-47
MCV	80.5	76-96
MCH	32.0	27-32
MCHC	33.2	31-35
ESR	05	Male 0-9, Female 0-20mm/FHR
Blood Group	"O" Positive	
S.Bilirubin(Total)	0.80	0.2-1.0mg/dl
Direct	0.32	0.0-0.25mg/dl
Indirect	0.48	
SGOT	25.0	5-35U/L
SGPT	30.5	8-40U/L
Alk Phosphatase	9.0	3-13 KA units
S. Protein(Total)	7.2	6.0-8.0mg%
Albumin	4.0	3.7-5.3mg%
Globulin	3.0	1.5 to 3.5 mg%
AG Ratio	1.24	1-2.0
Blood Urea Nitrogen (BUN)	16.0	7-20 mg/dl
S.Creatine	0.88	0.5-1.4mg/dl
S.Uric Acid	5.3	3.5-7.5mg%
Calcium	9.1	8.5-10.5 gm/dl
GTP	33.0	5-35 U/L/dl
Fasting Blood Sugar	89.5	70 to 110mg/dl
Post prandial Blood Sugar	111.8	Up to 150 mg/dl
Total Serum Cholesterol	175.6	100-250 mg%
Serum Triglyceride	139.8	Up to 160 mg%
Serum Cholesterol HDL	49.2	Up to 65 mg%
Serum Cholesterol LDL	98.4	Up to 125 mg%
VLDL	27.9	Up to 30 mg%
TC/HDL Ratio	3.61	Below 5
Glycosylated Hemoglobin	5.4	Below - 6.0 % -Non Diabetic control
		6-7 % -Excellent control
		Above- 8 % -Poor control



Dr. B. M. Agarwal
 MBBS, DCP


All test have technical limitation. Collaborative clinic pathological interpretation is mandatory. In case of disparity, test may be repeated immediately. Turnover time should be not more than 24 hours. This report is not valid for more than 1 month.

Pt.Name :-	Mr. Akash Soni
Age :-	31y/M
Refd. By :-	BOB
Lab.No.:-	197
Date :-	11/12/2021

URINE ANALYSIS


A. PHYSICAL EXAMINATION		C. MICROSCOPIC EXAMINATION	
1. Colour	Yellow	Pus Cells	2-3/HPF
2. Appearance	Clear	R.B.C.	Nil
3. Specific Gravity	Q.N.S.	Epithelial Cell	1-2/HPF
B. CHEMICAL EXAMINATION		Cast	Nil
1. Reaction	Acidic	Crystals(Cal.Oxa)	Nil
2. Albumin	Absent	Bacteria	Nil
3. Sugar	Nil	Amorphous	Nil
4. Bile Salts	Absent	T. Vaginatis	Nil

URINE COTININE	Negative	By Card method
----------------	----------	----------------



Dr. B. M. Agarwal
 M.B.B.S., DCP
 Pathologist

All test have technical limitation. Collaborative clinic pathological interpretation is mandatory. In case of disparity test may be repeated immediately. Typographic mistakes should be get correct instantly. This report is not valid for medico legal purpose



Dr. B. M. Agarwal
MD, Radiology
Consultant Radiologist
Radiologist

-NO CARDIO PULMONARY PATHOLOGY
-CORRELATE WITH CLINICAL FINDINGS.

IMPRESSION

Both domes and diaphragm normal

Both cp angles clear

Cardiac border normal

Both hilers normal

Both Lungs Field Clear.

Thoracic cage normal

Tricia Central


.....
REPORT

Pt.Name :-	Mr. Akash Soni
Age :-	31y/M
Refd. By :-	BOB
Lab.No.:-	197
Date :-	11/12/2021
Skigram	X Ray Chest PA View
Radiologist	Dr. B.M.Agarwal MD (Radiology)

E-7/636, पञ्जाब नेशनल बँक के पास, फोन रोड, अररा कॉलोनी भीपल (म.प.)
फोन: 0755-2465288, 0755-3520545 मो: 9826340190

डिवाकर डायग्नोस्टिक सेंटर





All test have technical limitation. Collaborative clinic pathological interpretation is mandatory. In case of disparity test may be repeated immediately. Typographic mistakes should be get correct instantly. This report is not valid for medico legal purpose

B. M. Agarwal
MBBS, DCP
Pathologist
Consultant Pathologist

Interpretation:
TSH Levels will be elevated in primary hypothyroidism, TSH levels will be low in Hyperthyroidism there is decreased production of thyroid hormones by the thyroid hence the person may experience symptoms such as weight gain, constipation, cold intolerance and fatigue. Iodine deficiency and Hashimoto thyroiditis is the most common cause of hypothyroidism It makes Thyroid stimulating hormone. If TSH levels are abnormally high it could mean you have an underactive thyroid or hypothyroidism.

TEST	RESULT	NORMAL VALUE
T3 - TOTAL	85.6	82-213 ng/dL
T4 - TOTAL	6.89	6.09-12.23 ug/dL
THYROID STIMULATING HORMONE (TSH)	2.56	0.45-4.25 uI/mL

Thyroid profile

EXAMINATION OF BLOOD

Pt.Name :-	Mr. Akash Soni
Age :-	31y/M
Refd. By :-	BOB
Lab.No.:-	197
Date :-	11/12/2021

डिवाकर डायग्नोस्टिक सेंटर



E-7/636, पंचम नगर क्षेत्र के पास, मंग रोड, अरुण कॉलोनी भापाल (म.प्र.)
फोन: 0755-2465288, 0755-3520545 फा: 9826340190



All test have technical limitation. Collaborative clinic pathological interpretation is mandatory. In case of disparity test may be repeated immediately. Typographic mistakes should be get correct instantly. This report is not valid for medico legal purpose

Dr. B. M. Agarwal
MBBS, DCP
Consultant Pathologist

TEST	RESULT	NORMAL VALUE
PSA	5.03 ng/ml.	0.21-6.77 ng/ml.

EXAMINATION OF BLOOD

Pt.Name :-	Mr. Akash Soni
Age :-	31y/M
Refd. By :-	BOB
Lab.No.:-	197
Date :-	11/12/2021

डिवाकर डायग्नोस्टिक सेंटर
E-7/636, पंचाल रेडियल बैंक के पास, मॉन रोड, अरुण कॉलोनी भीमल (म.प्र.)
फोन: 0755-2465288, 0755-3520545 मो: 9826340190



Dr. P. Savita, MD
MBBS, MD (O&G) Reg. No. 9971
श्री श्री हॉस्पिटल

Dr. Jayant Yadav, MD
MBBS, MD (Radiologist) Reg. No. 4166
सिद्धार्थलॉजिस्ट

PTO

Pancreas appear normal in size, shape and echo texture with smooth contour. No peripancreatic pathology seen. (Not seen due to gases)
Spleen is normal in size and echo texture.
IVC and aorta appear to be normal.
No evidence of lymphadenopathy is noted.
No evidence of free fluid is noted.
Right Kidney is normal in size, shape and position. Corticomedullary differentiation (CMD) is well maintained. Normal cortical thickness is noted. No E/O hydronephrosis or calculus is noted.

Liver appears normal in size and shape with normal outline. Normal/increased parenchymal echogenicity is noted. No E/O focal lesion/IHBR dilatation is seen. Hepatic veins and portal veins appear normal.
No E/O subdiaphragmatic Collection.
Gall Bladder is physiologically well distended. No. E/O echogenic foci in GB lumen. GB wall is normal / thickened. No E/O pericholecystic collection.
Common duct reveals normal course and caliber.

WHOLE ABDOMEN ULTRASOUND REPORT

Indication:

Name: Mrs. Atsah Anvi 31/male
R/B: Health check-up
Age: YRS./F
Date: 11/12/21
No.

श्री. सविता सिद्धार्थलॉजिस्टिक
34, पंतल, मोहिनी अदिति आर्कड, शाहपुरा मस्जिद के पास
भरत नगर रोड, ई-7/194, अरेरा कॉलोनी, भीपाल - 462038
Mob.: 8989649694, 9516333619
Clinic Registration : CL/5392/Jun/2017
PNDT Registration : MPPCPNDT/BPL/2017/206



Left Kidney is normal in size, shape and position. CMD is well maintained. Normal cortical thickness is noted. No E/O hydronephrosis or calculus is noted.

Urinary Bladder is well distended (physiological). its contents are echo free. No E/O bladder wall thickening is noted. ~~Post-void residue is insignificant.~~

Prostate is normal in size. Shape and echo texture with smooth outline. No E/O focal lesion is noted.

Uterus is ante/ retro verted and normal in size, shape and echo texture with smooth outline. No E/O focal lesion is noted. Endometrial echo appear normal. Cervical and vaginal shadows appear normal.

Right Ovary appears enlarged / Normal in size, shape and echo texture.

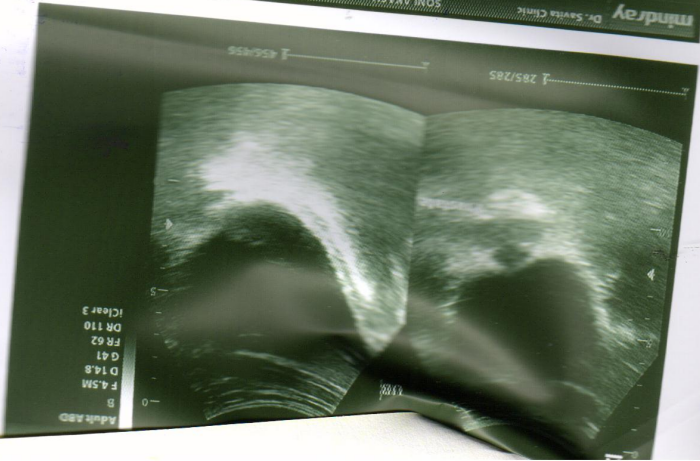
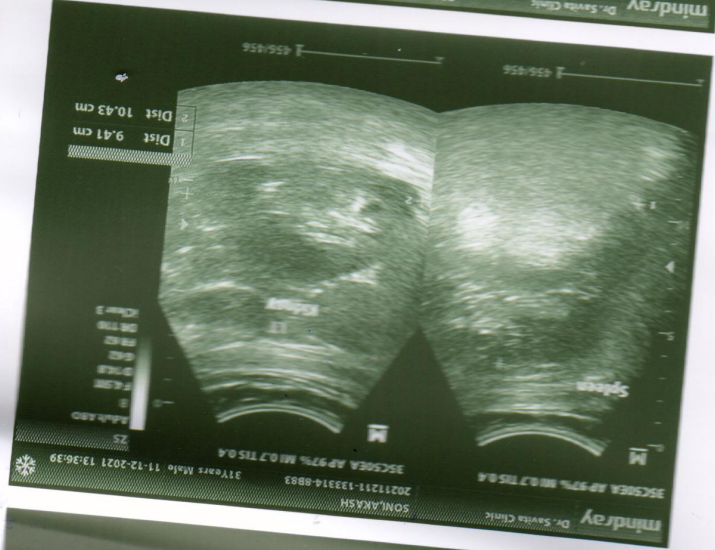
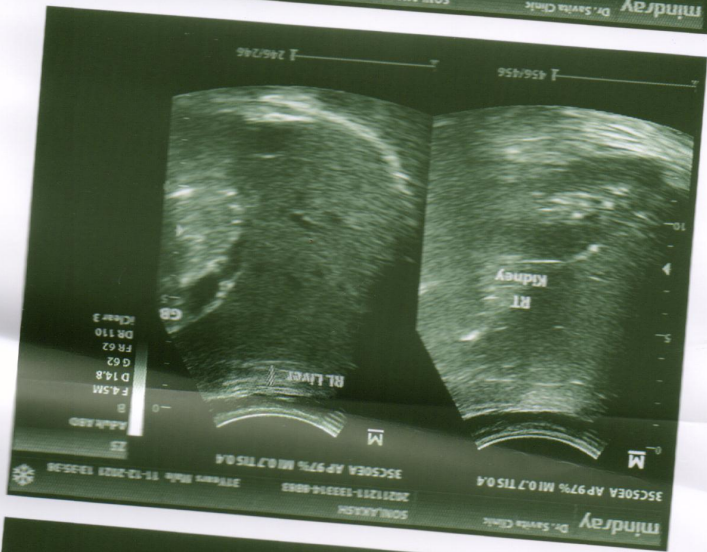
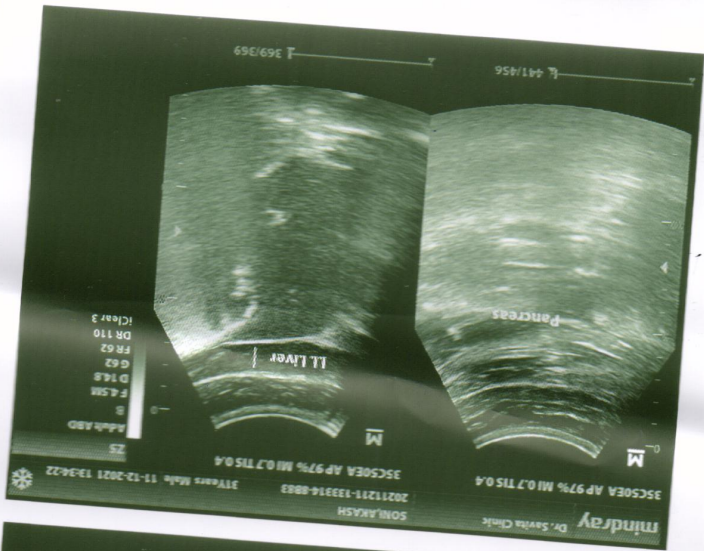
Left Ovary appears enlarged / Normal in size, shape and echo texture.

Impression : Normal study.

Advised clinical Correlation.

Dr. P. Savita, MD
MBBS, MD (O&G) Reg. No. 9971
स्त्री रोग विशेषज्ञ

Dr. Jayant Vaday, MD
MBBS, MD (Radiologist) Reg. No. 4166
डॉ. जयंत वाडय



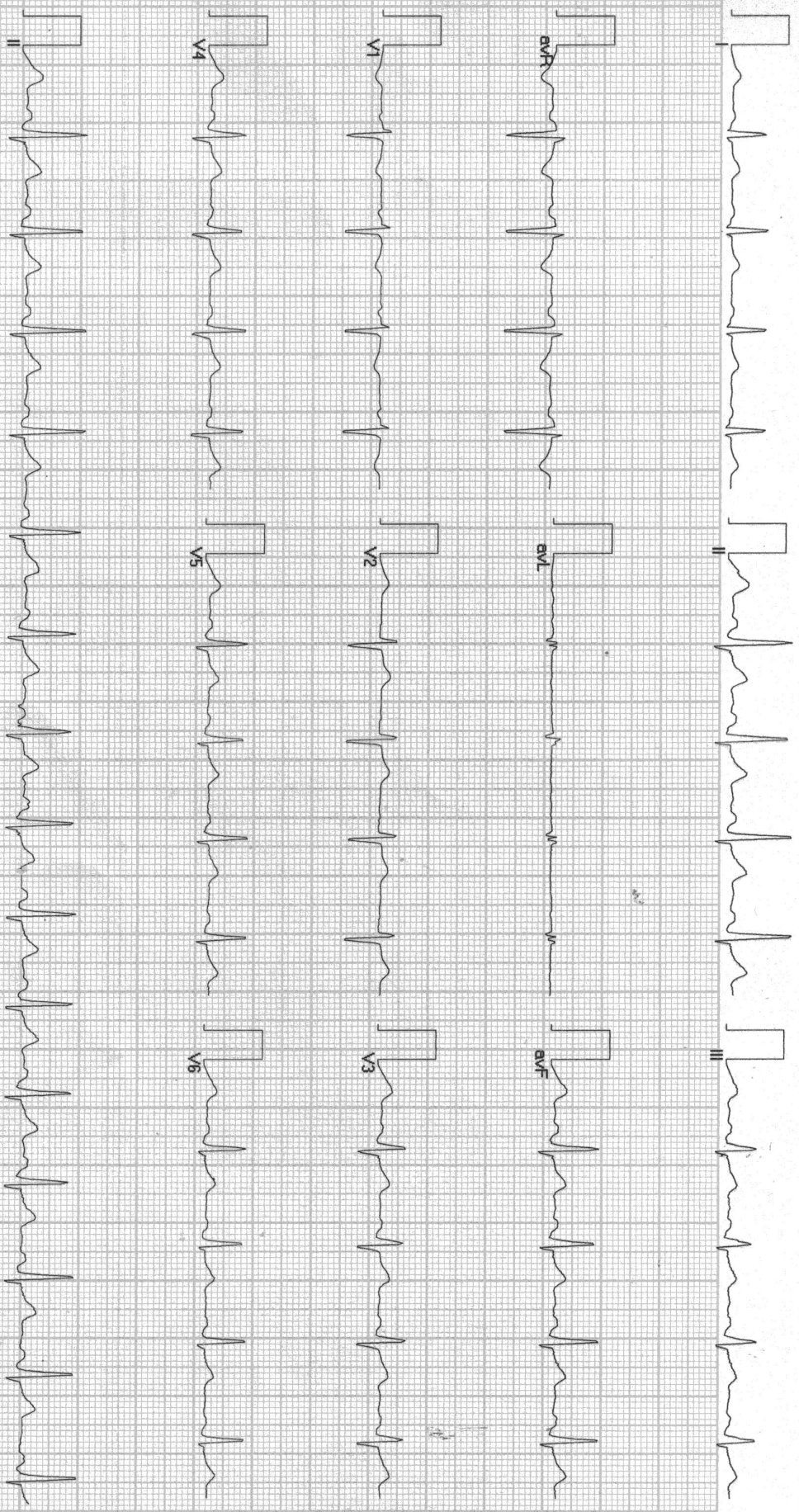
Allengers Global Healthcare Pvt Ltd.

4 / MR. AKASH SONI / 31 Yrs / M / 172Cms / 56Kgs.
Heart Rate : 90 bpm / Tested On : 11-Dec-21 13:49:36 / HF 0.06 Hz - LF 100 Hz / Notch 50 Hz / Sn 1.00 Cm/mV / Sw 25 mm/s

ECG

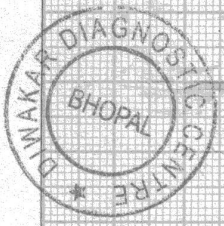


BPL-DYNATRAC



Allengers ECG (Piscos)(PIS213180317)

AKASH SONI



Diwaker Diagnostic Centre

E-7/636, Near Punjab National Bank Bhopal(M.P.)

13 / MR. AKASH SONI / 31 Yrs / M / 172 Cms / 76 Kg Date: 11-Dec-2021 Technician : BOB

Report

(GEM213180307)(R)Allengers



Report :

TEST OBJECTIVE : ROUTINE CHECK UP
RISK FACTOR : MALE
ACTIVITY : MODERATE ACTIVE
OTHER INVESTIGATION : ROUTINE BLOOD INVESTIGATION
REASON FOR TERMINATION : TEST COMPLETE, FATIGUE, HEART RATE ACHIEVED
EXERCISE TOLERANCE : GOOD
EXERCISE INDUCED ARRHYTHMIAS : NO
HAEMODYNAMIC RESPONSE : NORMAL
CHRONOTROPIC RESPONSE : NORMAL
FINAL IMPRESSION : STRESS TEST IS NEGATIVE FOR EXERCISE INDUCED ISCHAEMIC HEART DISEASE

Doctor : CARDIOLOGIST

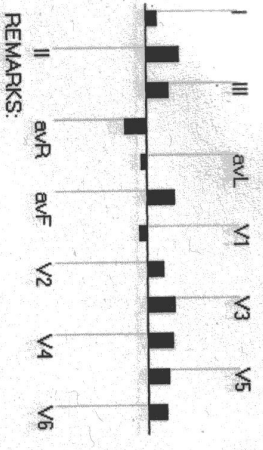
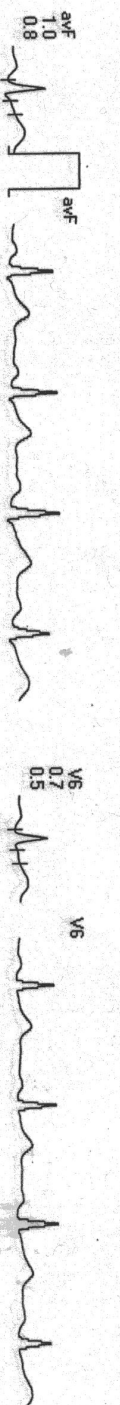
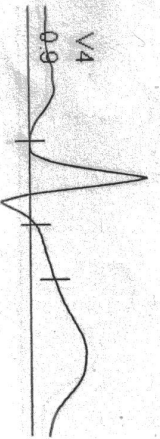


Stage	Time	Duration	Belt Speed (mph)	Elevation	METS	Rate	%THR Achieved	BP	RPP	PVC	Comments
Supine	00:13	0:01	00.0	00.0	01.0	82	43 %	120/80	098	00	
Standing	00:29	0:01	00.0	00.0	01.0	83	44 %	120/80	099	00	
Supine	00:42	0:01	00.0	00.0	01.0	084	44 %	120/80	100	00	
HV	00:55	0:01	00.0	00.0	01.0	089	47 %	120/80	106	00	
Warm Up	01:17	0:05	01.7	10.0	01.1	115	61 %	120/80	138	00	
ExStart	01:19	0:07	01.7	10.0	01.1	115	61 %	120/80	138	00	
BRUCE Stage 1	04:19	3:00	01.7	10.0	04.7	126	67 %	130/80	163	00	
BRUCE Stage 2	07:19	3:00	02.5	12.0	07.1	145	77 %	140/90	203	00	
BRUCE Stage 3	10:19	3:00	03.4	14.0	10.2	170	90 %	146/96	248	00	
PeakEx	10:21	3:00	03.4	14.0	10.3	170	90 %	146/96	248	00	
Recovery	11:20	1:00	00.0	00.0	04.2	146	77 %	130/90	189	00	
Recovery	12:20	2:00	00.0	00.0	01.0	122	65 %	120/80	146	00	
Recovery	12:27				00.0	000	0 %	---/---	000	00	

Findings :

Exercise Time : 09:03
 Max HR Attained : 170 bpm 90% of Target 189
 Max BP Attained : (Sys) 146/96
 Max Workload Attained : 10.3 Good response to induced stress
 Max ST Dep Lead & Value : Max ST Dep Lead & Value
 Test End Reasons : Test Complete, Fatigue, Heart Rate Achieved

Doctor : CARDIOLOGIST



REMARKS:




131/MR. AKASH SONI / 31 Yrs / M / 172 Cms / 76 Kg / HR : 83


Date: 11-Dec-2021 01:50:40 PM METS: 1.0/ 83 bpm 43% of THR BP: 120/80 mmHg Raw ECG/ BLC On/ Natch On/ HF 0.05 Hz/LF 20 Hz

4X 80 ms Pos J

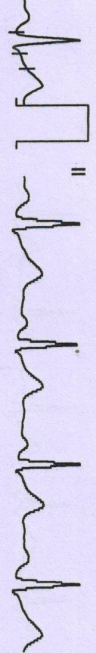
EXTime: 00:28 0.0 mph, 0.0%
25 mm/Sec. 1.0 Cm/mV




I
STL 0.4
STS 0.5



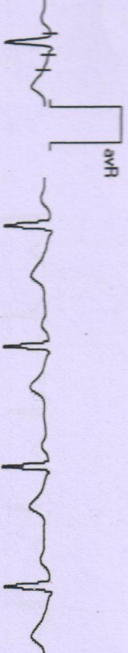II
1.5
1.3




III
1.0
0.8




avR
-1.0
-0.9



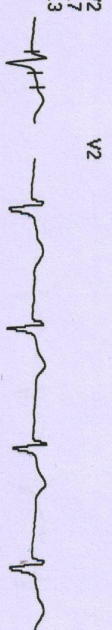avL
-0.2
-0.1



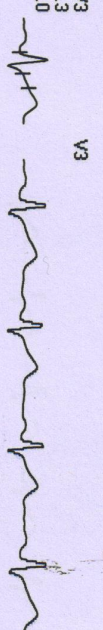V1
-0.2
-0.2



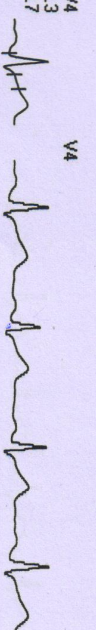V2
0.7
0.3



V3
1.3
1.0



V4
1.3
0.7



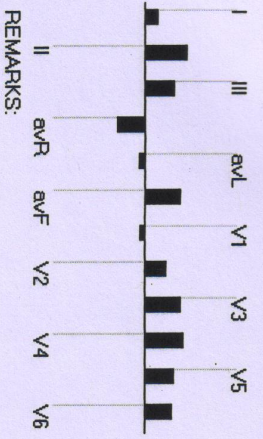
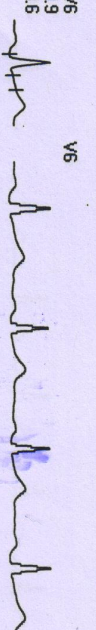
V5
1.0
0.7



avF
1.2
1.0



V6
0.9
0.6



REMARKS:

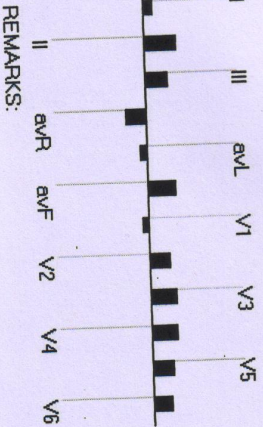
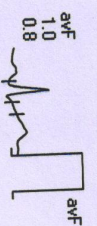





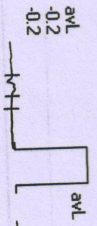
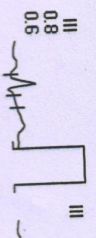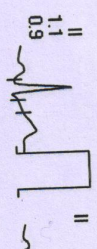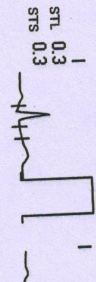

Diagnosis Diagnostic Centre

131/MR. AKASH SONI / 31 Yrs / M / 172 Cms / 76 Kg / HR : 89

Date: 11-Dec-2021 01:50:40 PM METS: 1.0/ 89 bpm 47% of THR BP: 120/80 mmHg Raw ECG/ BLC On/ Notch On/ HF 0.05 Hz/ LF 20 Hz

4X 80 ms Post J

EXTime: 00:54 0.0 mph 0.0%
25 mm/Sec. 1.0 Cm/mV



REMARKS:

(GEM213180307)(A)Allengers

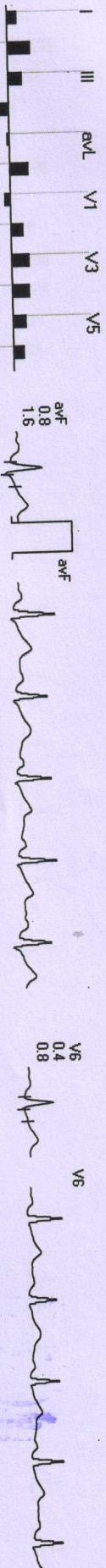







13 / MR. AKASH SONI / 31 Yrs / M / 172 Cms / 76 Kg / HR : 102

Date: 11-Dec-2021 01:50:40 PM METS: 1.0/ 102 bpm 53% of THR BP: 120/80 mmHg Raw ECG/ BLC On/ Notch On/ HF 0.05 Hz/LF 20 Hz

EXTime: 01:16 1.0 mph, 0.0%
25 mm/Sec. 1.0 Cm/mV

4X 80 ms Post J



REMARKS:

13 / MR. AKASH SONI / 31 Yrs / M / 172 Cms / 76 Kg / HR : 115

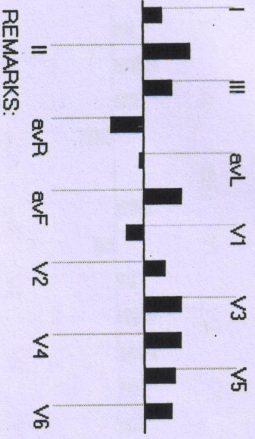
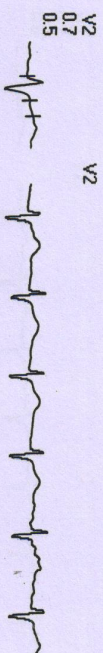
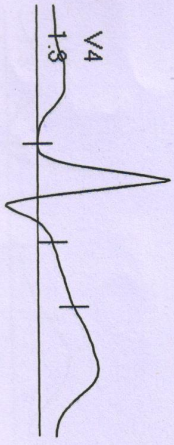





Date: 11-Dec-2021 01:50:40 PM METS: 1.0/ 115 bpm 60% of TFR BP: 120/80 mmHg Raw ECG/ BLC On/ Notch On/ HF 0.05 Hz/ LF 20 Hz

4X 80 ms Post J

ExStit



EXTime: 00:00 0.0 mph 0.0%
25 mm/Sec. 1.0 Cm/mV



REMARKS:




13 / MR. AKASH SONI / 31 Yrs / M / 172 Cms / 76 Kg / HR : 124

EXTime: 03:00 1.7 mph, 10.0%
25 mm/Sec. 1.0 Cm/mV

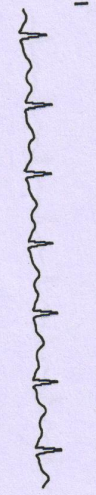
Date: 11-Dec-2021 01:50:40 PM

4X 80 mS Post J

Raw ECG/ BLC On/ Notch On/ HF 0.05 Hz/LF 20 Hz




I
STL 0.8
STS 0.7




V1
-0.8
-0.9



II
1.6
1.6



V2
0.7
0.6



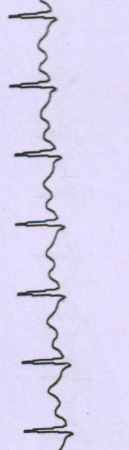
III
0.9
0.9



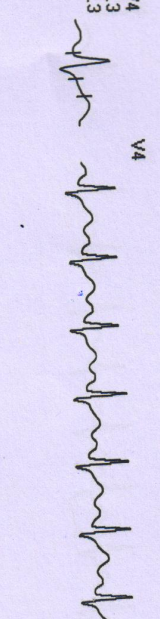
V3
1.3
1.4



avR
-1.2
-1.2



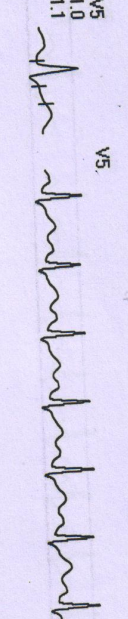
V4
1.3
1.3



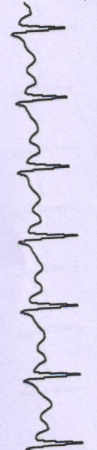
avL
-0.1
-0.1



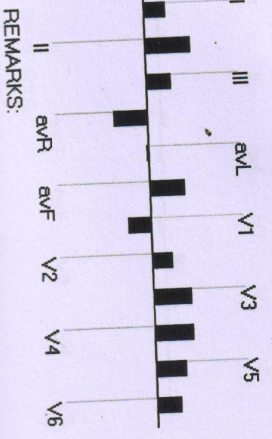
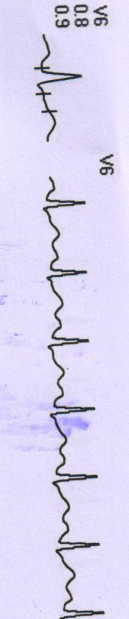
V5
1.0
1.1



avF
1.2
1.3



V6
0.8
0.9



REMARKS:

13 / MR. AKASH SONI / 31 Yrs / M / 172 Cms / 76 Kg / HR : 147

Date: 11-Dec-2021 01:50:40 PM METS: 7.1/147 bpm 77% of THR BP: 140/90 mmHg Raw ECG/ BLC On/ Notch On/ HF 0.05 Hz/ LF 20 Hz

BRUCE : Stage 2 (03:00)



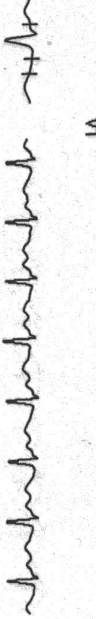EXTime: 06:00 2.5 mph, 12.0%
25 mm/Sec. 1.0 Cm/mV

4X 60 ms Post J

I
STL -0.2
STS 0.5



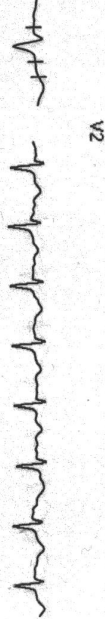V1
-0.2
-0.7



II
-0.2
1.3




V2
0.6
0.7



III
0.0
0.8



V3
0.3
1.4



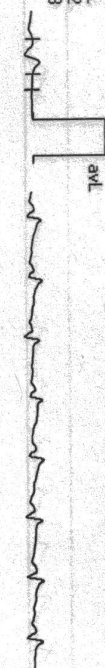aVR
0.2
0.9




V4
0.2
1.3



aVL
-0.2
-0.3




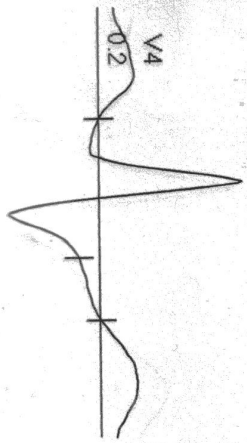

V5
-0.1
0.9



aVF
-0.1
1.0



V6
-0.1
0.8



REMARKS:

131/MR/ AKASH SONI / 31 Yrs / M / 172 Cms / 76 Kg / HR : 170

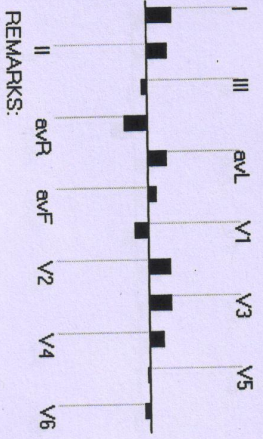

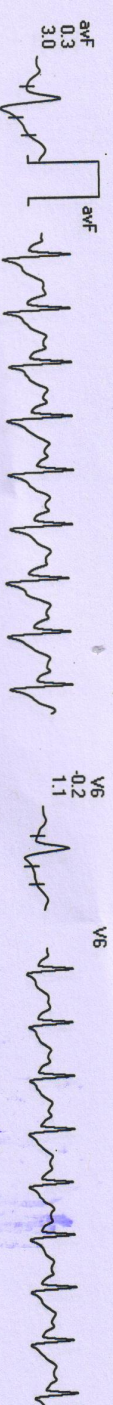





BRUCE : Stage 3 (03:00)



Date: 11-Dec-2021 01:50:40 PM METS: 10.2/170 bpm 89% of THR BP: 146/96 mmHg Raw ECG/ BLC On/ Notch On/ HF 0.05 Hz/LF 20 Hz

EXTime: 09:00 3.4 mph, 14.0%
25 mm/Sec. 1.0 Cm/mV

4X 60 ms Post J



REMARKS:

13/MR: AKASH SONI / 31 Yrs / M / 172 Cms / 76 Kg / HR : 170


Date: 11-Dec-2021 01:50:40 PM

METS: 10.3/170 bpm 89% of THR BP: 146/96 mmHg Raw ECG/ BLC On/ Notch On/ HF 0.05 Hz/LF 20 Hz


4X 60 ms Post J



EXTime: 09:02 4.2 mph, 16.0%
25 mm/Sec. 1.0 Cm/mV




I
STL 0.9
STS 0.6



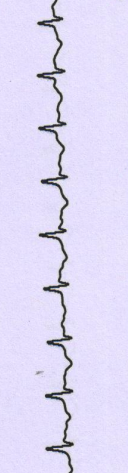
V1
-0.5
-1.3




II
0.7
3.2



V2
0.8
0.3



III
-0.2
2.7




V3
0.8
2.5




aVR
-0.8
-1.9



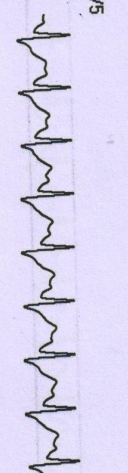
V4
0.5
2.5




aVL
0.6
-1.1



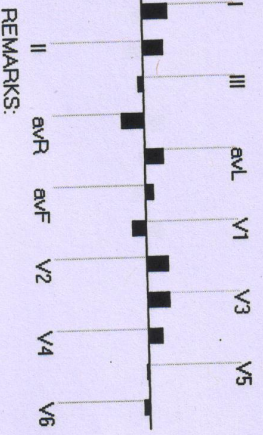

V5
-0.1
1.7



aVF
0.3
3.0



V6
-0.2
1.1



REMARKS:

Aaker Diagnostic Centre

131/MR. AKASH SONI / 31 YRS / M / 172 Cms / 76 Kg / HR. 146

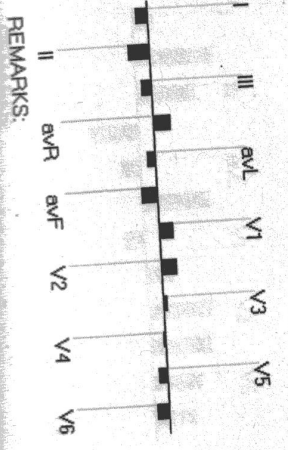

Date: 11-Dec-2021 01:50:40 PM METS: 42/146 bpm 77% of THR BP: 130/90 mmHg Raw ECG/ BLC On/ Notch On/ HF 0.05 Hz/LF 20 Hz

4X 50 ms Post J

Recovery : (01:00)



EXTime: 09:02 0.0 mph, 0.0%
25 mm/Sec. 1.0 Cm/mV



REMARKS:

(GEM213180307)AAllengers

Awaker Diagnostic Centre

13 / MR. AKASH SONI / 31 Yrs / M / 172 Cms / 76 Kg / HR : 122

Date: 11-Dec-2021 01:50:40 PM

METS: 1.0 / 122 bpm 64% of THR


BP: 120/80 mmHg Raw ECG/ BLC On/ Notch On/ HF 0.05 Hz/LF 20 Hz

4X 80 ms Post J

Recovery : (02:00)



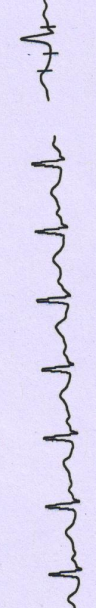EXTime: 09:02 0.0 mph, 0.0%
25 mm/Sec. 1.0 Cm/mV



STL 0.7
STS 1.0



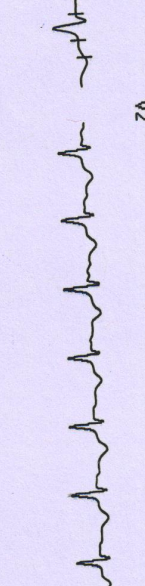
V1 -0.7
V1 -1.2




II 2.7
II 3.4




V2 0.9
V2 1.0




III 2.0
III 2.4




V3 2.2
V3 2.6




aVR -1.7
aVR -2.2





V4 2.1
V4 2.6




aVL -0.7
aVL -0.7



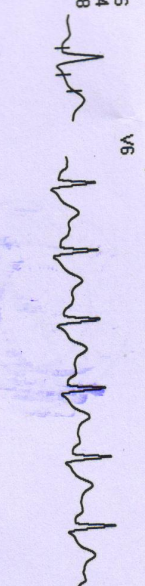
V5 1.7
V5 2.1



aVF 2.4
aVF 2.9



V6 1.4
V6 1.8



REMARKS:

(GEM213180307/A)Allengers

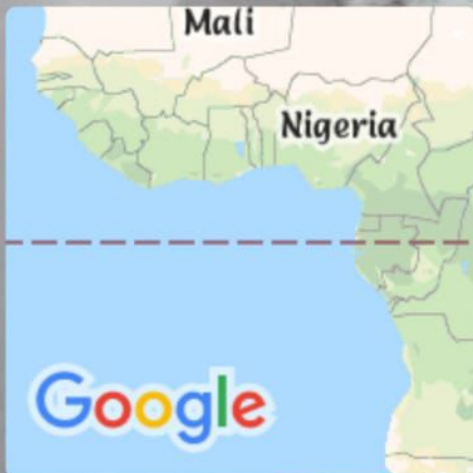


D Diagnostic Centre

पेथ | एक्स-रे | ई.सी.जी. | एको कार्डियो ग्राफी | सोनोग्राफी



GPS Map Camera



Bhopal, Madhya Pradesh, India

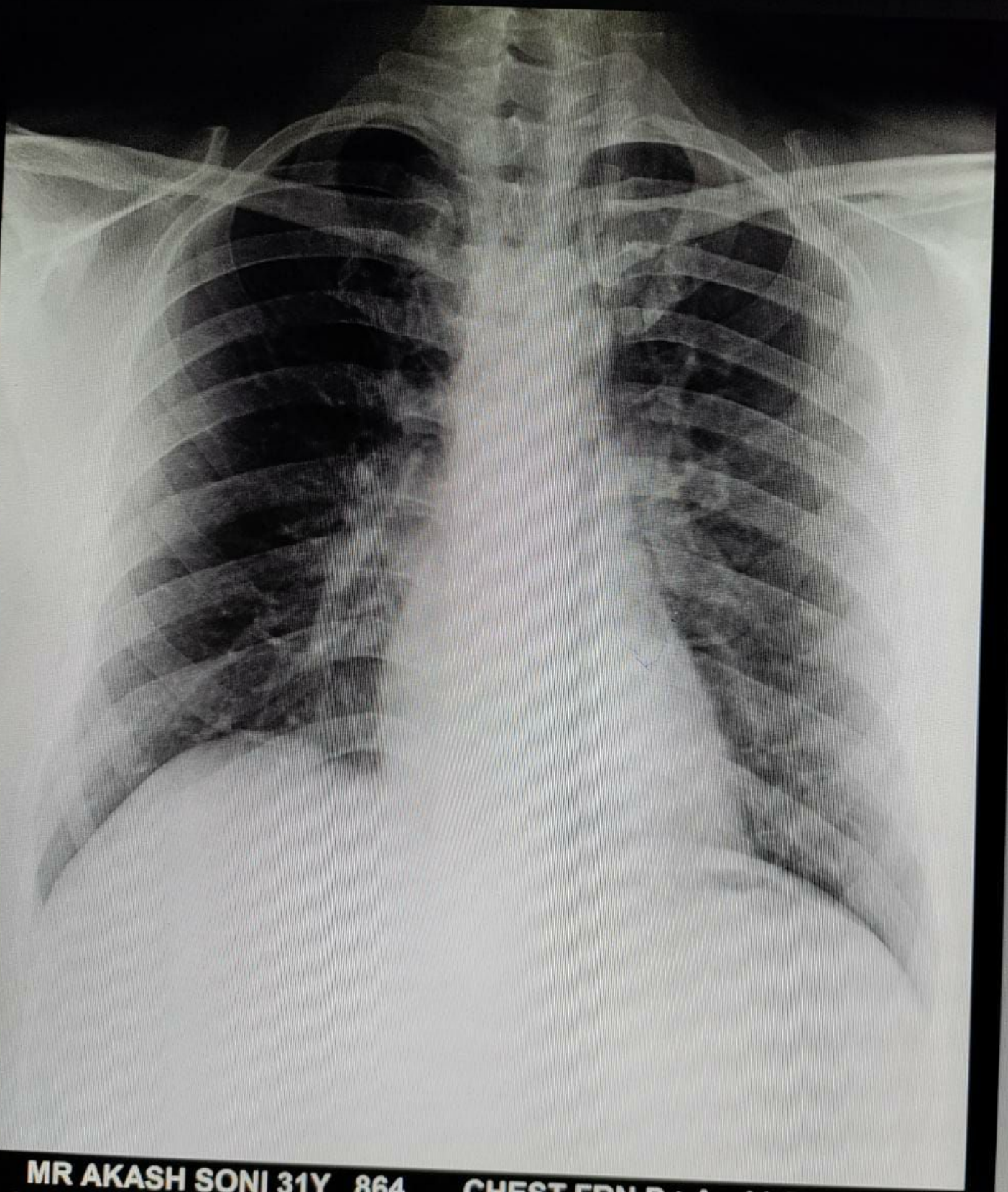
636, Champion School Rd, E-7, Arera Colony, Bhopal, Madhya

Pradesh 462016, India

Lat 23.205951°

Long 77.431682°

11/12/21 10:38 AM



**MR AKASH SONI 31Y 864 CHEST,FRN P->A 11-Dec-21
DIWAKAR DIAGNOSTIC CENTRE , ARERA COLONY ,BHOPAL**