



भारतीय विशिष्ट ओळख प्राधिकरण  
भारत सरकार  
Unique Identification Authority of India  
Government of India

नोंदविण्याचा क्रमांक / Enrollment No 1104/20353/08472

To,  
अश्विनी धोंडीराम कदम  
Ashwini Dhondiram Kadam  
D/O Dhondiram Kadam  
CHEMBUR GOVANDI ROAD, BEHIND ACHARYA  
COLLEGE AHILYABAI HOLKAR SOCIETY, ROOM NO. 3,  
KHARDEV NAGAR  
Chembur  
Chembur Mumbai  
Maharashtra 400071  
9920767253

Ref: 24 / 15E / 46535 / 47880 / P



UE466629662IN



आपला आधार क्रमांक / Your Aadhaar No. :

**8004 6245 0864**

आधार – सामान्य माणसाचा अधिकार



भारत सरकार  
GOVERNMENT OF INDIA



अश्विनी धोंडीराम कदम  
Ashwini Dhondiram Kadam  
आई : मंगल धोंडीराम कदम  
Mother : Mangal Dhondiram  
Kadam  
जन्म वर्ष / Year of Birth : 1985  
स्त्री / Female



**8004 6245 0864**

आधार – सामान्य माणसाचा अधिकार



*Ashwini Kadam*





LAB - Shop No. 7, "Diwan Towers" Mangalwar Peth, Near Mirajkar Tikti, Opp. Nutan Marathi High School, Kolhapur. Mob. 9158529408, 9422047480, 9921285167

NAME : MRS. ASHWINI KADAM  
REF BY : Dr. MEDIWHEEL LIFE INS

DATE : 19/07/2024 PT.NO. : 202 19072  
AGE : 38. Yrs. SEX : F

### HAEMOGRAM WITH INDICES

Test	Result	Units	Normal Range	Histogram
<b>Haemoglobin</b>	- 13.9	g/dl	12-16	<p>RBC</p>
RBC Count	- 4.98	millions / cu-mm	4.5 - 6.5	
PCV	- 45.0	%	40 - 54	
MCV	- 90.4	fL	80 - 96	
MCH	- 27.9	Pg	27 - 33	
MCHC	- 30.9	gm/dl	33 - 36	
RDW CV	- 13.0	%	11.0 - 14.5	
<b>WBC Count</b>	- 7800	/cumm	4000 - 11000	<p>WBC</p>
Neutrophils	- 56	%	55 - 75	
Lymphocytes	- 39	%	20 - 50	
Eosinophils	- 03	%	1 - 6	
Monocytes	- 02	%	2-10	
Basophils	- 00	%	0 - 1	
<b>Platelet Count</b>	- 227000	/ul	150000 - 450000	<p>PLT</p>
MPV	- 10.3	fL	7.4 - 10.4	
PDW	- 13.1	%	8-12	
P-LCR	- 28.2	%	15-35	
<b>E.S.R.</b>	- 09	mm at 1hr	0-15	
(By Wintrobe Method)				
RBC Morphology	-	Normochromic, Normocytic.		
WBC Morphology	-	Within Normal Limits		
Platelets	-	Adequate		
* Blood group	-	'A' Rh Positive		

Dr. Vandana G. Powar  
M.B.B.S., D.C.P.  
Reg. No. 68137



**PATHOLOGIST**

DR. VANDANA POWAR  
M.B.B.S., D.C.P.

All Biochemistry Tests Done By Computerised Auto Analyser

HAEMATOLOGY | CLINICAL PATHOLOGY | BIOCHEMISTRY | SEROLOGY | MICROBIOLOGY | HISTOPATHOLOGY

24 Hours Emergency Service

Home Service Available






PT.NAME : MRS. ASHWINI KADAM  
REF. BY : DR. MEDIWHEEL LIFE INS

DATE : 19/07/2024  
AGE : 38 Yrs. SEX : F  
PT.NO. : 202 190724

### BIOCHEMISTRY TEST REPORT

			<u>Normal Range</u>
Fasting Plasma Glucose	: 89.4	mg/dl	60-110 mg/dl
2 Hrs. Plasma Glucose	: 103.5	mg/dl	90-140 mg/dl
S. Creatinine	: 0.91	mg/dl	0.6 - 1.4 mg/dl
Blood Urea	: 21.5	mg/dl	12-42 mg/dl
Blood Urea Nitrogen	: 10.05	mg/dl	5 - 21 mg/dl
S. Uric acid	: 4.49	mg/dl	2.6 -6.0 mg/dl
CHOLESTEROL	: 160.8	mg/dl	0-250 mg/dl
HDL Cholesterol	: 34.1	mg/dl	30 - 70 mg/dl
S. Triglycerides	: 91.4	mg/dl	0 - 190 mg/dl
LDL Cholesterol	: 108.4	mg/dl	60 - 150 mg/dl
TC/HDLC Ratio	: 4.7		0 - 5
LDLC/HDLC Ratio	: 3.2		2.5 - 3.5

2.5 - 3.5  
Dr. Vandana G. Powar  
M.B.B.S., D.C.P.  
Reg. No. 68137



**PATHOLOGIST**

*Vandana*  
DR. VANDANA POWAR  
M.B.B.S., D.C.P.

All Biochemistry Tests Done By Computerised Auto Analyser

HAEMATOLOGY | CLINICAL PATHOLOGY | BIOCHEMISTRY | SEROLOGY | MICROBIOLOGY | HISTOPATHOLOGY

**24 Hours Emergency Service**

**Home Service Available**



Dr. Vandana G. Powar M.B.B.S., D.C.P.  
Consultant Pathologist



**PARTH**  
PATHOLOGY LABORATORY  
(Computerised)

LAB - Shop No. 7, "Diwan Towers" Mangalwar Peth, Near Mirajkar Tikti, Opp. Nutan Marathi High School, Kolhapur. Mob. 9158529408, 9422047480, 9921285167

PT.NAME : MRS. ASHWINI KADAM  
REF. BY : DR. MEDIWHEEL LIFE INS

DATE : 19/07/2024  
AGE : 38 Yrs. SEX : F  
PT.NO. : 202 190724

### BIOCHEMISTRY TEST REPORT

			<u>Normal Range</u>
S. Bilirubin (Total)	: 0.23	mg/dl	0 - 1.0 mg/dl
S. Bilirubin (Direct)	: 0.15	mg/dl	0 - 0.25 mg/dl
S. Bilirubin (Indirect)	: 0.08	mg/dl	0 - 0.75 mg/dl
S.G.O.T	: 19.3	IU/L	0 - 42 IU/L
S.G.P.T	: 14.5	IU/L	0 - 42 IU/L
S. Alkaline Phosphatase	: 73.6	IU/L	64-306 IU/L
Total Proteins	: 7.9	g/dl	6.6 - 8.3 g/dl
S. Albumin	: 4.7	g/dl	3.5 - 5.0 g/dl
S. Globulin	: 3.2	g/dl	1.5 - 3 g/dl
A/G Ratio	: 1.5 : 1		0.90 - 2.00

Dr. Vandana G. Powar  
M.B.B.S., D.C.P.  
Reg. No. 68137



**PATHOLOGIST**

*[Signature]*  
DR. VANDANA POWAR  
M.B.B.S., D.C.P.

All Biochemistry Tests Done By Computerised Auto Analyser

HAEMATOLOGY | CLINICAL PATHOLOGY | BIOCHEMISTRY | SEROLOGY | MICROBIOLOGY | HISTOPATHOLOGY

24 Hours Emergency Service

Home Service Available



Scanned with OKEN Scanner

Dr. Vandana G. Powar M.B.B.S., D.C.P.  
Consultant Pathologist



**PARTH**  
PATHOLOGY LABORATORY  
(Computerised)

LAB - Shop No. 7, "Diwan Towers" Mangalwar Peth, Near Mirajkar Tikti, Opp. Nutan Marathi High School, Kolhapur. Mob. 9158529408, 9422047480, 9921285167

PT.NAME : MRS. ASHWINI KADAM  
REF. BY : DR. MEDIWHEEL LIFE INS

DATE : 19/07/2024  
AGE : 38 Yrs. SEX : F  
PT.NO. : 202 190724

**REPORT ON % GLYCOHAEMOGLOBIN OF BLOOD**

% Glycohaemoglobin of blood : 5.0 %  
Estimated mean blood glucose : 97.6 mg/dl

(Reference For Guideline)

< 6.0 - Normal  
6.0 - 7.0 % - Good Control  
7.0 - 8.0 % - Fair Control  
8.0-10.0% - Unsatisfactory control  
>10.0% - Poor control

Dr. Vandana G. Powar  
M.B.B.S., D.C.P.  
Reg. No. 68137

**PATHOLOGIST**



*[Signature]*  
DR. VANDANA POWAR  
M.B.B.S., D.C.P.

All Biochemistry Tests Done By Computerised Auto Analyser

HAEMATOLOGY | CLINICAL PATHOLOGY | BIOCHEMISTRY | SEROLOGY | MICROBIOLOGY | HISTOPATHOLOGY

**24 Hours Emergency Service**

**Home Service Available**



Scanned with OKEN Scanner

Dr. Vandana G. Powar M.B.B.S., D.C.P.  
Consultant Pathologist



**PARTH**  
PATHOLOGY LABORATORY  
(Computerised)

LAB - Shop No. 7, "Diwan Towers" Mangalwar Peth, Near Mirajkar Tikti, Opp. Nutan Marathi High School, Kolhapur. Mob. 9158529408, 9422047480, 9921285167

PT.NAME : MRS. ASHWINI KADAM  
REF. BY : DR. MEDIWHEEL LIFE INS

DATE : 19/07/2024  
AGE : 38 Yrs. SEX : F  
PT.NO. : 202 190724

**EXAMINATION OF URINE**

Normal Range

**PHYSICAL EXAMINATION**

Quantity : 05 ml  
Colour : Pale Yellow  
Appearance : Clear  
Deposit : Absent  
Reaction (pH) : Acidic  
Specific Gravity : 1.024

**CHEMICAL EXAMINATION**

Proteins : Absent  
Glucose : Absent  
Ketone Bodies : --  
Bile Salts : -- Absent  
Bile Pigments : -- Absent  
Urobilinogen : --  
Occult Blood : Absent

**MICROSCOPIC EXAMINATION**

Epithelial Cells : 1 - 2 /hpf  
Pus Cells : 2 - 3 /hpf  
Red Blood Cells : Absent /hpf  
Casts : Absent  
Crystals : Absent  
Amorphous Deposits : Absent

**OTHER FINDINGS**

Yeast Cells : Absent  
Trichomonas vaginalis : Absent  
Bacteria : Absent  
Mucus Threads : Absent  
Spermatozoa : Absent

Dr. Vandana G. Powar  
M.B.B.S., D.C.P.  
Reg. No. 68137



**PATHOLOGIST**

DR. VANDANA POWAR  
M.B.B.S., D.C.P.

All Biochemistry Tests Done By Computerised Auto Analyser

HAEMATOLOGY | CLINICAL PATHOLOGY | BIOCHEMISTRY | SEROLOGY | MICROBIOLOGY | HISTOPATHOLOGY

24 Hours Emergency Service

Home Service Available



Scanned with OKEN Scanner

Dr. Vandana G. Powar M.B.B.S., D.C.P.  
Consultant Pathologist



**PARTH**  
PATHOLOGY LABORATORY  
(Computerised)

LAB - Shop No. 7, "Diwan Towers" Mangalwar Peth, Near Mirajkar Tikti, Opp. Nutan Marathi  
High School, Kolhapur. Mob. 9158529408, 9422047480, 9921285167

PATIENT NAME:- ASHWINI KADAM

AGE - 38/SEX - FEMALE

REFERANCE :- MEDWHEEL LIFE INS.

DATE - 19/07/2024

**BIOCHEMISTRY**

S. GAMMA G.T : 16.2 mmol/L

NORMAL RENGE

10 -50 mmol/L

Dr. Vandana G. Powar  
M.B.B.S., D.C.P.  
Reg. No. 68137



**PATHOLOGIST**

DR. VANDANA POWAR  
M.B.B.S., D.C.P.

All Biochemistry Tests Done By Computerised Auto Analyser

HAEMATOLOGY | CLINICAL PATHOLOGY | BIOCHEMISTRY | SEROLOGY | MICROBIOLOGY | HISTOPATHOLOGY

24 Hours Emergency Service

Home Service Available



Scanned with OKEN Scanner

Dr. Vandana G. Powar M.B.B.S., D.C.P.  
Consultant Pathologist



**PARTH**  
PATHOLOGY LABORATORY  
(Computerised)

LAB - Shop No. 7, "Diwan Towers" Mangalwar Peth, Near Mirajkar Tikti, Opp. Nutan Marathi  
High School, Kolhapur. Mob. 9158529408, 9422047480, 9921285167

PATIENT NAME: - ASHWINI KADAM

AGE - 38/SEX-FE MALE

REFERANCE :- MEDWHEEL LIFE INS.

DATE - 19/07/2024

BIOCHEMISTRY

NORMAL VALUE

SRUM VLDL - 11.4mmol/L

10-50 mmol / L

Dr. Vandana G. Powar  
M.B.B.S., D.C.P.  
Reg. No. 68137



**PATHOLOGIST**

*[Signature]*  
DR. VANDANA POWAR  
M.B.B.S., D.C.P.

All Biochemistry Tests Done By Computerised Auto Analyser

HAEMATOLOGY | CLINICAL PATHOLOGY | BIOCHEMISTRY | SEROLOGY | MICROBIOLOGY | HISTOPATHOLOGY

24 Hours Emergency Service

Home Service Available



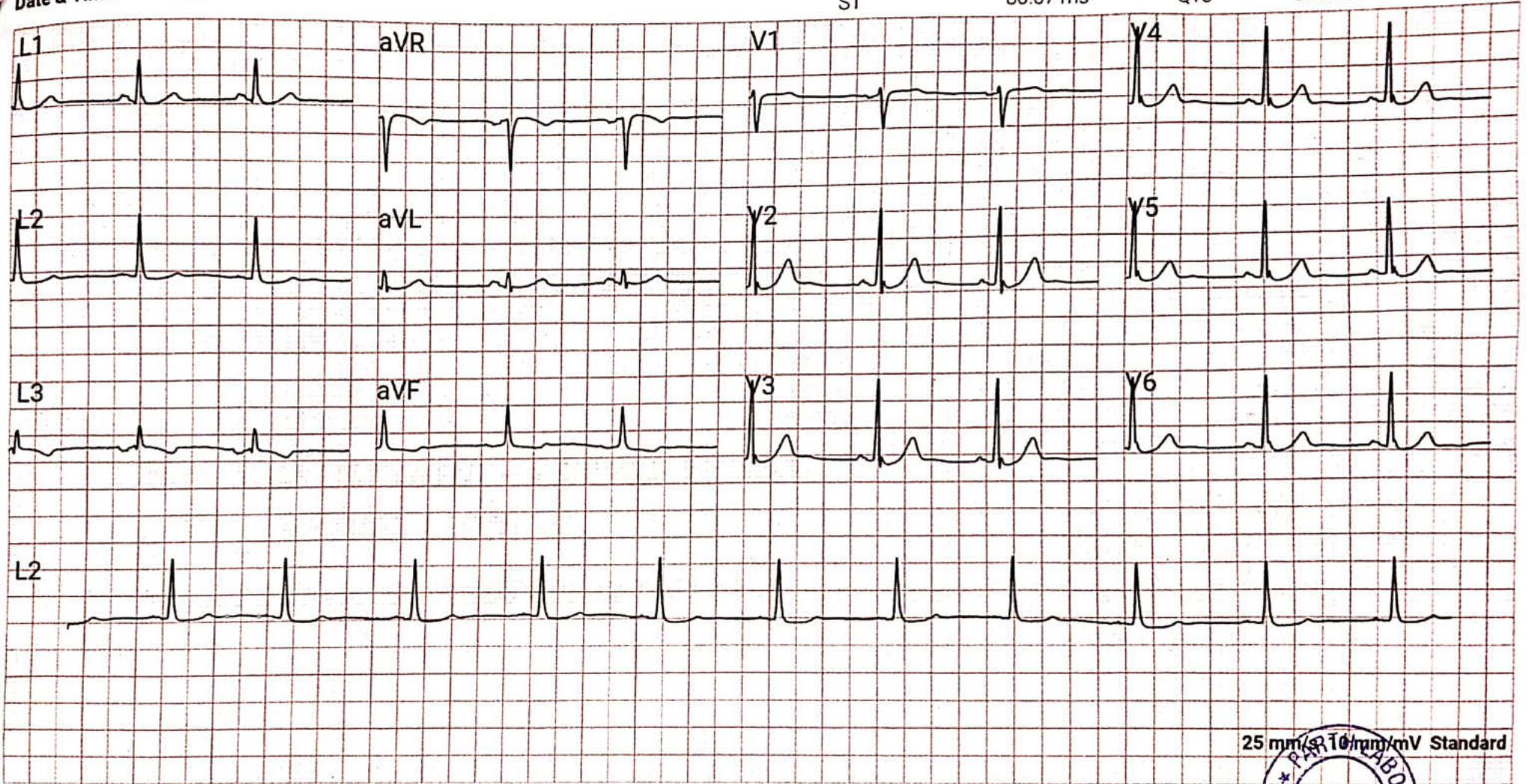
Scanned with OKEN Scanner



12 lead simultaneous ECG Report

est  
Patient Name: Ashwini Kadam  
Gender | Age: 38 | Female  
Date & Time: 19/07/2024 / 09:15

Heart Rate	68 bpm	QT	360.29 ms
QRS	151.71 ms	PR	142.0 ms
ST	80.67 ms	QTc	376.29 ms



25 mm/s 10 mm/mV Standard

Comments: normal

Reported By:



Dr. Vandana G. Powar M.B.B.S., D.C.P.  
Consultant Pathologist



**PARTH**  
PATHOLOGY LABORATORY  
(Computerised)

LAB - Shop No. 7, "Diwan Towers" Mangalwar Peth, Near Mirajkar Tikti, Opp. Nutan Marathi High School, Kolhapur. Mob. 9158529408, 9422047480, 9921285167

19/07/2024

**THE ECG OF THE CLIENT – ASHWINI KADAM  
IS WITHIN NORMAL LIMIT**

**NO ABNORMAL FINDINGS ARE DETECTED .**

Dr. Vandana G. Powar  
M.B.B.S., D.C.P.  
Reg. No. 68137

**PATHOLOGIST**

DR. VANDANA POWAR  
M.B.B.S., D.C.P.



All Biochemistry Tests Done By Computerised Auto Analyser

HAEMATOLOGY | CLINICAL PATHOLOGY | BIOCHEMISTRY | SEROLOGY | MICROBIOLOGY | HISTOPATHOLOGY

**24 Hours Emergency Service**

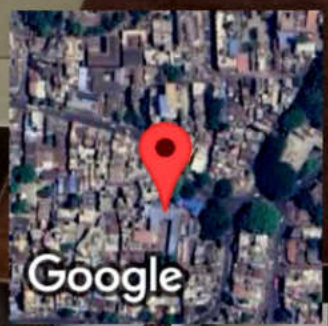
**Home Service Available**



Scanned with OKEN Scanner



GPS Map Camera



**Kolhapur, Maharashtra, India**  
1095/1B/1, Mangalwar Peth, C Ward, Kolhapur, Maharashtra 416012, India  
Lat 16.692799°  
Long 74.224285°  
19/07/24 08:54 AM GMT +05:30

Scanned with OKEN Scanner

Patient Name : MRS. ASHWINI KADAM  
Referred By : Dr. VANDANA POWAR

Date : 19 Jul 2024  
Age : 38 YEARS Sex : F

Clinically – FOR HEALTH CHECK UP.

### Abdomen Sonography

**LIVER** : is normal in size, shape, position and shows normal echogenicity. The contours are smooth. The parenchyma shows homogeneous echo texture. The intra – hepatic portal and venous system appears normal. The portal vein is normal and show hepatopetal flow. The intra-hepatic biliary radicals are not dilated. There is no focal mass lesion.

**GALL BLADDER**: is physiologically distended, normal in size and echotexture. There is no evidence of echoreflexive calculus in gall bladder. There is no abnormal biliary tree dilation noted. The portal vein & C.B.D appear normal. Wall thickness is normal. No e/o cholecystitis/calculus seen. PV measures -11 mm, CBD measures – 3 mm

**PANCREAS**: is normal size, position & echotexture. The contours are smooth. There is no focal mass lesion seen. No pancreatitis or calcification.

**SPLEEN**: is normal in size, shape and echopattern. The contours are smooth. The splenic vein and portal vein are normal in calibre.

**KIDNEYS**: Both the kidneys are normal in size, shape and position and contours. There is no echoreflexive obstructing calculus seen on either sides nor hydronephrosis. Both visualized ureters appear to be normal. Parenchymal thickness and cortical thickness is normal. Cortico-medullary differentiation is well maintained.

**Right kidney** measures- 99 X 43 mm, **Left kidney** measures 101 X 48 mm.

**Urinary bladder** is physiologically distended, appears normal. No intraluminal abnormality.

Aorta and IVC are normal. No e/o free fluid in peritoneal cavity. No ascites. No significant lymphadenopathy. **Bowel loops appear normal in size with good peristalsis.**

**Appendix** is not appreciated in today's study. Terminal ileum is well seen. No probe tenderness in right iliac fossa or anywhere in abdomen.

**IMPRESSION** : < NO SIGNIFICANT ABNORMALITY SEEN.

*Neha*

ADVICE - Clinical correlation and follow up if clinically needed.  
THANKS FOR REFERRAL. FEEDBACK IS WELCOME.

**DR. NEHA S. GHORPADE**  
MBBS DMRE Reg. No. 79916  
Consulting Radiologist

**डॉ. नेहा घोरपडे**  
एम. बी. बी. एस., डी.एम.आर.ई (रेडीओलॉजिस्ट)  
रजि.नं.79916

परत येताना सर्व जुने रिपोर्ट्स, सोनोग्राफी रिपोर्ट्स अथवा एक्स-रे असल्यास बरोबर घेऊन येणे.

Patient Name : MRS. ASHWINI KADAM DANEKAR  
Referred By : Dr. VANDANA POWAR

Date : 19 Jul 2024  
Age : 38 YEARS Sex : F

LMP : 25 June 2024  
CLINICALLY : FOR HEALTH CHECK UP.

### PELVIC SONOGRAPHY

UTERUS - has smooth outlines  
and normal echo-appearance

The endometrial echo is 6 mm thick. IUCD: Cu -T seen in situ.

Uterus ante-verted, Bulky measures are 82 x 42 x 53 mm.

Anterior wall of uterus shows LSCS scar isoechoic lesion having  
minimal vascularity, measuring about 12 x 10 mm -s/o scar endometrioma.

The ovaries are normal.

Right ovary size is 32 x 19 mm.

Left ovary size is 23 x 18 mm.

There is no abnormal adnexal mass.

There is no free fluid in cul de sac.

IMPRESSION : < BULKY UTERUS WITH IUCD(Cu-T) IN SITU.  
< SCAR ENDOMETRIOMA.

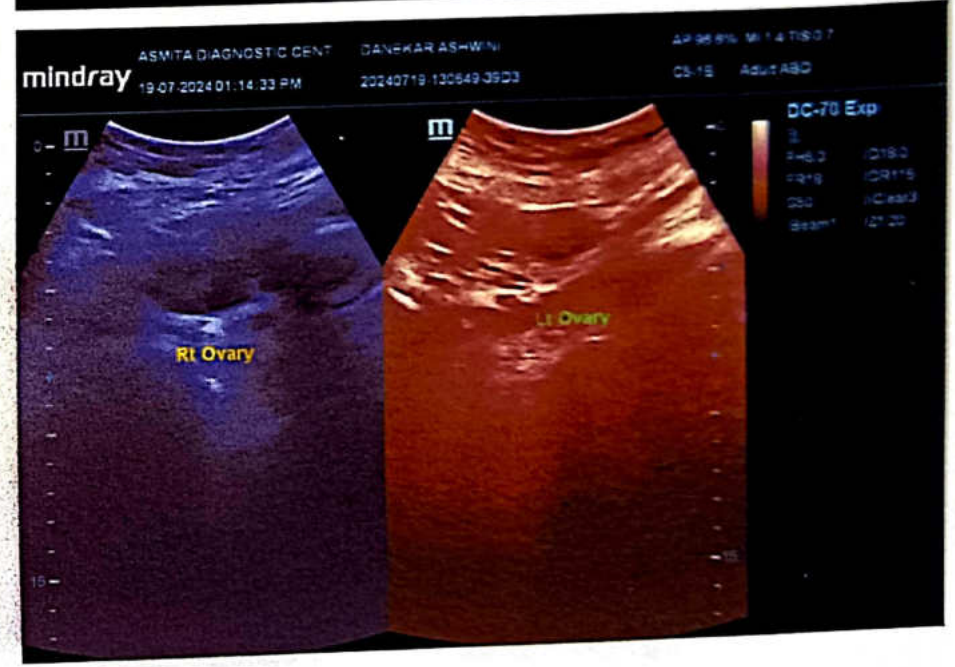
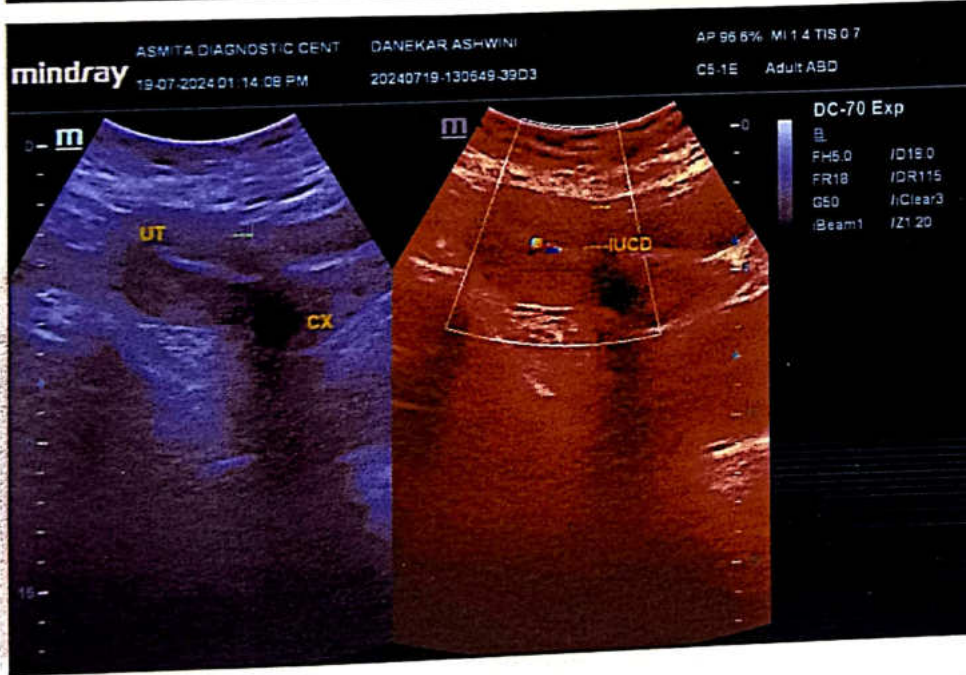
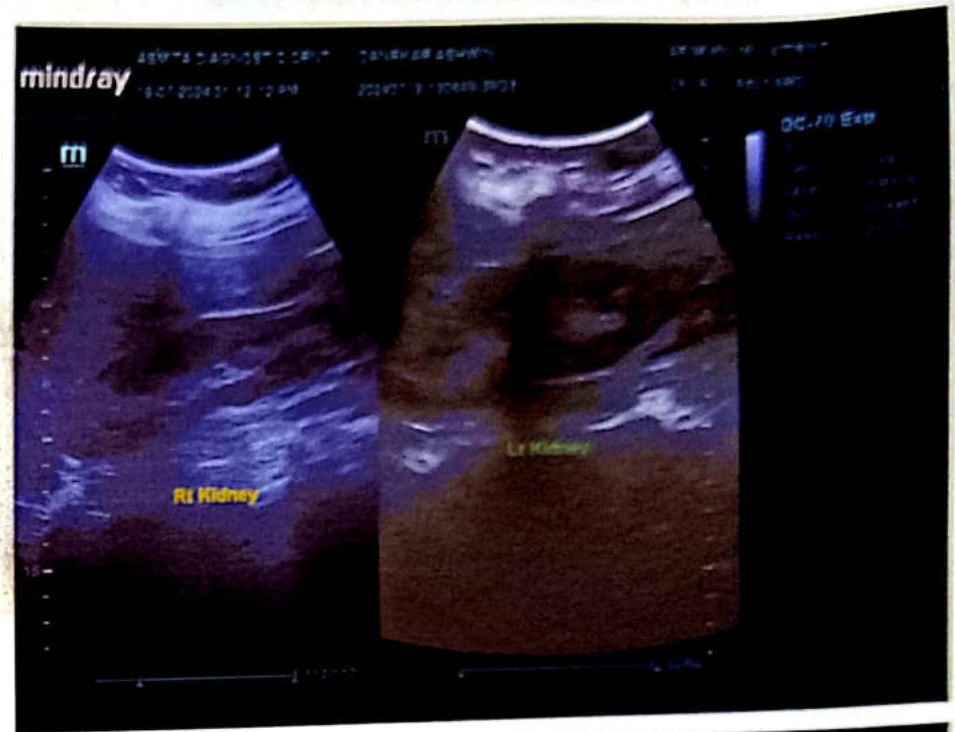
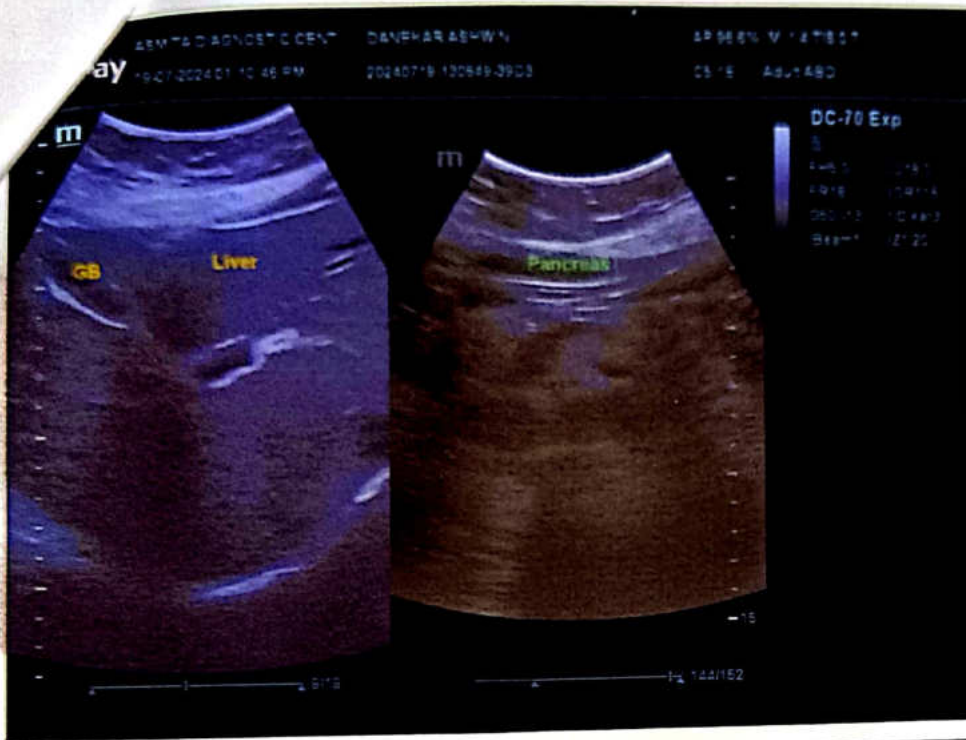
*Neha*

**DR. NEHA S. GHORPADE**  
MBBS DMRE Reg. No. 79916  
Consulting Radiologist

**डॉ. नेहा घोरपडे**

एम. बी. बी. एस., डी.एम.आर.ई (रेडीओलॉजिस्ट)  
रजि.नं.79916

परत येताना सर्व जुने रिपोर्ट्स, सोनोग्राफी रिपोर्ट्स अथवा एक्स-रे असल्यास बरोबर घेऊन येणे.





Corporate Office : HY PATHO LAB

CB 252, GROUND & FIRST FLOOR NARAINA, NEW DELHI 110028

7718962488

info@hypatholab.in

www.hypatholab.in

Toll Free No. : 18001030287

REPORT

PT Name : ASHWINI KADAM  
Ref By : DR. VANDANA POWAR  
Reg No : HL4900826558 / MH145  
Barcode : PT206839  
INV : THYROID PROFILE -3 (T3 T4 TSH)

Age : 38 Year | Sex : Female  
Registered on : 19-07-2024 02:21 PM  
Received on : 20-07-2024 11:36 AM  
Reported on : 20-07-2024 12:30 PM

SAMPLE COLLECTED AT :



SAMPLE : Serum

THYROID PROFILE -3 (T3 T4 TSH)

TEST DESCRIPTION	RESULT	UNITS	BIOLOGICAL REFERENCE RANGE
TOTAL TRIIODOTHYRONINE (T3) <small>Method: CLIA</small>	1.35	ng/mL	0.80 - 2.00
TOTAL THYROXINE (T4) <small>Method: CLIA</small>	9.25	µg/dl	5.10 - 14.10
THYROID STIMULATING HORMONE (TSH) <small>Method: CLIA</small>	0.97	uIU/ml	0.35 - 5.50

Reference Range

Thyroid hormone status during pregnancy:

Pregnancy	T3	T4	TSH
1st Trimester	0.70-1.80	6-16.5	0.37 - 3.6
2nd & 3rd Trimester	0.80-2.00	6-18.5	0.38 - 4.04

Reference ranges by Age

0-5 days: 0.7-15.2

6 days-2 months: 0.7-11.0

3-11 months: 0.7-8.4

1-5 years: 0.7-6.0

6-10 years: 0.6-4.8

Interpretation

1. Patients having low T3 and T4 levels but high TSH levels suffer from primary hypothyroidism, cretinism, juvenile myxedema or autoimmune disorders.
2. Patients having high T3 and T4 levels but low TSH levels suffer from Grave's disease, toxic adenoma or sub-acute thyroiditis.
3. Patients having either low or normal T3 and T4 levels but low TSH values suffer from iodine deficiency or secondary hypothyroidism.
4. Patients having high T3 and T4 levels but normal TSH levels may suffer from toxic multinodular goiter. This condition is mostly a symptomatic and may cause transient hyperthyroidism but no persistent symptoms.
5. Patients with high or normal T3 and T4 levels and low or normal TSH levels suffer either from T3 toxicosis or T4 toxicosis respectively.
6. In patients with non thyroidal illness abnormal test results are not necessarily indicative of thyroidism but may be due to adaptation to the catabolic state and may revert to normal when the patient recovers.
7. There are many drugs for eg. Glucocorticoids, Dopamine, Lithium, Iodides, Oral radiographic dyes, etc. which may affect the thyroid function tests.
8. Generally when total T3 and total T4 results are indecisive then Free T3 and Free T4 tests are recommended for further confirmation along with TSH levels.

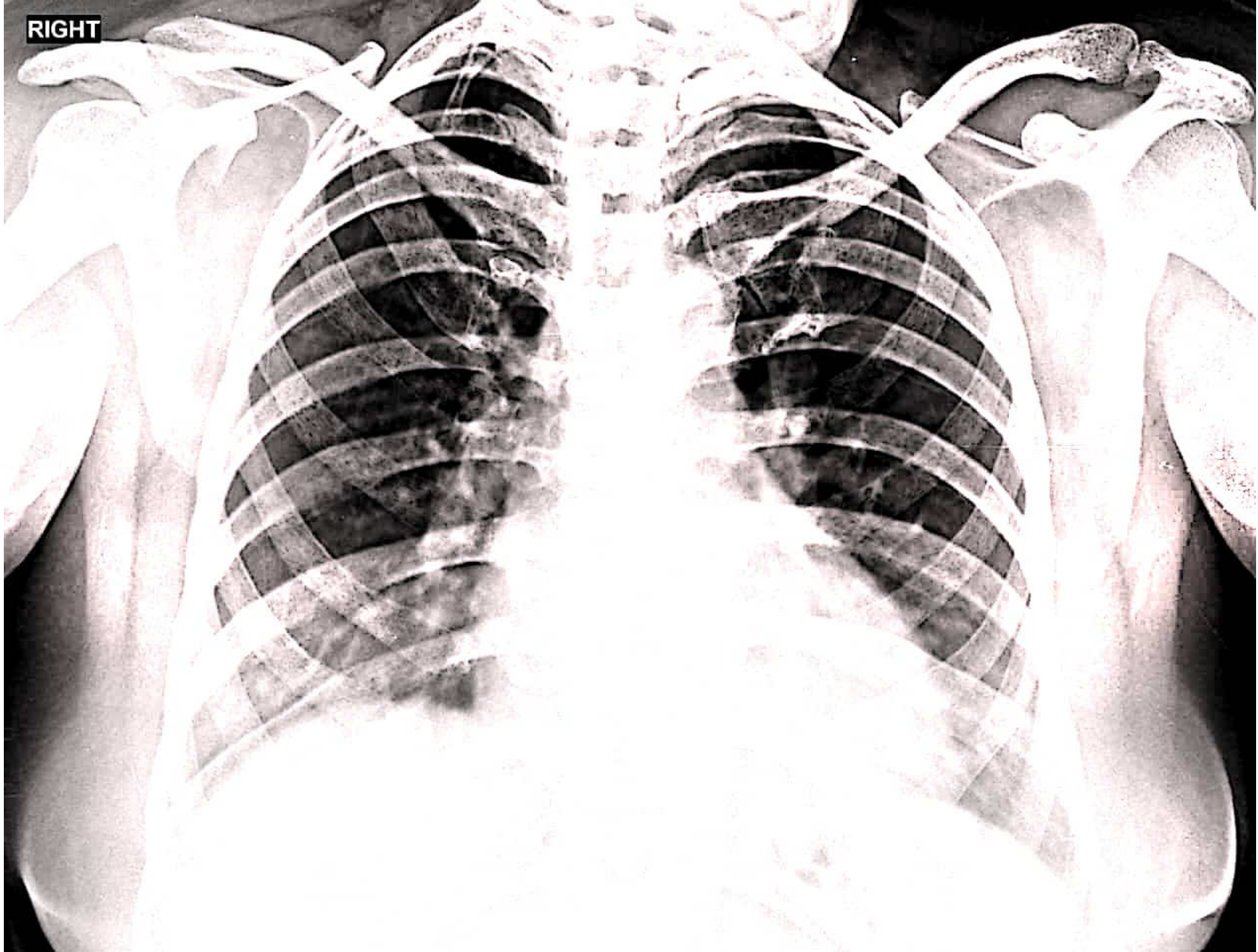
Please correlate with clinical conditions

--End of report--

Dr. PALLAVI SAXENA (MD PATH)  
Consultant Pathologist



RIGHT







# SWARA DIGITAL

## X- RAY

All Types Of Digital, Portable X-rays And Procedural X-rays

PATEINT NAME : MRS. ASHWINI KADAM

AGE/SEX : 38/FEMALE

REF BY : PARTH LAB

DATE : 19/07/2024

### CHEST X-RAY PA

Both lungs fields are normal

Both costophrenic angles appear normal

The tracheal lucency is centrally placed

The mediastinal & diaphragmatic outlines appear normal.

The heart shadow is normal

IMPRESSION : **NORMAL CHEST X-RAY**

ADV: Clinical correlated

**DR SAKSHAM GUPTA**

MBBS,MD Radio diagnosis FMF UK

Consultant Radiologist

**Mob. 9890185675**

Address : Bramhanand, Near Tawanappa Patne High School, Rajarampuri 10 Galli, Kolhapur.

Scanned with ACE Scanner



Scanned with OKEN Scanner