



# Bangalore Diagnostics & Multi-Speciality Centre

Quality Assurance : EQAP from AIIMS & CMC- Vellore

Quality. Trust. Since 1982.

# 198, 12th Main, 3rd Block, (Above Namma MTR, Next to SBI), Rajajinagar, Bangalore- 560 010.  
Ph. : 080-23505407, 9448079978 e-mail : bangalore.d.s@gmail.com

**Name :** MRS. RAM RANI PAL

**Reg. No :** C7224

**Age/Sex:** 57 Year(s) / Female

**Date :** 25/06/2022

**Ref. by :** DR. BANK OF BARODA

**Corporate:** NON CORPORATE

Test Name

Result

Reference Range

Page 1 of 4

## HAEMATOLOGY REPORT

BLOOD GROUP(ABO)

"A"

Rh Type (D)

POSITIVE

### **COMPLETE BLOOD COUNT**

Haemoglobin

12.2 gms %

Male : 13.0 - 18.0 gms %

Female: 11.0 - 15.0 gms %

Red Blood Cell Count

4.51 million/cumm

Male : 4.5-6.5 millions/cumm

Female : 3.7-5.5 million/cumr

Packed Cell Volume

36.2 %

Females: 32 - 45 %

Males: 39 - 54%

Total Count

7,800 cells /cumm

4000-11000 cells /cumm

### **Differential Count**

Neutrophils

55.2 %

40 - 75%

Lymphocytes

35.2 %

20 - 45%

Monocytes

5.6 %

01 - 10%

Eosinophils

4.0 %

01 - 06 %

Basophils

0.0 %

00 to 01 %

### **COMPLETE BLOOD COUNT**

Platelet count

1,65,000 cells/cumm

150000-400000 cells/cumm

Mean Corpuscular Volume

80 fL

78 - 98 fL

Mean Corpuscular Heamoglobin

27.1 pg

27 - 32 pg

Mean Corpuscular Haemoglobin Concentration

33.7 g/dl

31 - 36 g/dl

ESR

08 mm/hour

Male: 0 - 10 mm/ hour

Female: 0 - 20 mm/hour

ABSOLUTE EOSINOPHIL COUNT

308 cells/cumm

40 - 440 cells/cumm

## BIOCHEMISTRY REPORT

FASTING BLOOD SUGAR

94 mg/dl

70 to 100 mg/dl

FASTING URINE SUGAR

NIL

NIL

Dr. MAHADEVA, K.C.  
M.D., (Path)  
KMG. No: 17647



# Bangalore Diagnostics & Multi-Speciality Centre

Quality Assurance : EQAP from AIIMS & CMC- Vellore

Quality, Trust. Since 1982.

# 198, 12th Main, 3rd Block, (Above Namma MTR, Next to SBI), Rajajinagar, Bangalore- 560 010.  
Ph. : 080-23505407, 9448079978 e-mail : bangalore.d.s@gmail.com

**Name :** MRS. RAM RANI PAL

**Reg. No :** C7224

**Age/Sex:** 57 Year(s) / Female

**Date :** 25/06/2022

**Ref. by :** DR. BANK OF BARODA

**Corporate:** NON CORPORATE

Test Name

Result

Reference Range

Page 2 of 4

## BIOCHEMISTRY REPORT

### **Glycosylated Haemoglobin (HbA1c)**

Glycosylated Haemoglobin (HbA1c)	6.4 %	Normal <6.0 % Good control 6.0-7.0 % Fair control 7.0-8.0 % Unsatisfactory 8.0-10.0 % Poor control >10 %
----------------------------------	-------	--

### **LIPID PROFILE**

TOTAL CHOLESTEROL	244.6 mg/dl	up to 200 mg/dl
TRIGLYCERIDES	111.9 mg/dl	<150 : Normal
HDL Cholesterol	42.6 mg/dl	Male: >40 mg/dl Female: > 50 mg/dl
LDL Cholesterol	179.7 mg/dl	<100 mg/dl
VLDL Cholesterol	22.3 mg/dl	<40 mg/dl
CHOLESTEROL/HDL RATIO	5.7:1.0	up to 6.0 %

### **LIVER FUNCTION TESTS**

Total Bilirubin	0.48 mg/dl	up to 1.2 mg/dl
Direct Bilirubin	0.13 mg/dl	0 to 0.3 mg/dl
Indirect Bilirubin	0.35 mg/dl	up to 1.5 mg/dl
S.G.O.T. (AST)	21.8 U/L	0 - 46 U/L
S.G.P.T. (ALT)	25.1 U/L	0 - 49 U/L
ALKALINE PHOSPHATASE	80.6 U/L	Men : 80-306 Women : 64-306 Children upto 15 Yrs : upto 644 Children upto 17 yrs : upto 483
Gamma Glutamyl Transpeptidase (GGT)	16.1 IU/L	0 - 55 IU/L
Total Protein	6.4 gms/dl	6.6 - 8.3 gms/dl
Albumin	3.6 gms/dl	3.4 - 5.0 gms/dl
Globulin	2.8 gms/dl	2.3 - 3.5 gms/dl
A/G Ratio	1.3:1.0	1.2 : 1.0
URIC ACID	2.80 mg/dl	M: 3.5 - 7.2 mg/dl F: 2.6 - 6.0 mg/dl

*Teahllio*

Dr. MAHADEVA. K.C.  
M.D., (Path)  
KMC, No.: 17647



# Bangalore Diagnostics & Multi-Speciality Centre

Quality Assurance : EQAP from AIIMS & CMC- Vellore

Quality, Trust. Since 1982.

# 198, 12th Main, 3rd Block, (Above Namma MTR, Next to SBI), Rajajinagar, Bangalore- 560 010.  
Ph. : 080-23505407, 9448079978 e-mail : bangalore.d.s@gmail.com

**Name :** MRS. RAM RANI PAL

**Reg. No :** C7224

**Age/Sex:** 57 Year(s) / Female

**Date :** 25/06/2022

**Ref. by :** DR. BANK OF BARODA

**Corporate:** NON CORPORATE

Test Name

Result

Reference Range

Page 3 of 4

## **BIOCHEMISTRY REPORT**

BLOOD UREA NITROGEN (BUN)	7.90 mg/dl	7-18 mg/dl
SERUM CREATININE	0.92 mg/dl	Females 0.6 - 1.2 mg/dl Males 0.7 - 1.4 mg/dl
UREA	16.9 mg/dl	10 to 45 mg/dl
SERUM PHOSPHORUS	3.18 mg/dl	2.1 to 5.6 mg/dl

## **URINE EXAMINATION REPORT**

### **PHYSICAL EXAMINATION**

COLOUR	LIGHT YELLOW
APPEARANCE	CLEAR
REACTION	ACIDIC

### **BIOCHEMICAL EXAMINATION**

PROTEIN	NIL	
GLUCOSE	NIL	
BILE SALT	NIL	
BILE PIGMENT	NIL	
SPECIFIC GRAVITY	1.021	1.003 - 1.035

### **MICROSCOPIC EXAMINATION**

PUS CELLS	1-2/HPF
EP CELLS	2-3/HPF
MACROPHAGES	NIL
R.B.C.s	ABSENT
CASTS	NIL

Dr. MAHADEVA. K.C.  
M.D., (Path)  
KMC. No.: 17647



# Bangalore Diagnostics & Multi-Speciality Centre

Quality Assurance : EQAP from AIIMS & CMC- Vellore

Quality, Trust. Since 1982.

# 198, 12th Main, 3rd Block, (Above Namma MTR, Next to SBI), Rajajinagar, Bangalore- 560 010.  
Ph. : 080-23505407, 9448079978 e-mail : bangalore.d.s@gmail.com

**Name :** MRS. RAM RANI PAL

**Reg. No :** C7224

**Age/Sex:** 57 Year(s) / Female

**Date :** 25/06/2022

**Ref. by :** DR. BANK OF BARODA

**Corporate:** NON CORPORATE

Test Name

Result

Reference Range

Page 4 of 4

## URINE EXAMINATION REPORT

### **MICROSCOPIC EXAMINATION**

CRYSTALS

NIL

----- End of Report -----

**Biochemist**

**Microbiologist**

**Pathologist**

Dr. MAHADEVA. K.C.  
M.D., (Path)  
KMC. No.: 17647



# Bangalore Diagnostics & Multi-Speciality Centre

Quality Assurance : EQAP from AIIMS & CMC- Vellore

Quality. Trust. Since 1982.

# 198, 12th Main, 3rd Block, (Above Namma MTR, Next to SBI), Rajajinagar, Bangalore- 560 010.

Ph. : 080-23505407, 9448079978 e-mail : bangalore.d.s@gmail.com

**Name :** MRS. RAM RANI PAL

**Date :** 25/06/2022

**Age/Sex:** 57 Year(s) / Female

**Reg. No :** C7224

**Ref. by :** DR. BANK OF BARODA

**Corporate:** 0

Page 1 of 1

## HAEMATOLOGY REPORT

### **Peripheral Smear (P/S)**

R B C's are normocytic and normochromic with mild anisopoikilocytosis.

W B C's are normal in number, morphology and distribution.

PLATELETS are adequate in number.

Parasites/Abnormal cells are none evident.


IMPRESSION :: NORMOCYTIC NORMOCHROMIC BLOOD PICTURE.

----- End of Report -----

**Biochemist**

**Microbiologist**

**Pathologist**

  
Dr. MAHADEVA. K.C.  
M.D., (Path)  
KMC. No.: 17647



# Bangalore Diagnostics & Multi-Speciality Centre

PROCESSED AT:

Thyrocare,

SCA-711, 3rd Floor,

HRBR 2nd Block,

Hennur, Bengaluru-560043

# 198, 12th Main, 3rd Block, (Above Namma MTR, Next to SBI), Rajajinagar, Bangalore- 560 010.

Ph. : 080-23505407, 9448079978 e-mail : bangalore.d.s@gmail.com

Quality. Trust. Since 1982.

**NAME** : RAM RAMPAL (57Y/F)  
**REF. BY** : B O D LAB  
**TEST ASKED** : T3-T4-TSH

**SAMPLE COLLECTED AT :**  
BANGALORE DIAGNOSTIC CENTER

TEST NAME	TECHNOLOGY	VALUE	UNITS	REFERENCE RANGE
TOTAL TRIIODOTHYRONINE (T3)	C.L.I.A	124	ng/dl	60-200
TOTAL THYROXINE (T4)	C.L.I.A	8.64	µg/dl	4.5-12
THYROID STIMULATING HORMONE (TSH)	C.L.I.A	5.75	µIU/ml	0.3-5.5

**Comments :**

Please correlate with clinical conditions.

**Method :**

T3 - Competitive Chemi Luminescent Immuno Assay

T4 - Competitive Chemi Luminescent Immuno Assay

TSH - SANDWICH CHEMI LUMINESCENT IMMUNO ASSAY

-- End of report --

**Sample Collected on (SCT)** : 25 Jun 2022 12:00  
**Sample Received on (SRT)** : 25 Jun 2022 15:52  
**Report Released on (RRT)** : 25 Jun 2022 17:14  
**Sample Type** : SERUM  
**Labcode** : 2506074855/BAN03  
**Barcode** : Z2549215

Dr Syeda Sumaiya MD(Path) Dr Ajeet Prajapati MD(Path)

Page : 1 of 2



**Abdomen And Pelvic Ultrasound Scan Report**

**Name : Mrs. Ram Rani Pal**

**Date:25/06/2022**

**Ref By : Bank Of Baroda**

**Age/ Gender: 57 Years/Female**

**Liver** : Normal in size, shape and increased echotexture. No focal lesion seen.

No intrahepatic biliary dilatation seen. PV & CBD is normal

**Gall Bladder:** GB is normal. Normal in wall thickness. No abnormal intraluminal echoes.

**Pancreas** : Normal in size and echo texture. No focal lesion, Pancreatic duct appears normal.

**Spleen** : Normal in size, shape and echo texture

**Kidneys** : Both kidney's are normal in size, shape and position.

No calculi / hydronephrosis seen. Corticomedullary differentiation is good.

**Right Kidney : 110 x 17 mm**      **Left kidney : 112 x 16 mm**

**Urinary Bladder:** Normal in contour and wall thickness with clear contents.

Post void = Nil.

**Uterus** : Anteverted, Measures 63 x 25 x 34 mm, normal in size, shape and echotexture. Endometrial thickness = 6 mm. POD is empty.

**Ovaries** : Both ovaries are visualized in adnexa, appears normal.

**IMPRESSION:**

- **NO SONOLOGIC ABNORMALITY IS EVIDENT.**

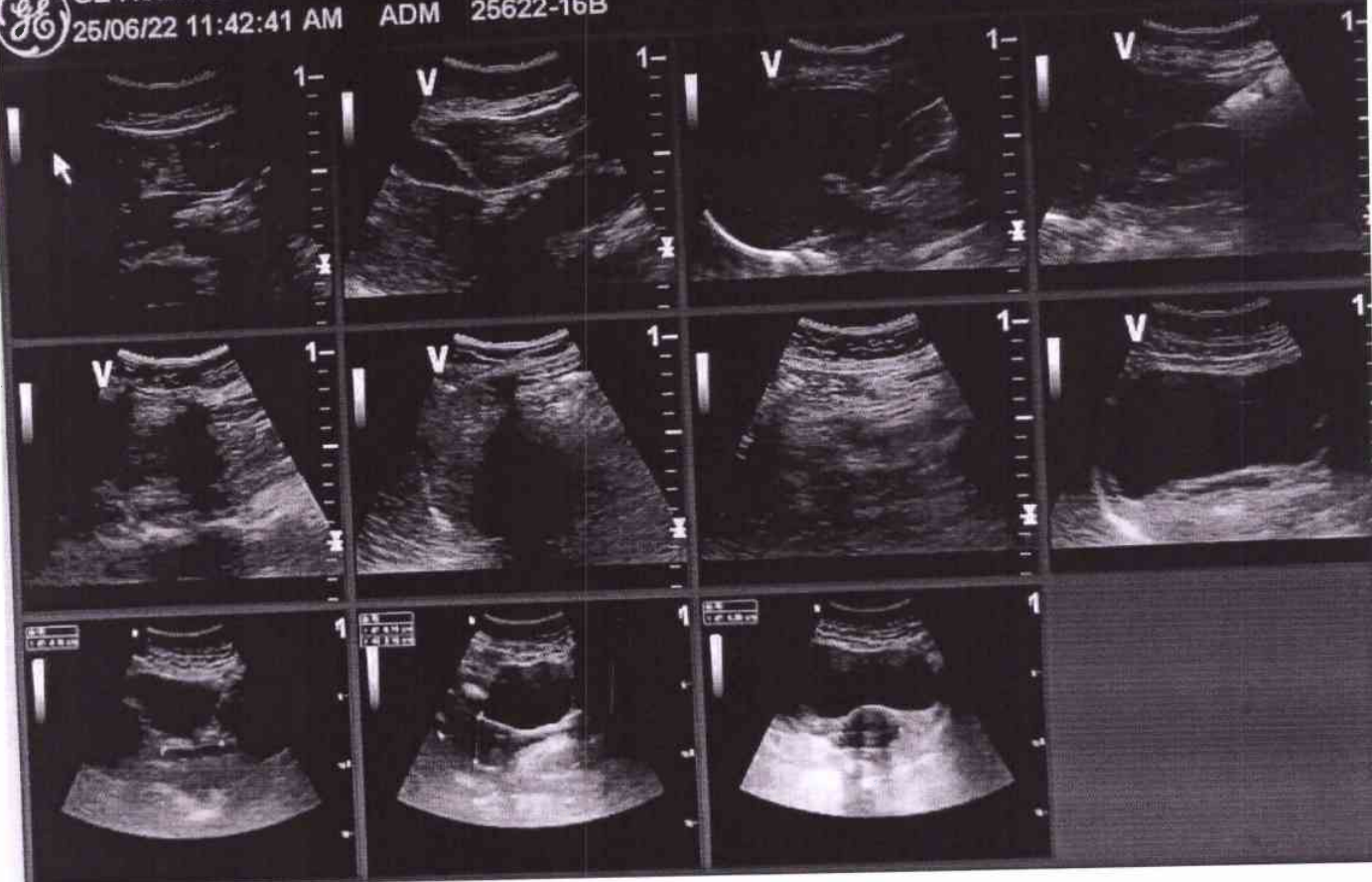  
Dr. Consultant Sonologist

**BANGALORE DIAGNOSTICS &  
MULTI-SPECIALITY CENTRE**  
# 198, 12th Main, 3rd Block  
Rajajinagar, Bangalore-560 010



GE Healthcare  
25/06/22 11:42:41 AM

RAMRANI PAL 57,  
ADM 25622-16B



BANGALORE DIAGNOSTICS &  
MULTI-SPECIALITY CENTRE  
# 198, 12th Main, 3rd Block  
Kajajinagar, Bangalore-560077





# Bangalore Diagnostics & Multi-Speciality Centre

Quality Assurance : EQAP from AIIMS & CMC- Vellore

Quality. Trust. Since 1982.

# 198, 12th Main, 3rd Block, (Above Namma MTR, Next to SBI), Rajajinagar, Bangalore- 560 010.

Ph. : 080-23505407, 9448079978 e-mail : bangalore.d.s@gmail.com

## Echocardiography Report

Name : Mrs. Ram Rani Pal

Date:25/06/2022

Ref By : Bank Of Baroda

Age/ Gender: 57 Years/Female

LA : 34 mm

MV : E 0.86 A : 0.90 m/sec

AO : 25 mm

AV : 1.87 m/sec

RVID : 18 mm

TV : 0.45 m/sec

LVIDD : 35 mm

PV : 0.90 m/sec

LVIDS : 24 mm

IVSD : 10 mm

MR : NIL

IVSS : 15 mm

AR : NIL

LVPWD : 10 mm

TR : NIL

LVPWS : 19 mm

PR : NIL

FS : 32.38 %

EF : 62.41 %

LV mass : 169.31 gm

### IMPRESSION

- Normal Chamber Dimensions.
- No RWMA.
- Normal LV Systolic Function. LVEF 59%
- Normal Valves.
- Normal Color Flow Doppler Study.
- No Thrombus / PE.

  
Dr. Consultant Cardiologist

BANGALORE DIAGNOSTICS &  
MULTI-SPECIALITY CENTRE  
# 198, 12th Main, 3rd Block  
Rajajinagar, Bangalore-560 010



GE Healthcare

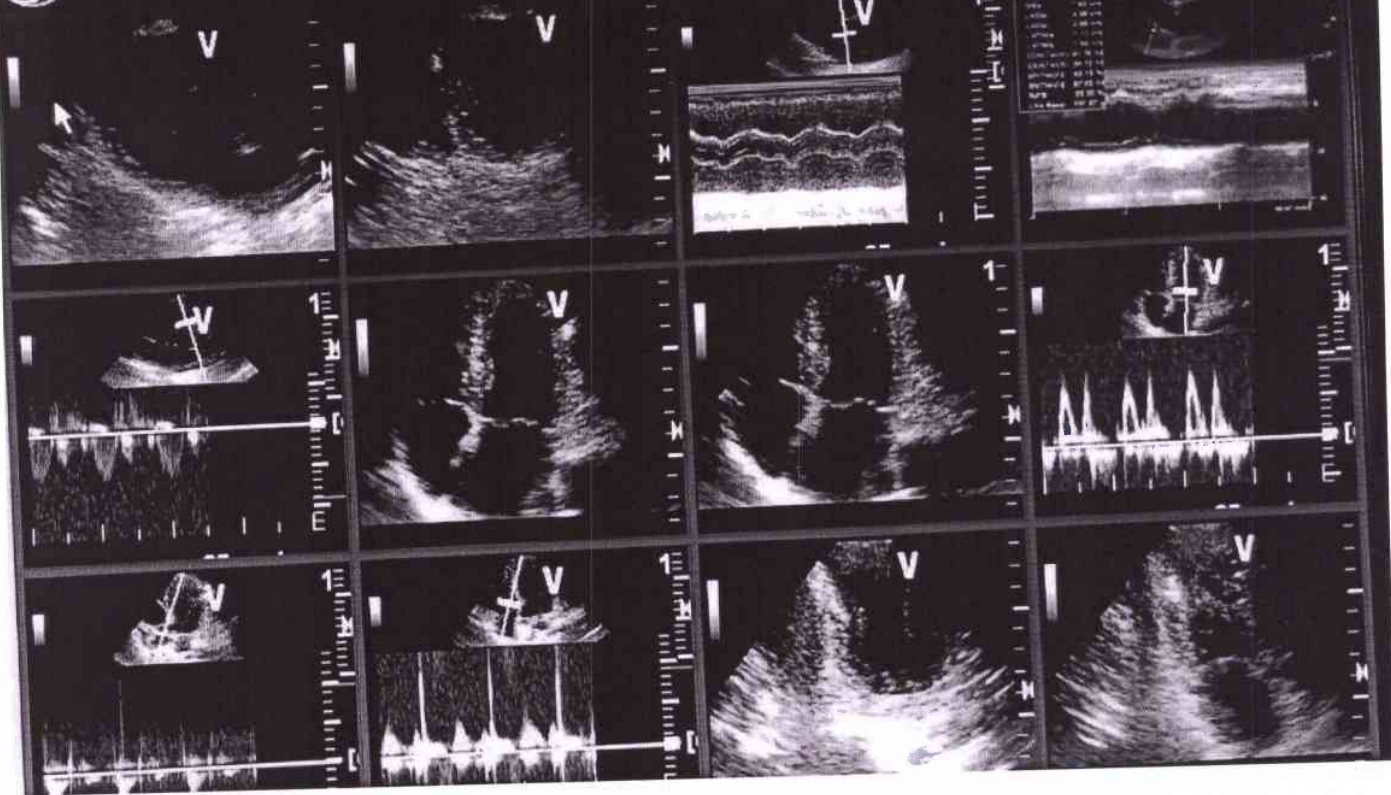
25/06/22 11:45:41 AM

ADM

RAMRANI PAL 57,

25622-16B

---



BANGALORE DIAGNOSTICS &  
MULTI-SPECIALITY CENTRE  
# 129, 12th Main, 3rd Block  
Rajajinagar, Bangalore-560 010



# Bangalore Diagnostics & Multi-Speciality Centre

Quality Assurance : EQAP from AIIMS & CMC- Vellore

Quality. Trust. Since 1982.

# 198, 12th Main, 3rd Block, (Above Namma MTR, Next to SBI), Rajajinagar, Bangalore- 560 010.  
Ph. : 080-23505407, 9448079978 e-mail : bangalore.d.s@gmail.com

## Breast Ultrasound Scan Report

Name : Mrs. Ram Rani pal

Date: 25/06/2022

Ref By :Bank of Baroda

Age/ Gender 57 Years/Female

**Right breast:** Shows normal echotexture of glandular and adipose soft tissue.

No obvious focal lesions noted. Nipple and areola appear normal.

Nipple and areola appear normal.

No ductal dilatation seen.

**Left breast:** Shows normal echotexture of glandular and adipose soft tissue.

A Tiny Clear Cyst is noted in Quadrant II at 2 O'Clock Position measuring 3 x 2 mm with thin wall .

Nipple and areola appear normal.

No ductal dilatation seen.

No evidence of enlarged lymphnodes seen in both axillae .

### IMPRESSION:

- Left Breast Tiny Clear Cyst is evident in Quadrant II.

BIRADE SCORE: II ( Benign Cyst)

Dr. Mohan Kumar

Consultant Radiologist

BANGALORE DIAGNOSTICS &  
MULTI-SPECIALITY CENTRE  
# 198, 12th Main, 3rd Block  
Rajajinagar, Bangalore-560 010



GE Healthcare

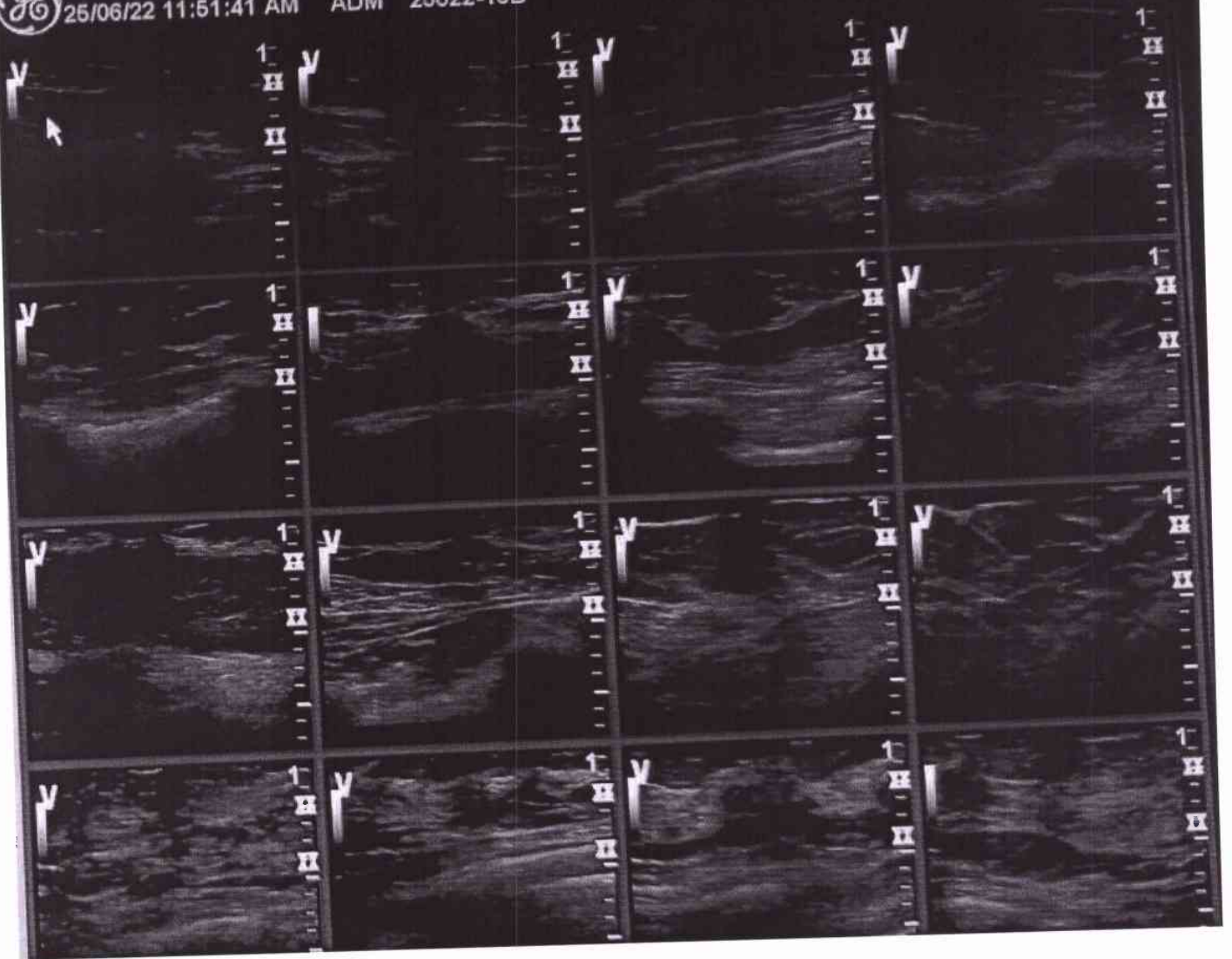
25/06/22 11:51:41 AM

ADM

RAMRANI PAL 57,

25622-16B

---



BANGALORE DIAGNOSTICS &  
MULTI-SPECIALITY CENTRE  
# 198, 12th Main, 3rd Block,  
Najajinagar, Bangalore-560 010



# Bangalore Diagnostics & Multi-Speciality Centre

Quality Assurance : EQAP from AIIMS & CMC- Vellore

Quality. Trust. Since 1982.

# 198, 12th Main, 3rd Block, (Above Namma MTR, Next to SBI), Rajajinagar, Bangalore- 560 010.  
Ph. : 080-23505407, 9448079978 e-mail : bangalore.d.s@gmail.com

Patient Name	MRS.RAMRANI PAL	Patient Id.	X-RAY-128
Age/DOB	57/	Gender	F
Ref.Doctor	BANK OF BARODA	Date	26/06/2022

Thank you for referring the patient for XRay

## X-RAY CHEST PA VIEW

### OBSERVATION:

- The trachea is central.
- The mediastinal and cardiac silhouette are normal.
- Cardiothoracic ratio is normal.
- Cardiophrenic and costophrenic angles are normal.
- Both hila are normal.
- The lung fields are clear.
- Bones of the thoracic cage are normal.
- Soft tissues of the chest wall are normal.

### IMPRESSION:

- No significant abnormality seen.

Dr. Shankar Poudel  
MD Radiodiagnosis  
Consultant Radiologist

BANGALORE DIAGNOSTIC  
MULTI-SPECIALITY CENTRE  
# 198, 12th Main, 3rd Block  
Rajajinagar, Bangalore-560 010

R

EZ128 MRI RAJPRASAD PAL 57 M 25.06.2022 13.05.26  
BANGALORE DIAGNOSTIC SERVICE RAJAJINAGAR BANGALORE-560010



# Bangalore Diagnostics & Multi-Speciality Centre

Quality Assurance : EQAP from AIIMS & CMC- Vellore

Quality. Trust. Since 1982.

# 198, 12th Main, 3rd Block, (Above Namma MTR, Next to SBI), Rajajinagar, Bangalore- 560 010.  
Ph. : 080-23505407, 9448079978 e-mail : bangalore.d.s@gmail.com

## ELECTROCARDIOGRAM

NAME/AGE : mesr. Ram Ranil Pal

Lab No.: 25/06/2022 DATE: 25/06/2022

Bank of Baroda

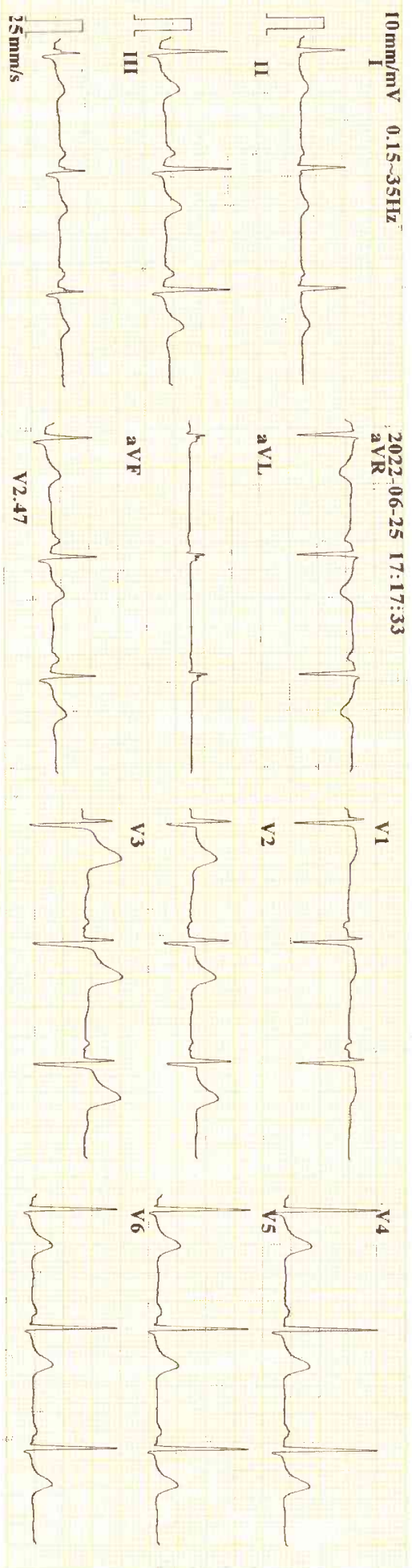
## ECG FINDINGS

Standardization	low	Rate	72b
Rhythm	sin	Axis	N
P Wave	N	PR Interval	0.14 sec
Q Wave	N	QRS Voltage	QRTNR 25h
QRS Duration	0.08 sec	ST Segment	ST depression
QT interval	0.36 sec		
U Wave		T Wave	N
Recommendations	normal		

Dr. Ashok

BANGALORE DIAGNOSTICS &  
MULTI-SPECIALITY CENTRE  
# 198, 12th Main, 3rd Block  
Rajajinagar, Bangalore-560 010

Dr. ASHOK  
MD (Internal Medicine)  
Reg No 13444



2022-06-25 17:17:33  
aVR

CHINA

**BP1**  
 ID : 220625-1717  
 Name : *Cam Rose pad*  
 Age : 57 yr  
 Sex : Female  
 BP :  
 Height :  
 Weight :  
 HR : 70 bpm  
 P Dur : 102 ms  
 PR int : 146 ms  
 QRS Dur : 89 ms  
 QT/QTc int : 378/408 ms  
 P/QRS/T axis : 74/33/62 °  
 RV5/SV1 amp : 1.650/0.885 mV  
 RV5+SV1 amp : 2.535 mV  
 RV6/SV2 amp : 1.531/0.393 mV

Minnesota Code:

Diagnosis Information:  
 800: Sinus Rhythm  
 \*\*\*Normal ECG\*\*\*

Report Confirmed by: