

Transport Department - National Capital Territory of Delhi
 Licence to drive vehicles throughout India

LICENCE NO. : P08112006503492 N

NAME : AMAN JAIN


Son of : SH V K JAIN

ADDRESS : 54 DIPNI APPT
 PITAMPURA
 DELHI 110034

DT. OF BIRTH : 18/07/1986

VEHICLE CLASS : MCYL
 LMV(NT)


04/11/2006
 04/11/2006


 (Holder's Signature)

DT. OF ISSUE : 04/11/2006

VALIDITY : 03/11/2026

BADGE NO. : NA


 Sig. Of Licencing Authority (NW2)

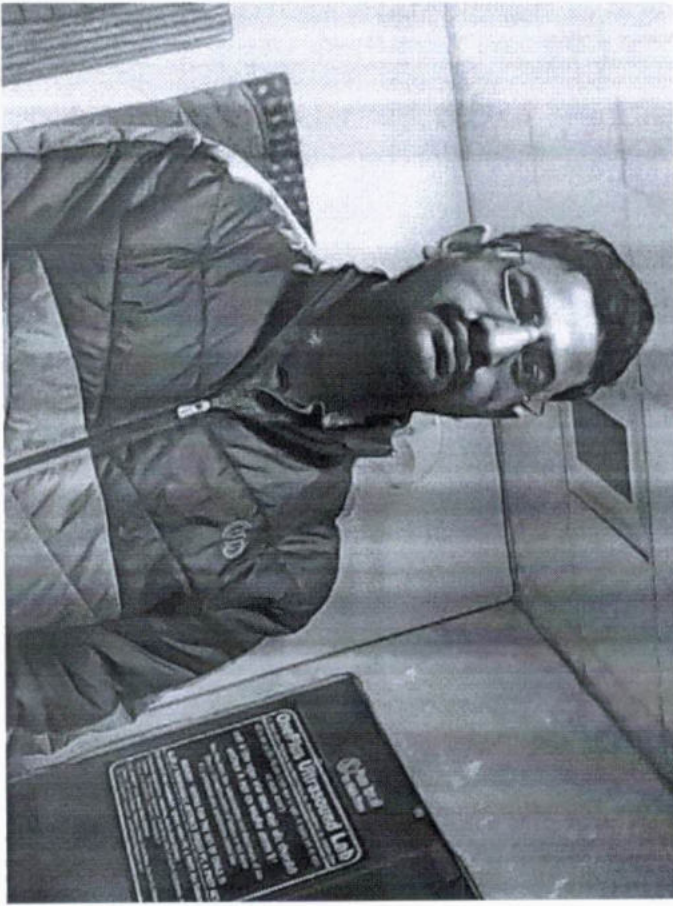
Amaya

[Signature]

Dr. NITIN AGARWAL
 MBBS, MD
 Regn. No. DMC-R-1436

ONEPLUS ULTRASOUND LAB
 47, Harsh Vihar, Pitam Pura,
 Delhi-110034
 Ph. 011-42480101, 9599913051
 E-mail: oneplusul@gmail.com





Dr. NITIN AGARWAL
MBBS, MD
Regn. No. DMC-R-1436

ONEPLUS ULTRASOUND LAB
47, Harsit Vihar, Pitam Pura,
Delhi-110034
Ph. 011-42480101, 9599913051
E-mail: oneplusul@gmail.com

ONEPLUS ULTRASOUND LAB

47, HARSH VIHAR, PITAMPURA, DELHI- 110034

Mr. AMAN JAIN
Age : 35M
Ref. by : MEDIVHEEL
Indication1 :
Indication2 :
Indication3 :
COMMENTS : Normal ECG

ID : 1857
HiWi : 18377
Recorded : 22-1-2022 12:15
Medication1 :
Medication2 :
Medication3 :

BPM : 80
BP : 118/78
P Axis : 75 deg
QRS Axis : 64 deg
T Axis : 78 deg

P duration : 93 msec
PR duration : 120 msec
QRS duration : 100 msec
QT Interval : 290 msec
QTc Interval : 325 msec

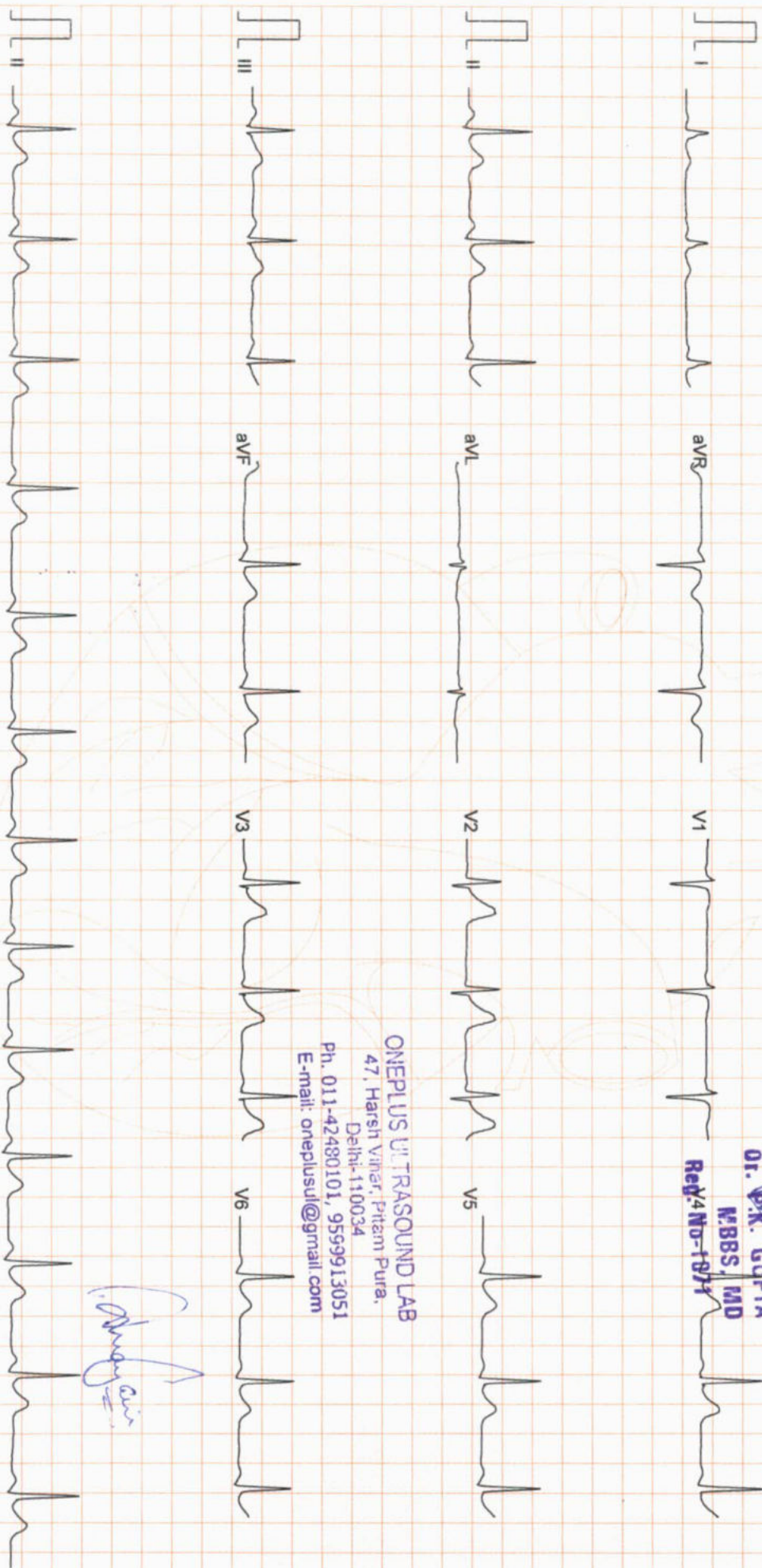
Raw E.C.G.(Seq)

Unconfirmed Report Reviewed By:

Cardiologist

Dr. P.K. GUPTA
MBBS, MD

Regd No-1871



ONEPLUS ULTRASOUND LAB
47, Harsh Vihar, Pitam Pura,
Delhi-110034
Ph. 011-42480101, 9599913051
E-mail: onepplusul@gmail.com

Amman Jain

Filtered

25mm/sec 10mm/mV

ASIMW

CardiCom, INDIA

ONEPLUS ULTRASOUND LAB

47, HARSH VIHAR PITAMPURA DELHI 110034

ID : 985

HiWi: 183/77
Recorded : 22-1-2022 12:18

TREADMILL TEST SUMMARY REPORT

Protocol: BRUCE

History:

Medication1 :

Medication2 :

Medication3 :

Mr. AMAN JAIN

Age/Sex : 35/M

Ref by : MEDWHEEL

Indication1 :

Indication2 :

Indication3 :

PHASE	PHASE TIME	STAGE TIME	SPEED (Km./Hr.)	GRADE (%)	H.R. (BPM)	B.P. (mmHg)	RRP X100	II	ST LEVEL (mm) V2	V5	METS
STANDING											
SUPINE											
STAGE 1	2:59	2:59	2.70	10.00	111	130/80	144	1.3	2.7	1.1	4.80
STAGE 2	5:59	2:59	4.00	12.00	128	138/84	176	1.1	2.5	1.0	7.10
STAGE 3	8:59	2:59	5.40	14.00	157	150/86	235	0.2	2.0	0.3	10.00
STAGE 4	9:14	0:14	6.70	16.00	165	150/86	247	0.1	1.9	0.0	10.31
PEAK EXER	9:25	0:25			168	164/90	275	0.0	1.5	-0.3	10.56
RECOVERY	2:59	2:59	0.00	0.00	98	126/82	123	0.5	1.4	0.3	

RESULTS

Exercise Duration : 9:25 Minutes
 Max Heart Rate : 168 bpm 90 % of target heart rate 185 bpm
 Max Blood Pressure : 164/90 mmHg
 Max Work Load : 10.56 METS
 Reason of Termination :

IMPRESSIONS

Normal for well fit



Cardiologist
 Dr. A.K. GUPTA
 MBBS, MD
 Reg. No-1071



ONEPLUS ULTRASOUND LAB
 47, Harsh Vihar, Pitam, Pura,
 Delhi-110034
 Ph. 011-42480101, 9559913051
 E-mail: onepulsul@gmail.com

ONEPLUS ULTRASOUND LAB

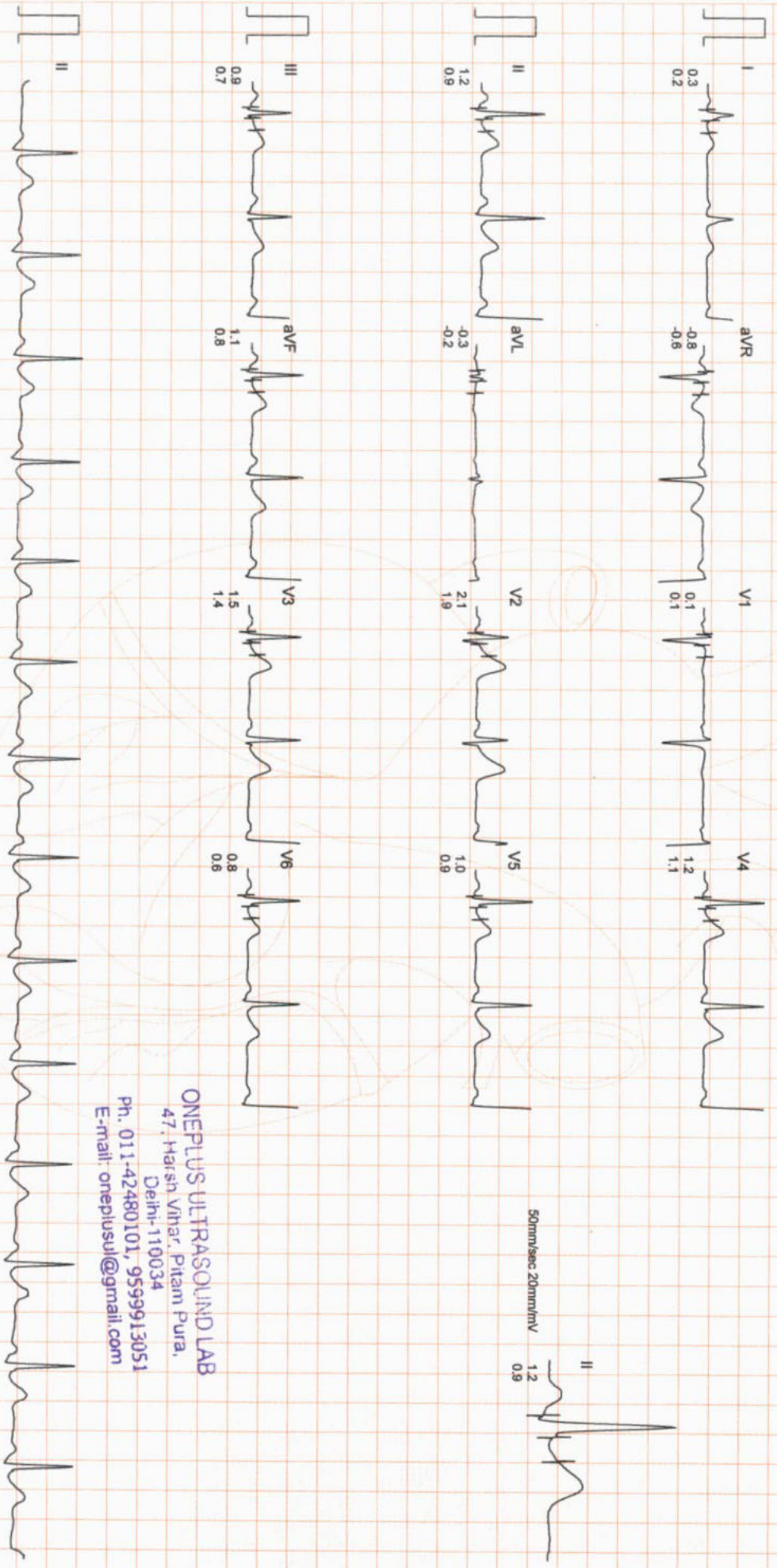
STANDING
PRETEST

ST @ 10mm/mV
80ms PostJ

Mr. AMAN JAIN
I.D. : 985
AGE/SEX : 35/M
RECORDED : 22-1-2022 12:18

RATE : 89 BPM
B.P. : 118/78 mmHg

LINKED MEDIAN



ONEPLUS ULTRASOUND LAB
47, Harsh Vihar, Pitam Pura,
Delhi-110034
Ph. 011-42480101, 9559913051
E-mail: oneplusul@gmail.com

ONEPLUS ULTRASOUND LAB

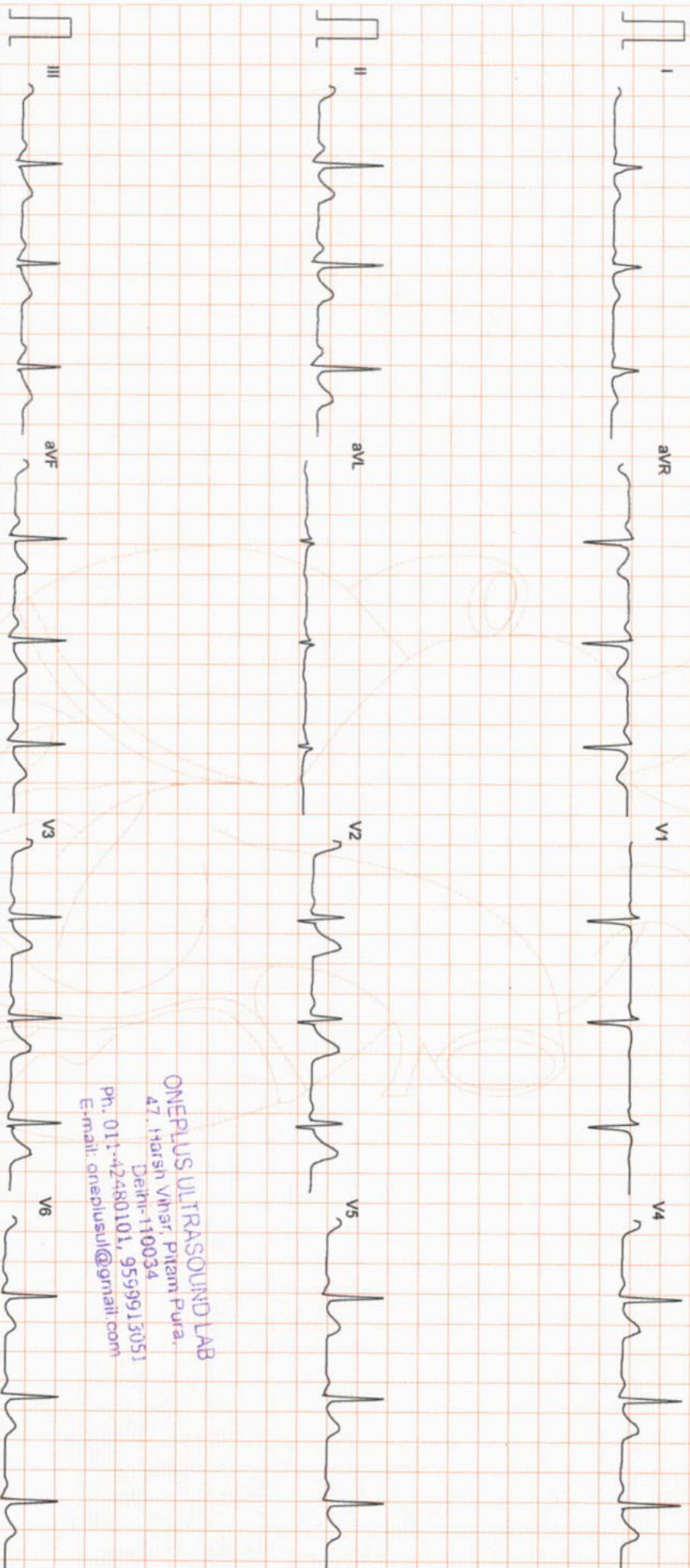
SUPINE
PRETEST

ST @ 10mm/mV
80ms PostJ

Mr. AMAN JAIN
I.D. : 985
AGE/SEX : 35/M
RECORDED : 22-1-2022 12:18

RATE : 88 BPM
B.P. : 118/78 mmHg

RAW E.C.G.



ONEPLUS ULTRASOUND LAB
47, Harsh Vihar, Pitam Pura,
Delhi-110034
Ph: 011-42480101, 9599913051
E-mail: oneplusul@gmail.com

Filtered

25mm/sec 10mm/mV

ACEW

CardiCom, INDIA Ph.:091-731-2620740, TeleFax:091-731-2431214

ONEPLUS ULTRASOUND LAB

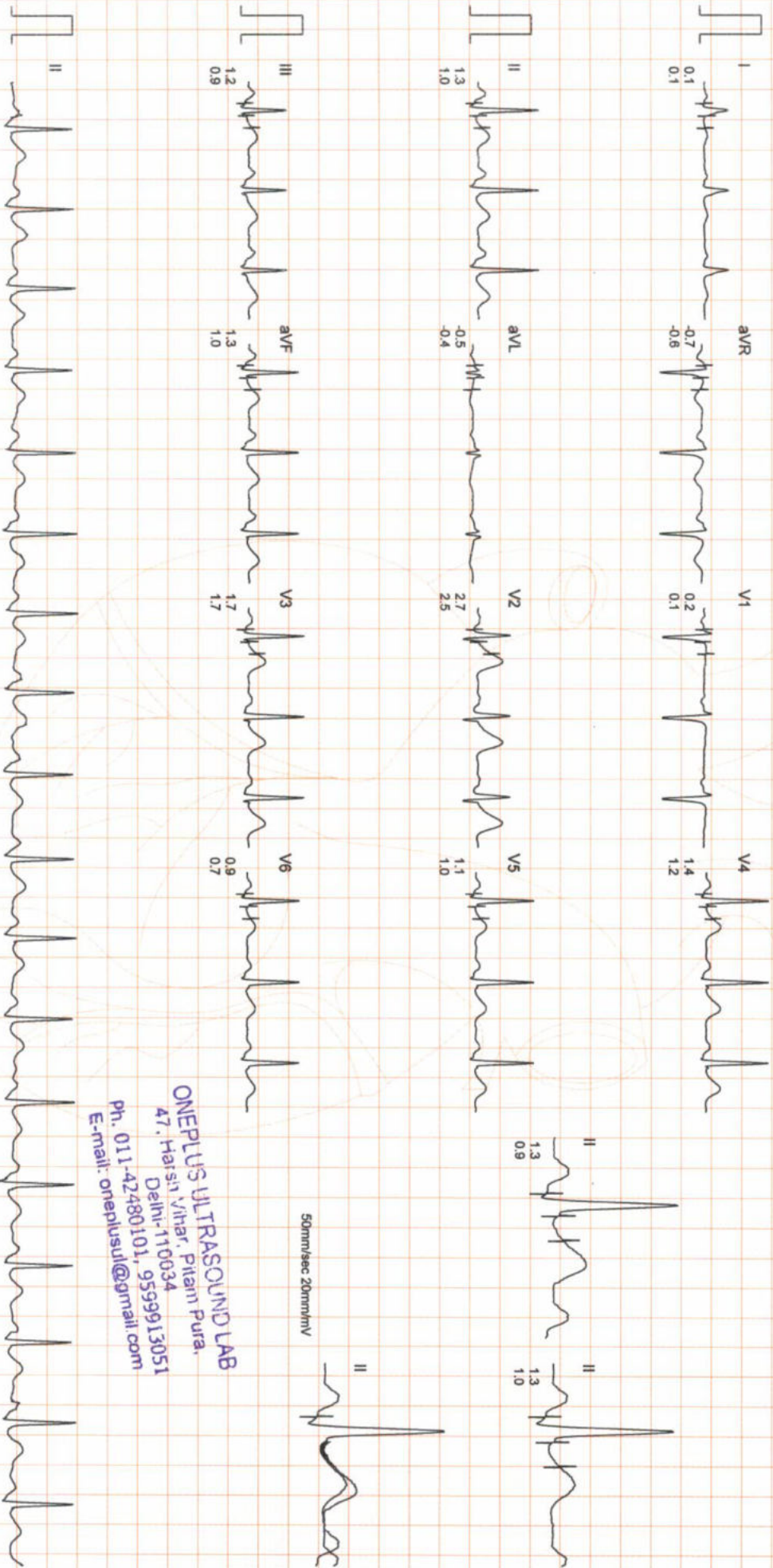
Mr. AMAN JAIN
I.D. : 985
AGE/SEX : 35/M
RECORDED : 22-1-2022 12:18

RATE : 111 BPM
B.P. : 130/80 mmHg

BRUCE
EXERCISE 1
PHASE TIME : 2:59
STAGE TIME : 2:59

ST @ 10mm/mV
80ms PostU
SPEED : 2.7 Km./Hr.
GRADE : 10.0 %

LINKED MEDIAN



ONEPLUS ULTRASOUND LAB
47, Harsiy Vihar, Pitam Pura,
Delhi-110034
Ph. 011-42480101, 9599913051
E-mail: onepplusul@gmail.com

50mm/sec 20mm/mV

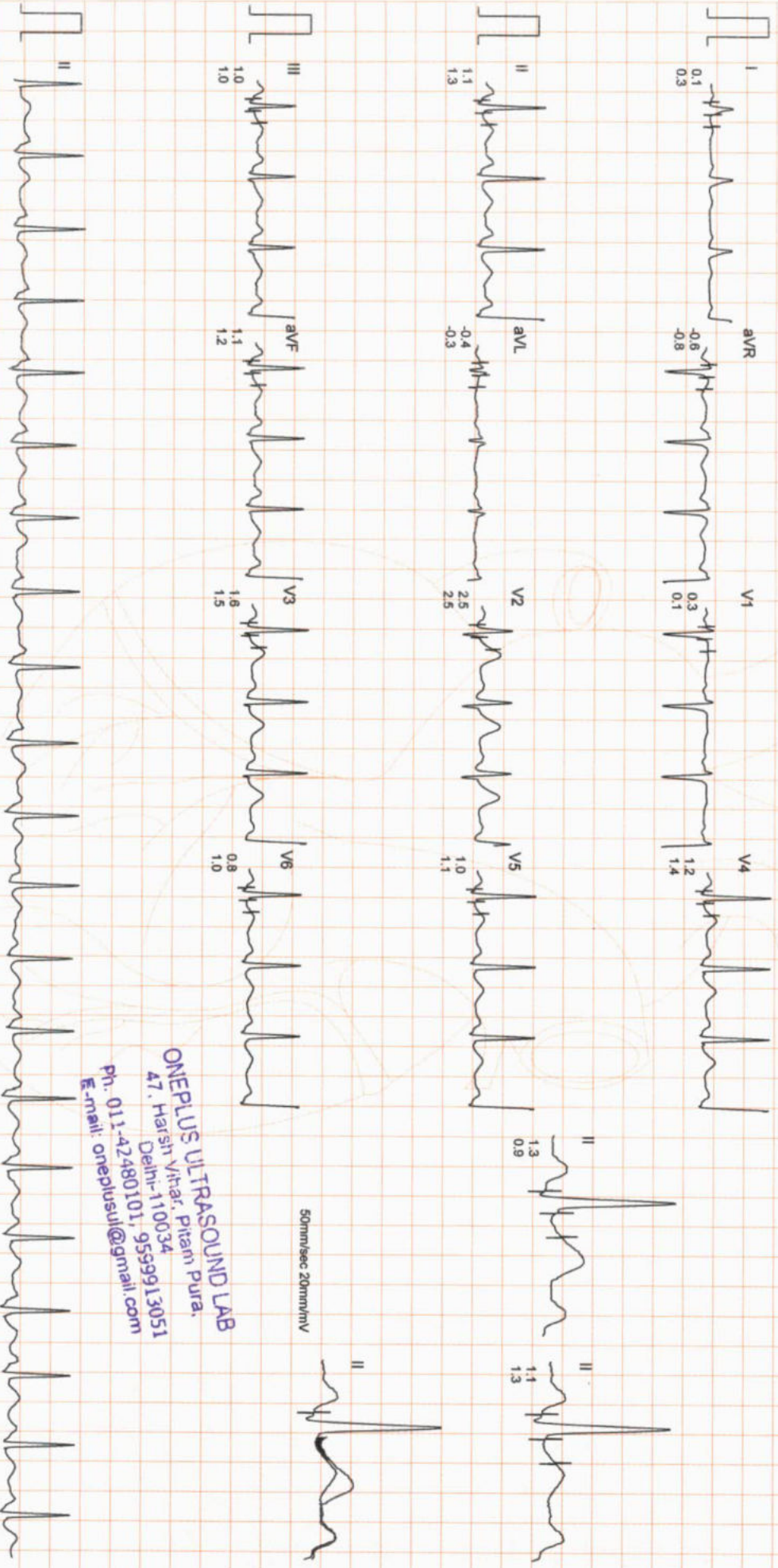
ONEPLUS ULTRASOUND LAB

Mr. AMAN JAIN
I.D. : 985
AGE/SEX : 35/M
RECORDED : 22-1-2022 12:18

BRUCE
EXERCISE 2
PHASE TIME : 5:59
STAGE TIME : 2:59

ST @ 10mm/mV
80ms PostJ
SPEED : 4.0 Km./Hr.
GRADE : 12.0 %

LINKED MEDIAN



ONEPLUS ULTRASOUND LAB
47, Harsh Vihar, Pitam Pura,
Delhi-110034
Ph: 011-42480101, 9539913051
E-mail: oneplusul@gmail.com

ONEPLUS ULTRASOUND LAB

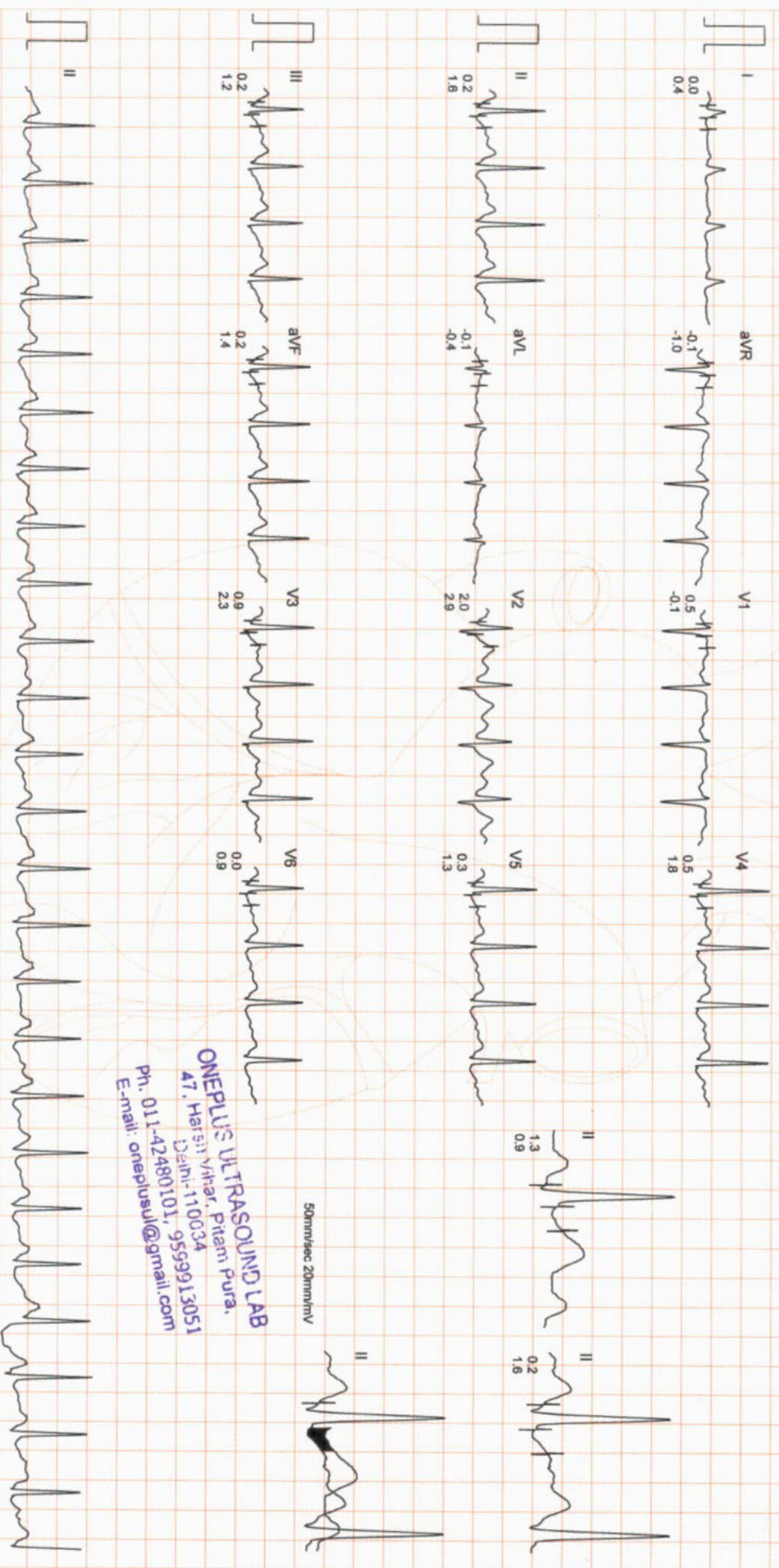
Mr. AMAN JAIN
I.D. : 985
AGE/SEX : 35/M
RECORDED : 22-1-2022 12:18

RATE : 157 BPM
B.P. : 150/86 mmHg

BRUCE
EXERCISE 3
PHASE TIME : 8:59
STAGE TIME : 2:59

ST @ 10mm/mV
80ms PostJ
SPEED : 5.4 Km./Hr.
GRADE : 14.0 %

LINKED MEDIAN



ONEPLUS ULTRASOUND LAB
47, Harsiji Vihar, Pitam Pura.
Delhi-110034
Ph. 011-42480101, 9599913051
E-mail: oneplusul@gmail.com

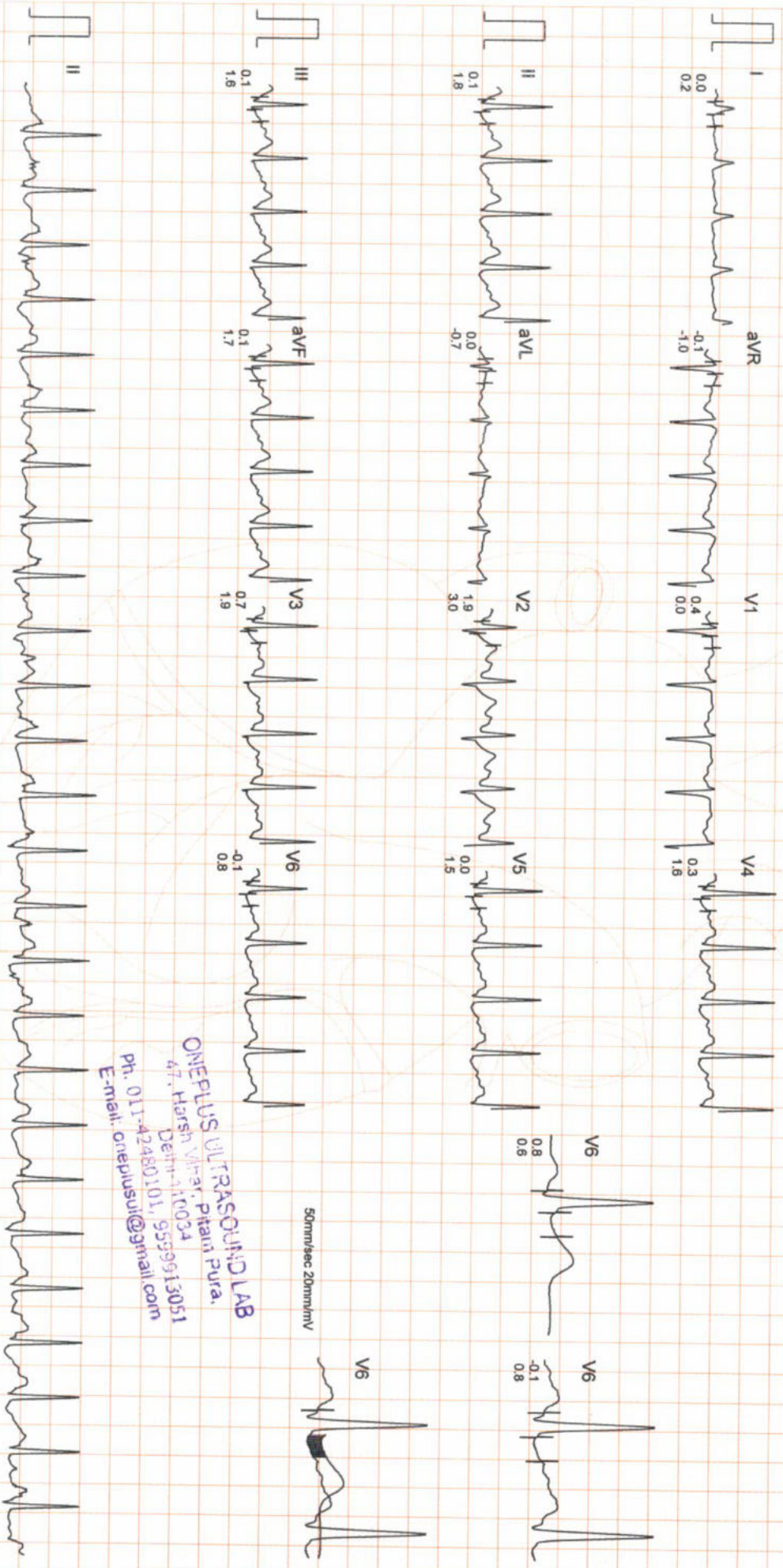
ONEPLUS ULTRASOUND LAB

Mr. AMAN JAIN
 I.D. : 985
 AGE/SEX : 35/M
 RECORDED : 22-1-2022 12:18

RATE : 165 BPM
 B.P. : 150/86 mmHg

BRUCE
 EXERCISE 4
 PHASE TIME : 9:14
 STAGE TIME : 0:14

ST @ 10mm/mV
 80ms PostJ
 SPEED : 6.7 Km./Hr.
 GRADE : 16.0 %
 LINKED MEDIAN



ONEPLUS ULTRASOUND LAB
 47, Harsh Vihar, Pitam Pura,
 Delhi-110034
 Ph. 011-42480101, 9559913051
 E-mail: oneplusul@gmail.com

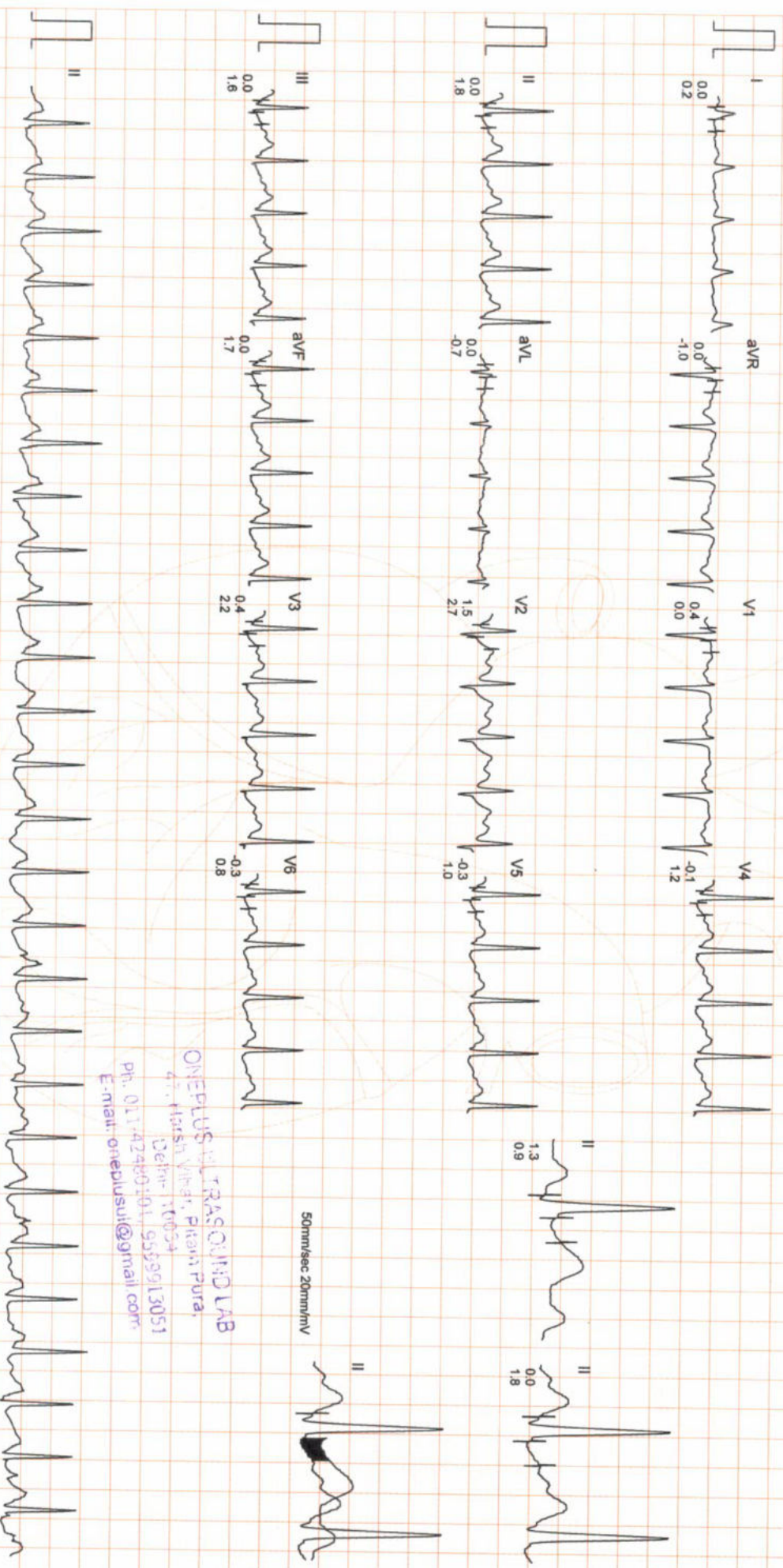
ONEPLUS ULTRASOUND LAB

Mr. AMAN JAIN
I.D. : 985
AGE/SEX : 35/M
RECORDED : 22-1-2022 12:18

RATE : 168 BPM
B.P. : 164/90 mmHg

BRUCE
PEAK EXER
PHASE TIME : 9:25
STAGE TIME : 0:25

ST @ 10mm/mv
80ms PostJ
SPEED : 6.7 Km./HR.
GRADE : 16.0 %
LINKED MEDIAN



ONEPLUS ULTRASOUND LAB
47, Harsh Vihar, Preeti Pura,
Delhi- 110054
Ph: 011-42460101, 9559913051
E-mail: onepiusul@gmail.com

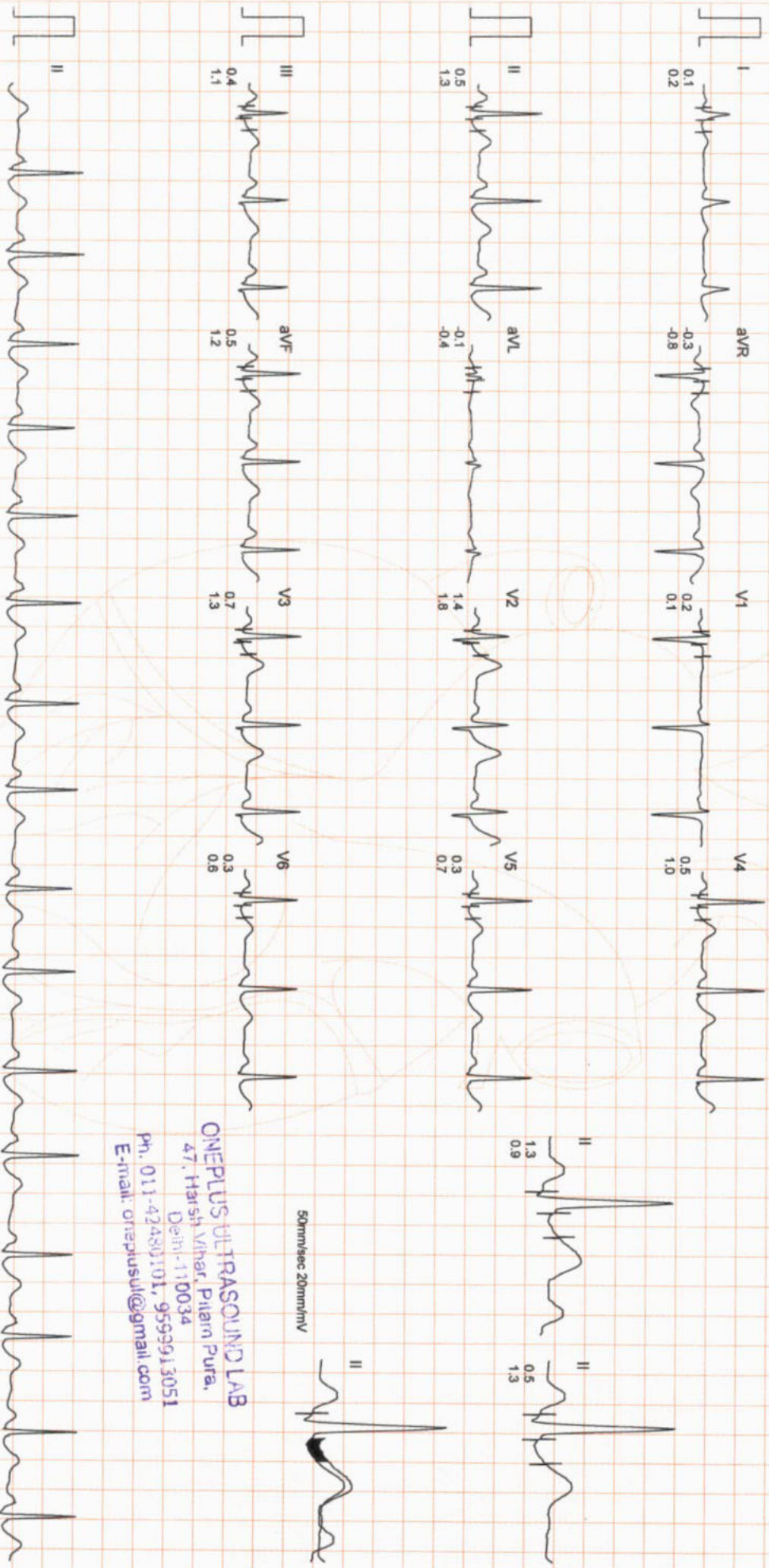
ONEPLUS ULTRASOUND LAB

Mr. AMAN JAIN
I.D. : 985
AGE/SEX : 35/M
RECORDED : 22-1-2022 12:18

RATE : 98 BPM
B.P. : 126/82 mmHg

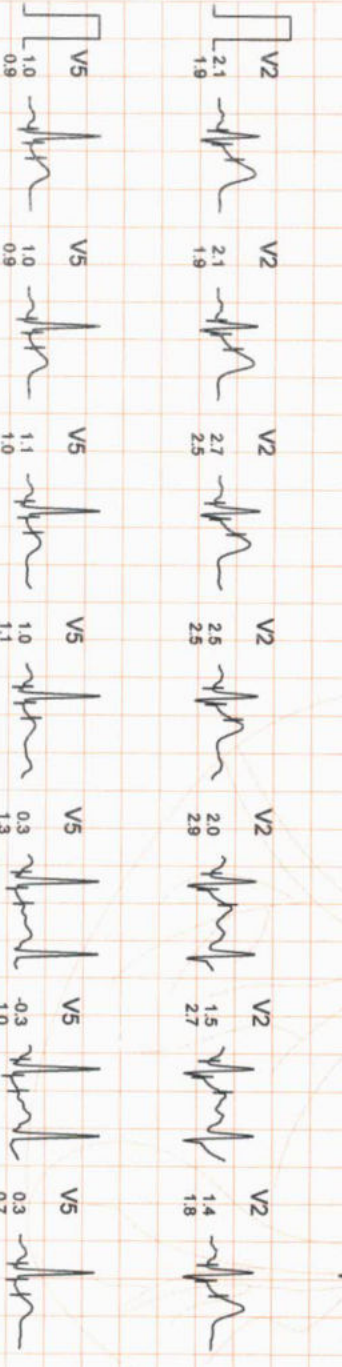
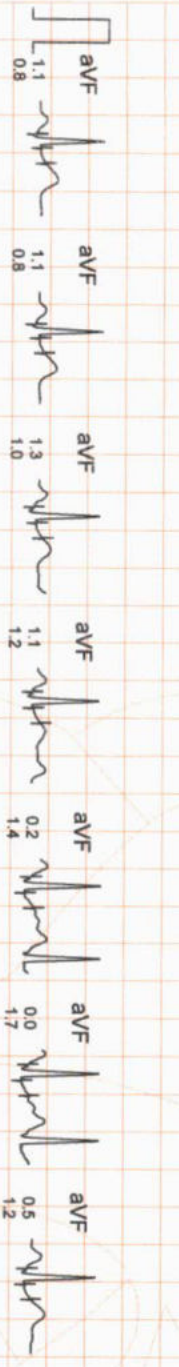
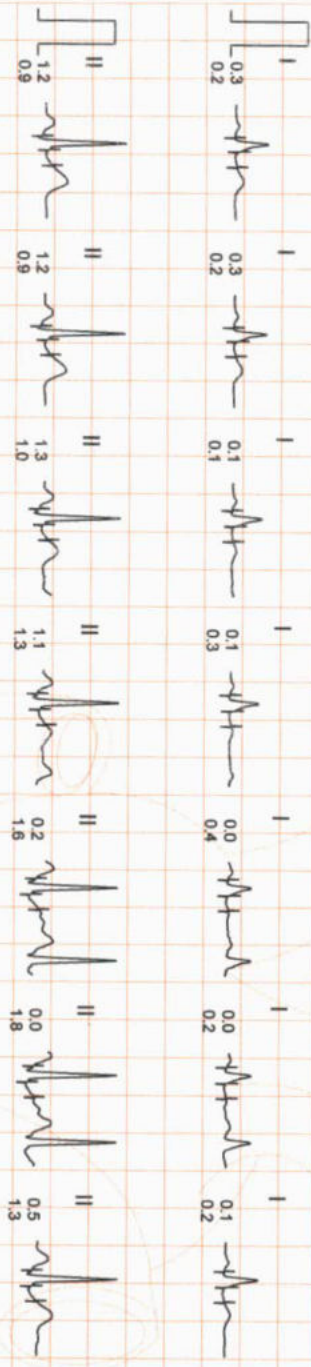
BRUCE
RECOVERY
PHASE TIME : 2:59

ST @ 10mm/mV
80ms PostJ
SPEED : 0.0 Km./Hr.
GRADE : 0.0 %
LINKED MEDIAN



ONEPLUS ULTRASOUND LAB
47, Harsh Vihar, Pitara Pura,
Delhi-110034
Ph. 011-42480101, 9599913051
E-mail: oneplusul@gmail.com

STANDING	SUPINE	STAGE 1	STAGE 2	STAGE 3	PEAK EXERCISE	RECOVERY
0.0kmph 0.0% 89 bpm B.P. 118/78 80ms Postu	0.0kmph 0.0% 88 bpm B.P. 118/78 80ms Postu	2.59 2:59 2.7kmph 10.0% 111 bpm B.P. 130/80 80ms Postu	5:59 2:59 4.0kmph 12.0% 128 bpm B.P. 138/84 80ms Postu	8:59 0:25 5.4kmph 14.0% 157 bpm B.P. 150/86 80ms Postu	9:25 0:25 6.7kmph 16.0% 168 bpm B.P. 164/90 80ms Postu	2:59 0.0kmph 0.0% 98 bpm B.P. 126/82 80ms Postu



ONEPLUS ULTRASOUND LAB
 47, Harsih vihar, Pitam Pura,
 Delhi-110034
 Ph. 011-42480101, 9559913051
 E-mail: oneplusul@gmail.com










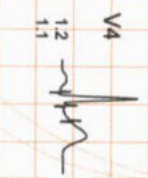

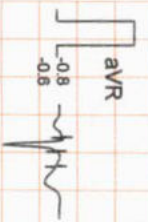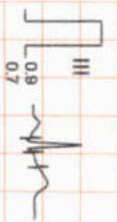




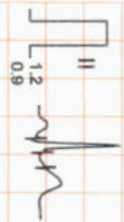
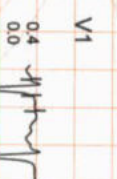

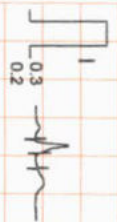
ONEPLUS ULTRASOUND LAB

SUPINE
 0.0Kmph
 0.0%
 88 bpm
 B.P. 118/78
 80ms PostU

PEAK EXERCISE
 9.25
 0.25
 6.7Kmph
 16.0%
 168 bpm
 B.P. 164/90
 80ms PostU

SUPINE
 0.0Kmph
 0.0%
 88 bpm
 B.P. 118/78
 80ms PostU

PEAK EXERCISE
 9.25
 0.25
 6.7Kmph
 16.0%
 168 bpm
 B.P. 164/90
 80ms PostU



ONEPLUS ULTRASOUND LAB
 47, Harsh Vihar, Pitam Pura,
 Delhi-110034
 Ph. 011-42480101, 9559913051
 E-mail: oneplusul@gmail.com



OnePLUS Ultrasound Lab

— QUALITY FIRST... ALWAYS! —

Dr. Nitin Agarwal

Pathologist & Director
Ex. Sr. Res. MAMC
& Lok Nayak Hospital
Ex. Chief of Lab Dr. Lal Path Labs.

Dr. Pooja (Garg) Agarwal

Radiologist & Director
MAMC & Lok Nayak Hospital



NAME	:Mr. AMAN JAIN	Barcode No	:10112301
AGE/GENDER	:35 YRS/Male	SPECIMEN DATE	:22/Jan/2022 11:19AM
PATIENT ID	:90282	SPECIMEN RECEIVED	:22/Jan/2022 01:09PM
REFERRED BY	:Dr. MEDIWHEEL	REPORT DATE	:22/Jan/2022 03:17PM
CENTRE NAME	:ONEPLUS ULTRASOUND LAB	LAB NO.	:012201220025

Test Name	Result	Unit	Ref. Range
-----------	--------	------	------------

HAEMATOLOGY

Health checkup 2 Male

Glycosylated Hemoglobin (HbA1c)	4.8	%	Non Diabetic adults <5.7 Prediabetic (at risk) 5.7-6.4 Diabetes >6.4
--	-----	---	--

Estimated average blood glucose (eag)	91
--	----

Reference range (mg/dl):

90 - 120:Excellent control, 121 - 150:Good Control, 151 - 180:Average Control, 181 - 210:Action Suggested

>211:Panic value

BLOOD GROUP (ABO)	B
Rh typing	POSITIVE

NOTE :

- * Apart from major A,B,H antigens which are used for ABO grouping and Rh typing, many minor blood group antigens exist. Agglutination may also vary according to titre of antigen and antibody.
- * So before transfusion, reconfirmation of blood group as well as cross-matching is needed.
- * Presence of maternal antibodies in newborns, may interfere with blood grouping.
- * Auto agglutination (due to cold antibody, falciparum malaria, sepsis, internal malignancy etc.) may also cause erroneous result.

CBC

Haemoglobin	15.2	g/dl	13.0-17.0
Total Leucocyte Count	5350	/cumm	4000-10000
Differential leucocyte count			
Neutrophils	56.5	%	40-80
Lymphocyte	34.40	%	20-40
Monocytes	6.10	%	2-10
Eosinophils	2.7	%	1-6
Basophils	0.3	%	0-2
RBC Count	4.88	million/cumm	4.5 - 5.5

Checked By.

DR. NITIN AGARWAL
MBBS, MD (PATHOLOGIST)
DMC/R/01436

47, Harsh Vihar, Pitampura, New Delhi-110034 | Ph.: 011-42480101, 9599913051

E-mail: oneplusul@gmail.com | Web.: www.oneplusul.in

Page 1 of 5



OnePLUS

Ultrasound Lab

— QUALITY FIRST... ALWAYS! —

Dr. Nitin Agarwal
Pathologist & Director
Ex. Sr. Res. MAMC
& Lok Nayak Hospital
Ex. Chief of Lab Dr. Lal Path Labs.

Dr. Pooja (Garg) Agarwal
Radiologist & Director
MAMC & Lok Nayak Hospital



NAME	:Mr. AMAN JAIN	Barcode No	:10112301
AGE/GENDER	:35 YRS/Male	SPECIMEN DATE	:22/Jan/2022 11:19AM
PATIENT ID	:90282	SPECIMEN RECEIVED	:22/Jan/2022 01:09PM
REFERRED BY	:Dr. MEDIWHEEL	REPORT DATE	:22/Jan/2022 03:17PM
CENTRE NAME	:ONEPLUS ULTRASOUND LAB	LAB NO.	:012201220025

Test Name	Result	Unit	Ref. Range
PCV(Hematocrit)	45.6	%	40-50
MCV	93.4	fL	83-101
MCH	31.0	Pg	27-32
MCHC	33.2	G/dL	32-35
Platelet count	221000	/cumm	150000-450000
RDW-CV	12.5	%	11.4-14.0
ESR(WESTEGRENs METHOD)	10	mm in 1st hr	0-20

BIOCHEMISTRY

<u>Blood sugar fasting</u>	93	mg/dL	70-110
<u>Bun (blood urea nitrogen)</u>	11.40	mg/dl	8.9-21.6
<u>Uric acid, serum</u>	3.8	mg/dl	3.4-7.0
<u>Creatinine, serum</u>	0.78	mg/dl	0.60-1.1

LFT(LIVER FUNCTION TEST)

Bilirubin Total	0.62	mg/dl	0.1-1.2
Bilirubin Conjugated	0.34	mg/dl	0-0.4
Bilirubin Unconjugated	0.28	mg/dl	up to 0.7
SGOT (AST)	26	U/L	0-35
SGPT (ALT)	28	U/L	<45.0
Alkaline phosphatase	94	U/L	40-129
Gamma glutamyl transpeptidase	24	U/L	<66
Total Protein	7.2	gm/dl	6.60 - 8.70
Albumin	4.0	g/dL	3.8-5.1
Globulin	3.20	gm/dl	1.8-3.4
Albumin/Globulin Ratio	1.25		1.10 - 2.50

LIPID PROFILE

Cholesterol	184	mg/dl	50-200
Triglycerides	282	mg/dL	25-150
HDL Cholesterol	44	mg/dL	30-70

Checked By.

DR. NITIN AGARWAL
MBBS, MD (PATHOLOGIST)

Dr NITIN AGARWAL
MBBS, MD (Path)

47, Harsh Vihar, Pitampura, New Delhi-110034 | Ph.: 011-42486101, 9599913051

E-mail: oneplusul@gmail.com | Web.: www.oneplusul.in

Page 2 of 5



OnePLUS

Ultrasound Lab

— QUALITY FIRST... ALWAYS! —

Dr. Nitin Agarwal

Pathologist & Director
Ex. Sr. Res. MAMC
& Lok Nayak Hospital
Ex. Chief of Lab Dr. Lal Path Labs.

Dr. Pooja (Garg) Agarwal

Radiologist & Director
MAMC & Lok Nayak Hospital



NAME	:Mr. AMAN JAIN	Barcode No	:10112301
AGE/GENDER	:35 YRS/Male	SPECIMEN DATE	:22/Jan/2022 11:19AM
PATIENT ID	:90282	SPECIMEN RECEIVED	:22/Jan/2022 01:09PM
REFERRED BY	:Dr. MEDIWHEEL	REPORT DATE	:22/Jan/2022 03:17PM
CENTRE NAME	:ONEPLUS ULTRASOUND LAB	LAB NO.	:012201220025

Test Name	Result	Unit	Ref. Range
LDL cholesterol	84	mg/dL	<130
VLDL cholesterol	56.4	mg/dL	5-40
Cholesterol/HDL Ratio	4.2		Low Risk 3.3-4.97 Average Risk 4.4-7.1 Moderate Risk 7.1-11.0 High Risk >11.0
LDL/HDL Ratio	1.9		0 - 3.55

According to ATP III and NCEP guidelines

Parameter	Normal	Desirable	Borderline	High
Total cholesterol	<200	200-239		240
Triglycerides	<150	150-199	200-499	500
LDL	Optimal <100 Near Optimal 100-129	130-159	160-180	190
HDL	<40 : LOW 60 : HIGH			

ENDOCRINOLOGY

PSA TOTAL

Prostatic specific antigen, Total 1.10 ng/ml <4.0

< 40 years	0.21 to 1.72 ng/ml
40 - 49	0.27 to 2.19 ng/ml
50 - 59	0.27 to 3.42 ng/ml
60 - 69	0.22 to 6.16 ng/ml
> 69	0.21 to 6.77 ng/ml

Notes:

PSA is principally produced by the glandular epithelium of the prostate, and is secreted in the seminal fluid. PSA is also present in urine and blood. PSA acts on seminal fluid to fluidify and increase sperm mobility. PSA levels rise in prostatic pathologies such as

Checked By.

DR. NITIN AGARWAL
MBBS, MD (PATHOLOGIST)

47, Harsh Vihar, Pitampura, New Delhi-110034 | Ph.: 011-42480101, 9599913051

E-mail: oneplusul@gmail.com | Web.: www.oneplusul.in

Page 3 of 5



OnePLUS

Ultrasound Lab

— QUALITY FIRST... ALWAYS! —

Dr. Nitin Agarwal

Pathologist & Director
Ex. Sr. Res. MAMC
& Lok Nayak Hospital
Ex. Chief of Lab Dr. Lal Path Labs.

Dr. Pooja (Garg) Agarwal

Radiologist & Director
MAMC & Lok Nayak Hospital



NAME	:Mr. AMAN JAIN	Barcode No	:10112301
AGE/GENDER	:35 YRS/Male	SPECIMEN DATE	:22/Jan/2022 11:19AM
PATIENT ID	:90282	SPECIMEN RECEIVED	:22/Jan/2022 01:09PM
REFERRED BY	:Dr. MEDIWHEEL	REPORT DATE	:22/Jan/2022 03:17PM
CENTRE NAME	:ONEPLUS ULTRASOUND LAB	LAB NO.	:012201220025

Test Name	Result	Unit	Ref. Range
-----------	--------	------	------------

benign prostatic hyperplasia (BPH) or prostate cancer.

THYROID PROFILE(T3,T4,TSH)

Triiodothyronine total [t3]	0.64	ng/dl	0.52-1.9
Thyroxine total [t4]	7.20	µg/dl	4.4 - 10.8
TSH (Thyroid Stimulating Hormone)	2.00	µIU/ml	0.25-5.0

AGE WISE VARIATION IN TSH

AGE	TSH(µIU/ml)	AGE	TSH(µIU/ml)
1-4 weeks	1.00 - 19.0	16-20 yrs	0.25 - 5.0
1-12 mths	1.70 - 9.1	21 - 80 yrs	0.25 - 5.0
1-5 yrs	0.80 - 8.2	I st trimester	0.25 - 5.0
6-10 yrs	0.25 - 5.0	II nd trimester	0.50 - 5.0
11-15 yrs	0.25 - 5.0	II rd trimester	0.4 - 6.0

Reference ranges - Interpretation of Diagnostic tests - (Jacques Wallach)

1. Primary hypothyroidism is accompanied by depressed serum T3 and T4 values and elevated serum TSH level.
2. Primary hyperthyroidism is accompanied by elevated serum T3 and T4 levels along with depressed TSH values.
3. Slightly elevated T3 levels may be found in pregnancy and estrogen therapy, while depressed levels may be encountered in severe illness, renal failure and during therapy with drugs like propranolol and propyl thiouracil.
4. Although elevated TSH levels are nearly always indicative of primary hypothyroidism, and may be seen in secondary thyrotoxicosis

CLINICAL PATHOLOGY

URINE ROUTINE

Physical examination

Quantity	20	ML
Colour	PALE YELLOW	
Transparency	CLEAR	CLEAR
Sp.gravity	1.020	1.010-1.030
pH	6.00	
Reaction	ACIDIC	ACIDIC

Chemical examination

Checked By.

DR. NITIN AGARWAL
MBBS,MD(PATHOLOGIST)

Dr NITIN AGARWAL
MBBS, MD (Path)
DMC/R/DT436

47, Harsh Vihar, Pitampura, New Delhi-110034 | Ph.: 011-42480101, 9599913051

E-mail: oneplusul@gmail.com | Web.: www.oneplusul.in

Page 4 of 5



OnePLUS Ultrasound Lab

— QUALITY FIRST... ALWAYS! —

Dr. Nitin Agarwal

Pathologist & Director
Ex. Sr. Res. MAMC
& Lok Nayak Hospital
Ex. Chief of Lab Dr. Lal Path Labs.

Dr. Pooja (Garg) Agarwal

Radiologist & Director
MAMC & Lok Nayak Hospital



NAME	:Mr. AMAN JAIN	Barcode No	:10112301
AGE/GENDER	:35 YRS/Male	SPECIMEN DATE	:22/Jan/2022 11:19AM
PATIENT ID	:90282	SPECIMEN RECEIVED	:22/Jan/2022 01:09PM
REFERRED BY	:Dr. MEDIWHEEL	REPORT DATE	:22/Jan/2022 03:17PM
CENTRE NAME	:ONEPLUS ULTRASOUND LAB	LAB NO.	:012201220025

Test Name	Result	Unit	Ref. Range
Urine protein	NIL		NIL
Urine sugar	NIL		NIL
Bilirubin, urine	NEGATIVE		NEGATIVE
Urobilinogen	NORMAL		NORMAL
Ketones	NEGATIVE		NEGATIVE
<u>Microscopic examination</u>			
Pus cells.	1-2	/HPF	0-2
Epithelial cells	1-2	/HPF	NIL
R.B.C.	NIL	/HPF	NIL
Casts	NIL	/HPF	NIL
Crystals	NIL	/HPF	NIL
Bacteria	NIL	/HPF	NIL
Others.	NIL	NIL	NIL

*** End Of Report ***

Checked By.

DR. NITIN AGARWAL
MBBS, MD (PATHOLOGIST)

Dr NITIN AGARWAL
MBBS, MD (Path)
DMC/R/01/01

47, Harsh Vihar, Pitampura, New Delhi-110034 | Ph.: 011-42480101, 9599913051

E-mail: oneplusul@gmail.com | Web.: www.oneplusul.in

Page 5 of 5



OnePLUS
Ultrasound Lab

— QUALITY FIRST... ALWAYS! —

Dr. Nitin Agarwal
Pathologist & Director
Ex. Sr. Res. MAMC
& Lok Nayak Hospital
Ex. Chief of Lab Dr. Lal Path Labs.

Dr. Pooja (Garg) Agarwal
Radiologist & Director
MAMC & Lok Nayak Hospital

Name	: Mr. AMAN JAIN	Age/Sex	: 35 YRS/Male
Ref. By	: Dr. MEDIWHEEL	Lab No	: 012201220025
Date	: 22-Jan-2022	Patient ID	: LSHHI90282

ULTRASOUND EXAMINATION---WHOLE ABDOMEN

Liver is normal in size (14.9 cm) and normal in outline with **altered echopattern. Diffuse increase in echogenicity of liver parenchyma is noted, suggestive of fatty infiltration (grade I).** Intrahepatic biliary radicles are not dilated. No abscess or mass lesion seen. Hepatic veins, portal vein, IVC and aorta are normal. CBD is normal in caliber.

Gall bladder is well distended with anechoic lumen. Wall thickness is normal.

Both kidneys are normal in size, shape, position, outline and echopattern. Corticomedullary differentiation is maintained. No pelvicalyceal dilation or mass lesion is seen.

Spleen is normal in size and echotexture. No mass lesion seen.

Pancreas is normal in size, outline and echotexture.

Urinary bladder is normal in shape and position. No evidence of intravesical stone or mass seen.

Prostate is normal in size, shape and echopattern.

Prostate measures 2.8 x 2.8 x 4.3 cm. **Weight of prostate is 17 grams.**

No abnormal bowel wall thickening seen in right iliac fossa.
No free fluid seen anywhere in abdomen.

IMPRESSION:

- **Fatty infiltration of liver (grade I) with no hepatomegaly.**

Dr. POOJA GARG
M.B.B.S., D.M.R.D.
Reg No. DMC/R/03398
Radiologist

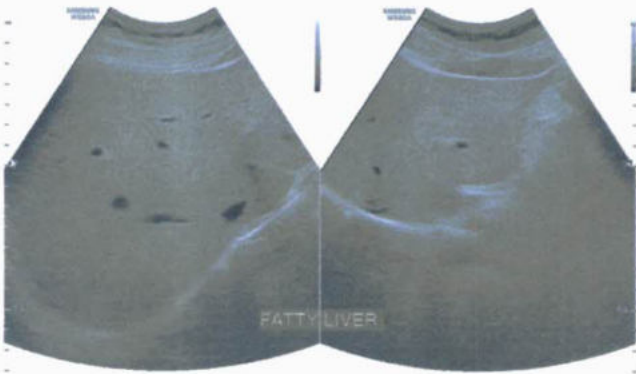DR. POOJA GARG
RADIOLOGIST
REG NO- DMC/R/03398

Type By : darshita

47, Harsh Vihar, Pitampura, New Delhi-110034 | Ph.: 011-42480101, 9599913051
E-mail: oneplusul@gmail.com | Web.: www.oneplusul.in

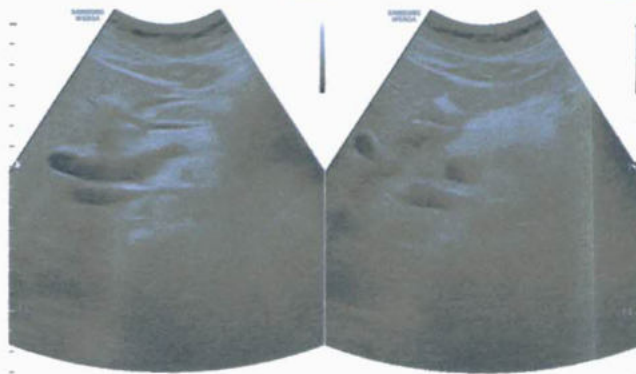W880A MR AMAN 35/M OnePlus Ultrasound Lab MI 1.4 22-01-2022
CA1-7A / Abdomen / FR 24Hz Tls 0.1 12:49:06 PM

G70 DR135-FAB-P90-Frq Gen.17.0cm G70 DR135-FAB-P90-Frq Gen.17.0cm



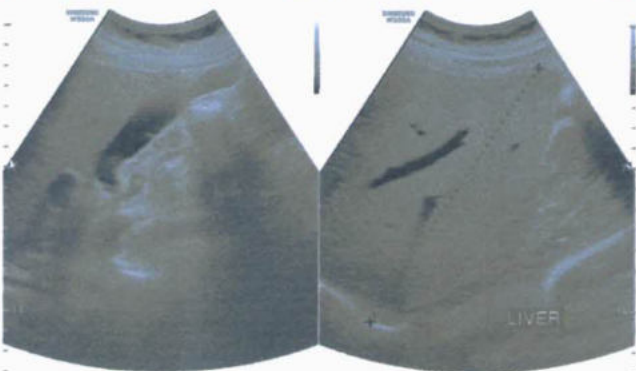W880A MR AMAN 35/M OnePlus Ultrasound Lab MI 1.4 22-01-2022
CA1-7A / Abdomen / FR 24Hz Tls 0.1 12:49:14 PM

G70 DR135-FAB-P90-Frq Gen.17.0cm G70 DR135-FAB-P90-Frq Gen.17.0cm



W880A MR AMAN 35/M OnePlus Ultrasound Lab MI 1.4 22-01-2022
CA1-7A / Abdomen / FR 24Hz Tls 0.1 12:49:33 PM

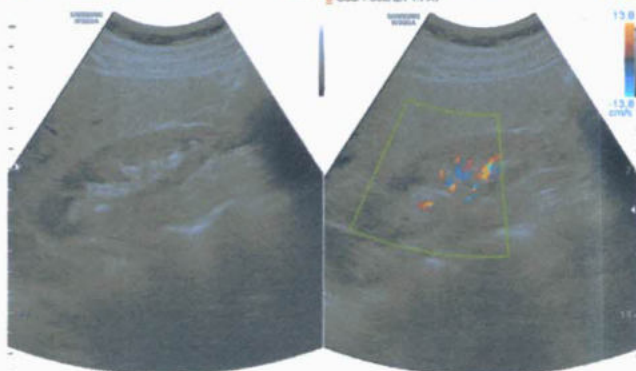
G70 DR135-FAB-P90-Frq Gen.17.0cm G70 DR135-FAB-P90-Frq Gen.17.0cm



D1 14.85 cm

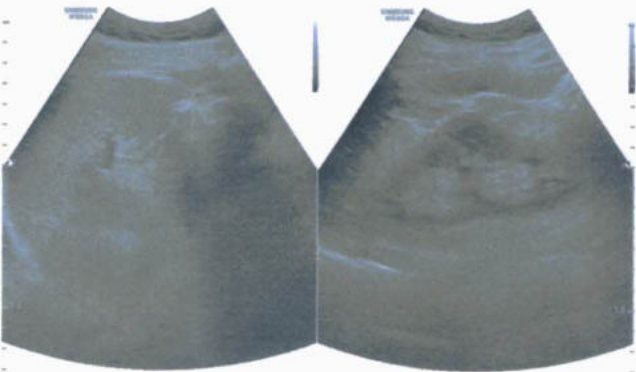W880A MR AMAN 35/M OnePlus Ultrasound Lab MI 1.3 22-01-2022
CA1-7A / Abdomen / FR 18Hz Tls 0.7 12:49:49 PM

G70 DR135-FAB-P90-Frq Gen.17.0cm G60-1 00MHz-F1-FA7



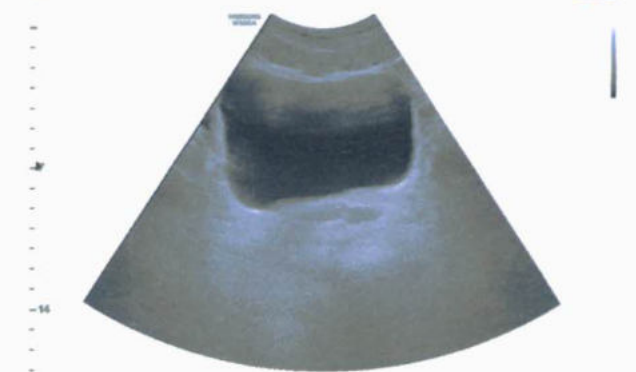
W880A MR AMAN 35/M OnePlus Ultrasound Lab MI 1.4 22-01-2022
CA1-7A / Abdomen / FR 24Hz Tls 0.1 12:50:10 PM

G70 DR135-FAB-P90-Frq Gen.17.0cm G70 DR135-FAB-P90-Frq Gen.17.0cm



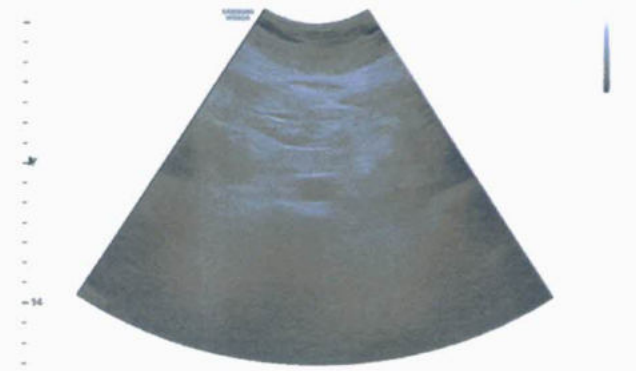W880A MR AMAN 35/M OnePlus Ultrasound Lab MI 1.4 22-01-2022
CA1-7A / Abdomen / FR 24Hz Tls 0.1 12:50:18 PM

G68 DR135-FAB-P90-Frq Gen.17.0cm



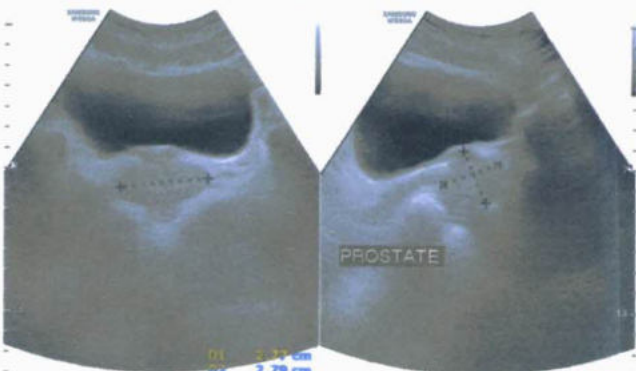W880A MR AMAN 35/M OnePlus Ultrasound Lab MI 1.4 22-01-2022
CA1-7A / Abdomen / FR 24Hz Tls 0.1 12:50:38 PM

G68 DR135-FAB-P90-Frq Gen.17.0cm



W880A MR AMAN 35/M OnePlus Ultrasound Lab MI 1.4 22-01-2022
CA1-7A / Abdomen / FR 24Hz Tls 0.1 12:51:15 PM

G68 DR135-FAB-P90-Frq Gen.17.0cm G68 DR135-FAB-P90-Frq Gen.17.0cm



D1 3.37 cm
D2 2.79 cm
D3 4.27 cm
Vol. 17.33 ml

D1 2.77 cm
D2 2.79 cm



04/09/2018

07:13:50.000 24°C 254.78400
04/09/2018 08:18:50.000



04/09/2018

07:13:50.000 24°C 254.78400
04/09/2018 08:18:50.000



04/09/2018

07:13:50.000 24°C 254.78400
04/09/2018 08:18:50.000



04/09/2018

07:13:50.000 24°C 254.78400
04/09/2018 08:18:50.000



04/09/2018

07:13:50.000 24°C 254.78400
04/09/2018 08:18:50.000



04/09/2018

07:13:50.000 24°C 254.78400
04/09/2018 08:18:50.000



04/09/2018

07:13:50.000 24°C 254.78400
04/09/2018 08:18:50.000



04/09/2018

07:13:50.000 24°C 254.78400
04/09/2018 08:18:50.000





OnePLUS
Ultrasound Lab
— QUALITY FIRST... ALWAYS! —

Dr. Nitin Agarwal
Pathologist & Director
Ex. Sr. Res. MAMC
& Lok Nayak Hospital
Ex. Chief of Lab Dr. Lal Path Labs.


Dr. Pooja (Garg) Agarwal
Radiologist & Director
MAMC & Lok Nayak Hospital

Name	: Mr. AMAN JAIN	Age/Sex	: 35 YRS/Male
Ref. By	: Dr. MEDIWHEEL	Lab No	: 012201220025
Date	: 22-Jan-2022	Patient ID	: LSHHI90282

X-ray-Chest PA view

Bony cage and soft tissues are normal.
Cardiothoracic ratio is normal.
Mediastinum is normal.
Both hila are normal.
Both costophrenic angles are clear.
Both domes of diaphragm are normal.
Lung fields are clear. No parenchymal lesion seen.

IMPRESSION: Normal Study.

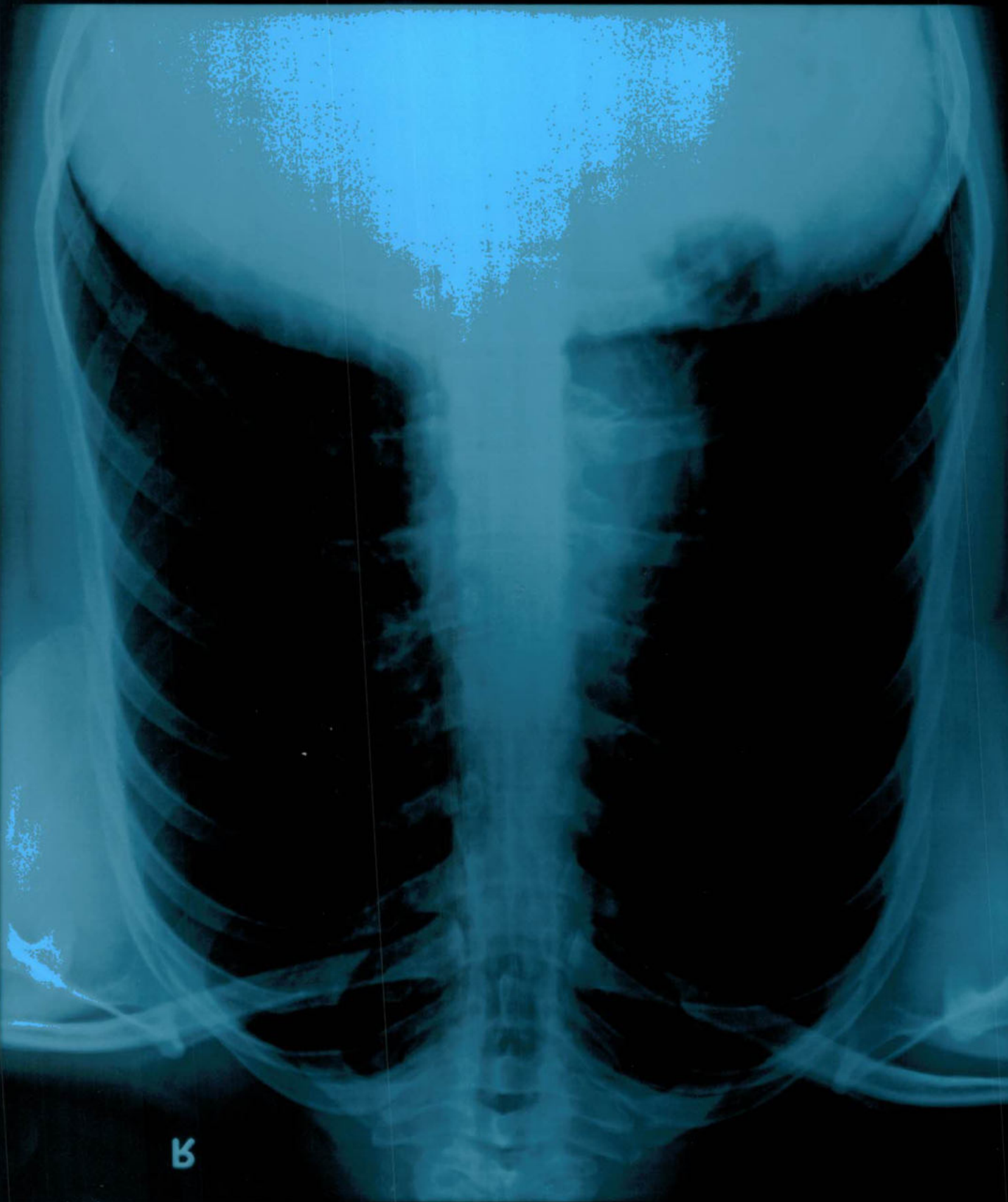
DR. POOJA GARG
RADIOLOGIST
REG NO- DMC/R/03398

Dr. POOJA GARG
M.B.B.S., D.M.R.D.
Reg No. DMC/R/03398
Radiologist

Type By : darshita

47, Harsh Vihar, Pitampura, New Delhi-110034 | Ph.: 011-42480101, 9599913051
E-mail: oneplusul@gmail.com | Web.: www.oneplusul.in

WEI APT2E 32 YR2 25-1-555 M CHEST PA VIEW
OIEPUS UGTR20UID GAV'47-HAP2H VINA'PITAMPURK



B

R

MR AMAN JAIN AGE 35 YRS 22-1-2022 M CHEST PA VIEW
ONEPLUS ULTRASOUND LAB,47-HARSH VIHAR,PITAMPURA