



MEDICOVER HOSPITAL KAKINADA

ADB Road, Near, Achampet Junction,
Kakinada, Andhra Pradesh 533005

0884 237 0777

GST No:

**Bill Of Supply
Corporate OP Bill**

Pt Name : Mr.PINNAM RAMALINGESWARA RAO

Bill No : KKBC90485

UMR NO : KKU44933

Bill Dt : 23-Mar-2024

Age/Sex : 33Y(s)/Male

Phone : 9848928336

These Services Are Under Package

CBP(COMPLETE BLOOD PICTURE)

HBA1C (GLYCOSYLATED HAEMOGLOBIN)

X-RAY CHEST PA VIEW

BUN(BLOOD UREA NITROGEN)

PLBS (POST LUNCH BLOOD GLUCOSE)

ESR

TOTAL PROTEINS A/G RATIO

OPHTHALMOLOGY CONSULTATION

SERUM URIC ACID

TMT

T3,T4 AND TSH

LIPID PROFILE

ECG

LFT(LIVER FUNCTION TEST)

VAMSI KRISHNA KEDARISETTI

BLOOD GROUPING AND RH

SERUM CREATININE

CUE(COMPLETE URINE EXAMINATION)

FBS (FASTING BLOOD GLUCOSE)

2D ECHO WITH COLOUR DOPPLER

USG ABDOMEN

VUTALA PRATHYUSHA

Bill Amt

Receipt Amt

Due Amt

2,450.00

0.00

2,450.00

Create By : 019422

Print By : 019422

Create Dt : 23-Mar-2024 09:15:26 am

Print Dt : 23-Mar-2024 09:15:28 AM

(Authorised Signatory)

24/7 HELPLINE:04068334455

Website:www.medicoverhospitals.in



KKU44

Out Patient Department

Dr. VUTALA PRATHYUSHA
BDS
CONSULTANT DENTIST

UMR No : KKU44933	Name : Mr. PINNAM RAMALINGESWARA RAO
Consultation Date : 23-Mar-2024	Age/Gender : 33 Year(s) / Male
Valid Upto :	Mobile No : 9848928336
Sponsor : ARCOFEMI HEALTHCARE PVT LTD (Visit Type : NORMAL

Cls pt came for dental checkup

Obs- Cal → ++ +
St → ++

Treatment plan: Adv-oral prophylaxis

Height	:	cms
Weight	:	kgs
BMI	:	kg/m2
Temp	:	F
Pulse Rate	:	bpm
Resp.Rate	:	bpm
BP	:	mm of Hg
Pain Score	:	
Nutritional Status	:	



Ind



MEDICOVER
HOSPITALS

A UNIT OF SAHRUDAYA HEALTHCARE (KAKINADA) PVT LTD.

Patient ID:	KKU44933	Patient Name:	PINNAM RAMALINGESWARA RAO
Age:	0 Days	Sex:	M
Accession Number:	KKBC90485	Modality:	US
Referring Physician:	HC	Study:	USG ABDOMEN
Study Date:	23-Mar-2024		

ULTRASOUND WHOLE ABDOMEN

FINDINGS:

LIVER: The liver is normal in size and echotexture. There is no evidence of any focal defect or mass lesion. The intra hepatic vascular biliary channels are normal. The portal vein is normal in course and calibre.

GB,CBD,PANCREAS: The gall bladder, bile duct and pancreas are normal in appearance.

KIDNEYS: Both kidneys are normal in shape, size and echotexture without evidence of any focal defect, mass lesion, hydronephrosis or calculus disease. The renal parenchymal thickness and echogenicity is normal on both sides.

SPLEEN: Spleen is normal in size and echotexture.

LYMPHNODES & ASCITES: There is no nodal enlargement or ascites.

URINARY BLADDER: The urinary bladder is normal in appearance.

PROSTATE: The prostate is normal in appearance.

IMPRESSION:

- NO SIGNIFICANT ABNORMALITY DETECTED.

Kindly correlate clinically

Tejaswi
DR. TEJASWI RAMU
MBBS, MD (RADIOLOGY)

Date: 23-Mar-2024 13:11:07

A UNIT OF SAHRUDAYA HEALTHCARE (KAKINADA) PVT LTD.

Male



Rate 58 . Age not entered, assumed to be 50 years old for purpose of ECG interpretation
 Sinus rhythm.....normal P axis, V-rate 50- 99
 PR 144 . Probable left atrial enlargement.....P >50ms, <-0.10mV V1
 QRS 98 . RSR' in V1 or V2, probably normal variant.....small R' only
 QT 406 . ST elev, probable normal early repol pattern.....ST elevation, age<55
 QTc 399

--AXIS--

P 80

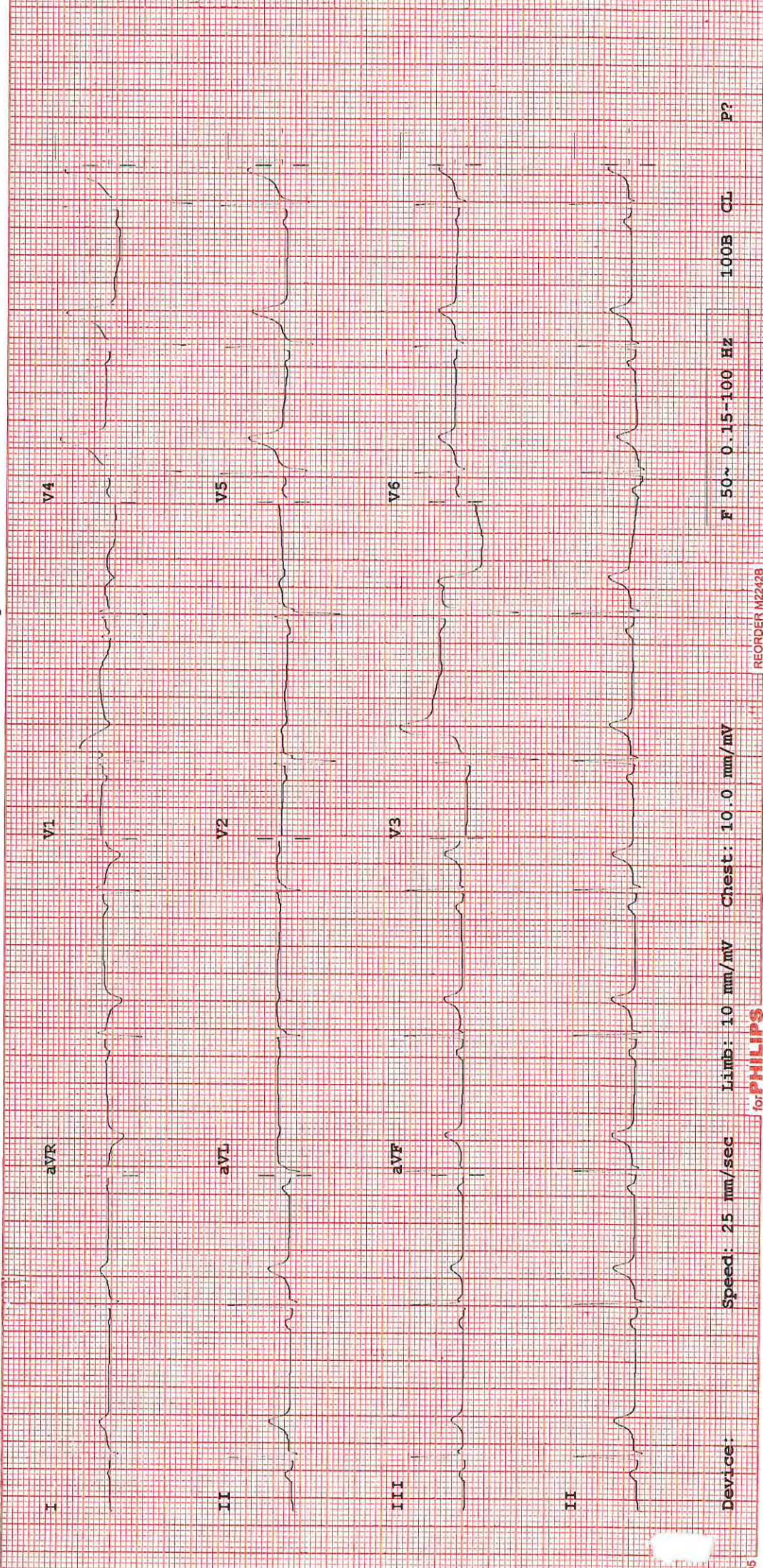
QRS 87

T 63

- BORDERLINE ECG -

12 Lead; Standard Placement

Unconfirmed Diagnosis



Device: Speed: 25 mm/sec Limb: 10 mm/mV Chest: 10.0 mm/mV

F 50~ 0.15-100 Hz

100B CL P?



MEDICOVER HOSPITALS

ADB Road, Near Atchampeta Junction,
Kakinada, Andhra Pradesh 533005.



MEDICOVER
HOSPITALS
KAKINADA

DEPARTMENT OF CARDIOLOGY

Name :	<i>p. Ramalingeswara Rao</i>	Age / Sex :	<i>93/m</i>	Date :	<i>23/3/24</i>
--------	------------------------------	-------------	-------------	--------	----------------

2D ECHO WITH COLOUR DOPPLER

Mitral Valve : |

Aortic Valve : | *Normal*

Pulmonary Valve : |

Tricuspid Valve : |

Left Ventricle : IVSd : *1.1* cm EDD : *4.6* cm EF : *63* %
 Pwd : *1.0* cm ESD : *2.8* cm

Aorta : *2.7* cm

Left Atrium : *3.0* cm

Right Atrium : |

Right Ventricle : |

Pulmonary Artery : |

IAS : | *Normal*

IVS : |

SVC/IVC/CS : |

Pericardium : |

Doppler study : MIF - E...A; AJV...*1.2* m/s; RVSP...*18* +RAP; PJV.....m/s

Other findings :

IMPRESSION :

NO LV RWMA
Normal LV Systolic function
Normal valves
no pe clots



CONSULTANT

Out Patient Department

Dr. VAMSI KRISHNA KEDARISETTI

MBBS, DNB-General Medicine

CONSULTANT GENERAL MEDICINE

UMR No : KKU44933	Name : Mr. PINNAM RAMALINGESWARA RAO
Consultation Date : 23-Mar-2024	Age/Gender : 33 Year(s) / Male
Valid Upto :	Mobile No : 9848928336
Sponsor : ARCOFEMI HEALTHCARE PVT LTD (Visit Type : NORMAL

Height	:	cms
Weight	:	kgs
BMI	:	kg/m2
Temp	:	F
Pulse Rate	:	bpm
Resp.Rate	:	bpm
BP	:	mm of Hg
Pain Score	:	
Natritional Status	:	