

Dr. Vaibhav Agrawal
Consultant- Internal Medicine and Critical Care
MD (Medicine), PGDC, PGDD & RD
Regd. No. - 2008/09/3399

WOCKHARDT
HOSPITALS

LIFE WINS
25/2/22

Mr. Akshay Kumar Ji Kanvate

30y/m

- Came for routine
health CIP

- Body big relative ?

- ↑ urine acid

- best me

Tab Febuxostat 60mg

—————○

x 3 months



WOCKHARDT HOSPITALS, NAGPUR

1643, North Ambazari Road, Nagpur - 440 033. Tel : (0712) 6624444, 6624100

Fax : (0712) 2261266 Website : www.wockhardthospitals.com

Registered Office Address :- Wockhardt Towers, BKC, Bandra (East) Mumbai 400051

CIN: U85100MH1991PLC063096

DEPARTMENT OF PATHOLOGY TEST REPORT

UHID	: WHN2.0000319016	Age/Sex: 29(Y)07(M)15(D)/M	Order Date	: 25-Feb-2022
Name	: Mr AKSHAYKUMAR HARIDAS KAWALE		Order No.	: OPD453488
Ref. Doctor	: WOCKHARDT HOSPITAL			
Con.Doctor	: WOCKHARDT		Report Date	: 25-Feb-2022

BOB ANNUAL HEALTH CHECK FOR MALE

<u>Parameter</u>	<u>Result</u>	<u>Unit</u>	<u>Reference Range</u>
<u>COMPLETE BLOOD COUNT (WITH ESR)</u>			
Haemoglobin, Cell counter	14.9	g%	14-18
Haematocrit, Calculated	45.0	%	37-47
MCV, Calculated	63.8 *	fl	76-96
MCH, Calculated	21.1 *	pg	27-32
MCHC, Calculated	33.1	%	30-35
RDW-CV, Calculated	15.4 *	%	12-15
RBC Count, Cell counter	4.06	Million/ul	4-5
TLC Count, Cell counter	7000	Cells/cumm	4000-11000
Differential Count			
Neutrophil, Cell Counter/Manual	60	%	40-70
Lymphocyte, Cell Counter/Manual	29	%	20-40
Monocyte, Cell Counter/Manual	08	%	2-8
Eosinophil, Cell Counter/Manual	03	%	2-6
Basophil, Cell Counter/Manual	0	%	0-2
Platelet Count, Cell counter	301	Thou/Cumm	150-450
Blood ESR, Westergren's Method	6	mm/hr	0-15

CBC done on 5-part Coulter UniCel DxH 800 haematology analyzer.

ESR done on ALIFAX Roller 20LC ESR analyzer.

* Indicates test value is outside reference range defined. All such values are rechecked.



Dr. ALKA THOOL, MD-PATH
SENIOR PATHOLOGIST

13217 VAISHALI CHALSE
Performed by


WOCKHARDT HOSPITALS, NAGPUR

1643, North Ambazari Road, Nagpur - 440 033. Tel : (0712) 6624444, 6624100

Fax : (0712) 2261266 Website : www.wockhardthospitals.com

Registered Office Address :- Wockhardt Towers , BKC , Bandra (East) Mumbai 400051

CIN: U85100MH1991PLC063096

DEPARTMENT OF PATHOLOGY TEST REPORT

UHID	: WHN2.0000319016	Age/Sex: 29(Y)07(M)15(D)/M	Order Date	: 25-Feb-2022
Name	: Mr AKSHAYKUMAR HARIDAS KAWALE		Order No.	: OPD453488
Ref. Doctor	: WOCKHARDT HOSPITAL			
Con.Doctor	: WOCKHARDT		Report Date	: 25-Feb-2022

BOB ANNUAL HEALTH CHECK FOR MALE

<u>Parameter</u>	<u>Result</u>	<u>Unit</u>	<u>Reference Range</u>
Fasting Blood Sugar, Hexokinase	100	mg/dl	70-115
Urine Sugar (fasting)	Not Detected		
Post Prandial Blood Sugar, Hexokinase	106	mg/dl	100-140
Urine Sugar (post Prandial)	NA		

Note Advised -Fructosamine test (for average blood glucose level)

Dr. ALKA THOOL , MD-PATH
SENIOR PATHOLOGIST

Performed by



WOCKHARDT HOSPITALS, NAGPUR

1643, North Ambazari Road, Nagpur - 440 033. Tel : (0712) 6624444, 6624100

Fax : (0712) 2261266 Website : www.wockhardthospitals.com

Registered Office Address :- Wockhardt Towers , BKC , Bandra (East) Mumbai 400051

CIN: U85100MH1991PLC063096

DEPARTMENT OF PATHOLOGY TEST REPORT

UHID	: WHN2.0000319016	Age/Sex: 29(Y)07(M)15(D)/M	Order Date	: 25-Feb-2022
Name	: Mr AKSHAYKUMAR HARIDAS KAWALE		Order No.	: OPD453488
Ref. Doctor	: WOCKHARDT HOSPITAL			
Con.Doctor	: WOCKHARDT		Report Date	: 25-Feb-2022

BOB ANNUAL HEALTH CHECK FOR MALE

<u>Parameter</u>	<u>Result</u>	<u>Unit</u>	<u>Reference Range</u>
<u>LIPID PROFILE</u>			
Serum Cholesterol, CHOD-PAP	168	mg/dl	1) Desirable Cholesterol Level: <201 2) Borderline Cholesterol: 200-240 3) High Cholesterol: >240
Serum Triglycerides, GPO-PAP	93	mg/dl	70-200
Serum HDL-Cholesterol, Direct Method	38	mg/dl	35-55
Serum VLDL Cholesterol, Calculated	18.60	mg/dl	10-35
Serum LDL Cholesterol, Calculated	111.40	mg/dl	80-130
Serum CHOL/HDL RATIO, Calculated	4.42		1) Low Risk 3.3-4.4 2) Average Risk 4.4-7.1 3) Moderate Risk 7.1-11.0 4) High Risk >11.0

Dr. ALKA THOOL, MD-PATH
SENIOR PATHOLOGIST

Performed by

**WOCKHARDT HOSPITALS, NAGPUR**

1643, North Ambazari Road, Nagpur - 440 033. Tel : (0712) 6624444, 6624100

Fax : (0712) 2261266 Website : www.wockhardthospitals.com

Registered Office Address :- Wockhardt Towers , BKC , Bandra (East) Mumbai 400051

CIN: U85100MH1991PLC063096

DEPARTMENT OF PATHOLOGY TEST REPORT

UHID	: WHN2.0000319016	Age/Sex 29(Y)07(M)15(D)/M	Order Date	: 25-Feb-2022
Name	: Mr AKSHAYKUMAR HARIDAS KAWALE		Order No.	: OPD453488
Ref. Doctor	: WOCKHARDT HOSPITAL			
Con.Doctor	: WOCKHARDT		Report Date	: 25-Feb-2022

BOB ANNUAL HEALTH CHECK FOR MALE

<u>Parameter</u>	<u>Result</u>	<u>Unit</u>	<u>Reference Range</u>
<u>PSA TOTAL</u>			
Serum PSA total, ECLIA	1.03	ng/mL	0-4

Test results cannot be interpreted as absolute evidence for the presence or absence of malignant disease.

Dr. ALKA THOOL , MD-PATH
SENIOR PATHOLOGIST

**WOCKHARDT HOSPITALS, NAGPUR**

1643, North Ambazari Road, Nagpur - 440 033. Tel : (0712) 6624444, 6624100

Fax : (0712) 2261266 Website : www.wockhardthospitals.com

Registered Office Address :- Wockhardt Towers , BKC , Bandra (East) Mumbai 400051

CIN: U85100MH1991PLC063096

DEPARTMENT OF PATHOLOGY TEST REPORT

UHID : WHN2.0000319016 Age/Sex: 29(Y)07(M)15(D)/M Order Date : 25-Feb-2022
Name : Mr AKSHAYKUMAR HARIDAS KAWALE Order No. : OPD453488
Ref. Doctor : WOCKHARDT HOSPITAL
Con.Doctor : WOCKHARDT Report Date : 25-Feb-2022

BOB ANNUAL HEALTH CHECK FOR MALE

<u>Parameter</u>	<u>Result</u>	<u>Unit</u>	<u>Reference Range</u>
Serum Creatinine, Jaffe's Kinetic	0.81	mg/dl	0.7-1.2
Blood Urea Nitrogen, Calculated	8.88	mg/dl	6-20
Serum Uric Acid, Enzymatic	9.02 *	mg/dl	1-7
Serum Total T3, ECLIA	168.5	ng/dL	84.6-201.8
Serum Total T4, ECLIA	13.59	µg/dl	5.13-14.06
Serum TSH, ECLIA	3.46	µIU/mL	0.2-4.2

* Indicates test value is outside reference range defined. All such values are rechecked.

Dr. ALKA THOOL, MD-PATH
SENIOR PATHOLOGIST

Performed by

**WOCKHARDT HOSPITALS, NAGPUR**

1643, North Ambazari Road, Nagpur - 440 033. Tel : (0712) 6624444, 6624100

Fax : (0712) 2261266 Website : www.wockhardthospitals.com

Registered Office Address :- Wockhardt Towers , BKC , Bandra (East) Mumbai 400051

CIN: U85100MH1991PLC063096

DEPARTMENT OF PATHOLOGY TEST REPORT

UHID	: WHN2.0000319016	Age/Sex	: 29(Y)07(M)15(D)/M	Order Date	: 25-Feb-2022
Name	: Mr AKSHAYKUMAR HARIDAS KAWALE	Order No.	: OPD453488		
Ref. Doctor	: WOCKHARDT HOSPITAL				
Con. Doctor	: WOCKHARDT	Report Date	: 25-Feb-2022		

BOB ANNUAL HEALTH CHECK FOR MALE

<u>Parameter</u>	<u>Result</u>	<u>Unit</u>
<u>URINE ROUTINE</u>		
<u>Physical Examination</u>		
Colour	Pale Yellow	
Appearance	Clear	
<u>Urinalysis(Roche UriSys1100)</u>		
Specific Gravity	1.025	
PH	5	
Leukocytes, by urinalyser, calculated	0.00	/hpf
Nitrite, urinalyser	Negative	
Protein, urinalyser	Negative	
Glucose, urinalyser	Normal	
Ketone, urinalyser	Negative	
Urobilinogen, urinalyser	Normal	
Bilirubin, urinalyser	Negative	
Erythrocytes, by urinalyser,calculated	0.00	/hpf

Dr. ALKA THOOL , MD-PATH
SENIOR PATHOLOGIST

2D ECHOCARDIOGRAPHY & COLOUR DOPPLER STUDY

Name : Mr. Akshaykumar Kawale
Done By : Dr. Prajakta Deshmukh
UHID NO. : 319016

Age / Sex: 29 Yrs. / Male
Date : February 25, 2022
OPD

Comments :

Sector echo done in plax, psax, apical 4 & 5 chambers, subcostal view shows:

Normal morphology of aortic, mitral, tricuspid and pulmonary valves.

The left atrium, left ventricle, right atrium and right ventricle are normal in dimension and morphology. There is no regional wall motion abnormality of left ventricle at rest. The left ventricular systolic function is **good**. The global left ventricular ejection fraction is 62 %.

The IAS and IVS are intact.

The pericardium is normal. There is no pericardial effusion.

Aortic root / visualized segment of ascending aorta normal.

Pulmonary arteries normal.

There is no clot or vegetation seen.

CW, PW and Colour Doppler: Transmitral flow is suggestive of normal left ventricular diastolic function. The flow pattern across other cardiac valves is normal. There is no evidence of pulmonary hypertension.

Impression:


Normal cardiac chambers and valves

No regional wall motion abnormality of left ventricle at rest

Good left ventricular systolic function. LVEF – 62 %

Normal LV diastolic function

Good RV systolic function



Dr. Prajakta Deshmukh
MD (Med.), MASE
Sr. Consultant - Non Invasive Cardiologist

Rate 80 . Age not entered, assumed to be 50 years old for purpose of ECG interpretation
 . Sinus rhythm.....normal P axis, V-rate 50- 99
 . Baseline wander in lead(s) V5

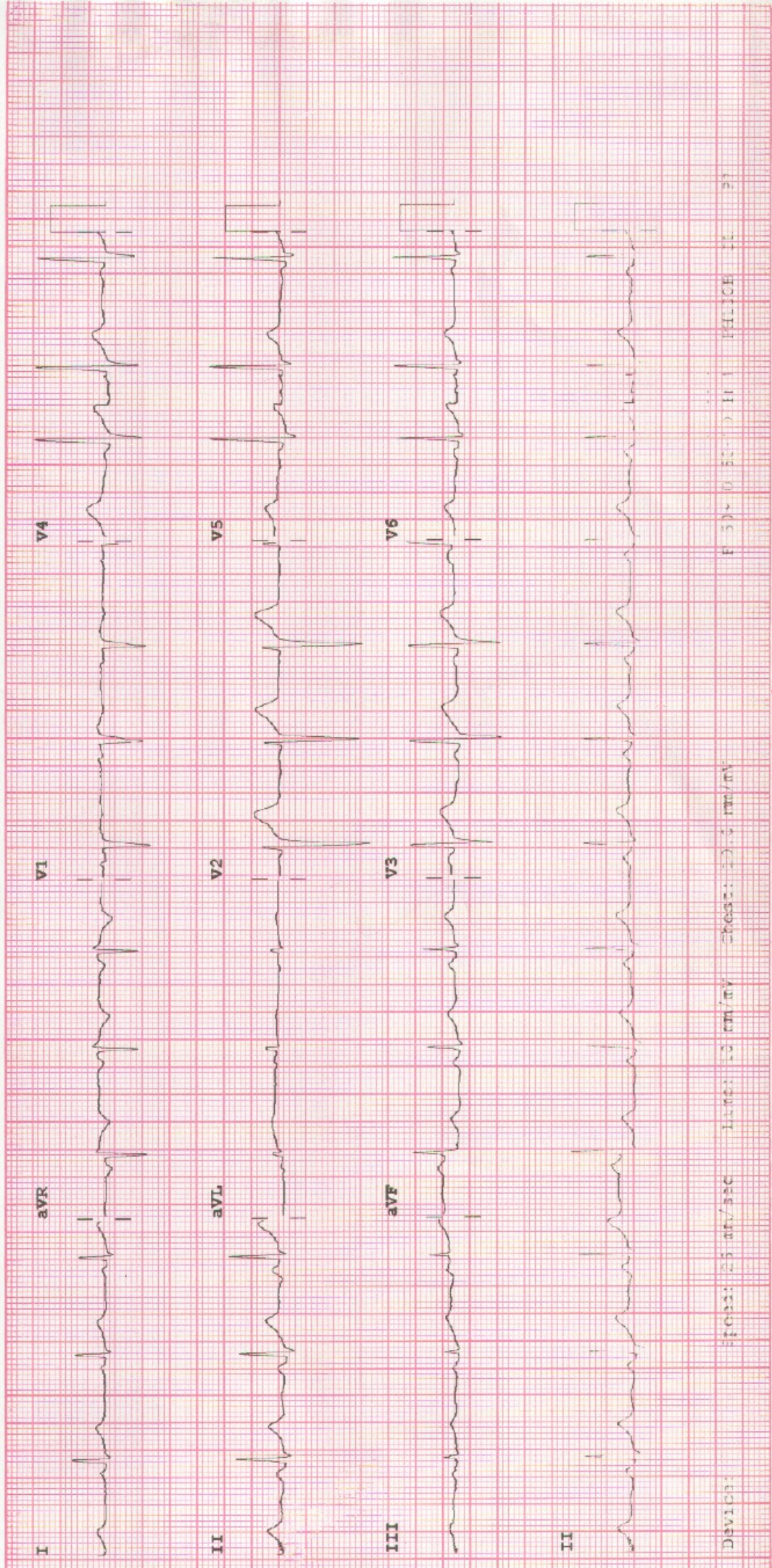
FR 143
 QRSd 85
 QT 366
 QTc 423

--AXIS--
 P 59
 QRS 47
 T 53

12 Lead; Standard Placement

- NORMAL ECG -

Unconfirmed Diagnosis



Speed: 25 mm/sec Paper: 50 mm/5V Date: 25 FEB 2022 Time: 12:08:06 PM

Device: F 50-050-011 Patch: II

Name : *Ashay*

Age/ Sex : yrs /

Date: *25/1/12*

Fundus Examination
(Direct Ophthalmoscopy)

Right

Left

Media

Optic Disc

Colour
Size
Shape
Margin
NRR
C:D

Normal
Reflex
Normal

va (6/6) Normal

Normal

6

Blood Vessels

A:V ratio

Abnormalities

Macula

FR

Abnormalities

Periphery

Impression

Dr. NITIN DHOK
9096377550
Consultant Ophthalmology



WOCKHARDT HOSPITALS, NAGPUR

1643, North Ambazari Road, Nagpur - 440 033. Tel : (0712) 6624444, 6624100

Fax : (0712) 2261266 Website : www.wockhardthospitals.com

Registered Office Address :- Wockhardt Towers , BKC , Bandra (East) Mumbai 400051

CIN: U85100MH1991PLC083096

DEPARTMENT OF RADIOLOGY

UHID : WHN2.0000319016	Age/Sex : 30 Year(s)/M	Order Date : 25-Feb-2022
Name : Mr AKSHAYKUMAR HARIDAS KAWALE		Order No. : OPD453488
Ref. Doctor : WOCKHARDT HOSPITAL		Report Date : 25-Feb-2022

BOB ANNUAL HEALTH CHECK FOR MALE

XR CHEST PA

RADIOLOGICAL OBSERVATION & IMPRESSION :

BILATERAL LUNG FIELDS APPEAR NORMAL.


BOTH CP ANGLES ARE CLEAR.

BILATERAL HILAE & CARDIAC SILHOUTTE APPEAR NORMAL.

BONY CAGE APPEAR NORMAL.

SOFT TISSUES IN VIEW ARE GROSSLY NORMAL.

IMPRESSION: NORMAL STUDY.


Dr. NAYEEM AHMAD KHAN

DMRE
Consultant Radiologist



WOCKHARDT HOSPITALS, NAGPUR

1643, North Ambazari Road, Nagpur - 440 033. Tel : (0712) 6624444, 6624100

Fax : (0712) 2261266 Website : www.wockhardthospitals.com

Registered Office Address :- Wockhardt Towers , BKC , Bandra (East) Mumbai 400051

CIN: U85100MH1991PLC063096

DEPARTMENT OF RADIOLOGY

UHID	: WHN2.0000319016	Age/Sex : 30 Year(s)/M	Order Date	: 25-Feb-2022
Name	: Mr AKSHAY KUMAR HARIDAS KAWALE		Order No.	: OPD453488
Ref. Doctor	: WOCKHARDT HOSPITAL		Report Date	: 25-Feb-2022

BOB ANNUAL HEALTH CHECK FOR MALE**USG UPPER ABDOMEN**

Liver is normal in size shape and echogenicity. No e/o any obvious focal lesion. IHBR not dilated. CBD & PV are normal in caliber.

Gall bladder is well distended and appear clear with normal wall thickness. No e/o sludge or calculus.

Spleen is normal in size shape and echogenicity.

Pancreas is entirely obscured by massive overlying bowel gases.

Right Kidney: 11.2 cm.

Left Kidney : 9.8 cm

Both kidneys normal in size shape and echogenicity. CMD well maintained.

No e/o hydronephrosis or calculus. Ureters are not dilated.

Bowel loops are normally peristaltic. No e/o any wall thickening or mass lesion.

No e/o free fluid or lymphadenopathy.

Both iliac fossae are unremarkable. No e/o any probe tenderness in RIF at present.

Urinary bladder is partially distended and appear clear with normal wall thickness.

Prostate is normal in size shape and echogenicity.

IMPRESSION:**NORMAL ABDOMINAL STUDY.**
Dr. NAYEEM AHMAD KHAN**DMRE**
Consultant Radiologist