



PARKLINE DIAGNOSTICS PVT. LTD.

L.G. 3, 4 & 5, Bhuvana Towers, S.D. Road, Secunderabad - 500 003.

Tel : +91 40-2784 5852, 6649 1787, 7995421787, 7093445852, Fax : +91 40 2784 7864

Email parklinediagnostics@gmail.com www.parklinediagnostics.com



NABL Accredited
Certificate No.MC-2

MEDICAL EXAMINATION REPORT

Name	Mr. Srinivasa Banathu		Date :	14/08/2021	
Company	old: Mediwheel		Reg. No. :	146065	
Contact No.	9542511153		Sex	<input checked="" type="checkbox"/> M	Age : <input type="checkbox"/> 33
Type	Pre-Emp		Emp. No.:	spouse	
	Overseas		Height	154 cm	
	Annual	<input checked="" type="checkbox"/>	Weight	40 kg	
Remarks	- S. ure acid ↑ to reduce proteins intake & follow-up.				
Fitness Status	Medically Fit / Unfit		Dr. K. VIKRAM Physician's Signature Reg.No. 8603		


COMPREHENSIVE MEDICAL EXAMINATION REPORT

NAME Mrs. Dhara Veth Kalpana

AGE 30 yrs.

MARITAL STATUS Married CHILDREN : M F

IDENTIFICATION (IF ANY) A wife



PAST HISTORY

Any family H/o : High Blood Pressure, Heart Disease, Tuberculosis, Diabetes, Asthma, Cancer

Any personal H/o Major illness like : Typhoid.....Jaundice.....Etc.

Any H/o STD.....Skin infection.....

H/o Blood Transfusion.....Recent Vaccination..... Covid 19 - 1st dose - Feb 2022

H/o Epilepsy.....Giddiness.....

H/o Surgery.....Fracture in the past.....

/NIL
/NIL

Any Personal H/O.

High Blood Pressure, Heart Disease Tuberculosis, Diabetes, Asthma, Cancer

Drug Abuse, Drug Allergy, Micturition, Bowels, Alcohol, Smoking, Sleep, MC, Wt. Loss/Wt. Gain

Present illness / Medication Hypothyroidism on 75 Mg/day

GENERAL EXAMINATION

Conjunctiva :

Skin : Hypopigmentation face

Ears :

Nose :

Throat & Oral Cavity :

Bone, Joints : NAD

Nutritional Status : well nourished.

Lymph Nodes : N.P.

Edema Feet :

Varicose Veins : /NIL

Distant Vision : Near Vision :

Right Eye: 6/6
With glasses / Without glasses
left Eye: 6/6 Pterygium (L) Advised surgery
with glasses / without glasses

Right Eye: 7/6
With glasses / Without glasses
left Eye: N6
with glasses / without glasses

Colour Vision: BE normal

DR. KATTA
Ophthalmologist's Signature
Regd: 555 (AMO)

Right Ear

Hearing: within (N) limits
Rinee's Test: +ve
Weber Test: Centralized
Discharge: NO active discharge

Left Ear

e in (N) limits
+ve
Centralized
-do-

D. Hari Krishna Reddy
Dr. D. Hari Krishna Reddy
MS (ENT)
Head & Neck Surgeon
Reg. No: 88379

SYSTEMIC EXAMINATION

Pulse: 72/66 B.P.: 110/74 wbg

Lungs: A. Shape of Chest Bi-l. symmetrical
B. Breath Sounds +
C. Adventitious Sounds NIL

Heart: A. Sounds S¹S²
B. Murmurs NIL

Nervous System

Abdomen: A. Liver INP
B. Spleen
C. Piles NIL
D. Any Lump

A. Higher Function :
B. Cranial Nerves :
C. Sensory System :
D. Motor System : (N)
E. Jerks :


General: A. Hernia
B. Hydrocele NIL
C. Varicocele

Breast: Rt _____ Lt. _____

CANDIDATE'S DECLARATION

I hereby solemnly declare that I am not suffering from Asthma, Hypertension, Diabetes, Occult Psychological disorders or any other ailment which can be suppressed without my voluntary declaration.

Date :


Signature

Place :

Note : General Physical Examination and Investigation included in the health check-up Have certain limitations and may not be able to detect all latent and asymptomatic diseases. Any new symptoms developing after the health check-up or persisting thereafter should be brought to the attention of the treating physician.




PARKLINE DIAGNOSTICS PVT. LTD.

L.G. 3, 4 & 5, Bhuvana Towers, S.D. Road, Secunderabad - 500 003 Tel : +91 40-2784 5852, 6649 1787
Fax : +91 40 2784 7864 Email parklinediagnostics@gmail.com www.parklinediagnostics.com



NABL Accredited
Certificate No. MC-2566

TEST REPORT

Req No. : 446065	Referred By : -
Name : Mr. SRINIVAS BANOTHU [SPOUSE]	Registration Date/Time : 14/08/2021/09:35
R/o : ---	Sampling Date/Time : 14/08/2021/
Age/Sex : 33 Years/Male	Sample : -
Barcode : 	Center : MEDIWHEEL

ULTRA SONOGRAPHY

ULTRA SOUND SCAN OF ABDOMEN*

LIVER : Normal in size and echotexture. No focal lesions.

No IHBD /CBD dilatation. Portal vein is normal in size.

SPLEEN: Normal in size and echotexture. No focal lesion seen.

GALL BLADDER: Well distended. No sludge / gall stones / sol.
Gall bladder -Wall thickness is normal.
No pericholecystic oedema.

PANCREAS : Normal in size and echotexture.No calcification / sol.
Pancreatic duct is normal. No peripancreatic fluid collection.

RIGHT KIDNEY : 8.78 x 4.12 cms.
Normal in size and echotexture.
Cortical thickness is normal.
No evidence of calculi / sol.
Pelvi calyceal system is normal.


LEFT KIDNEY : 8.75 x 4.48 cms.
Normal in size and echotexture.
Cortical thickness is normal.
No evidence of calculi / sol.
Pelvi calyceal system is normal.

URINARY BLADDER : Well distended. Normal in contour.
Wall thickness is normal. No calculus / sol.

PROSTATE : Normal in size and echotexture.
No calcification / sol.
No pre or para aortic adenopathy / ascites noted.

IMPRESSION : Normal Study.

Clinical correlation.


Dr. D.J. MOHAN
MD DMRD
(Reg No. 8995)
Consultant Radiologist

****End of Report****

Printed on : 14/08/2021 / 10.46

The Test marked with *are not accredited by NABL

Lab Timings (Weekdays) : 7.00 am to 8.30 pm

Sundays & Holidays : 7.00 am to 1.00 pm

Radiologists Timings(Weekdays) : 7.30 am to 1.30 pm
& 5.30 pm to 7.30 pm

Sundays & Holidays : 7.30 am to 9.30 am

Page No. 1



PARKLINE DIAGNOSTICS PVT. LTD.


L.G. 3, 4 & 5, Bhuvana Towers, S.D. Road, Secunderabad - 500 003 Tel :+91 40-2784 5852, 6649 1787

Fax : +91 40 2784 7864 Email parklinediagnostics@gmail.com www.parklinediagnostics.com



NABL Accredited
Certificate No.MC-2566

TEST REPORT

Req.No : 446065
Name : Mr. SRINIVAS BANOTHU [SPOUSE]
R/O : --
Age / Sex : 33 Years / Male
Bar Code : 

Referred By : SELF
Req Date/Time : 14/08/2021 /09:35
Sampling Date/Time : 14/08/2021 /11:00
Sample : -
Centre : MEDIWHEEL

CARDIOLOGY

TEST(Methodology)	RESULT
Mitral Valve	Normal
Aortic valve	Normal
Tricuspid valve	Normal
Pulmonary valve	Normal
Aorta	2.90 cm
Left Atrium	3.16 cm
Left Ventricle	LVDd: 4.26 cm IVSd : 1.0 cm EF: 58 % LVDs: 2.98 cm LVPwd: 1.0 cm FS: 30 %
RWMA	Nil
Right Atrium	Normal
Right Ventricle	Normal
Pulmonary Artery	Normal
IAS	Intact
IVS	Intact
Pericardium	Normal
Svc / Ivc	Normal
Intracardiac Masses	Nil
Doppler Study	Mitral flow: E: 0.69 m/sec A: 0.4 m/sec E/A ratio : 1.5 Aortic flow : 1.0 m/sec Pulmonary flow : 0.60 m/sec No MR / AR / TR / PR.
Colour Doppler	No RWMA.
CONCLUSION	Normal valves/ Normal chambers. No MR/ AR/ TR /PR. Good LV/ RV function. No PE/ clot/ vegetation.

MEDIWHEEL MALE 30 YRS AND BELOW

**** END OF REPORT ****

Reported on : 14/08/2021 / 11:01

Printed on : 14/08/2021 / 11:01

The Test marked with *are not accredited by NABL

Lab Timings (Weekdays) : 7.00 am to 8.30 pm

Sundays & Holidays : 7.00 am to 1.00 pm

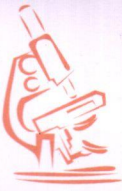Radiologists Timings (Weekdays): 7.30 am to 1.30 pm

Sundays & Holidays

& 5.30 pm to 7.30 pm

: 7.30 am to 9.30 am

Dr PANDURANGA
MD., DM
Consultant Interventional Cardiologist
Reg No: 73MC/FMR/00054




PARKLINE DIAGNOSTICS PVT. LTD.

L.G. 3, 4 & 5, Bhuvana Towers, S.D. Road, Secunderabad - 500 003 Tel : +91 40-2784 5852, 6649 1787
Fax : +91 40 2784 7864 Email parklinediagnostics@gmail.com www.parklinediagnostics.com



NABL Accredited
Certificate No.MC-256

TEST REPORT

Req No. : 446065
Name : Mr.SRINIVAS BANOTHU [SPOUSE]
R/o : ---
Age/Sex : 33 Years/Male
Barcode : 

Referred By : -
Registration Date/Time : 14/08/2021/09:35
Sampling Date/Time : 14/08/2021/
Sample : -
Center : MEDIWHEEL

RADIOLOGY

X-RAY CHEST PA VIEW*

Lung fields are clear.

Cardia is normal.


Hila are normal.

C P angles are free.

Bony cage is normal.

Soft tissues are normal.

IMPRESSION : NORMAL CHEST X-RAY.


DR. PRAJAKTA SUKHADEV
DNB RADIOLOGY
Reg. No. 68493

****End of Report****

Printed on : 14/08/2021 / 12.38

The Test marked with *are not accredited by NABL

Lab Timings (Weekdays) : 7.00 am to 8.30 pm

Sundays & Holidays : 7.00 am to 1.00 pm

Radiologists Timings(Weekdays) : 7.30 am to 1.30 pm

Sundays & Holidays

& 5.30 pm to 7.30 pm

: 7.30 am to 9.30 am

Free Home Visit for Sample Collection.

Call : 7995421787, 7093445852, 8121147282, 9885202212

Page No. 1

ID: 446065 14-08-2021 10:32:11 AM
MR.SRINIVAS BANOTHU
Male 33Years

CARDIART

HR : 59 bpm
P : 112 ms
PR : 159 ms
QRS : 83 ms
QT/QTc : 372/371 ms
P/QRS/T : 54/82/37 °
RV5/SV1 : 1.322/0.801 mV

Diagnosis Information
~~Virus Brachycardia~~
~~Slight ST elevation (V1)~~

*co-lead
with lead
V1*

Dr PANDURANGA
MD., DM

Consultant Interventional Cardiologist
Reg No TSMC/FMR/09054

Report Confirmed by: