

NAME : Amruta Agrawal AGE/SEX: 23/F YEARS/feet -
 DATE : 16/03/2024 REFERRED BY: medi

PERSONAL HISTORY:

Sleep	Disturbed / Sound <input checked="" type="checkbox"/>	Acidity	<u>Occasionally</u>
Appetite	Good / Reduced / Increased	Exercise	<u>NO</u>
Micturition	Burning / Normal <input checked="" type="checkbox"/>	Diet	<u>veg</u>
Bowel Movement	Regular / Irregular / Constipation	Marital Status	<u>Unmarried</u>
Water Intake	<u>2-3 liter</u>		

PAST HISTORY:

Any allergies	<u>NO</u>	Coronary Heart Disease	<u>NO</u>
Hypertension	<u>NO</u>	Any Operations/ Surgery	<u>NO</u>
Diabetes	<u>NO</u>	Treatment/Medication History	<u>NO</u>
Tuberculosis	<u>NO</u>	Hospitalization	<u>NO</u>

SOCIAL HISTORY:-

Drinking	<u>NO</u>
Smoking	<u>NO</u>

FAMILY HISTORY:

RELATIONSHIP	ALIVE/NOT ALIVE	IF ALIVE GIVE PRESENT STATE OF HEALTH/ IF NOT ALIVE SPECIFY CAUSE OF DEATH
Father	<u>Alive</u>	<u>H/O diabetes</u>
Mother	<u>Alive</u>	<u>Healthy</u>
Sister	<u>Alive</u>	<u>Healthy</u>
Brother	<u>Alive</u>	<u>Healthy</u>
Wife/Husband	<u>NO</u>	<u>NO</u>
Children	<u>NO</u>	<u>NO</u>

FEMALE PATIENTS

Frequency & Regularity of Periods Regular Any Children Unmarried
 Contraception NO Full Term / Pre mature NO
 Pregnancy / Miscarriage / Termination NO L.M.P. 23/02/2024

PHYSICAL EXAMINATION:

Hydration <u>Normal</u>	Joint swelling / Deformity	Nicotine Stains
Palms	Cyanosis / clubbing	Pallor <u>NO</u>
Osler's nodes	Palpation of lymph nodes	Icterus <u>NO</u>
Palmar erythema	Edema <u>NO</u>	
Yellow Skin	Pitting	
	Non Pitting	
	Dependent	

VITAL SIGNS:-

Temperature 98.1 Basic Measurements
 Respiratory Rate 20 Height 149 cm
 Pulse rate / rhythm 100/min Weight 64.7 kg
 Blood Pressure 110/80 mmHg BMI 29.1

ABDOMINAL EXAMINATION: No Hepatosplenomegaly, No Tenderness.

Inspection	Spleen
Palpation	Other
Liver	Tenderness

NERVOUS SYSTEM: All reflexes and cranial nerves are normal. No sensory / motor deficit detected.

Reflexes	Sensory Nerve
Cranial Nerve	Motor System
Sensory Nerve	Others

MUSCULO SKELETAL SYSTEM: No evident abnormality detected. All movements are normal.

Extremities	
Movements	

CARDIO VASCULAR SYSTEM: Heart Sounds Normal. No other abnormality detected.

HEART SOUNDS:-

Heart Sound 1	Murmur
Heart Sound 2	Other Findings

RESPIRATORY SYSTEM: Air entry normal and equal on both sides. No added sounds or other abnormality detected.

Inspection of Thorax	Breathing
Auscultation	Added Sounds
Air Entry	Other Findings

SUGGESTIONS:

CBC - Reaction lymphocytes
present otherwise (M/C)

USG → Uterine fibroid +
Polycystic ovarian changes in both
ovaries
other reports normal

RECOMMENDATION:-

Dr. Name: _____


DR (MRS) GANESH SINGH
M.M.C. REG. NO. 44217
Mansha Healthcare & Research Pvt. Ltd.

CONSENT FORM

Date 16/03/2024

To Whomsoever it may concern

This is inform that Pap Smear test
Amruta Agrawal

was not conducted for

Mr/Mrs./Miss Amruta Agrawal

Reason Not Physically Active Pap Smear
Test

Dr. DR. RAJESH KUMAR SINGH
MBBS DGO
MMC REG. NO 49217
Neesha Healthcare & Research Pvt. Ltd

Agrawal
Patient sign.



भारत सरकार
Government of India

भारतीय विशिष्ट पहचान प्राधिकरण
Unique Identification Authority of India

सामांजन क्रम/ Enrolment No.: 0653/34172/00329

To

अमृता संजय अग्रवाल

Amruta Sanjay Agrawal

Flat Number-02 Siddhivwas

Sr Number-222/ 1/ 1 Plot Number-55

Near Shantidham Apartment


Ambad

Nashik

Nashik Maharashtra - 422010

7066480130

Signature has verified



आपका आधार क्रमांक / Your Aadhaar No. :

5942 8897 6935

VID : 9169 3356 0163 3215

मेरा आधार, मेरी पहचान



भारत सरकार
Government of India



अमृता संजय अग्रवाल

Amruta Sanjay Agrawal

जन्म तिथि/DOB: 14/02/2001

लिंग/ GENDER: FEMALE

M. Agrawal

5942 8897 6935

VID : 9169 3356 0163 3215

मेरा आधार, मेरी पहचान



Government of India



सूचना

- आधार पदचान का प्रमाण है, नागरिकता का नहीं।
- सुरक्षित QR कोड / ऑफलाइन XML / ऑनलाइन ऑथेंटिकेशन से पदचान प्रमाणित करे।
- यह एक इलेक्ट्रॉनिक प्रक्रिया द्वारा बना हुआ पत्र है।

INFORMATION

- Aadhaar is a proof of identity, not of citizenship.
- Verify identity using Secure QR Code/ Offline XML/ Online Authentication.
- This is electronically generated letter.

- आधार देश भर में मान्य है।
- आधार कई सरकारी और गैर सरकारी सेवाओं को पाना आसान बनाता है।
- आधार में मोबाइल नंबर और ईमेल ID अपडेट रखें।
- आधार को अपने स्मार्ट फोन पर रखें, mAadhaar App के साथ।

- Aadhaar is valid throughout the country.
- Aadhaar helps you avail various Government and non-Government services easily.
- Keep your mobile number & email ID updated in Aadhaar.
- Carry Aadhaar in your smart phone – use mAadhaar App.



भारतीय विशिष्ट पहचान प्राधिकरण
Unique Identification Authority of India



पता:

फ्लैट नंबर-02 सिद्धिववास, स. नंबर-222/ 1/ 1 प्लॉट

नंबर-55, शांतिधाम अपार्टमेंट जवाब, अम्बड, नाशिक,

महाराष्ट्र,

महाराष्ट्र - 422010

Address:

Flat Number-02 Siddhivwas, Sr Number-222/

1/ 1 Plot Number-55, Near Shantidham

Apartment, Ambad, Nashik, Nashik,

Maharashtra - 422010



5942 8897 6935

VID : 9169 3356 0163 3215

1947 | help@uidai.gov.in | www.uidai.gov.in

ID: 43029
AMRUTA AGRAWAL
Female 23Years
149cm 64kg

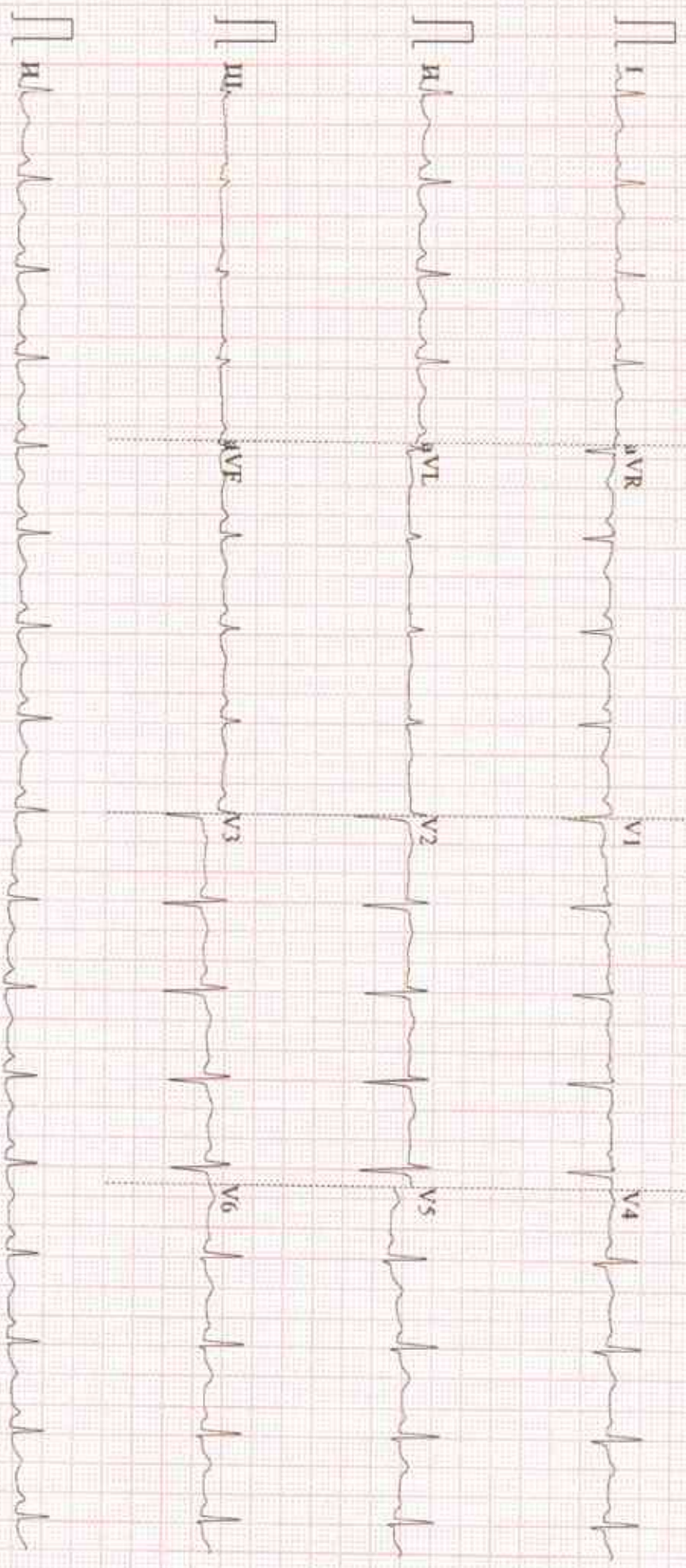
HR	: 100	bpm
P	: 101	ms
PR	: 144	ms
QRS	: 76	ms
QT/QTc	: 324/418	ms
P/QRS/T	: 64/46/48	°
RV5/SV1	: 0.66/1.0.688	mV

Diagnosis Information:
Sinus Rhythm
Normal ECG

Amruta Agrawal
Normal ECG

Report Confirmed by:

[Signature]





MEESHA
 DIAGNOSTICS AND POLYCLINIC

Branch :

Ground Floor, 12-C, Moti Mahal, C.S. No. 1631, Churchgate, Mumbai-400 020.
 Tel. : +91 22 3574 1977 / 93241 87465 / 77100 84304

NAME:- Amrutesh Agrewal
DATE:-
REFERRED BY:- 16/3/24
 kel

REF No. :-
AGE/SEX:- 23 / f

EYE CHECKUP

HISTORY OF EYE RELATED COMPLAINTS: no ocular complaints

HISTORY OF SYSTEMIC ILLNESS :

EXAMINATION		RIGHT	LEFT
Distance vision	Without correction	6/6 (P)	6/6
	With correction	-	-
Near Vision	Without correction	NG	NG
	With correction	-	-
ANTERIOR SEGMENT		Co clear	Co clear
LENS		WNL	WNL
POSTERIOR SEGMENT		WNL	WNL
ROPLAS		WNL	WNL
TENSION		10 mmHg	10 mmHg
COLOR VISION		MAN (MAN)
DAIGNOSIS		(R)	

ADVICE : (R) glasses
 Systemic Hypertension & Diabetes

	RIGHT				LEFT			
	SPH	CYL	AXIS	Vn	SPH	CYL	AXIS	Vn
DISTANCE	-	-0.50	10°	6/6	-	-0.50	10°	6/6
NEAR	-	-	-	-	-	-	-	-

CONCLUSION:

h
DR. SMITA DIXIT
DOMS.FC PS (OPHTHALMOLOGY)

Branch :

Ground Floor, 12-C, Moti Mahal, C.S. No. 1631, Churchgate, Mumbai-400 020.
Tel. : +91 22 3574 1977 / 93241 87465 / 77100 84304

LAB REPORT

Printed Date: 2024-03-16 06:40 PM

Patient Id	: 43029	Patient Name	: Miss AMRUTA AGRAWAL	Treatmentid	: 19411
Age/Gender	: 23Y/Female	Mobile No	: 7066480130	Ref. By	:
Registered On	: 16-03-2024 08:12 AM	Collected On	: 16-03-2024 08:20 AM	Reported On	: 16-03-2024 06:39 PM
Nationality	: Indian	Patient Type	: Sponsor	Sponsor Name	: MediWheel(Arcotem Healthcare Pvt. Ltd.)


CBC (COMPLETE BLOOD COUNT)

<u>Test Name</u>	<u>Test Result</u>	<u>Normal Values</u>	<u>Unit</u>
Haemoglobin	14.0	12 - 15	g/dl
R.B.C. Count	4.68	3.8 - 4.8	mill/cumm
Hematocrit(PCV)	40.7	36 - 46	%
M.C.V.	86.97	83 - 101	fl
M.C.H.	29.91	27 - 32	pg
M.C.H.C.	34.40	31 - 35	g/dl
RDW-CV	14.5 H	11.5 - 14	%
RDW-SD	48.1		
Platelet Count	278000	150000 - 400000	/cumm
Platelet On Smear	Adequate		
TOTAL WHITE BLOOD CELLS	8800	4000 - 10500	/cumm
Neutrophils	70	40 - 70	%
Band cells	00	0 - 10	%
Eosinophils	02	1 - 6	%
Lymphocytes	25	20 - 40	%
Monocytes	03	2 - 10	%
Basophils	00	0 - 02	%
R.B.C. Morphology	Normocytic Normochromic		
W.B.C Morphology	Reactive Lymphocytes are seen		
Parasite	-		
Comment	-		

Equipment: CELL COUNTER ERBA H 360

--End Of Report--


Priyanka Sharma
(Technician Name)


Dr. Tabassum Shaikh
MBBS, MD (Pathology)
Consultant Pathologist
Reg No.2016083587

1st Floor, La View, B. J. Marg, Jacob Circle, Mahalaxmi, Mumbai-400 011.
Tel. : +91 22 2305 3534 / 36 / 77100 84305 / 3511 5146
info@meeshahealth.net | www.meeshahealth.net



Branch :

Ground Floor, 12-C, Moti Mahal, C.S. No. 1631, Churchgate, Mumbai-400 020.
Tel. : +91 22 3574 1977 / 93241 87485 / 77100 84304

LAB REPORT

Printed Date: 2024-03-16 06:40 PM


Patient Id	: 43029	Patient Name	: Miss-AMRUTA AGRAWAL	TreatmentId	: 19431
Age/Gender	: 23Y/Female	Mobile No	: 7066480130	Ref. By	:
Registered On	: 16-03-2024 08:12 AM	Collected On	: 16-03-2024 08:20 AM	Reported On	: 16-03-2024 06:39 PM
Nationality	: Indian	Patient Type	: Sponsor	Sponsor Name	: MediWheel(Arcofem Healthcare Pvt. Ltd.)

ESR (Erythrocyte Sedimentation Rate)

<u>Test Name</u>	<u>Test Result</u>	<u>Normal Values</u>	<u>Unit</u>
ESR	61 H	0 - 20	mm/hr

--End Of Report--


Priyanka Sharma
(Technician Name)


Dr. Tabassum Shaikh
MBBS,MD (Pathology)
Consultant Pathologist
Reg No.2016083567



MEESHA
DIAGNOSTIC AND POLYCLINIC

Branch :

Ground Floor, 12-C, Moti Mahal, C.S. No. 1631, Churchgate, Mumbai-400 020.
Tel. : +91 22 3674 1977 / 93241 87465 / 77100 84304

LAB REPORT

Printed Date: 2024-03-16 06:40 PM

Patient Id	: 43029	Patient Name	: Miss AMRUTA AGRAWAL	TreatmentId	: 19431
Age/Gender	: 23Y/Female	Mobile No	: 7086480130	Ref. By	:
Registered On	: 16-03-2024 08:12 AM	Collected On	: 16-03-2024 08:20 AM	Reported On	: 16-03-2024 06:39 PM
Nationality	: Indian	Patient Type	: Sponsor	Sponsor Name	: MediWheel(Arcofem) Healthcare Pvt. Ltd.)


BLOOD GROUP AND Rh TYPING

<u>Test Name</u>	<u>Test Result</u>
Blood Group	B
Rh Factor (D)	Positive

Interpretation: -1. Agglutination is a positive result and indicates the presence of A, B or D (Rho) Antigen
2. No agglutination is a negative result and indicates the absence of A, B or D (Rho) Antigen

--End Of Report--


Priyanka Sharma
(Technician Name)


Dr Tabassum Shaikh
MBBS,MD (Pathology)
Consultant Pathologist
Reg No.2018083587



MEESHA
DIAGNOSTICS AND POLYCLINIC

Branch :

Ground Floor, 12-C, Moti Mahal, C.S. No. 1631, Churchgate, Mumbai-400 020.
Tel. : +91 22 3574 1977 / 93241 87465 / 77100 84304

LAB REPORT

Printed Date: 2024-03-16 06:40 PM

Patient Id : 43029	Patient Name : Miss AMRUTA AGRAWAL	TreatmentId : 19431
Age/Gender : 23Y/Female	Mobile No : 7066480130	Ref. By :
Registered On : 16-03-2024 08:12 AM	Collected On : 16-03-2024 08:20 AM	Reported On : 16-03-2024 06:39 PM
Nationality : Indian	Patient Type : Sponsor	Sponsor Name : MediWheel(Arcotemi Healthcare Pvt. Ltd.)

BSF

<u>Test Name</u>	<u>Test Result</u>	<u>Normal Values</u>	<u>Unit</u>
Blood Sugar (F)	80	70 - 110	mg/dl

Equipment: ERBA-EM 200 FULLY AUTOMATED CLINICAL CHEMISTRY ANALYSER.

--End Of Report--

Priyanka Sharma
(Technician Name)

Dr Tabassum Shaikh
MBBS,MD (Pathology)
Consultant Pathologist
Reg No.2016083597



Branch :

Ground Floor, 12-C, Moti Mahal, C.S. No. 1631, Churchgate, Mumbai-400 020.
Tel. : +91 22 3574 1977 / 93241 87465 / 77100 84304

LAB REPORT

Printed Date: 2024-03-16 06:40 PM

Patient Id : 43029	Patient Name : Miss AMRUTA AGRAWAL	TreatmentId : 19431
Age/Gender : 23Y/Female	Mobile No : 7066480130	Ref. By :
Registered On : 16-03-2024 08:12 AM	Collected On : 16-03-2024 08:20 AM	Reported On : 16-03-2024 06:30 PM
Nationality : Indian	Patient Type : Sponsor	Sponsor Name : MediWise(Arcotem) Healthcare Pvt. Ltd.

HbA1c (GLYCOSYLATED HAEMOGLOBIN)

<u>Test Name</u>	<u>Test Result</u>	<u>Normal Values</u>	<u>Unit</u>
GLYCOSYLATED HAEMOGLOBIN(HbA1c)	5.7	4.6 - 6.2	%
MEAN PLASMA GLUCOSE	118.89	0 - 154	mg/dl

Interpretation: 6.2 - 7.0 %----- Near Normal Glycemia
7.0 - 8.0 %----- Fair Control
8.0 - 10.0 %----- Unsatisfactory Control
Above 10.0 %----- Poor control

TRACIBILITY :

The method has been certified by the National Glycohaemoglobin Standardization Program

CLINICAL SIGNIFICANCE :

HbA1c is a glycated form of haemoglobin formed by the attachment of glucose residues in the blood to the haemoglobin molecules. The level of HbA1c is proportional to the level of glucose in the blood & has been widely accepted as an indicator of the mean blood glucose concentration in the preceding 6-8 weeks. It is therefore a long term indicator of diabetic control. For routine use HbA1c levels should be monitored every 3-4 months.

Equipment: mispa-i2

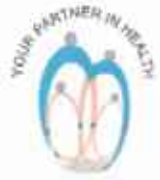--End Of Report--

Priyanka Sharma
(Technician Name)

Dr Tabassum Shaikh
MBBS,MD (Pathology)
Consultant Pathologist
Reg No.2016083587

ISO : 9001:2015 Certified

Right Diagnosis, Right Treatment, Right Place



MEESHA
DIAGNOSTICS AND POLYCLINIC

Branch :

Ground Floor, 12-C, Moti Mahal, C.S. No. 1631, Churchgate, Mumbai-400 020.
Tel. : +91 22 3574 1977 / 93241 87465 / 77100 84304

LAB REPORT

Printed Date: 2024-03-16 06:40 PM

Patient Id : 43029	Patient Name : Miss AMRUTA AGRAWAL	TreatmentId : 19431
Age/Gender : 23Y/Female	Mobile No : 7066480130	Ref. By
Registered On : 16-03-2024 08:12 AM	Collected On : 16-03-2024 08:20 AM	Reported On : 16-03-2024 06:30 PM
Nationality : Indian	Patient Type : Sponsor	Sponsor Name : MediWheel(Arcofemi Healthcare Pvt. Ltd.)

LIPID PROFILE

<u>Test Name</u>	<u>Test Result</u>	<u>Normal Values</u>	<u>Unit</u>
Serum Cholesterol Total	147	140 - 250	mg/dl
Serum HDL Cholesterol	40.0	30 - 70	mg/dl
Serum Triglycerides	90.2	0 - 165	mg/dl
Serum LDL Cholesterol	88.96	85 - 130	mg/dl
Serum VLDL Cholesterol	18.04	0 - 40	mg/dl
LDL - HDL Ratio	2.22	0 - 100	ug/dl

Equipment: ERBA-EM 200 FULLY AUTOMATED CLINICAL CHEMISTRY ANALYSER.

--End Of Report--

Priyanka Sharma
(Technician Name)

Dr Tabassum Shaikh
MBBS,MD (Pathology)
Consultant Pathologist
Reg No.2016083587

Branch :

Ground Floor, 12-C, Moti Mahal, C.S. No. 1631, Churchgate, Mumbai-400 020.
Tel. : +91 22 3574 1977 / 93241 87465 / 77100 84304

LAB REPORT

Printed Date: 2024-03-16 06:40 PM

Patient Id : 43029	Patient Name : Miss AMRUTA AGRAWAL	Treatmentid : 19431
Age/Gender : 23Y/Female	Mobile No : 7066480130	Ref. By :
Registered On : 16-03-2024 08:12 AM	Collected On : 16-03-2024 08:20 AM	Reported On : 16-03-2024 06:39 PM
Nationality : Indian	Patient Type : Sponsor	Sponsor Name : MediWheel (Ancoletia Healthcare Pvt. Ltd.)


BUN

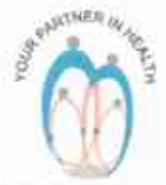<u>Test Name</u>	<u>Test Result</u>	<u>Normal Values</u>	<u>Unit</u>
Serum BUN	07	0 - 20	mg/dl

Equipment: ERBA-EM 200 FULLY AUTOMATED CLINICAL CHEMISTRY ANALYSER.

--End Of Report--


Priyanka Sharma
(Technician Name)


Dr. Tabassum Shaikh
MBBS, MD (Pathology)
Consultant Pathologist
Reg No. 2016083587



MEESHA
DIAGNOSTICS AND POSTCARE

Branch :

Ground Floor, 12-C, Moti Mahal, C.S. No. 1631, Churchgate, Mumbai-400 020.
Tel. : +91 22 3674 1977 / 93241 87465 / 77100 84304

LAB REPORT

Printed Date: 2024-03-16 06:40 PM

Patient Id	: 43029	Patient Name	: Miss AMRUTA AGRAWAL	TreatmentId	: 19431
Age/Gender	: 23Y/Female	Mobile No	: 7066480130	Ref. By	:
Registered On	: 16-03-2024 08:12 AM	Collected On	: 16-03-2024 08:20 AM	Reported On	: 16-03-2024 06:39 PM
Nationality	: Indian	Patient Type	: Sponsor	Sponsor Name	: MediWheel(Arcotemi Healthcare Pvt. Ltd.)

CREATININE

<u>Test Name</u>	<u>Test Result</u>	<u>Normal Values</u>	<u>Unit</u>
Serum Creatinine	0.65	0.6 - 1.3	mg/dl

Equipment: ERBA-EM 200 FULLY AUTOMATED CLINICAL CHEMISTRY ANALYSER.

--End Of Report--

Priyanka Sharma
(Technician Name)

Dr Tabassum Shaikh
MBBS,MD (Pathology)
Consultant Pathologist
Reg No.2016083567



MEESHA
DIAGNOSTIC AND POLYCLINIC

Branch :

Ground Floor, 12-C, Moti Mahal, C.S. No. 1631, Churchgate, Mumbai-400 020,
Tel. : +91 22 3574 1977 / 93241 87465 / 77100 84304

LAB REPORT

Printed Date: 2024-03-16 06:40 PM

Patient Id : 43029	Patient Name : Miss AMRUTA AGRAWAL	Treatmentid : 19431
Age/Gender : 23Y/Female	Mobile No : 7066480130	Ref. By :
Registered On : 16-03-2024 08:12 AM	Collected On : 16-03-2024 08:20 AM	Reported On : 16-03-2024 06:30 PM
Nationality : Indian	Patient Type : Sponsor	Sponsor Name : MediWheel(Arcotem Healthcare Pvt. Ltd.)


BUN /CREATININE RATIO

<u>Test Name</u>	<u>Test Result</u>	<u>Normal Values</u>	<u>Unit</u>
Serum BUN	07	0 - 20	mg/dl
Serum Creatinine	0.65	0.6 - 1.3	mg/dl
BUN / Creat Ratio	10.77 L	30 - 40	/cummm

Equipment: ERBA-EM 200 FULLY AUTOMATED CLINICAL CHEMISTRY ANALYSER.

--End Of Report--


Priyanka Sharma
(Technician Name)


Dr. Tabassum Shaikh
MBBS,MD (Pathology)
Consultant Pathologist
Reg No. 2016083507



MEESHA
DIAGNOSTICS AND POLYCLINIC

Branch :

Ground Floor, 12-C, Moti Mahal, C.S. No. 1631, Churchgate, Mumbai-400 020.
Tel. : +91 22 3574 1977 / 93241 87465 / 77100 84304

LAB REPORT

Printed Date: 2024-03-16 06:40 PM

Patient Id	: 43029	Patient Name	: Miss AMRUTA AGRAWAL	TreatmentId	: 19431
Age/Gender	: 23Y/Female	Mobile No	: 7066480130	Ref. By	:
Registered On	: 16-03-2024 08:12 AM	Collected On	: 16-03-2024 08:20 AM	Reported On	: 16-03-2024 06:30 PM
Nationality	: Indian	Patient Type	: Sponsor	Sponsor Name	: MediWheel(Arcotem) Healthcare Pvt. Ltd.

URIC ACID SERUM

<u>Test Name</u>	<u>Test Result</u>	<u>Normal Values</u>	<u>Unit</u>
Serum Uric Acid	3.8	2.5 - 6.8	mg/dl

Equipment: ERBA-EM 200 FULLY AUTOMATED CLINICAL CHEMISTRY ANALYSER.

--End Of Report--

Priyanka Sharma
(Technician Name)

Dr. Tabassum Shaikh
MBBS, MD (Pathology)
Consultant Pathologist
Reg No.2016083587

ISO : 9001:2015 Certified

Right Diagnosis, Right Treatment, Right Place



MEESHA
DIAGNOSTIC AND POLYCLINIC

Branch :

Ground Floor, 12-C, Moti Mahal, C.S. No. 1631, Churchgate, Mumbai-400 020.
Tel. : +91 22 3574 1977 / 93241 87465 / 77100 84304

LAB REPORT

Printed Date: 2024-03-16 06:40 PM

Patient Id	: 43029	Patient Name	: Miss AMRUTA AGRAWAL	TreatmentId	: 19431
Age/Gender	: 23Y/Female	Mobile No	: 7066480130	Ref. By	:
Registered On	: 16-03-2024 08:12 AM	Collected On	: 16-03-2024 08:20 AM	Reported On	: 16-03-2024 06:39 PM
Nationality	: Indian	Patient Type	: Sponsor	Sponsor Name	: MediWheel(Arcotemi Healthcare Pvt. Ltd.)

LFT - LIVER FUNCTION TEST

Test Name	Test Result	Normal Values	Unit
Serum Bilirubin Total	0.16	0.1 - 1.2	mg/dl
Serum Bilirubin Direct	0.07	0 - 0.5	mg/dl
Serum Bilirubin Indirect	0.09	0 - 0.9	mg/dl
Serum SGOT (AST)	24	0 - 40	IU/L
Serum SGPT (ALT)	22	0 - 40	IU/L
Serum Alkaline Phosphatase	96	40 - 111	IU/L
Serum GGT	16	11 - 50	IU/L
Serum Total Proteins	6.2 L	6.4 - 8.3	g/dl
Serum Albumin	3.3 L	3.5 - 5.2	g/dl
Serum Globulin	2.90	1.6 - 3.5	g/dl
A/G Ratio	1.14	0 - 100	micro IU/mL

Equipment: ERBA-EM 200 FULLY AUTOMATED CLINICAL CHEMISTRY ANALYSER.

--End Of Report--

Priyanka Sharma
(Technician Name)

Dr. Tabassum Shaikh
MBBS, MD (Pathology)
Consultant Pathologist
Reg No. 2016083587

ISO : 9001:2015 Certified

Right Diagnosis, Right Treatment, Right Place



MEESHA
DIAGNOSTICS AND POLYCLINIC

Branch :

Ground Floor, 12-C, Moti Mahal, C.S. No. 1631, Churchgate, Mumbai-400 020.
Tel. : +91 22 3574 1977 / 93241 87465 / 77100 84304

LAB REPORT

Printed Date: 2024-03-16 06:40 PM

Patient Id	: 43029	Patient Name	: Miss AMRUTA AGRAWAL	TreatmentId	: 19431
Age/Gender	: 23Y/Female	Mobile No	: 7066480130	Ref. By	:
Registered On	: 16-03-2024 08:12 AM	Collected On	: 16-03-2024 08:20 AM	Reported On	: 16-03-2024 06:39 PM
Nationality	: Indian	Patient Type	: Sponsor	Sponsor Name	: MediWiser(Arcotem Healthcare Pvt. Ltd.)

T3,T4,TSH (THYROID PROFILE)

Test Name	Test Result	Normal Values	Unit
SERUM T3 (Tri-Iodothyronine)	81	55 - 205	ng/dl
SERUM T4 (Tetra-Iodothyronine)	5.86	3.5 - 12.5	ug/dl
SERUM TSH (Thyroid Stimulating Hormone)	0.86	0.25 - 5.0	µIU/ml

Interpretation: REFERENCE RANGE : a. ADULT :-Euthyroid : 0.25 - 5.0 IU/ml
Hypothyroid : >7.0 IU/ml
Hyperthyroid:< 0.15 IU/ml

NOTE : TSH values between 0.15 - 0.25 IU/ml and between 5.0 - 7.0 IU/ml are to be considered as a borderline. Repeat results after 2 weeks.

b. PREGNANCY :- First Trimester : 0.25 - 4.0 IU/ml
Second Trimester : 0.5 - 4.0 IU/ml
Second Trimester : 0.5 - 4.0 IU/ml
Third Trimester : 0.4 - 5.0 IU/ml

c. NEWBORN :-
1 - 4 days : 1.0 - 39.0 IU/ml
1 - 4 weeks : 1.7 - 9.1 IU/ml
1 - 12 months : 0.8 - 8.2 IU/ml
1 - 5 years : 0.7 - 5.7 IU/ml

NOTE : This assay is performed as per the standard kit protocol.

Equipment: BIOMERIEUX VIDAS

--End Of Report--

Priyanka Sharma
(Technician Name)

Dr Tabassum Shaikh
MBBS,MD (Pathology)
Consultant Pathologist
Reg No.2016083507

ISO : 9001:2015 Certified

Right Diagnosis, Right Treatment, Right Place



MEESHA
DIAGNOSTIC AND POLYCLINIC

Branch :

Ground Floor, 12-C, Moti Mahal, C.S. No. 1631, Churchgate, Mumbai-400 020.
Tel. : +91 22 3574 1977 / 93241 87465 / 77100 84304

LAB REPORT

Printed Date: 2024-03-16 06:40 PM

Patient Id : 43029	Patient Name : Miss AMRUTA AGRAWAL	Treatmentid : 19431
Age/Gender : 23Y/Female	Mobile No : 7066480130	Ref. By :
Registered On : 16-03-2024 08:12 AM	Collected On : 16-03-2024 08:20 AM	Reported On : 16-03-2024 06:39 PM
Nationality : Indian	Patient Type : Sponsor	Sponsor Name : MediWheel(Arcofemi Healthcare Pvt. Ltd.)

VITAMIN 'D' TOTAL 25-OH (D2+D3)

<u>Test Name</u>	<u>Test Result</u>	<u>Normal Values</u>	<u>Unit</u>
Vitamin D	47.9	20 - 100	ng/ml

Interpretation: INTERPRETATION :

Deficiency :- < 20 ng/ml
Insufficiency :- 20-29 ng/ml
Sufficiency :- 30-100 ng/ml
Toxicity :- > 100 ng/ml

NOTE : The test has been carried out in Fully Automated Immunoassay System VIDAS using ELFA (Enzyme-Linked Fluorescence Assay) technology.

Equipment: BIOMERIEUX VIDAS

--End Of Report--

Priyanka Sharma
(Technician Name)

Dr. Tabassum Shakh
MBBS,MD (Pathology)
Consultant Pathologist
Reg No.2016083587



MEESHA
DIAGNOSTIC AND POLYCLINIC

Branch :

Ground Floor, 12-C, Moti Mahal, C.S. No. 1631, Churchgate, Mumbai-400 020.
Tel. : +91 22 3574 1977 / 93241 87465 / 77100 84304

LAB REPORT

Printed Date: 2024-03-16 06:40 PM

Patient Id	: 43029	Patient Name	: Miss AMRUTA AGRAWAL	TreatmentId	: 19431
Age/Gender	: 23Y/Female	Mobile No	: 7066480130	Ref. By	:
Registered On	: 16-03-2024 08:12 AM	Collected On	: 16-03-2024 08:20 AM	Reported On	: 16-03-2024 06:30 PM
Nationality	: Indian	Patient Type	: Sponsor	Sponsor Name	: MedWheel(Arcotem) Healthcare Pvt. Ltd.)

URINE ROUTINE

<u>Test Name</u>	<u>Test Result</u>
PHYSICAL EXAMINATION	
Quantity	40 ml
Appearance	Slightly Hazy
Colour	Pale Yellow
Specific Gravity	1.020
Blood	Absent
CHEMICAL EXAMINATION	
Reaction (pH)	Acidic 5.0
Albumin	Absent
Glucose	Absent
Ketone Bodies	Absent
Bile Pigment	Absent
Urobilinogen	Normal
Occult blood	Absent
MICROSCOPIC EXAMINATION	
Epithelial Cells	1-2/hpf
Pus Cells	3-4/hpf
Red Blood Cells	0-1/hpf
Yeast cell	Absent
Casts	Absent
Crystals	Absent
Amorphous Deposit	Absent
Bacteria	<u>Few</u>

--End Of Report--

Priyanka Sharma
(Technician Name)

Dr Tabassum Shaikh
MBBS,MD (Pathology)
Consultant Pathologist
Reg No. 2016083587

ISO : 9001:2015 Certified

Right Diagnosis, Right Treatment, Right Place

Branch :

Ground Floor, 12-C, Moti Mahal, C.S. No. 1631, Churchgate, Mumbai-400 020.
Tel. : +91 22 3574 1977 / 93241 87465 / 77100 84304

PATIENT'S NAME : MISS.AMRUTA AGRAWAL

DATE: 16-Mar-24

Age/Sex 23 / F

REPORTED ON: 16-Mar-2024

REFERRED BY Dr.:

SAMPLE ID: 9889ABU

Page 1 of 2

16-Mar-24 4:12:43PM

Folic Acid

Result

Serum Folic Acid

16.63

Units : ng/ml

Reference Values : 3 - 17 ng/ml

Sensitivity of assay : 0.85 ng/ml

Method : CLIA

End of Report: Folic Acid

- This test has been performed at Bhide Laboratory



Dr Tabassum Shaikh
MBBS,MD (Pathology)
Consultant Pathologist
Reg No 2016063587



Branch :

Ground Floor, 12-C, Moti Mahal, C.S. No. 1631, Churchgate, Mumbai-400 020.
Tel. : +91 22 3574 1977 / 93241 87465 / 77100 84304

PATIENT'S NAME : MISS.AMRUTA AGRAWAL

DATE: 16-Mar-24

Age/Sex 23 / F

REPORTED ON: 16-Mar-2024

REFERRED BY Dr.:

SAMPLE ID: 9889ABU

Page 2 of 2

16-Mar-24 4:12:43PM

Vitamin B12

Result

Serum Vitamin B12

338.0

Units : pg/ml

Biological Reference Interval : 189 -
883 pg/ml

Sensitivity of assay : 80 pg/ml

Method : CMIA

Note : Very high levels (>1200) may be
seen for several weeks after injections
of B12

End of Report: Vitamin B12

- This test has been performed at Bhide Laboratory

Dr Tabassum Shaikh
MBBS MD (Pathology)
Consultant Pathologist
Reg No.2016083587



MEESHA HEALTHCARE & RESEARCH PVT LTD

La View,1st Floor,B.J. Marg,Jacob Circle,Saat Rasta,Mahalaxmi Mumbai
Pin - 400011

Phone No. 022-23053534/36/7710084305

www.meeshahealth.net Email: info@meeshahealth.net

Name	AMRUTA AGRAWAL				
Age/Sex	023Y/F	Patient ID	43029	Referred By	MEDIWHEEL
Study Date	2024-03-16 09:31		Report Date	2024-03-16 11:51	

RADIOGRAPH OF THE CHEST PA VIEW

FINDINGS:

Both the lung fields are clear.

Both the costophrenic angles are clear.

Hilar shadows appear normal.

Cardiothoracic ratio is within normal limits.

Hemidiaphragms are normal in position and contour.

Trachea is in the midline.

Bony thorax under view is unremarkable.

IMPRESSION:

Radiograph chest does not reveal any significant abnormality.


DR. Jyotiashree Pathak
Consultant Radiologist
MBBS, DNB
Reg No. 207182/1014



Branch :

Ground Floor, 12-C, Moti Mahal, C.S. No. 1631, Churchgate, Mumbai-400 020.
Tel. : +91 22 3574 1977 / 93241 87465 / 77100 84304

Patient Name : MISS.AMRUTA AGRAWAL **ID No : 43029**
Age : 23 YEARS **Sex : FEMALE**
Ref. By : MEDI WHEEL(ARCOFEMI HEALTHCARE) **Date : 16.03.2024**

ULTRASONOGRAPHY OF THE ABDOMEN AND PELVIS

Liver

Is normal in size measures 13.8 cm and shows normal echotexture.
No focal or diffuse lesion is seen.
The biliary tree and portal vein radicals are normal.
Portal vein measures 9.5 mm Common bile duct measures 4.6 mm

Gall bladder

Is physiologically distended and reveals an anechoic lumen.
No gallstone or evidence of cholecystitis is seen.

Pancreas

Reveals a homogenous normal parenchymal echotexture and appears normal in size.
No solid or cystic mass lesion is seen. No pancreatic calcification or duct dilatation is seen.

Spleen

Is normal in size measures 8.6 cms. The parenchymal echotexture is normal.
No focal mass lesion is seen.

Kidneys

The right kidney measures 9.6 x 3.3 cms. The left kidney measures 9.6 x 4.0 cms
Both kidneys are normal in size, shape and reveal normal differentiation of cortex, medulla and central echo complex.
No hydronephrosis, calculus or scarring is seen.

Urinary bladder

Was distended and revealed no intrinsic abnormality.

No para aortic lymphadenopathy or ascites is seen.



MEESHA
DIAGNOSTICS AND POLYCLINIC

Branch :

Ground Floor, 12-C, Moti Mahal, C.S. No. 1631, Churchgate, Mumbai-400 020.
Tel. : +91 22 3574 1977 / 93241 87465 / 77100 84304

Patient Name : MISS.AMRUTA AGRAWAL **ID No : 43029**
Age : 23 YEARS **Sex : FEMALE**
Ref. By : MEDI WHEEL(ARCOFEMI HEALTHCARE) **Date : 16.03.2024**

Uterus

Is retroverted and normal in size. Uterus measures 5.4 x 3.8 x 3.7 cms.
The myometrium and endometrium reveal normal echogenicity.
There is a 2.0 x 1.7 x 1.5 cm sized left antero – lateral subserosal fibroid noted.
There is a 8.2 x 7.1 x 6.9 cm sized right postero – lateral subserosal fibroid noted.
Endometrium thickness is normal and measures 9.5 mm.

Ovaries

Both ovaries appear bulky and show multiple small peripherally arranged follicles and echogenic stroma – s/o polycystic changes.
Right ovary measures 3.5 x 3.3 x 2.7 cms (vol-16.7 cc)
Left ovary measures 3.6 x 3.0 x 2.3 cms (vol-13.7 cc)

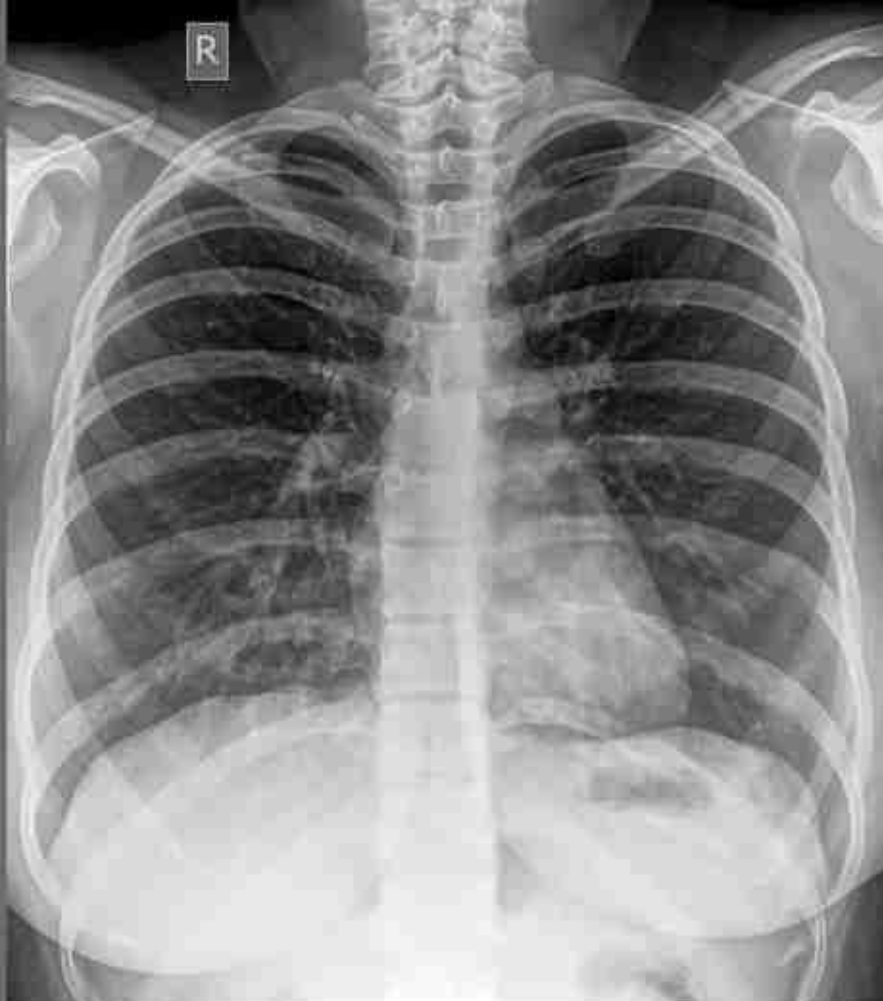Cul de sac is unremarkable.

IMPRESSION :

- Uterine fibroid as described above.
 - Polycystic changes in both ovaries.
- Suggest Clinicopathological correlation.

DR. ANKITA V. MAREWAR
M.B.B.S, D.M.R.E
CONSULTANT RADIOLOGIST

R



AMRITA AGRAWAL Female

CHEST PA

16-Mar-24 9:31:46 AM

43029

23 year(s)

T066480130

MEDMHEEL

MEESHA HEALTHCARE & RESEARCH PVT LTD

YOUR PARTNER IN HEALTH

