


Name : Mrs. ULAGAMMAI K S Address : E CITY Plan : ARCOFEMI MEDIWHEEL FEMALE AHC CREDIT PAN INDIA OP AGREEMENT	Age: 59 Y Sex: F	UHID: CELE.0000063904  OP Number: CELEOPV323825 Bill No : CELE-OCR-52779 Date : 30.11.2023 08:55
---	---------------------------------------	--

Sno	Service Type/ServiceName	Department
1	ARCOFEMI - MEDIWHEEL - FULL BODY ANNUAL PLUS CHECK ADVANCED - FEMALE - 2D ECHO - PAN INDIA - FY2324	
1	URINE GLUCOSE(FASTING) — 12	
2	GAMMA GLUTAMYL TRANSFERASE (GGT)	
3	SONO MAMOGRAPHY - SCREENING — Pending	
4	HbA1c, GLYCATED HEMOGLOBIN	
5	2D ECHO — 11	
6	LIVER FUNCTION TEST (LFT)	
7	X-RAY CHEST PA — 09	
8	GLUCOSE, FASTING	
9	HEMOGRAM + PERIPHERAL SMEAR	
10	ENT CONSULTATION — 06 — Pending	
11	FITNESS BY GENERAL PHYSICIAN — Pending	
12	GYNAECOLOGY CONSULTATION	
13	DIET CONSULTATION — Pending	
14	COMPLETE URINE EXAMINATION	
15	URINE GLUCOSE(POST PRANDIAL)	
16	PERIPHERAL SMEAR	
17	ECG — 13	
18	BLOOD GROUP ABO AND RH FACTOR	
19	LIPID PROFILE	
20	BODY MASS INDEX (BMI)	
21	LBC PAP TEST- PAPSURE — 16	
22	OPHTHAL BY GENERAL PHYSICIAN — 05	
23	RENAL PROFILE/RENAL FUNCTION TEST (RFT/KFT)	
24	ULTRASOUND - WHOLE ABDOMEN — 08	
25	THYROID PROFILE (TOTAL T3, TOTAL T4, TSH)	
26	DENTAL CONSULTATION — 15	
27	GLUCOSE, POST PRANDIAL (PP), 2 HOURS (POST MEAL)	

REI- 6/9 ?
 LEI- 6/6p } with glasses
 color vision! - normal

Personal Details
UHID: 00XHE1PU6QN0T8F

Pre-Existing Medical-Conditions

Symptoms

Vitals

Measurements

PatientID: 63904
Name: Mrs Ulagammai K S

Age: 59

Gender: Female

Mobile: 9964080679

HR : 78 BPM

PR: 150 ms

PD: 108 ms

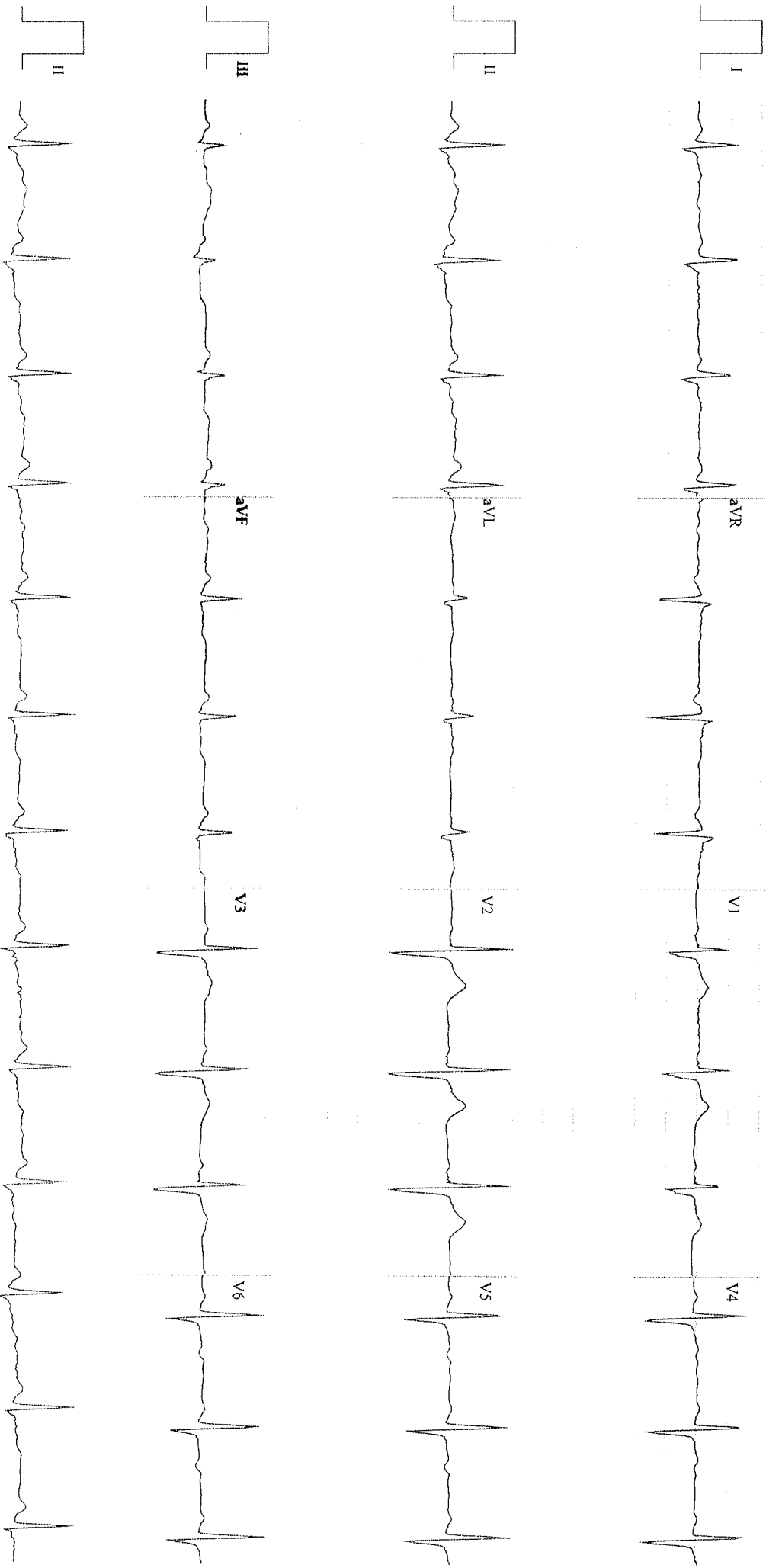
QRS: 94 ms

QRS Axis: 54 deg

QT/QTc: 371/423 ms

Interpretation(Unconfirmed)
Normal Sinus Rhythm
Normal Axis
Inverted T waves in Lateral Leads

This trace is generated by KardiasScreen; Cloud-Connected, Portable, Digital, 6-12 Lead Scalable ECG Platform from IMEDRIX



Disclaimer: ECG data for reference by qualified Medical Practitioners only.

Speed: 25 mm/sec

F: 0.05 - 40 Hz

Limh: 10 mm/mV

Chest: 10 mm/mV

NAME:	Mrs. ULAGAMMAI K S
AGE / SEX:	59YRS/ FEMALE
DATE:	30/11/2023
REFERRED BY:	ARCOFEMI

ABDOMINAL ULTRASONOGRAPHY REPORT

LIVER: Appear normal in size and mild increased echogenicity. No focal lesion seen. The intra hepatic biliary and portal venous radicals are normal. Portal vein and CBD is normal.

GALL BLADDER: Moderately distended and appears normal. No abnormal wall thickening / pericholecystic fluid seen.

PANCREAS: Normal to the extent visualized.

SPLEEN: Normal in size and echo texture. No focal lesion noted

KIDNEYS: Both kidneys are normal in position, size and echo texture. Normal cortico-medullary differentiation is maintained. No calculus/ hydronephrosis on both sides.

PELVIC ORGANS:

Urinary bladder is minimally distended

Uterus and Ovaries : Not Visualised – Post surgical status.

Adnexa : Normal.

No free fluid in the abdomen and pelvis.

IMPRESSION:

- *Mild fatty liver. .*

*To correlate clinically & with other investigations.
Not for medico-legal purpose*



DR C G NADAGOUD
CONSULTANT RADIOLOGIST

Apollo Health and Lifestyle Limited

(CIN - U85110TG2000PLC115819)

Regd. Office: 1-10-60/62, Ashoka Raghupathi Chambers, 5th Floor, Begumpet, Hyderabad, Telangana - 500 016.

Ph No: 040-4904 7777, Fax No: 4904 7744 | Email ID: enquiry@apollohl.com | www.apollohl.com

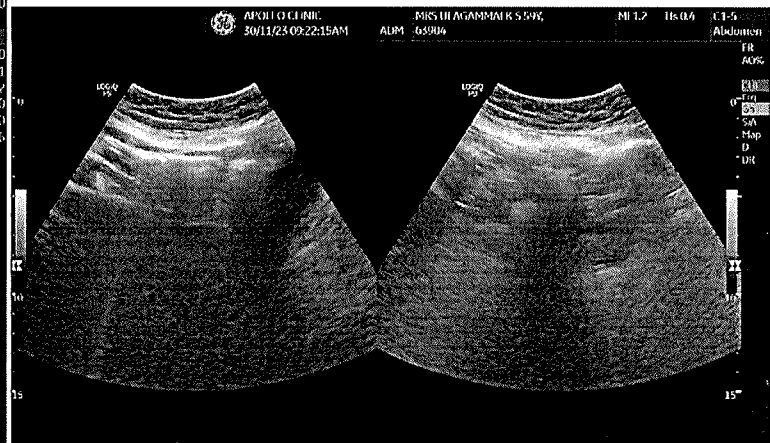
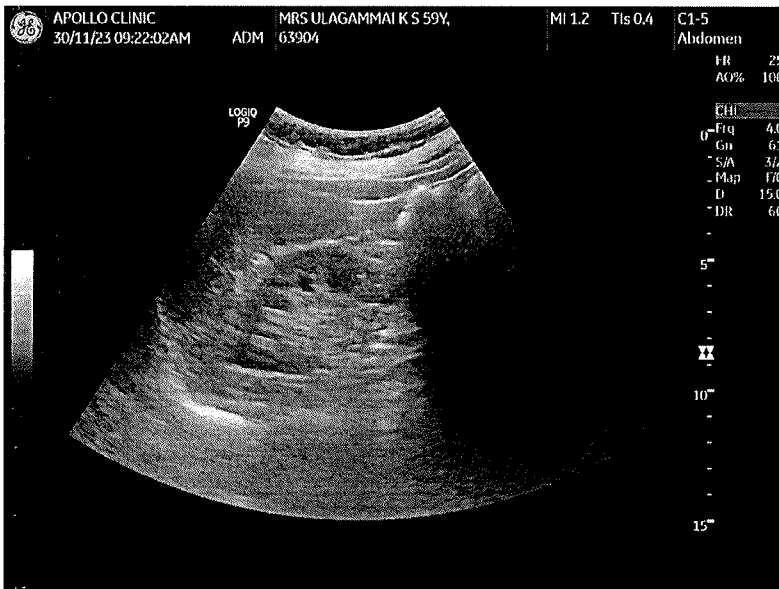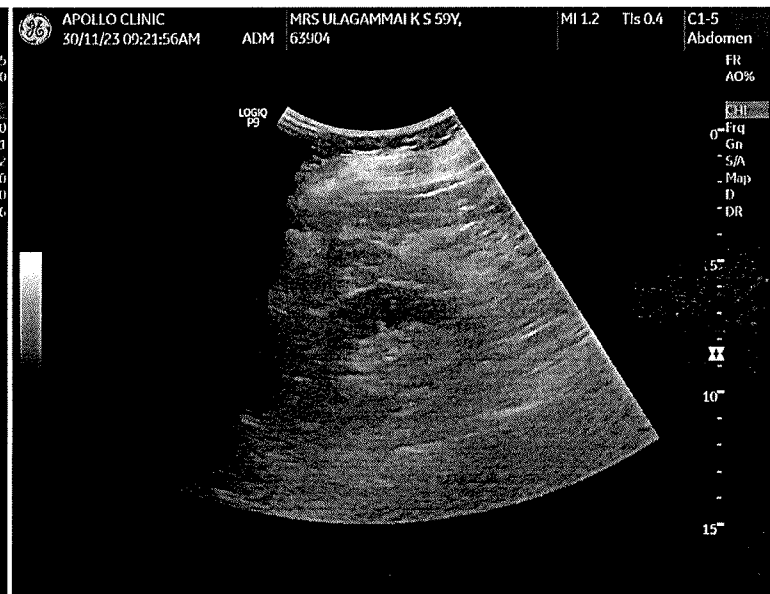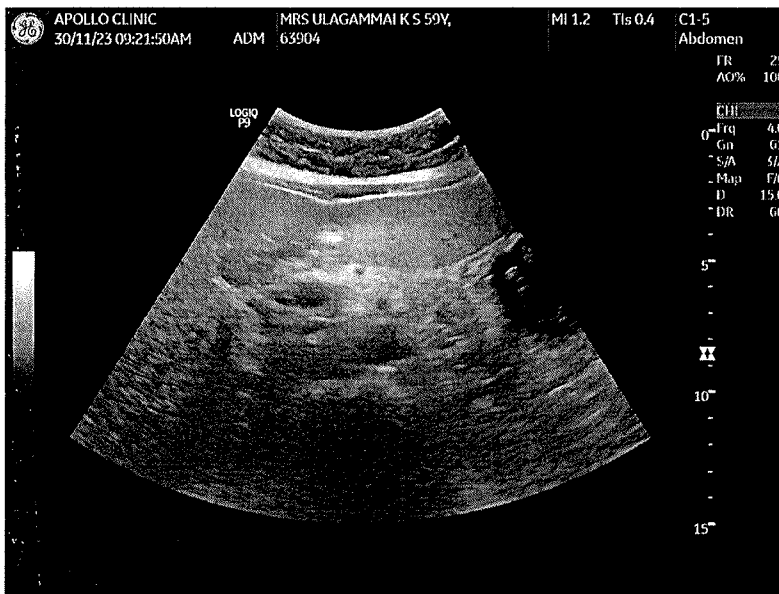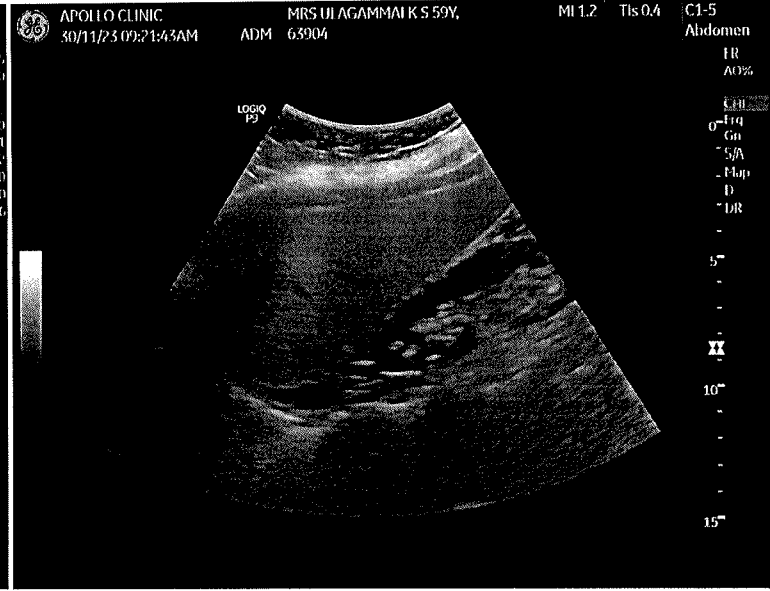
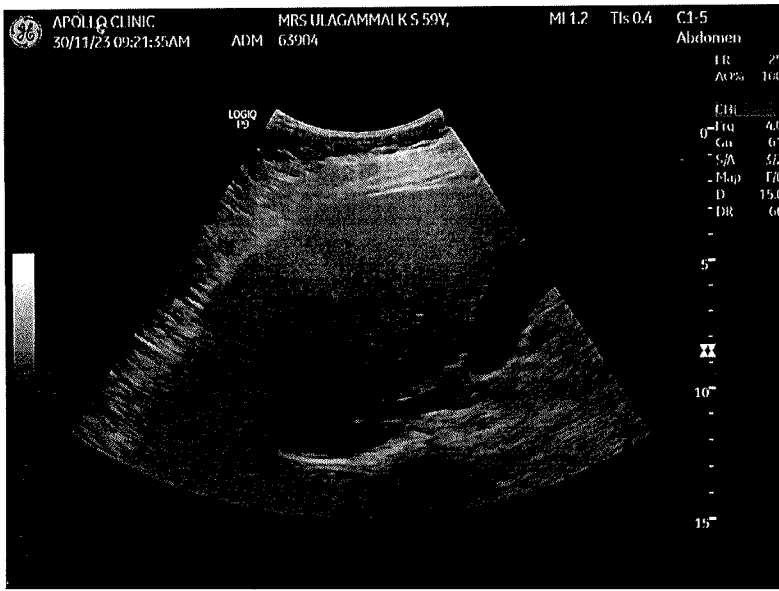
APOLLO CLINICS NETWORK KARNATAKA

Bangalore (Basavanagudi | Bellandur | Electronic City | Fraser Town | HSR Layout | Indira Nagar | JP Nagar | Kundalahalli | Koramangala | Sarjapur Road) **Mysore** (VV Mohalla)

Online appointments: www.apolloclinic.com

TO BOOK AN APPOINTMENT

 **1860 500 7788**





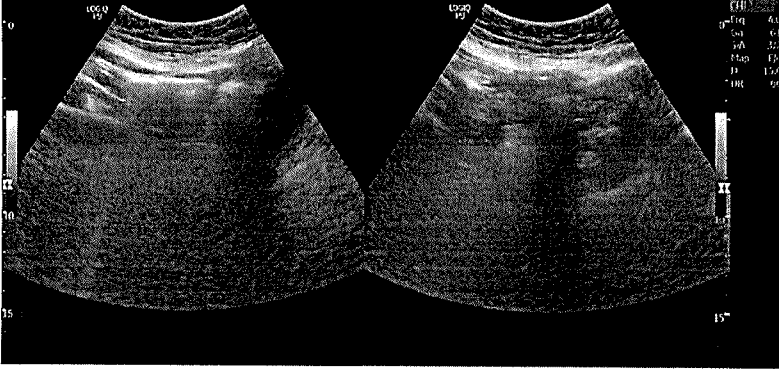
APOLLO CLINIC
30/11/23 09:22:31AM

BHUVANAGANNAI K S 59Y,
ADM 45804

MU L2 T16.04

CT-5

Abdomen
FR 24
AGE 109
CH 2023
FR 40
SA 61
SA 32
MAP 150
D 170
T 90



2-D ECHO-CARDIOGRAPHY DOPPLER & COLOUR DOPPLER REPORT

NAME : MRS ULAGAMMAI K S

DATE :30/11/2023

AGE/SEX: 59Y / F

REF :ARCOFEMI

UHID:63904/11/165

***** MEASUREMENTS & FLOW VELOCITIES AS DEPICTED IN IMAGES OVERLEAF.**

1. NORMAL VALVES.
2. NORMAL FLOW ACROSS ALL VALVES.
3. NO MR/ AR/ TR.
4. NORMAL GREAT VESSELS.
5. NORMAL SYSTEMIC VEINS & AT LEAST 3 PULMONARY VEINS SEEN DRAINING INTO LA.
6. NORMAL SIZED CHAMBERS.
7. NO REGIONAL WALL MOTION ABNORMALITIES.
8. INTACT SEPTAE (IVS & IAS).
9. GOOD LV & RV SYSTOLIC FUNCTION.
10. PERICARDIUM : NORMAL
11. NO OBVIOUS VEGETATION / CLOTS.



DR (CAPT.)S.V KRISHNA RAO

MD (PGI), DNB (Card)

Senior Consultant – Cardiologist

Reg No : ANP 19780000746KTK

To correlate with clinical findings & other relevant investigations .

Apollo Health and Lifestyle Limited

(CIN - U85110TG2000PLC115819)

Regd. Office: 1-10-60/62, Ashoka Raghupathi Chambers, 5th Floor, Begumpet, Hyderabad, Telangana - 500 016.

Ph No: 040-4904 7777, Fax No: 4904 7744 | Email ID: enquiry@apollohl.com | www.apollohl.com

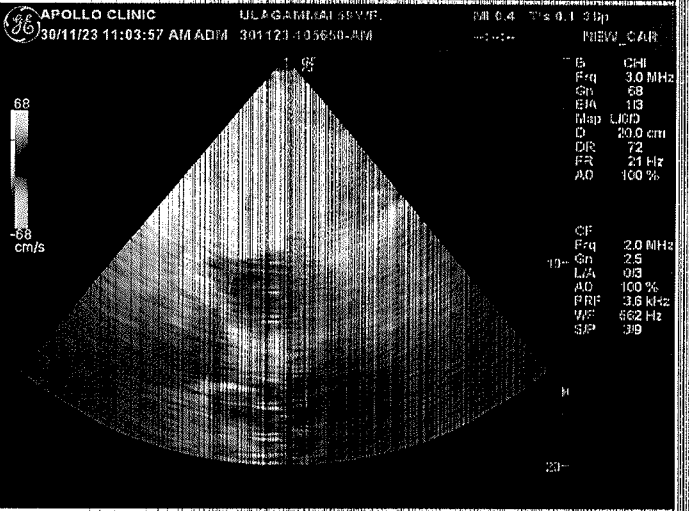
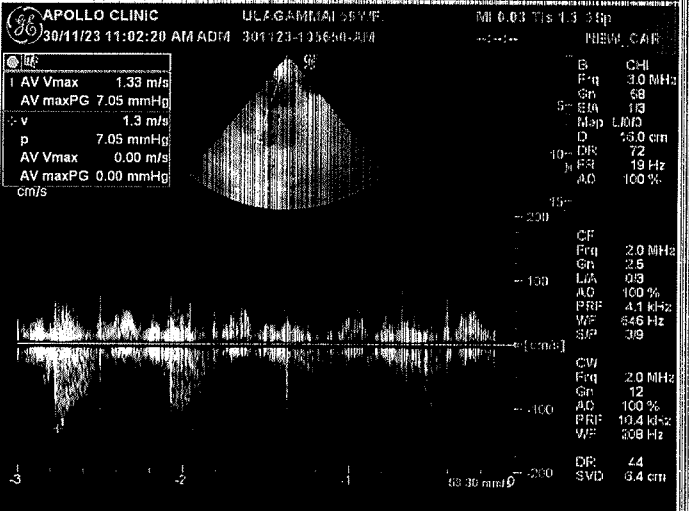
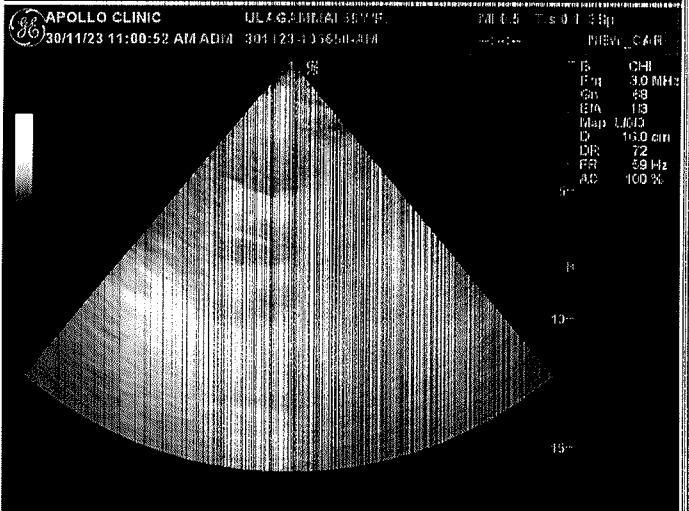
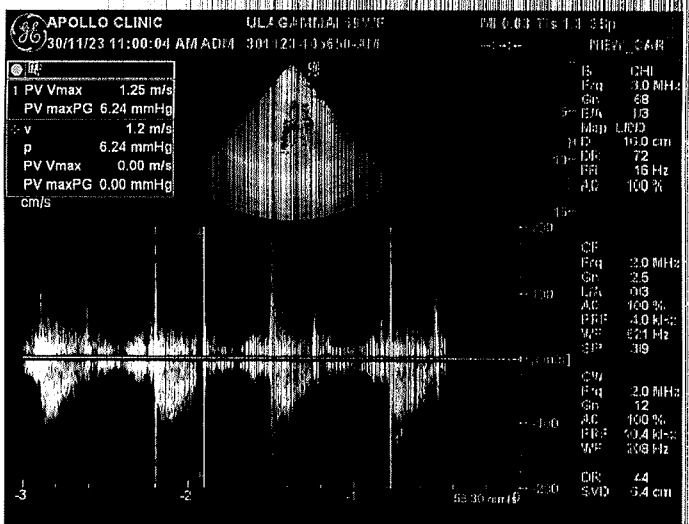
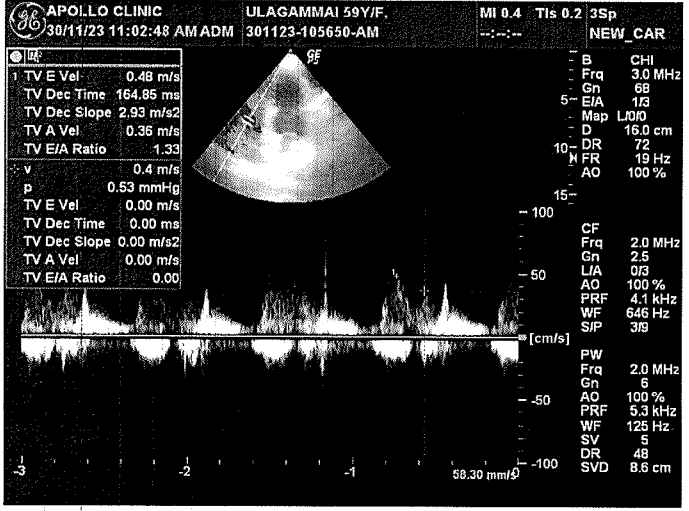
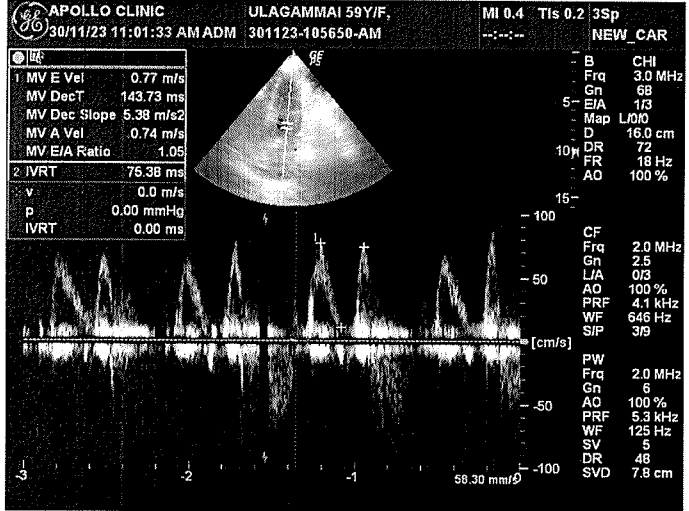
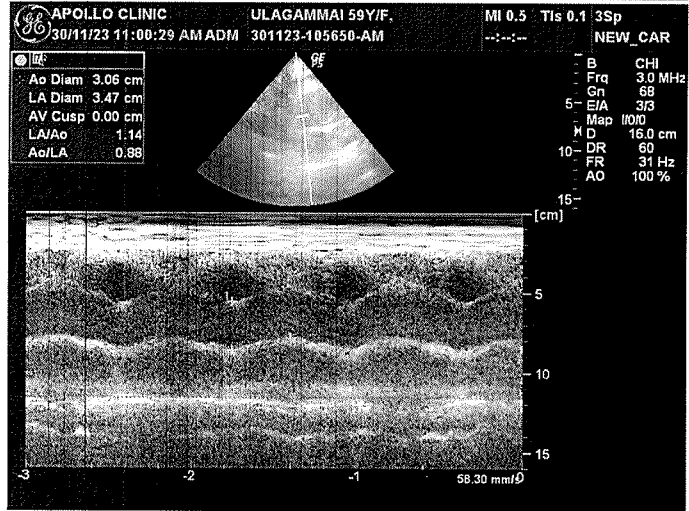
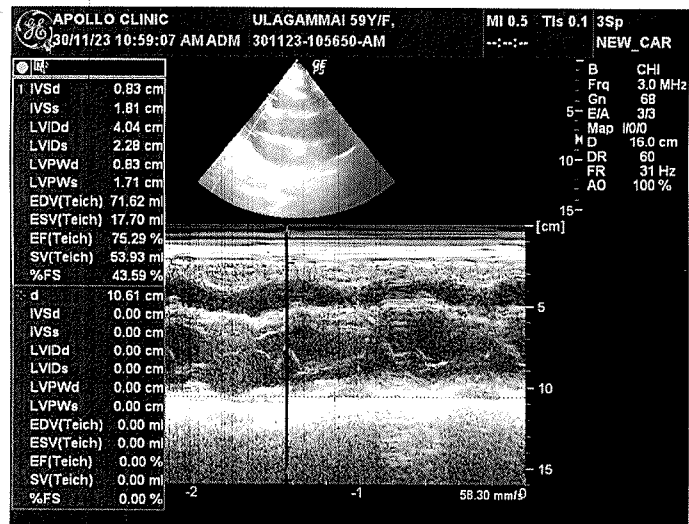
APOLLO CLINICS NETWORK KARNATAKA

Bangalore (Basavanagudi | Bellandur | Electronic City | Fraser Town | HSR Layout | Indira Nagar | JP Nagar | Kundalahalli | Koramangala | Sarjapur Road) **Mysore** (VV Mohalla)

Online appointments: www.apolloclinic.com

TO BOOK AN APPOINTMENT

 **1860 500 7788**



Patient Name	: Mrs. ULAGAMMAI K S	Age	: 59 Y F
UHID	: CELE.0000063904	OP Visit No	: CELEOPV323825
Reported on	: 30-11-2023 15:27	Printed on	: 30-11-2023 15:27
Adm/Consult Doctor	:	Ref Doctor	: SELF

DEPARTMENT OF RADIOLOGY

X-RAY CHEST PA

Both lung fields and hila are normal .

No obvious active pleuro-parenchymal lesion seen .

Both costophrenic and cardiophrenic angles are clear .

Both diaphragms are normal in position and contour .


Thoracic wall and soft tissues appear normal.

CONCLUSION :

No obvious abnormality seen

Printed on:30-11-2023 15:27

---End of the Report---


For **Dr. CHANNAPPAGOUD NADAGOUD**
MBBS, DMRD, DNB Radio Diagnosis
Radiology

Apollo Health and Lifestyle Limited

(CIN - U85110TG2000PLC115819)

Regd. Office: 1-10-60/62, Ashoka Raghupathi Chambers, 5th Floor, Begumpet, Hyderabad, Telangana - 500 016.


Ph No: 040-4904 7777, Fax No: 4904 7744 | Email ID: enquiry@apollohl.com | www.apollohl.com

APOLLO CLINICS NETWORK KARNATAKA

Bangalore (Basavanagudi | Bellandur | Electronic City | Fraser Town | HSR Layout | Indira Nagar | JP Nagar | Kundalahalli | Koramangala | Sarjapur Road) **Mysore** (VV Mohalla)

Online appointments: www.apolloclinic.com

TO BOOK AN APPOINTMENT

 **1860 500 7788**

MRS. Ulagammi K.S.
59 F.

30/11/23.
DR. KRISHNA SHAW
Gynaec.

HC + LBC.

Height :	Weight :	BMI :	Waist Circum :
Temp :	Pulse :	Resp :	B.P :

General Examination / Allergies
History

Clinical Diagnosis & Management Plan

P/W. TAH - 2007
 P/L3 - AIA NDS, open T done.
 P/A Abd soft.
 P/V
 P/S - CXR - (W).
 B/L Br. No Inf.
 Adv.
 ← R/W Repts
 R

Follow up date:

Doctor Signature

THE JOHN RYAN GROUP
Bank of America

THE
Name
R. C. Mc
152000

UNITED STATES OF AMERICA
Washington, D. C.

Original instrument
Search Authority

Signature of Holder

Signature



प्रति,

समन्वयक,

Mediwheel (Arcofemi Healthcare Limited)

हेल्पलाइन नंबर: 011-41195959

महोदय/ महोदया,

विषय: बैंक ऑफ़ बड़ौदा के कर्मचारियों के लिए वार्षिक स्वास्थ्य जांच।

हम आपको सूचित करना चाहते हैं कि हमारे कर्मचारी जिनका विवरण निम्नानुसार हैं हमारे करार के अनुसार आपके द्वारा उपलब्ध कराई गई कैशलेस वार्षिक स्वास्थ्य जांच सुविधा का लाभ लेना चाहते हैं।

	कर्मचारी विवरण
नाम	MS. S ULAGAMMAI K
क.कू.संख्या	152966
पदनाम	JOINT MANAGER
कार्य का स्थान	BANGALORE,ELECTRONIC CITY GENN
जन्म की तारीख	12-05-1964
स्वास्थ्य जांच की प्रस्तावित तारीख	14-11-2023
बुकिंग संदर्भ सं.	23D152966100074886E

यह अनुमोदन/ संस्तुति पत्र तभी वैध माना जाएगा जब इसे बैंक ऑफ़ बड़ौदा के कर्मचारी आईडी कार्ड की प्रति के साथ प्रस्तुत किया जाएगा। यह अनुमोदन पत्र दिनांक 09-11-2023 से 31-03-2024 तक मान्य है। इस पत्र के साथ किए जाने वाले चिकित्सा जांच की सूची अनुलग्नक के रूप में दी गई है। कृपया नोट करें कि उक्त स्वास्थ्य जांच हमारी टाई-अप व्यवस्था के अनुसार कैशलेस सुविधा है। हम अनुरोध करते हैं कि आप हमारे कर्मचारी के स्वास्थ्य जांच संबंधी आवश्यकताओं पर उचित कार्रवाई करें तथा इस संबंध में अपनी सर्वोच्च प्राथमिकता तथा सर्वोत्तम संसाधन उपलब्ध कराएं। उपर्युक्त सारणी में दी गई कर्मचारी कूट संख्या एवं बुकिंग संदर्भ संख्या का उल्लेख अनिवार्य रूप से इनवॉइस में किया जाना चाहिए।

हम इस संबंध में आपके सहयोग की अपेक्षा करते हैं।

भवदीय,

हस्ता/-

(मुख्य महाप्रबंधक)

मानव संसाधन प्रबंधन विभाग

बैंक ऑफ़ बड़ौदा

(नोट: यह कंप्यूटर द्वारा जनरेट किया गया पत्र है। हस्ताक्षर की आवश्यकता नहीं है। कृपया किसी भी स्पष्टीकरण के लिए Mediwheel (Arcofemi Healthcare Limited) से संपर्क करें।)

SUGGESTIVE LIST OF MEDICAL TESTS

FOR MALE	FOR FEMALE
CBC	CBC
ESR	ESR
Blood Group & RH Factor	Blood Group & RH Factor
Blood and Urine Sugar Fasting	Blood and Urine Sugar Fasting
Blood and Urine Sugar PP	Blood and Urine Sugar PP
Stool Routine	Stool Routine
Lipid Profile	Lipid Profile
Total Cholesterol	Total Cholesterol
HDL	HDL
LDL	LDL
VLDL	VLDL
Triglycerides	Triglycerides
HDL / LDL ratio	HDL / LDL ratio
Liver Profile	Liver Profile
AST	AST
ALT	ALT
GGT	GGT
Bilirubin (total, direct, indirect)	Bilirubin (total, direct, indirect)
ALP	ALP
Proteins (T, Albumin, Globulin)	Proteins (T, Albumin, Globulin)
Kidney Profile	Kidney Profile
Serum creatinine	Serum creatinine
Blood Urea Nitrogen	Blood Urea Nitrogen
Uric Acid	Uric Acid
HBA1C	HBA1C
Routine urine analysis	Routine urine analysis
USG Whole Abdomen	USG Whole Abdomen
General Tests	General Tests
X Ray Chest	X Ray Chest
ECG	ECG
2D/3D ECHO / TMT	2D/3D ECHO / TMT
Stress Test	Thyroid Profile (T3, T4, TSH)
PSA Male (above 40 years)	Mammography (above 40 years) and Pap Smear (above 30 years).
Thyroid Profile (T3, T4, TSH)	Dental Check-up consultation
Dental Check-up consultation	Physician Consultation
Physician Consultation	Eye Check-up consultation
Eye Check-up consultation	Skin/ENT consultation
Skin/ENT consultation	Gynaec Consultation