

DAKSH HOSPITAL

396 - 397, Gandhi Nagar, Scheme No. 8, ALWAR -301001

Ref. No.

Date.....15/11/23.....

EDICAL EXAMINATION REPORT
Mediwheel (BOB)

Name: Mr. Raghav Khandelwal Age: 28 yrs Sex: Male

Date: 15/11/2023

General Physical ExaminationHeight : 174 cm
Pulse : 72 /mt
Respiration : 18 /mtWeight : 77.5 kg
BP : 120/80 mm/hg
BMI : 25.6 kg/m²**Systemic Exam:-** NORMAL**Dental Check up :-** NORMAL**Eye check-up :-** - NORMAL**Skin Check up:-** - NORMAL**ENT Check up:-** - NORMAL**Impression:-** 28 yrs old gentleman, NORMAL Built & WT, Undergone medical checkup. No MILD Pleurisy, S slight increase O/P/P. Rest other normal.**Recommendation:-**
• PBF
• HbSA4
• HCV
• CMPDr. Mukesh Kumar Gupta
MD Gen. Medicine
Reg. No 5423/16262डॉ० मुकेश गुप्ता
M.D.F.C.C.S.
फिजिशियन एवं मधुमेह रोग विशेषज्ञ
दक्ष हॉस्पिटल, अलवर
रजि० नं०-5423/16262

Results

Run Date 15/11/2023 10:11:28 AM

Operator DAKSH

Last Name

Sample ID 2

First Name MR. RAGHAV

Department

Gender Male Age

Physician DR. MUKESH GUPTA M.D

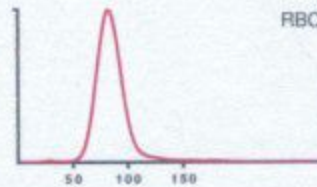
Patient ID AUTO_PID17730

Type Man

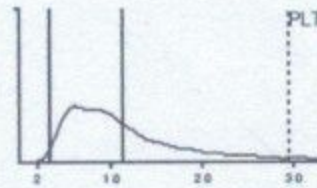
Date of birth

Sample comments

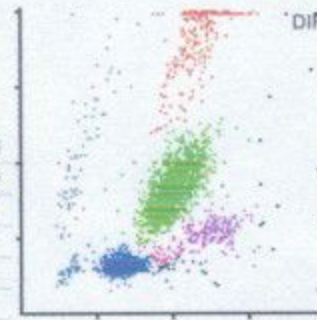
			Range
RBC	5.33	10 ⁶ /μL	3.80 - 5.50
HGB	15.8	g/dL	13.0 - 17.0
HCT	45.5	%	39.0 - 52.0
MCV	85.4	μm ³	76.0 - 100.0
MCH	29.6	pg	26.0 - 34.0
MCHC	34.7	g/dL	32.0 - 35.0
RDW-CV	13.0	%	11.0 - 16.0
RDW-SD	44.8	μm ³	37.0 - 49.0



			Range
PLT	272	10 ³ /μL	150 - 450
PCT	0.29	%	0.15 - 0.40
MPV	10.6	μm ³	8.0 - 11.0
PDW	18.0	μm ³	11.0 - 22.0
P-LCC	98	10 ³ /μL	44 - 140
P-LCR	35.9	%	18.0 - 50.0



			Range
WBC	6.00	10 ³ /μL	3.50 - 10.00
	#	Range	%
NEU	3.28	1.60 - 7.00	54.9
LYM	2.17	1.00 - 3.00	36.5
MON	0.08 l	0.20 - 0.80	1.3 l
EOS	0.37	0.00 - 0.50	6.3 h
BAS	0.06	0.00 - 0.15	1.0
LIC	0.04	0.00 - 0.10	0.7



R.S. Gupta
Dr. R.S. GUPTA
 MD (Pathology) (MAHE)
 RMC No. 7924/19778

Date :-15/11/2023

Name :- MR RAGHAV KHANDELWAL

Age & Sex :- 28 Yrs/ male

Refd. :- Dr Mukesh Gupta M.D.

	TEST NAME	RESULT	REFERENCE RANGE	
		ESR	15	00 -20 mm/hrs
	Blood Group & Rh Factor	A * POSITIVE		
	HbA1C	4.67	4 - 5.6%	
	Blood Sugar (F)	80.1	< 70 - 100 mg/dl	
	Blood Sugar (PP)	97.1	< 140 mg/dl	
	Urine Sugar (F)	NIL	-	
	Urine Sugar (PP)	NIL	-	
LIVER	S.Billirubin Total	1.00	0.30 - 1.20 mg/dl	
	S.Billirubin Direct	0.30	0.10 - 0.30 mg/dl	
	S.Billirubin Indirect	0.70	0.30 - 0.90 mg/dl	
	S.G.O.T.	59	> 37 u/l	
	S.G.P.T.	67	> 40 u/l	
	S.Alk. Phosp.	205	80 - 306 u/l	
	G.G.T.	26	5 -40 u/l	
	Total Protein	6.8	6.5 - 8.5 gm/dl	
	Albumin	3.7	3.8 - 5.4 gm/dl	
	Globulin	3.1	2.3 - 3.5 gm/dl	
	A/G Ratio	1.2	-	
AST/ALT Ratio	0.8	-		
KIDNEY	Blood Urea	25.1	15 -45 mg/dl	
	S.Creatinine	1.0	0.60 - 1.30 mg/dl	
	BUN	17.1	6 -24 mg/dl	
	S.Uric Acid	5.4	M 3.1 - 7.0, F 2.5 - 5.6 mg/dl	
	BUN/Creatinine Ratio	17.1	-	
LIPID PROFILE	Total Cholesterol	140.1	Up to 200 mg/dl	
	S.HDL	42.1	30 - 70 mg/dl	
	S.LDL	74.1	Up to 170 mg/dl	
	S.VLDL	24.1	5.0 - 40 mg/dl	
	S. Triglycerides	120.1	Up to 170 mg/dl	
	LDL/HDL Ratio	1.76	-	
THYROID	Total Cholesterol/ HDL Ratio	3.3	-	
	T3	65.1	40 - 181 ng/dl	
	T4	6.0	4.6 - 10.5 µg/dl	
	TSH	1.67	0.30 - 5.0 mIU/l	
URINE EXAMINATION			<i>Microscopic Examination:</i>	
General/Chemical Examination:			RBC	Absent
	Colour	Pale Yellow	WBC	1 -2
	Reaction	Acidic	Epithelial Cells	0 -1
	Specific Gravity	QNS	Cast	Absent
	Appearance	Clear	Crystal	Absent
	Albumin	TRACE	Spermatozoa	Absent
	Sugar	Nil	Amorphous Sediments	Absent
		Other	Absent	
X-RAY CHEST	NORMAL STUDY			
STOOL EXAMINATION			<i>Microscopic Examination:</i>	
General/ Chemical Examination:			RBC	-
	Colour	-	WBC	-
	Consistency	-	Ova & Parasites	-
	PH	-		
	Reducing Substances	-		

Dr. R.S. GUPTA
MD (Pathology) (MAHE)
RMC No. 7924/19778

TECHNOLOGIST

All investigation have their own limitations regarding the sensitivity & specificity of individual assay procedures, Isolated laboratory investigations never confirm the final diagnosis of the disease. They only help in arriving at a diagnosis in conjunction with clinical presentation and other related investigations. Report is not valid for medico-legal purpose subject to ALWAR jurisdiction only.



दक्ष हॉस्पिटल

396, गाँधी नगर स्कीम नं.8, अलवर (राज०) ☎ 0144-2703340

Sonography / 2D Echo Cardiography / Doppler Report

2D/ ECHO REPORT

Name: - Mr Raghav Khandelwal

Age: - 28 Yrs

Date: - 15-Nov-23

Reg. No.: - Alw/2009/04
BOB health checkup

PROCEDURES:

M-MODE/2D/DOPPLER/COLOR/CONTRAST B.A.S. M²


MEASUREMENT:		DOPPLER:	
AOD	24	NORMAL	NORMAL (cm/sec.)
LA	24	(20- 37mm)	MV 0.54 (0.8- 1.3) MR No
AVO	18	(19- 40mm)	AV 1.3 (1.2- 1.8) AR No
RVDd.	19.4	(12- 25mm)	TV 0.6 (0.3- 0.8) TR No
		(03- 09mm)	PV 0.8 (0.7- 1.1) PR No
LVDd	49.1	(37- 56mm)	MITRAL VALVE-
LVDs	31.0	(22- 40mm)	AML Normal
IVS d	09.7	(06- 12mm)	PML Normal
IVS s	14.2		AORTIC VALVE Normal
PWd	05.2	(05- 10mm)	TV & PV are normal.
LV FUNCTION			
M- E- S Separation		<0.9cm	
Minor		24.42%	
LV Ejection Fraction	67%	65 +/- 12%	

LV WALL MOTION: NO RWMA
ALL CARDIAC CHAMBERS ARE NORMAL
ALL VALVES ARE NORMAL
NO CLOT, VEGETATION, PERICARDIAL EFFUSION

FINAL DIAGNOSIS: NORMAL STUDY

Adv: - Follow up/ review at higher center for confirmation

Note: - Please Correlate clinically. Due to technical limitations as well as inaccuracies inherent in the laboratory and statistical analysis of biological process. Diagnostic accuracy of ECHO is up to 95% only. Report is not valid for medico-legal purpose.


Dr. Mukesh Kumar Gupta
DR. MUKESH GUPTA
Physician & Sonologist
PHYSICIAN
RM 5423/16262



भ्रूण लिंग परीक्षण की शिकायत
104 टोल फ्री सेवा पर भी की
जा सकती है

भ्रूण लिंग परीक्षण की शिकायत 104 टोल फ्री सेवा पर भी की जा सकती है



दक्ष हॉस्पिटल

396, गाँधी नगर स्कीम नं.8, अलवर (राज०) ☎ 0144-2703340

Sonography / 2D Echo Cardiography / Doppler Report

Name: MR. RAGHAV KHANDELWAL /M/28 YRS

Date: 15-Nov-23

BOB HEALTH CHECK UP

U.S.G. OF ABDOMEN & PELVIS

LIVER

Liver is normal in size shape with normal echo-texture. Intra hepatic biliary radicals are not dilated.
No evidence of focal or diffuse lesion.

GALL BLADDER

Gall bladder is normal dilated. Lumen clear. Wall thickness normal. CBD normal

PANCREAS

Pancreas is normal in size, shape & echo-texture.

SPLEEN

Spleen 10.8cm in size with normal shape & echo- texture.

BOTH KIDNEY

Both kidneys are normal in size shape and echo- texture.

PROSTATE & URINARY BLADDER is normal shape, size & echo texture..

Imp - Mild splenomegaly

Advice- X Ray KUB / URINE EXAM

Please correlate clinically. USG accuracy is 95 % due to technical limitations as well as inaccuracies inherent in the laboratory and statistical analysis biological process.

This report is not valid for medico-legal cases.

Dr. Mukesh Kumar Gupta
DR. MUKESH GUPTA
Physician & Sonologist
RM 5423/16262



भ्रूण लिंग परीक्षण की शिकायत
104 टोल फ्री सेवा पर भी की
जा सकती है।

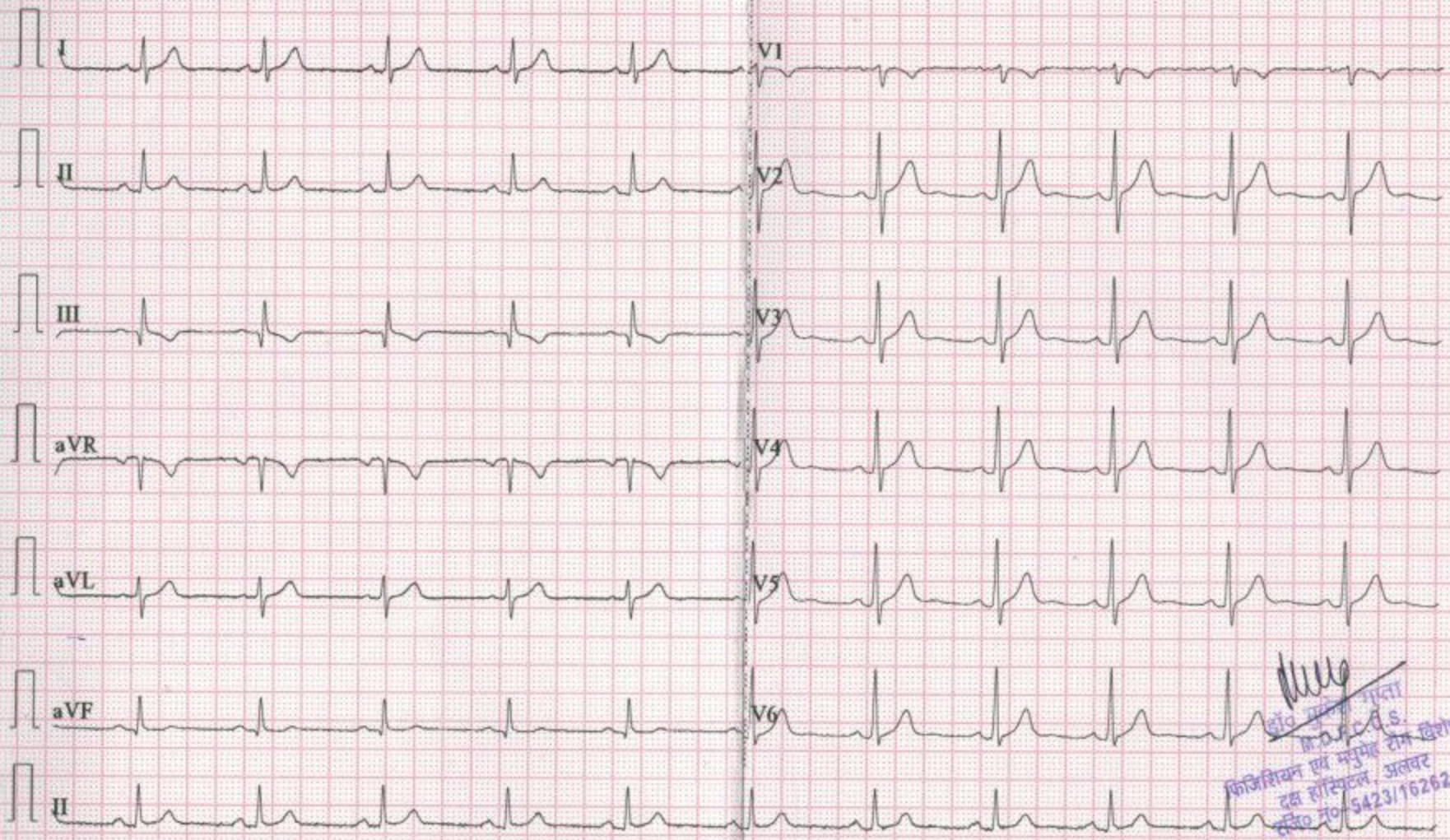
भ्रूण लिंग परीक्षण की शिकायत 104 टोल फ्री सेवा पर भी की जा सकती है।

Male Years
Req. No. :

P : 98 ms
PR : 150 ms
QRS : 82 ms
QT/QTcBz : 350/373 ms
P/QRS/T : 45/54/10 °
RV5/SV1 : 1.155/0.299 mV

Sinus rhythm
Normal ECG

Report Confirmed by:



[Signature]
Dr. A.C.S.
फिजिशियन एवं मनुष्य रोग विशेषज्ञ
दक्ष हॉस्पिटल, अलवर
संकेत नं०-5423/16262

1905

R

8cm

8cm

VIJAY DIAGNOSTIC CENTRE 1/16 KALA KUAN ALWAR

1905

