

Health Check up Booking Confirmed Request(bobE30257),Package Code-
PKG10000249, Beneficiary Code-63198

Mediwheel <wellness@mediwheel.in>

Tue 2/21/2023 5:02 AM

To: Info Sarjapur <info.sarjapur@narayanahealth.org>

Cc: mediwheelwellness@gmail.com <mediwheelwellness@gmail.com>

Attention: This email originated outside of Narayana Health domain. Links and attachments cannot be verified as authentic. Do not share personal/organisational data including passwords or act based on the content of the email, unless you have verified the authenticity of the sender and email address thoroughly.

011-41195959

Email:wellness@mediwheel.in

Hi Narayana Multispeciality Clinic ,

Diagnostic/Hospital Location :83/3 Doddakanneli,Sarjapur,Main Road , Near Wipro Gate-
560035, City:Bangalore

We have received the confirmation for the following booking .

Beneficiary Name : PKG10000249

Beneficiary Name : MS. RATHORE PRIYA

Member Age : 30

Member Gender : Female

Member Relation : Employee

Package Name : Mediwheel Metro Full Body Health Checkup Female Below 40

Location : BENGALURU,Karnataka-NULL

Contact Details : 9759798693

Booking Date : 20-02-2023

Appointment Date : 25-02-2023

Instructions to undergo Health Check:

1. Please ensure you are on complete fasting for 10-To-12-Hours prior to check.
2. During fasting time do not take any kind of medication, alcohol, cigarettes, tobacco or any other liquids (except Water) in the morning.
3. Bring urine sample in a container if possible (containers are available at the Health Check centre).
4. Please bring all your medical prescriptions and previous health medical records with you.
5. Kindly inform the health check reception in case if you have a history of diabetes and cardiac problems.

For Women:

1. Pregnant Women or those suspecting are advised not to undergo any X-Ray test.
2. It is advisable not to undergo any Health Check during menstrual cycle.

We request you to facilitate the employee on priority.

119882

Package Details



Patient Name : Ms Rathore Priya, 2010000023978, female, 30y	Multispeciality Clinic
Package Name : EHP Mediwheel Full Body Health checkup Below 40 Female	Unit of Narayana Health
Start Date : 25/02/2023 09:50 End Date : 26/02/2023 09:50	
Generated By: Bhuvaneshwari B C	
Generated On : 25-02-2023 09:50	

Service Name	Ordered Date	Service Center	Consultant	Qty	Explicit
PAP SMEAR	25/02/2023 09:50 AM	CYTOLOGY	Dr. Sharma Vasant Kumar	1	No
CONSULTATION - FIRST VISIT	25/02/2023 09:50 AM	OPD-2F	Dr. Sharma Vasant Kumar	1	No
CONSULTATION - FIRST VISIT	25/02/2023 09:50 AM	OPD-2F	Dr. Dhivya Chandrasekar	1	No
USG ABDOMEN	25/02/2023 09:50 AM	ULTRA SOUND-2F	Dr. Sharma Vasant Kumar	1	No
ECHO COLOR DOPPLER	25/02/2023 09:50 AM	ECHO-2F	Dr. Sharma Vasant Kumar	1	No
XRAY CHEST PA	25/02/2023 09:50 AM	X-RAY	Dr. Sharma Vasant Kumar	1	No
TREADMILL TEST	25/02/2023 09:50 AM	OPD-2F	Dr. Sharma Vasant Kumar	1	No
ECG	25/02/2023 09:50 AM	OPD-2F	Dr. Sharma Vasant Kumar	1	No
BLOOD UREA NITROGEN (BUN)	25/02/2023 09:50 AM	BIOCHEMISTRY	Dr. Sharma Vasant Kumar	1	No
URIC ACID	25/02/2023 09:50 AM	BIOCHEMISTRY	Dr. Sharma Vasant Kumar	1	No
LIVER FUNCTION TEST (LFT)	25/02/2023 09:50 AM	BIOCHEMISTRY	Dr. Sharma Vasant Kumar	1	No
SERUM CREATININE	25/02/2023 09:50 AM	BIOCHEMISTRY	Dr. Sharma Vasant Kumar	1	No
THYROID PROFILE (T3, T4, TSH)	25/02/2023 09:50 AM	BIOCHEMISTRY	Dr. Sharma Vasant Kumar	1	No
LIPID PROFILE (CHOL, TRIG, HDL, LDL, VLDL)	25/02/2023 09:50 AM	BIOCHEMISTRY	Dr. Sharma Vasant Kumar	1	No
HBA1C	25/02/2023 09:50 AM	BIOCHEMISTRY	Dr. Sharma Vasant Kumar	1	No
URINE FOR SUGAR (FASTING)	25/02/2023 09:50 AM	CLINICAL PATHOLOGY	Dr. Sharma Vasant Kumar	1	No
URINE FOR SUGAR (POST PRANDIAL)	25/02/2023 09:50 AM	CLINICAL PATHOLOGY	Dr. Sharma Vasant Kumar	1	No
FASTING BLOOD SUGAR (FBS)	25/02/2023 09:50 AM	BIOCHEMISTRY	Dr. Sharma Vasant Kumar	1	No
POST PRANDIAL BLOOD SUGAR (PPBS)	25/02/2023 09:50 AM	BIOCHEMISTRY	Dr. Sharma Vasant Kumar	1	No
BLOOD GROUP & RH TYPING	25/02/2023 09:50 AM	NARAYANA HRUDAYALAYA BLOOD CENTRE	Dr. Sharma Vasant Kumar	1	No
STOOL ROUTINE EXAMINATION	25/02/2023 09:50 AM	CLINICAL PATHOLOGY	Dr. Sharma Vasant Kumar	1	No
URINE ROUTINE & MICROSCOPY	25/02/2023 09:50 AM	CLINICAL PATHOLOGY	Dr. Sharma Vasant Kumar	1	No

Page 1 of 2

Eye HT - 160 cm
ms - 68.3

waist - 90 cm
PR - 108 cm
hip - 107 cm



Narayana Hrudayalaya Limited

Above HDFC Bank, 83/3, Doodakannelli, Sarjapura Main Road,

Varthur Hobli, Bangalore - 560035

Tel: + 91 88844 31319, Email: info.sarjapura@narayanahealth.org

Service Name	Ordered Date	Service Center	Consultant	Qty	Explicit
COMPLETE BLOOD COUNT (CBC)	25/02/2023 09:50 AM	HEMATOLOGY	Dr. Sharma Vasant Kumar	1	No
ERYTHROCYTE SEDIMENTATION RATE (ESR)	25/02/2023 09:50 AM	HEMATOLOGY	Dr. Sharma Vasant Kumar	1	No



25-02-2023 09:50

TRANS-THORACIC ECHO REPORT

Patient MRN : 20100000023978

Date : 25.02.2023

Patient Name : Ms.RATHORE PRIYA

Age/Gender : 30 yrs/Female

M-MODE / 2D MEASUREMENTS

LVEF (>55)% : 60%	LVID(d) (40-56)mm : 40mm	LVID (s) mm : 27mm
TAPSE (>16) mm : 20mm	IVS (d) (6-10)mm : 10mm	LV-EDV ml : --
LA (<39) mm : 28mm	PWD (d) (6-10)mm : 9mm	LV-ESV ml : --
RA (<44)mm : 30mm	RV (<35) mm : 26mm	BSA m² :-

DOPPLER MEASUREMENTS

MITRAL VALVE : E/A - 0.8/0.5 M/S, NORMAL LV DIASTOLIC FUNCTION, MR-TRIVIAL

AORTIC VALVE : PG -9 MMHG/AR-TRIVIAL

TRICUSPID VALVE : TR -TRIVIAL

PULMONARY VALVE : PG -4 MMHG

PA PRESSURE : PASP-18 MMHG/ NORMAL PA PRESSURE.

FINDINGS

SITUS SOLITUS, LEVOCARDIA, AV AND VA CONCORDANT, NORMAL GREAT ARTERY RELATIONSHIP

VALVES

MITRAL : NORMAL

AORTIC : NORMAL

TRICUSPID : NORMAL

PULMONARY : NORMAL

CHAMBERS

LV : NORMAL SIZED, NORMAL LV SYSTOLIC FUNCTION.

RV : NORMAL SIZED, NORMAL RV FUNCTION.

RWMA : NO RWMA

LVOT : NORMAL

LEFT ATRIUM : NORMAL SIZED

RIGHT ATRIUM : NORMAL SIZED



SEPTAE

IVS : INTACT

IAS : INTACT

ARTERIES & VEINS

AORTA : AORTIC ANNULUS- 20 MM, ASCENDING AORTA- 26 MM,
NORMAL ARCH NORMAL SIZED.

PULMONARY ARTERY : NORMAL

IVC, SVC & CS : IVC – 13 MM, NORMAL SIZED, COLLAPSING, NORMAL RA PRESSURE.

PULMONARY VEINS : NORMAL

PERICARDIUM : NORMAL


VEGETATION / THROMBUS / TUMOR: NIL

OTHER FINDINGS:

SINUS RHYTHM-81 BPM
NO PREVIOUS ECHO REPORT

CONCLUSION

NORMAL CHAMBER DIMENSIONS
NORMAL PA PRESSURE
NO RWMA
NORMAL LV SYSTOLIC FUNCTION
LVEF:- 60%


CHANDANA V
CARDIAC SONOGRAPHER

SCOPE OF SERVICES

Specialities

R

NARAYANA MULTISPECIALITY CLINIC, SARJAPUR ROAD,
MID. PRINCE PATRIOTIC SOCIETY, 15, 201, 250, 255, 258, 260, 262, 264, 266, 268, 270, 272, 274, 276, 278, 280, 282, 284, 286, 288, 290, 292, 294, 296, 298, 300, 302, 304, 306, 308, 310, 312, 314, 316, 318, 320, 322, 324, 326, 328, 330, 332, 334, 336, 338, 340, 342, 344, 346, 348, 350, 352, 354, 356, 358, 360, 362, 364, 366, 368, 370, 372, 374, 376, 378, 380, 382, 384, 386, 388, 390, 392, 394, 396, 398, 400, 402, 404, 406, 408, 410, 412, 414, 416, 418, 420, 422, 424, 426, 428, 430, 432, 434, 436, 438, 440, 442, 444, 446, 448, 450, 452, 454, 456, 458, 460, 462, 464, 466, 468, 470, 472, 474, 476, 478, 480, 482, 484, 486, 488, 490, 492, 494, 496, 498, 500, 502, 504, 506, 508, 510, 512, 514, 516, 518, 520, 522, 524, 526, 528, 530, 532, 534, 536, 538, 540, 542, 544, 546, 548, 550, 552, 554, 556, 558, 560, 562, 564, 566, 568, 570, 572, 574, 576, 578, 580, 582, 584, 586, 588, 590, 592, 594, 596, 598, 600, 602, 604, 606, 608, 610, 612, 614, 616, 618, 620, 622, 624, 626, 628, 630, 632, 634, 636, 638, 640, 642, 644, 646, 648, 650, 652, 654, 656, 658, 660, 662, 664, 666, 668, 670, 672, 674, 676, 678, 680, 682, 684, 686, 688, 690, 692, 694, 696, 698, 700, 702, 704, 706, 708, 710, 712, 714, 716, 718, 720, 722, 724, 726, 728, 730, 732, 734, 736, 738, 740, 742, 744, 746, 748, 750, 752, 754, 756, 758, 760, 762, 764, 766, 768, 770, 772, 774, 776, 778, 780, 782, 784, 786, 788, 790, 792, 794, 796, 798, 800, 802, 804, 806, 808, 810, 812, 814, 816, 818, 820, 822, 824, 826, 828, 830, 832, 834, 836, 838, 840, 842, 844, 846, 848, 850, 852, 854, 856, 858, 860, 862, 864, 866, 868, 870, 872, 874, 876, 878, 880, 882, 884, 886, 888, 890, 892, 894, 896, 898, 900, 902, 904, 906, 908, 910, 912, 914, 916, 918, 920, 922, 924, 926, 928, 930, 932, 934, 936, 938, 940, 942, 944, 946, 948, 950, 952, 954, 956, 958, 960, 962, 964, 966, 968, 970, 972, 974, 976, 978, 980, 982, 984, 986, 988, 990, 992, 994, 996, 998, 1000

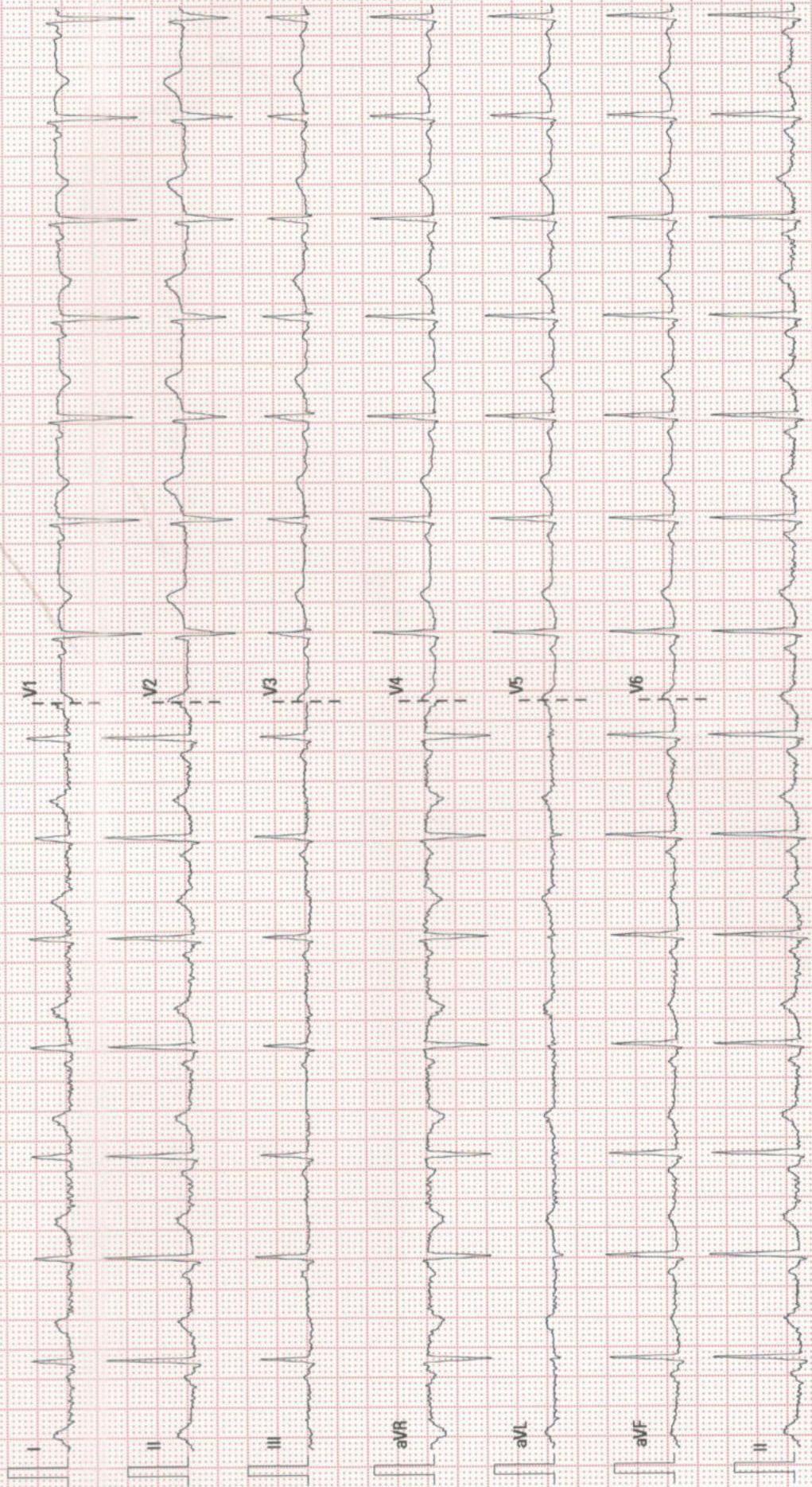
ID: 201-23978
Name: MRS. RATHORE PRIYA
Age: 30 Years
Gender: Female

25-02-2023 11:18:24

Vent. Rate 87 bpm
PR Interval 124 ms
QRS Duration 76 ms
QT/QTc Interval 384/431 ms
P/QRS/T Axes 62/61/29 deg
RV5/SV1 1.213/1.413 mV
RV5 + SV1 2.626 mV
QTc:Hodges

Sinus rhythm
Normal ECG

Unconfirmed Diagnosis



25 mm/s

10 mm/mV

50 Hz

BDR 35 Hz

NARAYANA MSC -SARJAPUR

02.04.00\28.4.1

SN FN-58003

Patient Name : Mrs.RATHORE PRIYA
Age : 30 Years
Referring Doctor : PKG

Patient ID : 201-23978
Sex : Female
Date : 25 .02.2023

ULTRASOUND ABDOMEN AND PELVIS

FINDINGS:

Liver is normal in size (13.5 cm) and echopattern. No intra or extra hepatic biliary duct dilatation. No focal lesions.

Portal vein is normal in size, course and caliber. CBD is not dilated.

Gall bladder is normal without evidence of calculi, wall thickening or pericholecystic fluid.

Pancreas to the extent visualized, appears normal in size, contour and echogenicity

Spleen is normal in size (10.2cm), shape, contour and echopattern. No evidence of mass or focal lesions.

Right Kidney is normal in size (measures 9.5 cm in length & 1.3 cm in parenchymal thickness), position, shape and echopattern. Corticomedullary differentiation is maintained. No evidence of calculi or hydronephrosis.

Left Kidney is normal in size (measures 9.7 cm in length & 1.2cm in parenchymal thickness), position, shape and echopattern. Corticomedullary differentiation is maintained. No evidence of calculi or hydronephrosis.

Retroperitoneum – Obscured by bowel gas.

Urinary Bladder is well distended. Wall thickness is normal. No evidence of calculi, mass or mural lesion.

Uterus is anteverted and normal in size, measures 6.7 x 3.3 x 5.3cm. diffusely altered Myometrial echo textur . Endometrium measures – 5.7mm. Endometrial cavity is empty.

Both ovaries are normal in size and echopattern.

Right ovary: measures 2.2 x 2.1 cm. Left ovary: measures 2.6 x 1.5 cm.

Both adnexa: Normal. No mass is seen.

There is no ascites or pleural effusion.

IMPRESSION:

- UNREMARKABLE STUDY OF ABDOMEN AND PELVIS

Dr. Ananthalakshmi.S
Sonologist



Narayana Hrudayalaya Limited

Above HDFC Bank, 83/3, Doddakanneli, Sarjapura Main Road,
Varthur Hobli, Bangalore - 560035
Tel: + 91 88844 31319. Email : info.sarjapura@narayanahealth.org

