


 बैंक ऑफ बड़ोदा
Bank of Baroda

नाम अर्घा हालदार
Name Argha Halder

कचनपत्र नं. ३
E.C. No. 119377


अर्घा हालदार
Issuing Authority: C.M. (Genl), KZ



अर्घा हालदार
Signature of Holder





APOLLO CLINIC OM TOWER
36C, B.T. ROAD OPP "RBU"
KOL 700002
Ph 033 25565555
033 25563333

K.Z.
 020 91 22 6800 5196 5197 91 22 2652 5147
 - Add: General Manager (Security), Bank of Baroda, Baroda Corporate Centre
 C-26, G Block, Bandra-Kurla Complex, Mumbai-400 051, India
 Phone: 91 22 6800 5196 Fax: 91 22 2652 5147
 Name & Pn (Person to emergency contact) **Madhulika Halder**
9455682218
 Blood Group **B+ve** Allergy **Nil**
 Other health conditions **Black mole on throat**
 Branch Office
 806, Kankaria Zone, Plot No. 362, Road No. 1, Ghatlode, Gandhinagar, Kolkata-700 061



PHOTO CLINIC ON TOWER
 3RD, B.T. ROAD OPP. "RBU"
 KOL. 700005
 033 2586333
 033 2586333

भारत सरकार
GOVERNMENT OF INDIA



अर्घा हल्दर
Argha Halder
जन्म वर्ष/YoB:1985
पुरुष Male



5355 1515 9618

आधार - आम आदमी का अधिकार

APOLLO CLINIC OM TOWER
36C, B.I.ROAD OPP "RBU"
KOL 700002
Ph 033 25565555
033 25563333



भारतीय विशिष्ट पहचान प्राधिकरण
UNIQUE IDENTIFICATION AUTHORITY OF INDIA

पता:

C/O सुशील कुमार

श्रीवास्तव, बडेल रोड, सामने

आकाश पेलेस मैरिज हॉल

नखपेडा बाग, बाराबंकी,

बाराबंकी

उत्तर प्रदेश, 225001

Address:

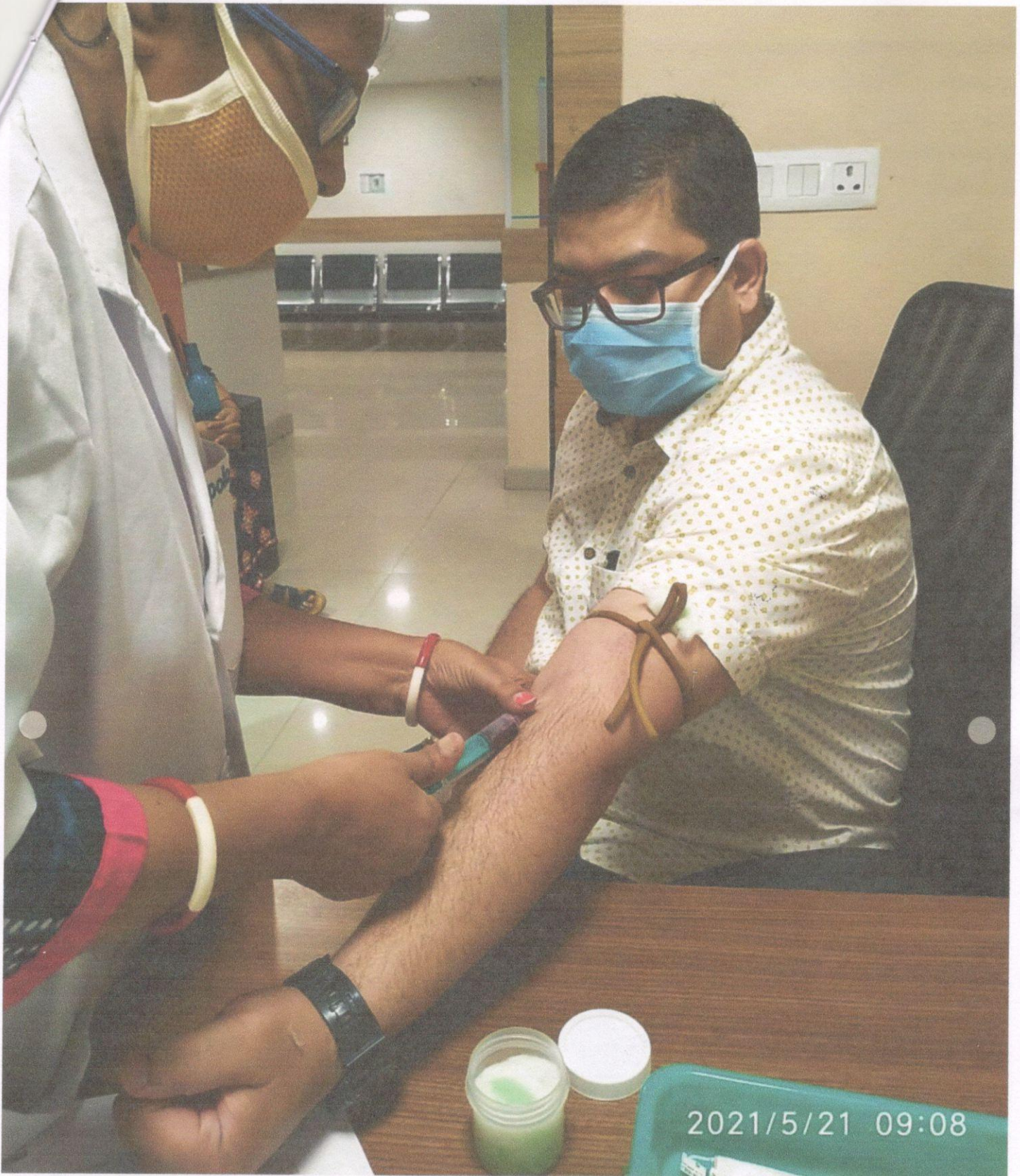C/O Susheel Kumar Srivastava,

bareil road, opposite akash
palace marriage hall lakhpera

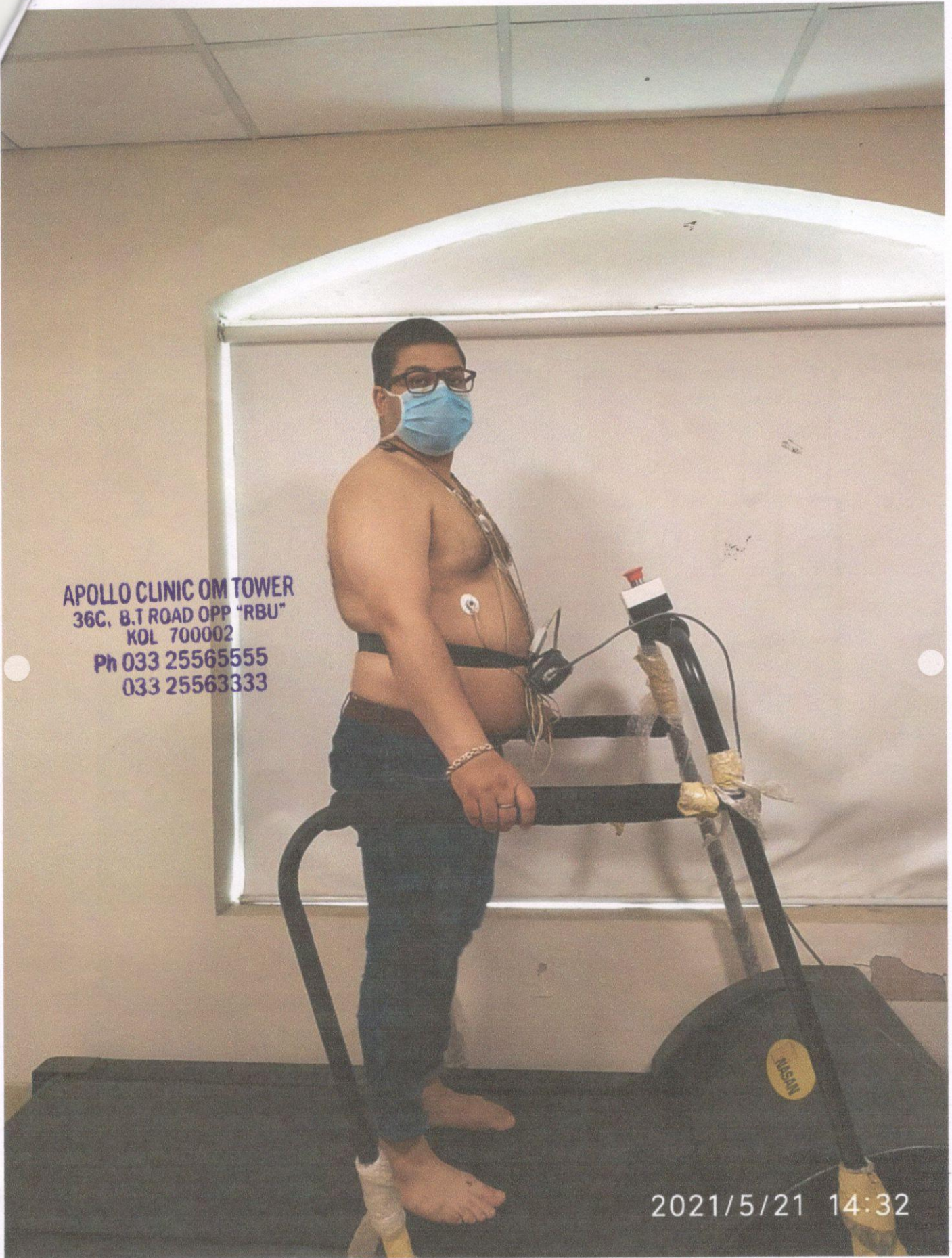
bagh, barabanki, Barabanki

Uttar Pradesh, 225001

Aadhaar - Aam Aadmi ka Adhikar

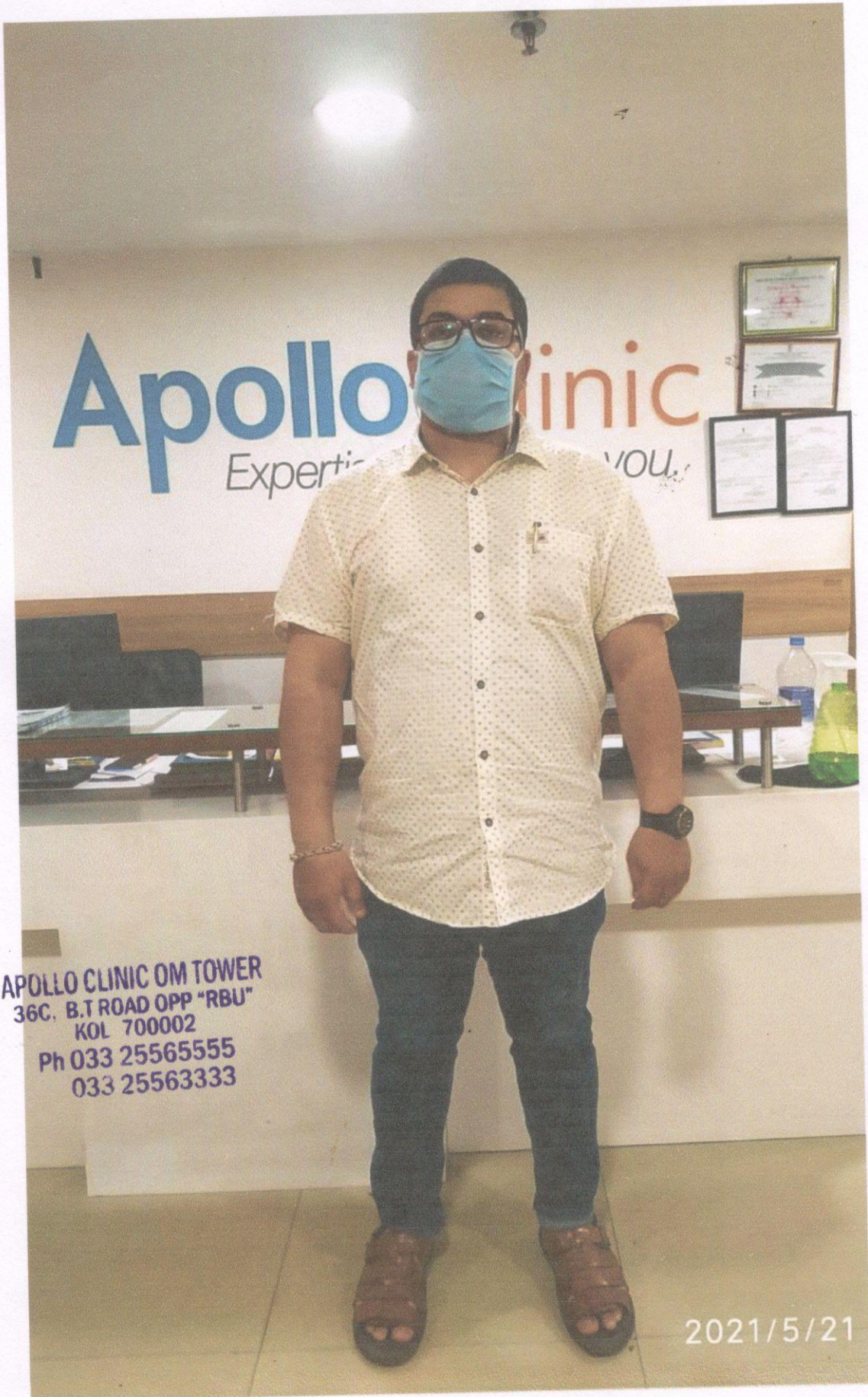

APOLLO CLINIC OM TOWER
36C, B.T ROAD OPP "RBU"
KOL 700002
Ph 033 25565555
033 25563333



APOLLO CLINIC OM TOWER
36C, B.T ROAD OPP "RBU"
KOL 700002
Ph 033 25565555
033 25563333

2021/5/21 14:32



APOLLO CLINIC OM TOWER
36C, B.T ROAD OPP "RBU"
KOL 700002
Ph 033 25565555
033 25563333

2021/5/21

DEPARTMENT OF RADIOLOGY X-RAY REPORT OF CHEST (PA)

MR. NO- FSIN.0000000000

SEX-MALE

NAME-MR.ARGHA HALDER

EXAMINATION DATE-21/05/2021

AGE-35 YRS

REPORT DATE- 21/05/2021

REF.DR.-SELF

FINDINGS:

Bilateral lung fields are clear.

Tracheal shadow is in the midline.

Bilateral CP angle are clear.

Both hilar appear normal.

CTR is normal.

No definite bone fracture is noted.



DR.ARNAB MANDAL

MD, Physician, PGDUS (Delhi) CEPT-USG (WBUHS KOLKATA)
Fellow of Jefferson Ultrasound Radiology and Education Institute
Philadelphia Ex-Radiology Resident (S.E.Railway)
Regd.No:72022(WBMC)

APOLLO CLINIC @ OM TOWER
Opp. of Rabindra Bharati University

Licensee : Satyam Credit Pvt. Ltd.

36C, B.T. Road, Kolkata - 700 002

E-mail : sinthimor@theapolloclinic.com
satyamcreditpvtltd@gmail.com



033 2556 3333



033 2556 5555



+91 98521 66666



+91 74392 97827