

[Redacted Name]





सुहेलता
Snehlata
जन्म तिथि/ DOB: 04/09/1991
महिला / FEMALE




5518 2029 6481

आधार-आम आदमी का अधिकार

*दोने सुलता
(For health checkup purpose
only at Anareja wing here)*

[Redacted Name] पहचान प्राधिकरण
GOVERNMENT OF INDIA



पता:
W/O: इंदरजीत यादव,
रिवाली, अलवर,
राजस्थान - 301701

Address:
W/O: Inderjeet Yadav, Riwali, Alwar,
Rajasthan - 301701

5518 2029 6481

Aadhaar-Aam Admi ka Adhikar



THAREJA SONOGRAPHY CENTRE

1, Ram Kuteer, Company Bagh Road, ALWAR - (0144) 2700184



This report is not valid for MLC Purpose

Ref. No.

Date..... 12/03/2023

Name of Patient MRS SNEHLATA Age 32 yrs Sex F
Ref.By: SELF

Sonography Report – abdomen

LIVER: Size: RL: 11.6 Cm. L. L.: 4.6 Cm.
Margins: Regular I. H. B. R.: ND
Parenchyma: Echo

C. B. D. Size: 3.4 mm. LUMEN: Clear
P.V. Size: mm LUMEN: Clear

GALL BLADDER Size 5.8 X 1.8 cm
Wall thickness: N LUMEN: Clear
PANCREAS: N
SPLEEN: 8.3 cm
KIDNEYS: Size:- Right : 9.3 X 4.0 cm Left: 9.5 X 4.2 cm

Pelvicacal System : | N
Cortico – Medu. Diff : |

RETROPERITONEUM : Not seen
LYMPH – NODES :
PLEURAL EFFUSION :
ASCITES :


URINARY BLADDER:
Prevoiding Volume : 98 C. C.
Wall Thickness N Lumen: Clear
UTERUS

Size:- 4.4 X 2.5 cm Shape : N Position:-
Endometrium, 6.0 mm
Endometrial Cavity: N
Myometrium : N

Cervix: size 1.9 cm Canal – N
OVARIESE : size N Right :- N Left: - N
Other :- NIL

Conclusion :- Normal study

Thanks,


Dr. Savita Thareja
Reg. No. 7600
RMC

Enclosed: Photo - 2

PLEASE NOTE: INTESTINAL PATHOLOGY CAN NOT BE RULE OUT.

This is only an opinion, not an diagnosis, which should be clinically co-related. No procedure/surgery should be undertaken simply on the basis of this opinion because Ultrasound accuracy is only 96%.

* Subject to Alwar jurisdiction. * Not valid for medico-legal purpose.



THAREJA NURSING HOME

1, Ram Kuteer Company Bagh Road, ALWAR - 301001 (Raj.)
Mob. 9982111801, Ph. 0144-2700184, 2331842
E-mail: drmnthareja@yahoo.com



Name Snehleela Age 31 yrs Yr OPD/UHID Date 12 March
Address Mobile No.....

VITALS	B.P.	Pulse	Temp.	Wt.	Ht.	Allergies
--------	------	-------	-------	-----	-----	-----------

Complaints

Patient came for routine dental check up.

Findings

Cavious $\frac{5}{4}$
Decayed $\frac{1}{3}$

Investigation

Adv:- RVE

Treatment

Adv:- Restoration / RCT $\frac{5}{4}$.

DR. M.N. THAREJA

7233 (RMC)
Male Infertility Specialist

DR. SAVITA THAREJA

7600 (RMC)
Female Infertility Specialist

DR. JAYANT THAREJA

A-0824 (RSDC)
M.D.S.
Oral & Maxillo - Facial Surgery
Ex Resident Trauma Centre,
AIIMS, Delhi

DR. SHIVANI THAREJA

10807 / 31220 (RMC)
Ophthalmologist
Cornea Specialist

DR. PRERNA THAREJA

A-3574
MDS (Endodontics)
Root Canal Specialist
Ex Resident
AIIMS, Jodhpur

DR. H.R. GUPTA

1744 (RMC)
Senior Consultant
M.S. Gen Surgeon

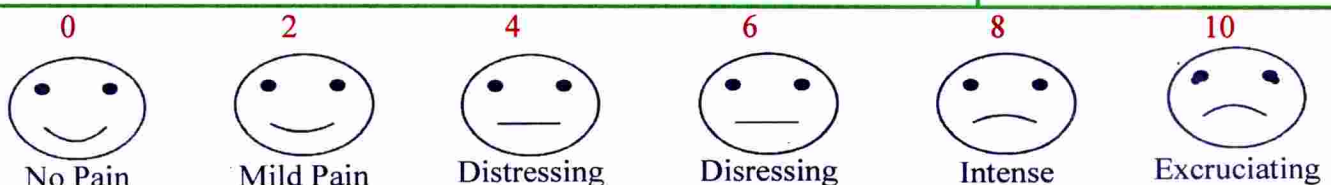
DR. VARUN SAPRA

Reg. No. 70990 (DMC)
MBBS DNB ORTHO, D.ORTHO
Joint Replacement &
Arthroscopy Surgeon

Dr. Jayant

Note: RGHS Facility For Dental and Eye Department

Pain Scale





THAREJA NURSING HOME

1, Ram Kuteer Company Bagh Road, ALWAR - 301001 (Raj.)
Mob. 9982111801, Ph. 0144-2700184, 2331842
E-mail: drmnthareja@yahoo.com



Name Mrs Sneh late Age 31/F Yr OPD/UHID Date 12/3/23
Address Mobile No.....

VITALS	B.P.	Pulse	Temp.	Wt.	Ht.	Allergies
--------	------	-------	-------	-----	-----	-----------

Complaints

Routine eye check up

Findings

*VA - 6/6
WG - 6/6
NB*

*8/L
Cornea clear B/E*

*Color vision - WNC
- WNC*

Treatment

*Adv
both eyes within normal
limit*

- DR. M.N. THAREJA**
7233 (RMC)
Male Infertility Specialist
- DR. SAVITA THAREJA**
7600 (RMC)
Female Infertility Specialist
- DR. JAYANT THAREJA**
A-0824 (RSDC)
M.D.S.
Oral & Maxillo - Facial Surgery
Ex Resident Trauma Centre,
AIIMS, Delhi
- DR. SHIVANI THAREJA**
10807 / 31220 (RMC)
Ophthalmologist
Cornea Specialist
- DR. PRERNA THAREJA**
A-3574
MDS (Endodontics)
Root Canal Specialist
Ex Resident
AIIMS, Jodhpur
- DR. H.R. GUPTA**
1744 (RMC)
Senior Consultant
M.S. Gen Surgeon
- DR. VARUN SAPRA**
Reg. No. 70990 (DMC)
MBBS DNB ORTHO, D.ORTHO
Joint Replacement &
Arthroscopy Surgeon

Shivani
Dr. Shivani Thareja
M.S. (OPHTHAL)
Fellow (CORNEA)
L.V. Prasad Eye Institute
CORNEA CONSULTANT

Note: RGHS Facility For Dental and Eye Department

Pain Scale

0	2	4	6	8	10
No Pain	Mild Pain	Distressing	Disressing	Intense	Excruciating



THAREJA NURSING HOME



DIGITAL X-RAY, OPG, COMPUTERISED ECG & EEG, DIAGNOSTIC LABORATORY EQUIPED WITH COMPUTERISED AUTO ANALYZER & CBC

1, Ram Kuteer, Company Bagh Road, ALWAR - 301001 (Raj.) Ph: 0144-2700184, 2331842

PROPOSAL NO.

Patient Name **MRS SNEHLATA**
Ref. By Dr. **M. N. THAREJA**

Date 12-03-23
Age 31 Yrs.
Sex F

Details of packages		Patients report	Units	Normal value
HB		12.6	gm%	M-11.5-18, F-11.5-16.5
TRBC		4.14	million /cu mm	M-4.0-5.5, F-3.9-5.6
TWBC		5400	cu mm	4000-11000
DLC	Polymorphs	60	%	42-75
	Lymphocytes	32	%	20-50
	Eosinophil	08	%	1-6
ESR		02	mm 1 st Hr.	M-0-9, F-0-20
Platelets		199000	Lack / cu mm	1.5-4
PCV		36.2	%	37-54
MCV		87.4	Cubicmicrons	86-98
MCH		30.4	Picograms	26-34
MCHC		34.8	%	32-36
Blood Grouping & Rh Factor		"O"Rh+VE		
BUN		11.5		04-20
S.Creatinine		0.86	Mg/100ml	0.9-1.4 mg /100 ml
HBsAg		-		
HIV I & II		-	Elisa Method	
HbA1C		4.7	%	4-6%
PSA		-	Ng/ml	Less Then 4.0 Ng/ml

Details of packages		Patients report	Units	Normal value	
LFT	GGTP	23	U/L	5-60	
	SGOT	14	Units / ml	Upto 40	
	SGPT	17	Units / ml	Upto 40	
	S. Bilirubin	Total	0.7	mg%	Upto 1.2
		Direct	0.4	mg%	0-0.25
		Indirect	0.3	mg%	
		T. Protein	7.6	Gm%	6.2-8.3
	S. Albumin	4.4	Gm%	3.2-5.3	
	Globulin	3.2	Gm%		
	Alkaline phosphate		IU/L	60 - 170	
S. Calcium	-	Gm%	8.5-10.5		
Uric Acid	3.8	Mg%	2.5-7 mg%		
Blood Sugar Fasting		89.0	Mg%	60-110/ mg %	
Blood Sugar PP			Mg%	Upto 160	
Lipid Profile	S. Cholesterol	259	mg%	120-220	
	S. Triglycerides	128	mg/ml	Upto 170	
	HDL Cholesterol	49	IU/L	30 to 70	
	LDL cholesterol	184	IU/L	450 at 37° C	
	VLDL	25	mg %	Upto 35	

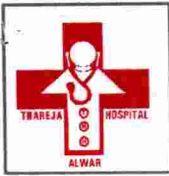Routine Urine Analysis

Physical/ Chemical		Microscopic:	
Appearance	Clear	RBCs	Nil
Specific Gravity	1010	WBCs	1-2/ HPF
Ph	ACIDIC	Epith. Cells	2-3/HPF
Albumin	NIL	Casts	Nil
Glucose	NIL	Crystals	Nil
Ketones	----	Bacteria	Nil
Blood	Nil	Urine Sugar pp	-

Signature of Technician

Signature of Doctor

This Report is not Valid for Medical Legal Purpose



THAREJA NURSING HOME



DIGITAL X-RAY, OPG, COMPUTERISED ECG & EEG, DIAGNOSTIC LABORATORY EQUIPED WITH COMPUTERISED AUTO ANALYZER & CBC

1, Ram Kuteer, Company Bagh Road, ALWAR - 301001 (Raj.) Ph: 0144-2700184, 2331842

Name : **SNEHLATA** age **31** Sex : **FEMALE**

Ref. By : **DR M.N. THAREJA** Lab No. : Date : **March 12, 2023**

HORMONES & MARKERS

Test	Value	Units	Biological Ref. Values
T3 (Total Triiodothyronine)	0.97	ng/dL	0.60-1.81 ng/dL Adults
T4 (Total Thyroxine)	5.50	µg/dL	3.2-12.60 µg/dL : Adults
TSH (Thyroid Stimulating Hormone)	1.72	µIU/mL	Adults : 0.35-5.50 µIU/mL

Interpretation of TSH :-

Children

0 Days : 1.0~39.0 uIU/mL
 5 days : 1.7~9.1 uIU/mL
 1 year : 0.4~8.6 uIU/mL
 2 years : 0.4~7.6 uIU/mL
 3 years : 0.3~6.7 uIU/mL
 4-19 years : 0.4~6.2 uIU/mL

Adults

20-54 years : 0.35-5.50 uIU/mL
 55-87 years : 0.5-8.9 uIU/mL

Pregnancy

1st Trimester : 0.30 - 4.50 µIU/mL
 2nd Trimester : 0.50 - 4.60 µIU/mL
 3rd Trimester : 0.80 - 5.20 µIU/mL

Interpretation of TSH :-

Children

3.20 - 34.6 µIU/mL 1- 2 Days
 0.70 - 15.4 µIU/mL 3 - 4 Days
 0.70 - 9.10 µIU/mL 15 Days - 5 Months
 0.70 - 6.40 µIU/mL 5 Months - 20 Years

Pregnancy

0.30 - 4.50 µIU/mL 1st Trimester
 0.50 - 4.60 µIU/mL 2nd Trimester
 0.80 - 5.20 µIU/mL 3rd Trimester

Method : **Fluorescence Immunoassay Technology**

Sample Type : **Fresh Blood Serum**

Remarks :

Primary malfunction of the Thyroid gland may result in excessive (hyper) or Low (hypo) release of T3 or T4. In addition, as TSH directly affect thyroid function, malfunction of the pituitary or the hypothalamus influences the thyroid gland activity.

Disease in any portion of the thyroid-pituitary-hypothalamus system may influence the level of T3 and T4 in the blood, in Primary Hypothyroidism,

TSH levels are significantly elevated, while in secondary and tertiary hypothyroidism, TSH levels may be low. In addition, in Euthyroid sick syndrome, multiple alterations in serum thyroid function test findings have been recognized.

Signature of Technician


Signature of Doctor



THAREJA NURSING HOME



DIGITAL X-RAY, OPG, COMPUTERISED ECG & EEG, DIAGNOSTIC
LABORATORY EQUIPED WITH COMPUTERISED AUTO ANALYZER & CBC

1, Ram Kuteer, Company Bagh Road, ALWAR - 301001 (Raj.) Ph: 0144-2700184, 2331842

PROPOSAL NO.

Date 12/03/2023

Patient Name SNEHLATA

AGE 31 Yrs.

Ref. By Dr. M. N. THAREJA

Sex F

PART - X-RAYED : X-RAY CHEST PA VIEW

REPORT : X-RAY CHEST P.A. VIEW

:- Chest is bilaterally symmetrical.

:- C.P. Angles are clear.

CONCLUSSION: NORMAL STUDY

Signature of Technician

M. N. Thareja
Signature of Doctor

This Report is not Valid for Medical Legal Purpose

Patient Name: **Suehlafe**

HR 65/min

AXIS: P 40°
QRS -14°
T 17°

SINUS RHYTHM
LEFTWARD AXIS
OTHERWISE NORMAL ECG

Age: **31** M

Weight: **51** kg

Height: **170** cm

Intervals:
RR 949 ms
PR 126 ms
QRS 92 ms
QT 416 ms
QTc 429 ms

P (I) 0.12 mV
S (V1) -0.77 mV
R (V5) 0.59 mV
Sokol. 1.46 mV

UNCONFIRMED REPORT

12/3/23

10 mm/mV

10 mm/mV

