



Summary

Ref. By :
Medication :
Objective :

Protocol : BRUCE
History :

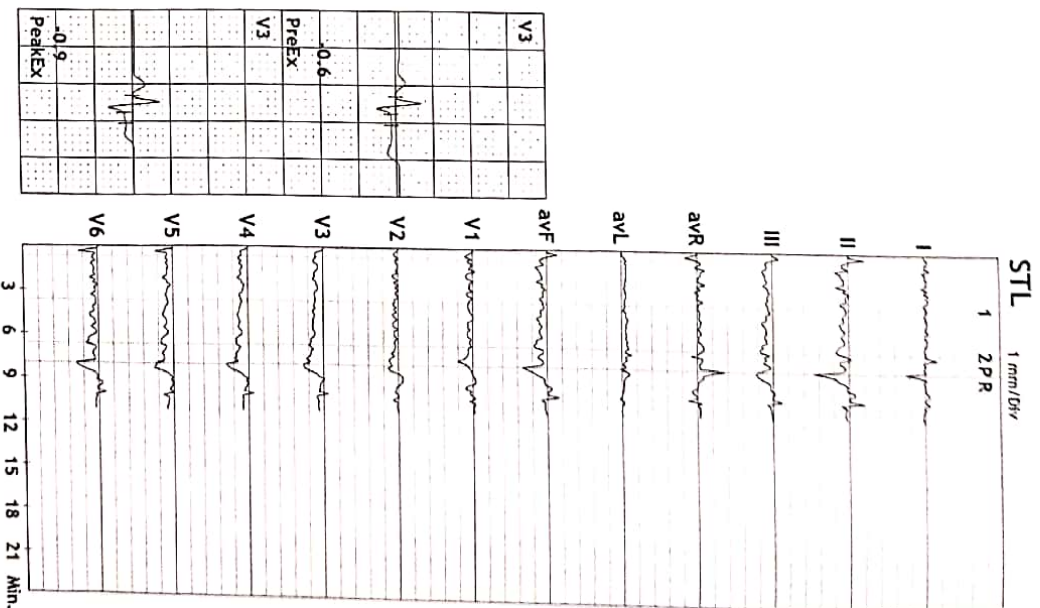
KSHIPRA SCANS & LABS
2B COURT CHOURAHA UDAIPUR
2208102561/MRS ANKITA RAJPUROHIT 34 Yrs/Female 0 Kg/0 Cms
Date: 27-Aug-2022 01:34:28 PM

Stage	StageTime (Min:Sec)	PhaseTime (Min:Sec)	Speed (mph)	Grade (%)	METS	H.R. (bpm)	B.P. (mmHg)	R.P.P. x100	PVC	Comments
Supine					1.0	98	120/80	117	-	
Standing					1.0	104	120/80	124	-	
ExStart					1.0	104	120/80	124	-	
Stage 1	3:00	3:01	1.7	10.0	4.7	104	120/80	124	-	
Stage 2	3:00	6:01	2.5	12.0	7.1	134	130/90	174	-	
PeakEx	1:20	7:21	3.4	14.0	8.5	167	140/100	233	-	
Recovery	1:00		0.0	0.0	1.2	121	140/100	169	-	
Recovery	3:00		0.0	0.0	1.0	83	120/80	99	-	

Findings :

Exercise Time : 7:21 minutes
 Max HR attained : 167 bpm 90% of Max Predictable HR 186
 Max BP : 140/100(mmHg)
 Workload attained : 8.5 (Fair Effort Tolerance)
 No significant ST segment changes noted during exercise or recovery.
 No Angina/Arrhythmia/S3/murmur
 Final Impression : Test is negative for inducible ischaemia.
 Maximum Depression: 7:21

Advice/Comments:





12 Lead + Median

2208102561/MRS ANKIT AHIRAR/ROHIT
34 Yrs/Female
0 Kg/0 Cms
Date: 27-Aug-2022 01:34:28 PM

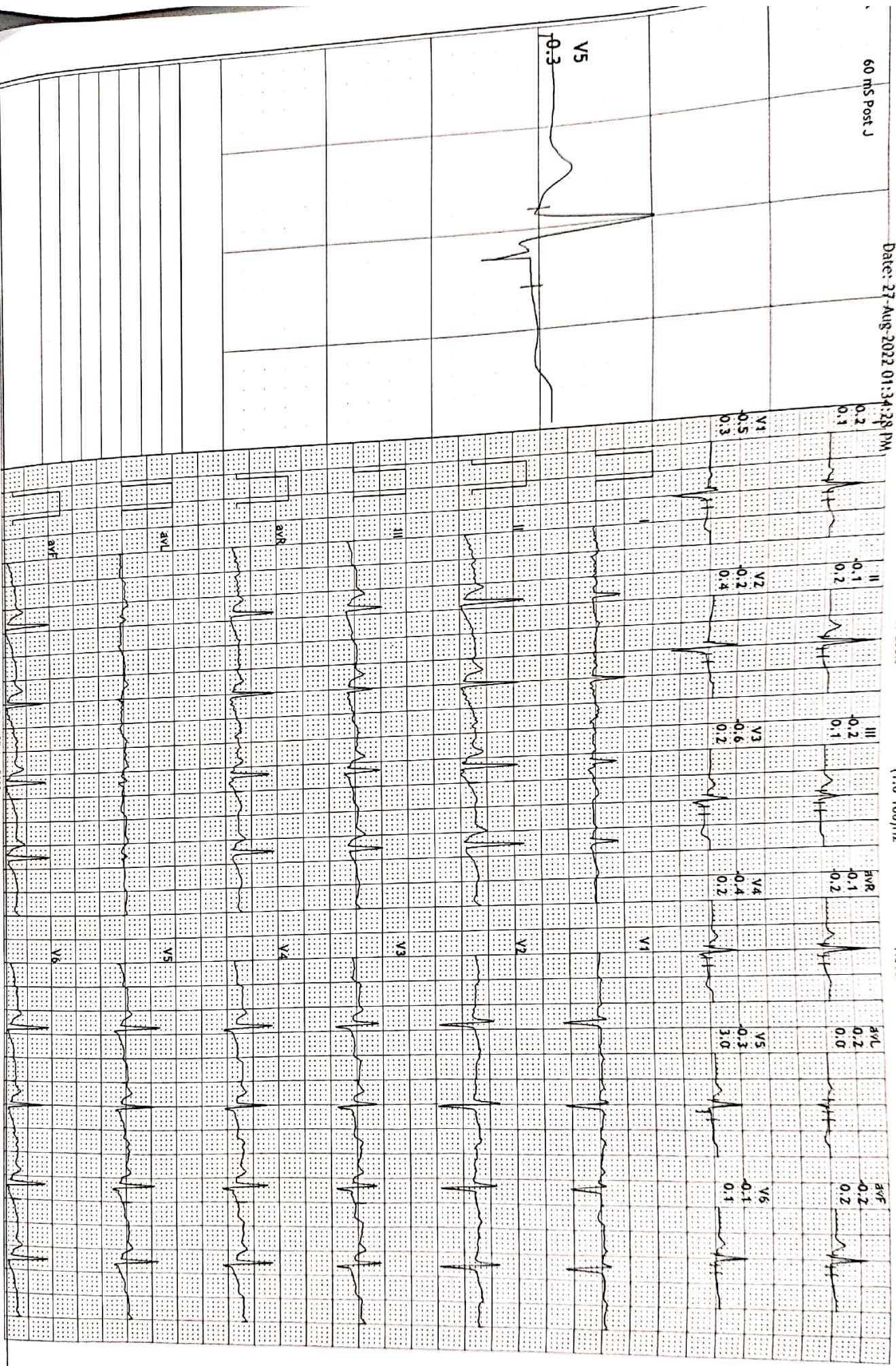
MHR: 52% of 186
Speed: 0.0 mph
Grade: 0.0%

KSHIPRA SCANS & LABS
2B COURT CHOURAHA UDAIPUR

RAW ECG
BRUCE
1.0-100/Hz
Ex Time 00:32
BLC : On
Notch : On

Supine
10.0 mm/mV
25 mm/Sec.

60 MS Post J





12 Lead + Median

KSHIPRA SCANS & LABS

2B COURT CHOURAHA UDAIPUR

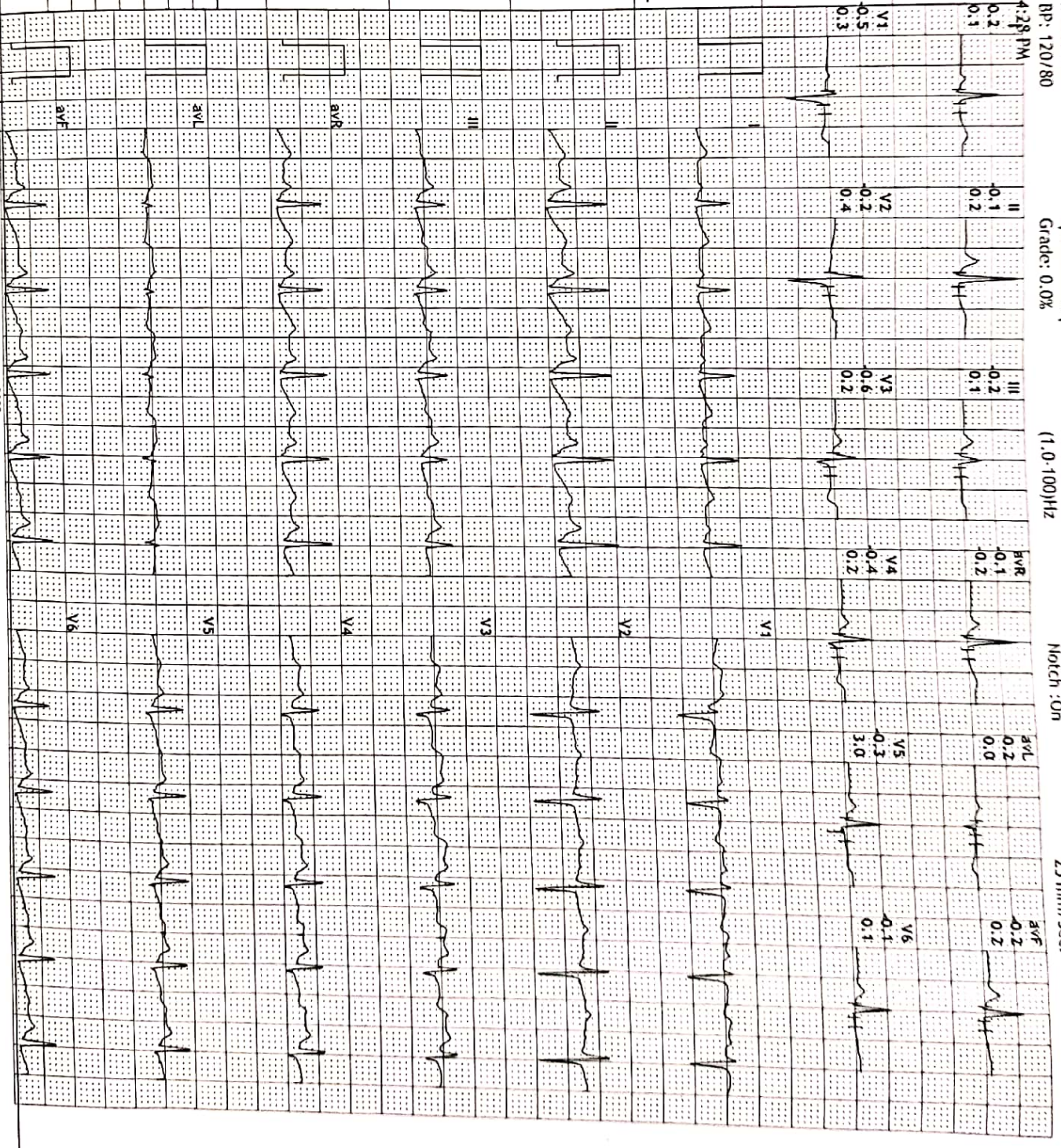
2208102561/MRS ANKITARA RAJADHIT
34 Yrs/Female
0 Kg/0 Cms
Date: 27-Aug-2022 01:34:28 PM

MPHR: 55% of 186
Speed: 0.0 mph
Grade: 0.0%

Raw ECG
BRUCE
(1.0-100)Hz
Ex Time 00:37
BLC :On
Notch :On

Standing
10.0 mm/mV
25 mm/Sec.

4X 60 ms Post J





12 Lead + Median

2208102561/MRS ANKIT AIRA
34 Yrs/Female
0 Kg/0 Cms
Date: 27-Aug-2022 01:34:29 PM

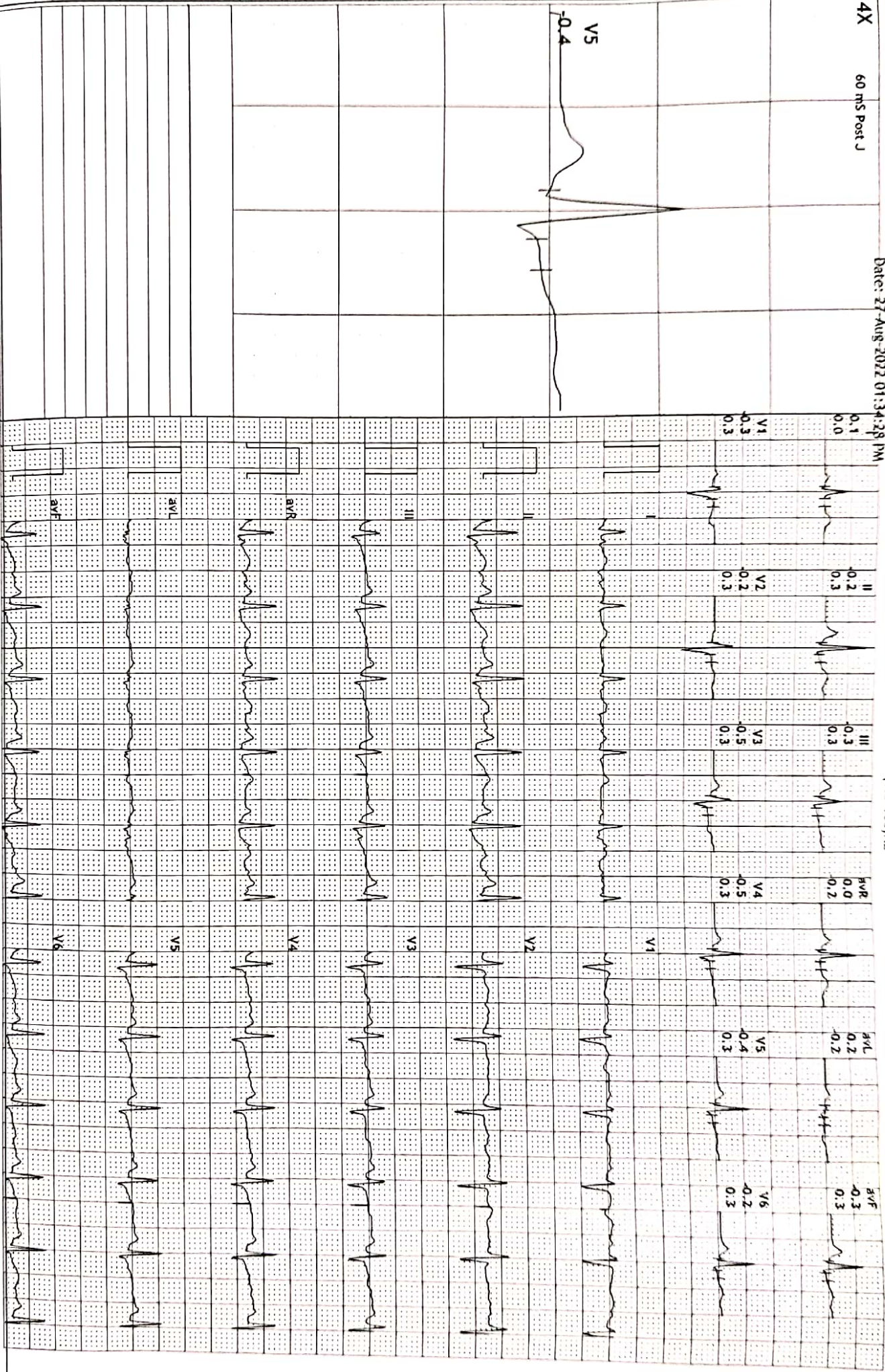
MLTS: 4.7
RP: 120/80
MPHR: 55% of 186
Speed: 1.7 mph
Grade: 10.0%

KSHIPRA SCANS & LABS
2B COURT CHOURAHIA UDAIPUR

Raw ECG
BRUCE
(1.0-100)HZ
Ex Time 03:00
BLC : On
Notch : On

BRUCE: Stage 1 (3:00)
10.0 mm/mV
25 mm/Sec.

4X 60 ms Post J





12 Lead + Median

2208102561/MRS ANKITA RAJESH KHANDE
34 Yrs/Female
0 Kg/0 Cms
Date: 27-Aug-2022 01:34:28 PM

MPHR: 72% of 186
Speed: 2.5 mph
Grade: 12.0%

KSHIPRA SCANS & LABS
2B COURT CHOURAHIA UDAIPUR


Raw ECG
BRUCE
(1.0-100)HZ

Ex Time 06:00
BLC : On
Notch : On

BRUCE: Stage 2(3:00)
10.0 mm/mV
25 mm/Sec.

4X 60 ms Post J

V5
-0.8





12 Lead + Median

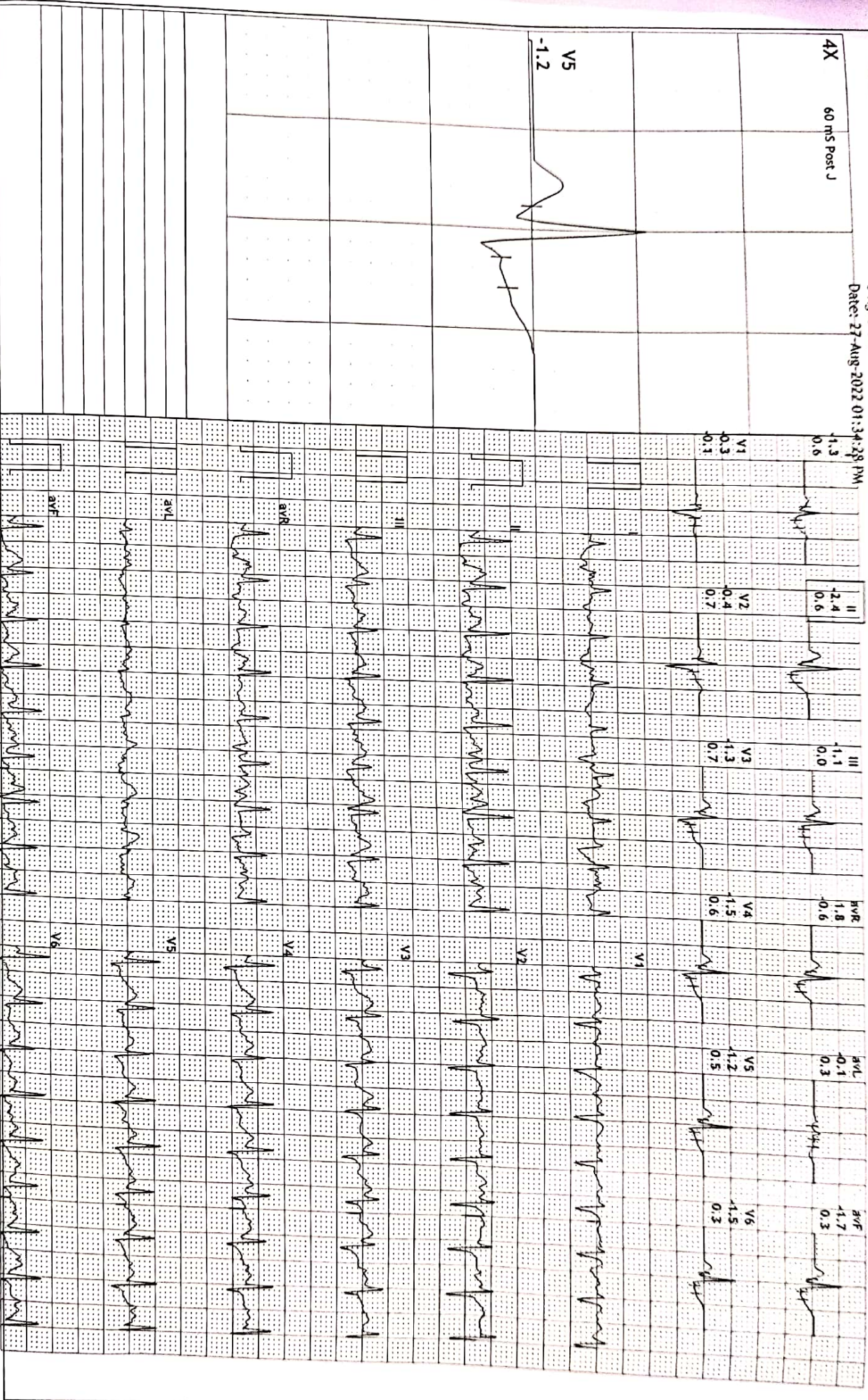
2208102561/MRS ANKITA RAJESH KHAT
34 Yrs/Female
0 Kg/0 Cms
Date: 27-Aug-2022 01:34:28 PM
METs: 8.5
BP: 140/100

MPHR: 89% of 186
Speed: 3.4 mph
Grade: 14.0%

KSHIPRA SCANS & LABS
2D COURT CHOURAHA UDAIPUR
Raw ECG
BRUCE
(1.0-100)HZ

Ex Time 07:20
PLC : On
Notch : On

BRUCE: PeakEx(1:20)
10.0 mm/mV
25 mm/Sec.





12 Lead + Median

2208102561/MRS ANKITA RAJESH KHATH
34 Yrs/Female
0 Kg/0 Cms
Date: 27-Aug-2022 01:34:29 PM

MIHR: 65% of 186
Speed: 0.0 mph
Grade: 0.0%

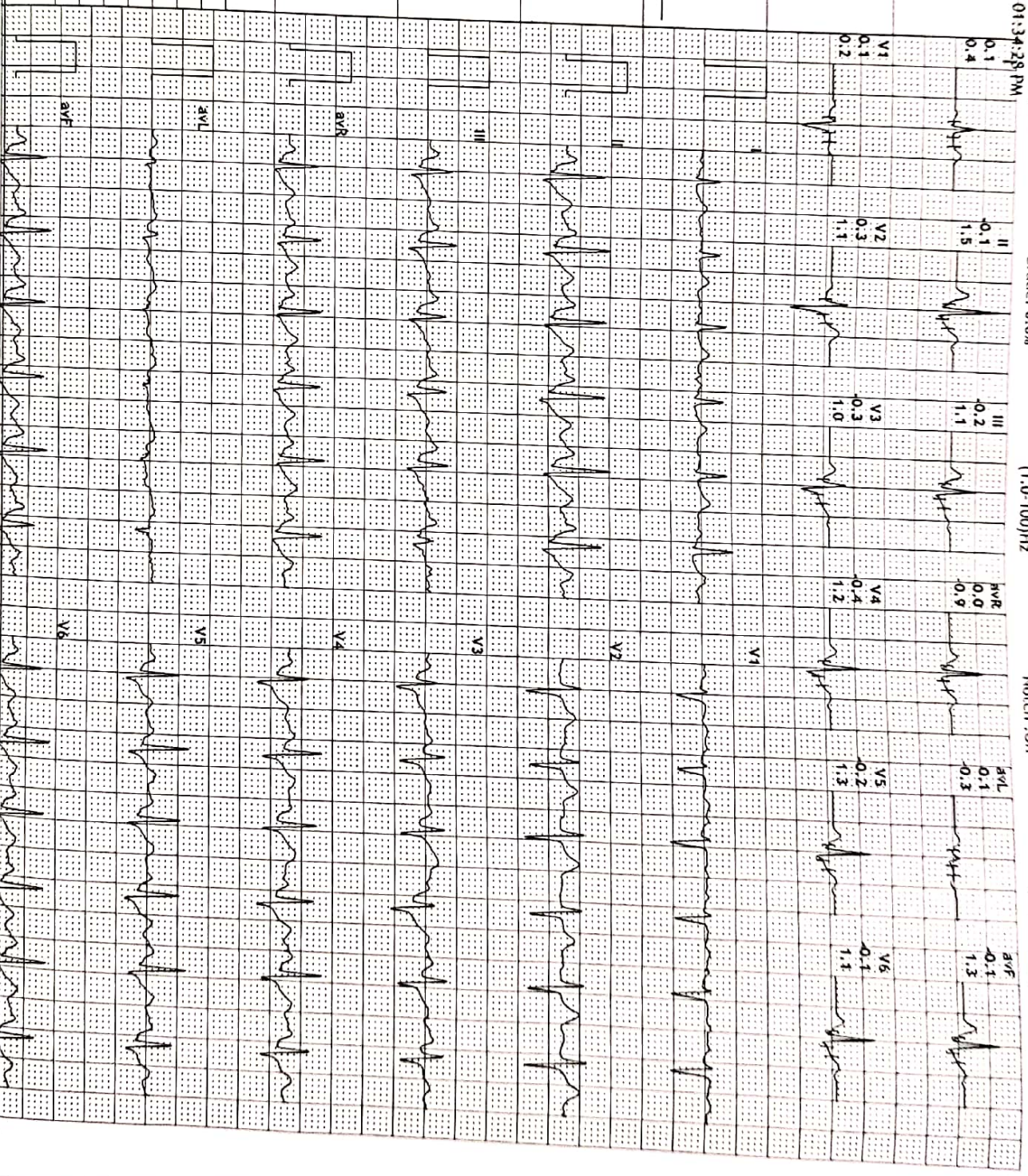
KSHIPRA SCANS & LABS
2B COURT CHOURAHA UDAIPUR

Raw ECG
BRUCE
(1.0-100)HZ
Ex Time 07:21
BLC : On
Notch : On

Recovery(1:00)
10.0 mm/mV
25 mm/Sec.

4X 60 MS Post J

V5 -0.2





12 Lead + Median

2208102561/MRS ANKITA RAJ RAOHIT
34 Yrs/Female
0 Kg/0 Cms
Date: 27-Aug-2022 01:34:29 PM

MPHR: 44% of 186
Speed: 0.0 mph
Grade: 0.0%

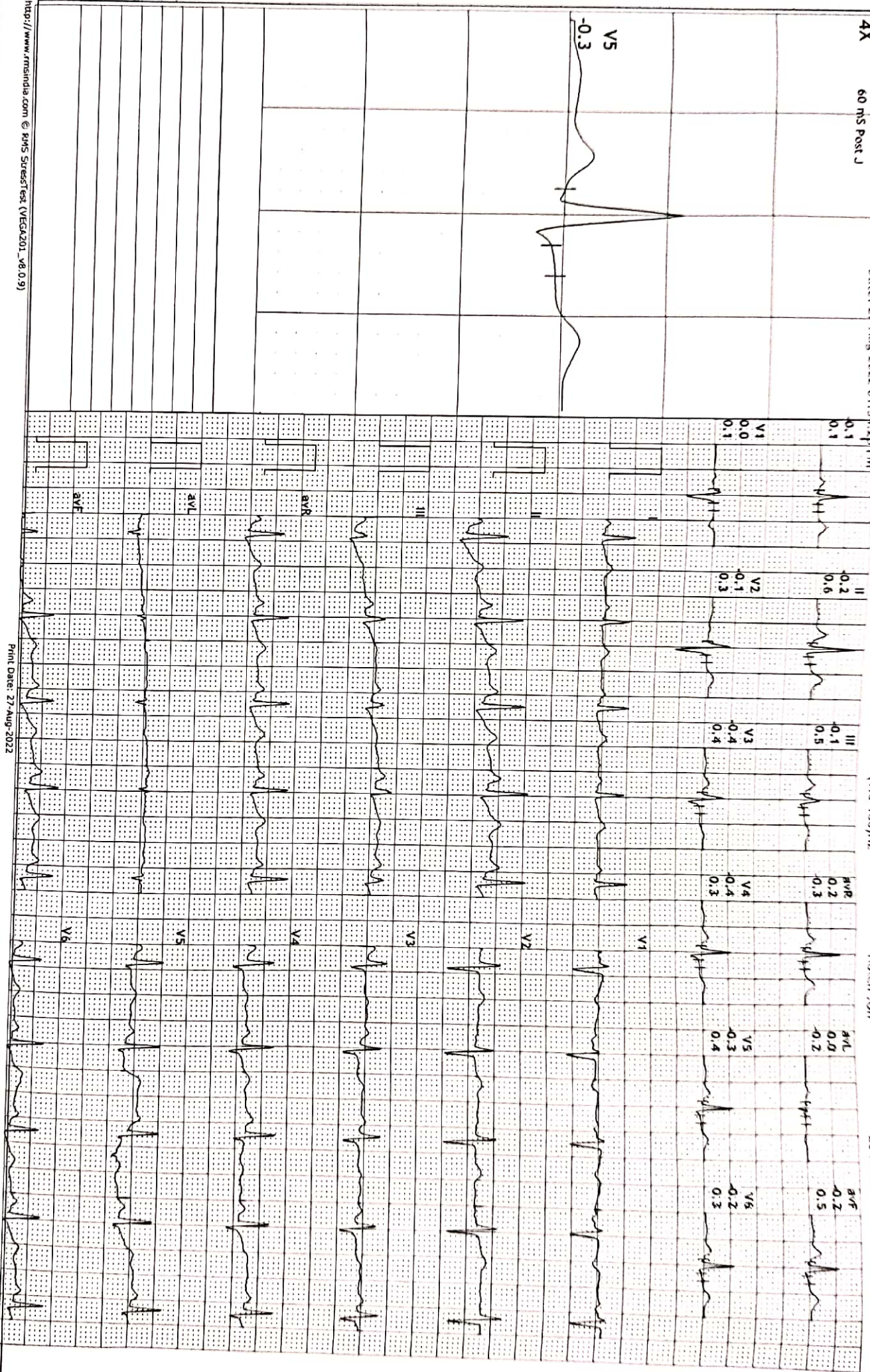
KSHIPRA SCANS & LABS
2B COURT CHOURAHIA UDAIPUR

Raw ECG
BRUCE
(1.0-100)HZ
Ex Time 07:21
BLC : On
Notch : On

Recovery(3:00)
10.0 mm/mV
25 mm/Sec.

4X 60 ms Post J

V5
-0.3



MER- MEDICAL EXAMINATION REPORT

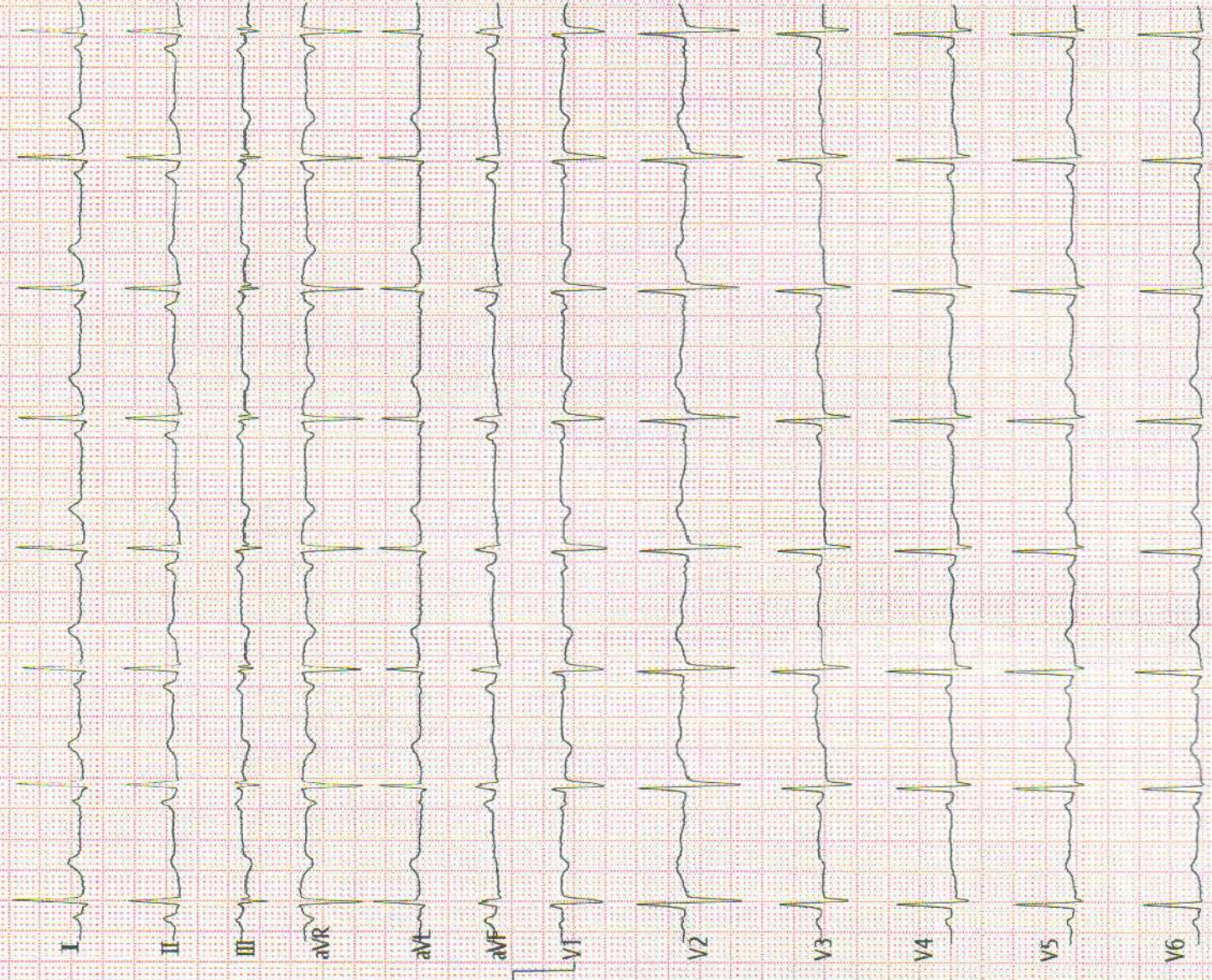
Date of Examination	27/08/2022		
NAME	Ankita		
AGE	37	Gender	F
HEIGHT(cm)	5.9	WEIGHT (kg)	58
B.P.	95/85		
ECG	Normal		
X Ray	Normal		
Vision Checkup	Normal		
Present Ailments			
Details of Past ailments (If Any)			
Comments / Advice : She /He is Physically Fit	unfit		

Dr. BHARAT JAIN
CONSULTANT RADIOLOGIST

[Handwritten Signature]

Signature with Stamp of Medical Examiner

10mm/mV



<ECG Analysis Result>

800 Normal Sinus Rhythm
 611 T Abnormal(Flat T)

Vent. Rate(BPM) : 74
 PR Int.(ms) : 127
 P/QRS/T Int.(ms) : 88 92 170
 QT/QTc Int.(ms) : 371 416
 P/QRS/T Axis(Deg.) : 65 27 16
 RV1/SV5 Amp.(mV) : 0.20 0.15
 RV5/SV1 Amp.(mV) : 0.98 0.66

*** Borderline Abnormal ECG ***

Technician: V2 33

Note: Unconfirmed Report Need to Review

ST LEVEL(mV)

I	II	III	aVR	aVL	aVF
-0.01	-0.03	-0.01	+0.02	+0.00	-0.02
V1	V2	V3	V4	V5	V6
-0.01	-0.01	-0.05	-0.04	-0.03	-0.03

CARDIOPRINT

<ANKITA JI > 751610215315 F 34Y

/ cm/Kg

ml/v

Name	: Ankita	Age	: 32Yrs. / F
Thanks To	: Mediwheel wellness	Date	: 27-08-2022

ULTRASOUND STUDY OF WHOLE ABDOMEN

LIVER :

Liver is normal in size, shape & echotexture. No focal mass lesion is seen. Intra hepatic biliary radicles are normal. Portal vein is normal in caliber.

GALL BLADDER :

Gall bladder is well distended. The wall thickness appears normal. No evidence of calculus or mass lesion is seen. C.B.D. appears normal.

PANCREAS :

Pancreas is normal in size, shape & echotexture. No focal mass lesion is seen.

SPLEEN :

Spleen is normal in size, shape & echotexture. No focal mass lesion is seen.

BOTH KIDNEYS :

Both kidneys are normal in size, shape & echotexture. Renal parenchyma appears normal. No evidence of hydronephrosis, calculus or cortical scarring is seen in either kidney.

Right kidney measures : 10.2 x 4.8 cms.

Left kidney measures : 8.98 x 4.9 cms.

URINARY BLADDER :

Urinary bladder is well distended and appears normal in contour. The wall thickness appears normal.

UTERUS :

Uterus is retroverted, normal in size, shape and echotexture. It measures 6.5 x 4.5 x 3.4 cms. Endometrial appears normal and measures 7.4 mm.

BOTH OVARIES :

Both ovaries are normal in size, shape and echotexture.

Right ovary measures: 2.9 x 2.0 cms.

Left ovary measures: 3.2 x 1.9 cms.

No obvious abdominal lymphadenopathy is seen.

No free fluid is seen in peritoneal cavity.

OPINION:

- No significant abnormality is seen.


Dr Bharat Jain

MD (Radio-Diagnosis)
Consultant Radiologist

(This report is not valid for any Medico-legal purpose)

ENCL:- PCPNDT Registration Certificate is printed on the back side of this report.

2-B Ground Floor, Court Choraha, Main Road Tehsil ke Samne, Udaipur 313001 (Raj.),

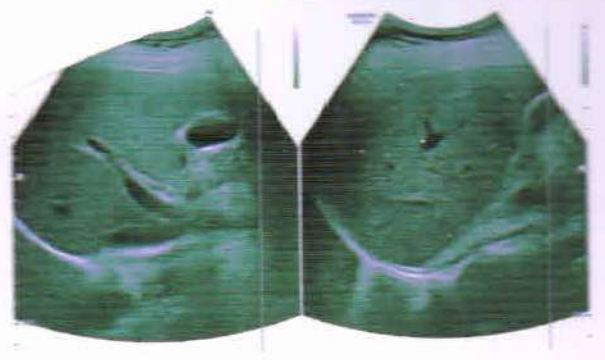Mob. : 7229961115, 7229970005, 7229901188

(24 x 7 Customer Service) Email : kshipralabsudaipur@gmail.com

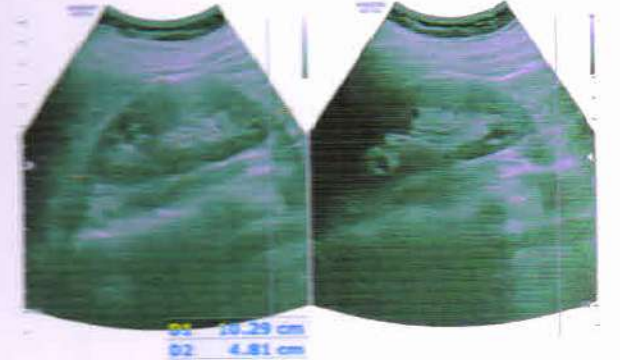REGISTRATION (1) and 8(2))
 B (S) and 8(2))
 (1) of the Pre-natal Diagnostic
 Act, 1994 (57 of 1994), the
 Ultrasonic clinic has
 being Pre-natal Diagnostic
 the aforesaid

KSHIPRA LABS UDAIPUR

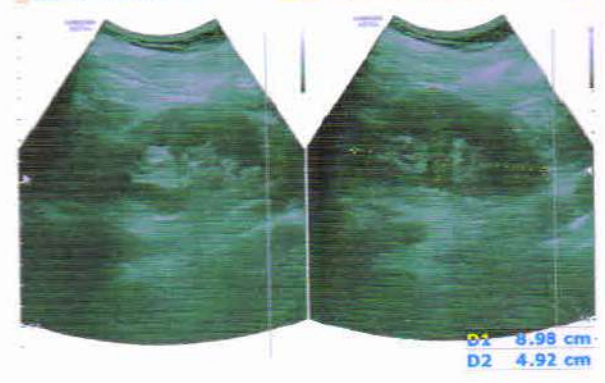27-08-2022-0020
 ANKITA J
 KSHIPRA LABS UDAIPUR
 CAI-7A / Abdominal / PR 27Hz
 MI 1.4 Ts 0.1
 27-08-2022 01:14:21 PM



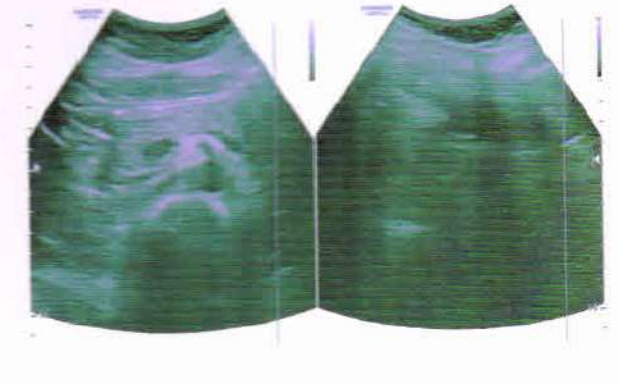27-08-2022-0021
 ANKITA J
 KSHIPRA LABS UDAIPUR
 CAI-7A / Abdominal / PR 27Hz
 MI 1.4 Ts 0.1
 27-08-2022 01:14:34 PM



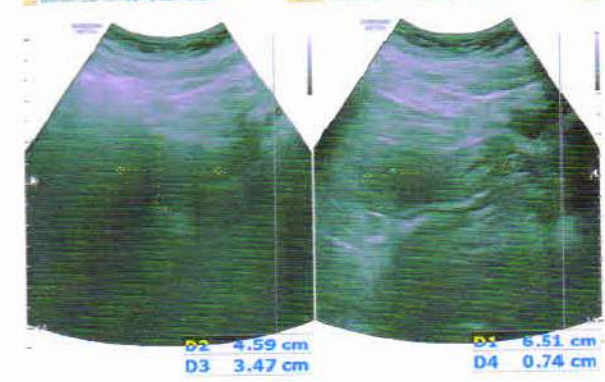
27-08-2022-0022
 ANKITA J
 KSHIPRA LABS UDAIPUR
 CAI-7A / Abdominal / PR 27Hz
 MI 1.4 Ts 0.1
 27-08-2022 01:14:21 PM



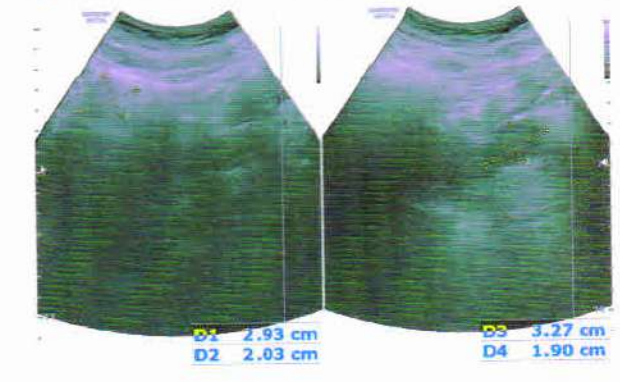
27-08-2022-0023
 ANKITA J
 KSHIPRA LABS UDAIPUR
 CAI-7A / Abdominal / PR 27Hz
 MI 1.4 Ts 0.1
 27-08-2022 01:15:04 PM



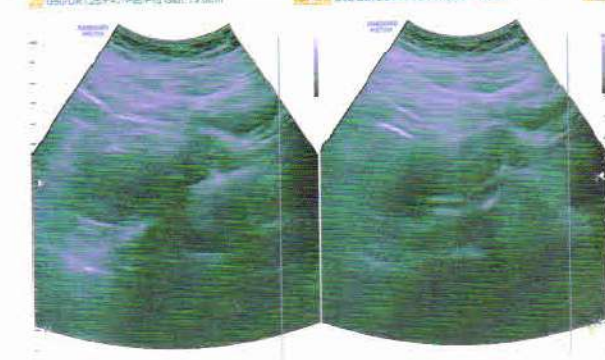
27-08-2022-0024
 ANKITA J
 KSHIPRA LABS UDAIPUR
 CAI-7A / Abdominal / PR 27Hz
 MI 1.4 Ts 0.1
 27-08-2022 01:15:43 PM



27-08-2022-0025
 ANKITA J
 KSHIPRA LABS UDAIPUR
 CAI-7A / Abdominal / PR 27Hz
 MI 1.4 Ts 0.1
 27-08-2022 01:16:08 PM



27-08-2022-0026
 ANKITA J
 KSHIPRA LABS UDAIPUR
 CAI-7A / Abdominal / PR 27Hz
 MI 1.4 Ts 0.1
 27-08-2022 01:16:16 PM



Name	:	Ankita	Age	:	32 Yrs. / F
Thanks To	:	Self	Date	:	27.08.2022

X-RAY CHEST (PA VIEW)

Both lung fields appear normal.

No e/o Koch's lesion or consolidation seen.

Both CP angles appear clear.

Both domes of diaphragm appear normal.

Heart size and aorta are within normal limits.

Bony thorax under vision appears normal.

Both hila appear normal.


Consultant Radiologist

(This report is not valid for any Medico-legal purpose)

MRS Ankita

32/F

22/08/22


Ref for Eye check up.

-VA
 19
 6p

NU A < N/G
 N/G

relax vision - (N)

Accp < -0.50 DS (G)6
 -0.50 X100' (G)6


Dr. SHARVA PANDYA
 M.B.B.S., M.S. (Ophth.)
 Jai Drishti Eye Hospital
 Udaipur (Raj.)

Cosmetology Partner :



PAP SMEAR

Maturity Index : 00/35/65

Inflammation : +

Bacteria : ++

RBC : Absent

Endocervical Cells : present

Dysplasia : NIL

Neoplasia :NIL

Trichomonas / Candida :NOT SEEN

Impression : Inflammatory smear

Bethesda Category : Negative for Intraepithelial Lesion or Malignancy (NILM)