



Bharath
Scans & Labs

32nd
YEAR OF SERVICE

Name : Mr.Ramasubramaniyan
Age : 67 Years
Sex : Male
Doctor : Dr.Mediwheel




SID No : KIL029614

Collected Date : 28/05/2022
Reported Date : 28/05/2022

FINAL TEST REPORT

TEST DESCRIPTION	RESULT	BIOLOGICAL REFERENCE INTERVAL	UNITS
ENDOCRINOLOGY:-			
TOTAL T3 (CLIA)	128.2	Adults : 86 - 192	pg/ml
TOTAL T4 (CLIA)	7.26	Adults : 4.5 - 12.5	ug / dl
TSH 3 RD GEN (CLIA)	3.85	Adults : 0.3 - 5.0	mIU/ml

End of the Report


Mr. Deepan Suresh,
Sr. Technician.

Health Check up Booking Request(bobS12176),Package Code(PKG10000236),Beneficiary Code(420)



011-41195959

[Email:wellness@mediwheel.in](mailto:wellness@mediwheel.in)

Name : Rama subramanian
Age : 67
Gender : Male
Member Relations : Spouse
Package Name : Medi-Wheel Full Body Health Checkup Male Above 40
Package Code : PKG10000236
User Location : Tamil Nadu,VEPPATHUR,612105
Contact Details : 9629747747
Booking Date : 24-05-2022
Appointment Date : 28-05-2022

Member Information			
Booked Member Name	Age	Gender	Cost(In INR)
Rama subramanian	67	Male	Cashless
Total amount to be paid			Cashless

Please login to your account to confirm the same. Also you mail us for confirmation

Package Name : Medi-Wheel Full Body Health Checkup Male Above 40 - Includes (40)Tests

Ecg, TSH, X-ray Chest, Stress Test (tmt)/ 2d Echo, Blood Sugar Postprandial, Psa(for Male), Dental Consultation, Creatinine, Serum, A:g Ratio, Blood Group, Total Cholesterol, Triglycerides, Fasting Blood Sugar, Ultrasound Whole Abdomen , Glycosylated Haemoglobin (hba1c), Hdl, Vldl, Urine Analysis, LDL, Total Protine, General Consultation, HDL/ LDL ratio, GGT(Gamma-glutamyl Transferase), Eye Check-up consultation, ALP (ALKALINE PHOSPHATASE), Uric Acid, AST/ALT Ratio, Serum Protein, CBC with ESR, Stool Analysis, Urine Sugar Fasting, Urine Sugar PP, T3, T4, Cholesterol Total / HDL Ratio, BUN, BUN/Creatinine Ratio, Bilirubin Total & Direct and Indirect, Albumin, Globulin

Tests included in this Package

BHARATH SCANS & LABS

34, Rajappa Nagar, 4th Street Near Pillai & Sons Maruthi Showroom

Medical College Road, Thanjavur - 613 007.

Contact No.04362 273388 +91 96009 73038 +91 89033 31106

Patient Name: Mr.Rama Subramanian

Sl.No.211/MAY/2022

Age: 67 Yrs

Sex: Male

Date: 28.05.2022

Referred By Dr.MEDI WHEEL BENIFICIARY NAME:PKG10000236

TEST NAME	PATIENT REPORT	LAB NORMAL
COMPLETE HAEMOGRAM		
WBC	8.9	4.0 - 11.0 cumm
RBC	4.5	2.5 - 5.5 millions
HGB	13.7	8.0 - 17.0 GMS/ dl
HCT	41	26.0 - 50.0 %
M C V	102	86.0 - 110.0 fl
M C H	27	26.0 - 38.0 Pg
M C H C	36	31.0 - 37.0 g / dl
PLATELET COUNT	3,23,000	150000-400000 cumm
LYMPHOCYTES	39	5 - 55 %
MIXED CELLS	6	1 - 20 %
NEUTROPHILS	55	45 - 95 %
LYMPH	6.5	10 * 3 ul
MIXED	9.2	10 * 3 ul
NEUTR	8.9	10 * 3 ul
R D W	4.0	%
P D W	10.5	fl
M P V	7.4	fl
PI LCR	18	%
E S R 30 MINUTES	3	MM
E S R 60 MINUTES	7	<10MM
LIPID PROFILE		
Total Cholesterol	189	125 - 200 mg / dl
HDL - C	43	30 - 50 mg / dl
LDL - C	125	90 - 150 mg / dl
Triglycerides	149	60 - 160 mg / dl
V.L.D.L	36	30 - 60 mg / dl
R.F.1	4.3	
R.F.2	2.9	

BHARATH SCANS & LABS

34, Rajappa Nagar, 4th Street Near Pillai & Sons Maruthi Showroom

Medical College Road, Thanjavur - 613 007.

Contact No. 04362 273388 +91 96009 73038 +91 89033 31106

Patient Name: **Mr.Rama Subramanian**

S1.No.211/MAY/2022

Age: **67 Yrs**

Sex: **Male**

Date: **28.05.2022**

Referred By **Dr.MEDI WHEEL BENIFICIARY NAME:PKG10000236**

TEST NAME	PATIENT REPORT	LAB NORMAL
CREATININE	1.1	0.5 - 1.5 mg/dL
BLOOD UREA NITROGEN(BUN)	31	15 - 35 mg/dL
HBA1C	5.6%	5.0 - 6.0
URIC ACID	4.9	3.4 - 7.0 mg/dl
HBSAG	NEGATIVE	
HIV I & II	NEGATIVE	
LIVER FUNCTION TEST		
Total Billirubin	0.9	Upto 1.2 mg/dl
Direct Bilirubin	0.3	Upto 0.4 mg/dl
Indirect Bilirubin	0.6	
S.G.O.T	33	Upto 35 U/L
S.G.P.T	27	Upto 40 U/L
Alkaline Phosphatase	195	150 - 250 IU/L
Total Protein	7.1	6.0 - 8.0 g/dl
Albumin	4.1	3.8 - 5.0 g/dl
Globulin	3.0	2.5 - 3.5 g/dl
A/g Ratio	1.3	
GGTP	27	10 - 30 IU/L
GLUCOSE FASTING	89	60 - 90 mg / dl
GLUCOSE POST PRANDIAL	110	90 - 150 mg/ dL
PSA	2.7	
URINE SUGAR[F]	NIL	
URINE SUGAR[PP]	NIL	
URINE COMPLETE EXAM		
COLOUR	PALE YELLOW	
PH	7.4	
SPECIFIC GRAVITY	1.019	
SUGAR	NIL	
ALBUMIN	NIL	
BILE SALT	NEGATIVE	
BILE PIGMENT	NEGATIVE	
ACETONE	NEGATIVE	
PUS CELLS	3-4	

BHARATH SCANS & LABS

34, Rajappa Nagar, 4th Street Near Pillai & Sons Maruthi Showroom

Medical College Road, Thanjavur - 613 007.

Contact No. 04362 273388 +91 96009 73038 +91 89033 31106

Patient Name: **Mr.Rama Subramanian**

Sl.No.211/MAY/2022


Age: 67 Yrs

Sex: Male

Date: 28.05.2022

Referred By Dr.MEDI WHEEL BENIFICIARY NAME:PKG10000236

TEST NAME	PATIENT REPORT	LAB NORMAL
EPITHELIAL CELLS	1-2	
R B C	NIL	
CASTS	NIL	
CRYSTALS	NIL	
BACTERIAL RODS	NIL	



Dr.KOMALA. G. MD.,
Consultant



Name	Mr.Rama subramanian	ID	135/05/2022
Age&Sex	67Year : Male	Date	28-05-2022
Ref Dr	MEDIWHEEL	Study Name	General Abdomen

General Abdomen

Liver: 9.3 cm

Liver filled with homogeneous parenchymal echoes.
No abscess or mass lesion in the liver.

Gallbladder: 7.1 cm

Gallbladder walls appeared normal. No calculi seen in the gallbladder.
Common duct appeared normal. No calculi seen in the common duct.

Spleen: 8.0 cm

Spleen appeared normal.

Pancreas:

Pancreas appeared normal.

Aorta:

Aorta appeared normal.
No para aortic lymphadenopathy.
No free fluid in the peritoneal cavity.

KUB:

Cortex and collecting system of both kidneys appeared normal.
Multiple calculi seen.
Adrenal glands appeared normal.

Right Kidney measured 9.1 X 5.2 cm.

Left Kidney measured 8.8 X 4.8 cm.

Ureters appear normal on both sides. No dilatation seen.

Bladder appeared not well filled.

Prostate appeared normal and measures 3.7 x 3.0 cm.

No intravesical enlargement of prostate seen.





Bharath
Scans & Labs

32nd
YEAR OF SERVICE

IMPRESSION:

**BILATERAL MULTIPLE NON OBSTRUCTIVE NEPHROLITHIASIS- CALYCES NOT DILATED ,
RIGHT KIDNEY SHOWS ONE CALCULUS IN THE UPPER POLE ONE IN THE MID POLE
EACH 5 MM.**

**LEFT KIDNEY SHOWS ONE CALCULUS IN THE UPPER POLE AND TWO IN THE MID POLE
EACH 7 MM.**

URINARY BLADDER NOT WELL FILLED NO CALCULUS,

PROSTATE NORMAL .

NORMAL APPEARING LIVER, GALLBLADDER, COMMON DUCT, PANCREAS, SPLEEN, AORTA.

Sonologist

Dr. Christina Joseph, M B B S., DO., PG Dip in USG.,



bharathprimex@gmail.com



www.bharathscans.com

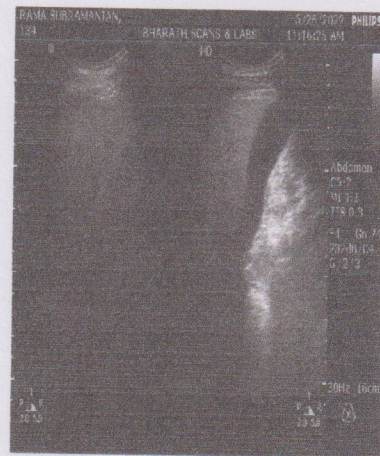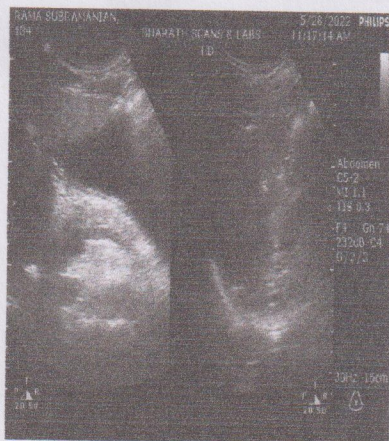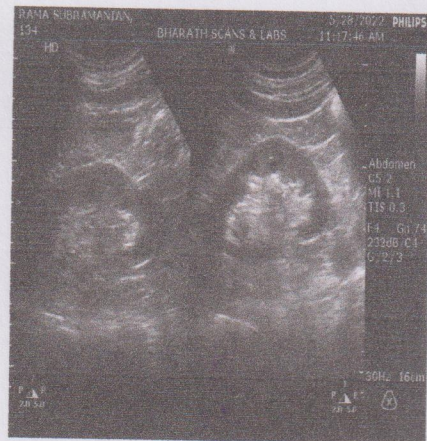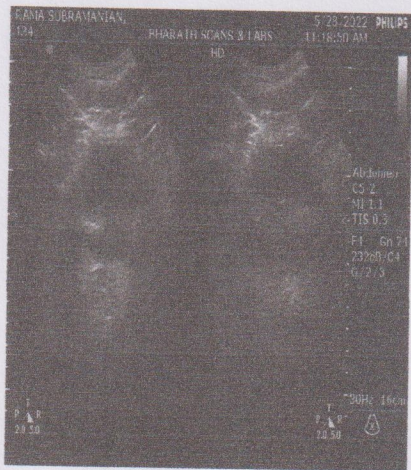


**34, Rajappa Nagar, 4th Street,
Near Pillai and Sons Maruti Showroom,
Medical College Road, Thanjavur - 613007.**



**04362 273388
+91 96009 73038
+91 99527 31106**

Name	Mr.Rama subramanian	ID	135/05/2022
Age&Sex	67Year : Male	Date	28-05-2022
Ref Dr	MEDIWHEEL	Study Name	General Abdomen





Bharath
Scans & Labs

Date: 28.05.2022

32nd
YEAR OF SERVICE

Name of patient Mr.Rama subramanian Age: 67Yrs Sex :M

X RAY – CHEST – PA VIEW

-
- Both the lung fields & CP angles are clear.
- Hila are normal.
-
- Heart size & bony cage appear normal

IMPRESSION

➤ Normal X – ray chest.

Dr. R.UMA MAHESHWARI, M.B.B.S,MD,(Pead), M.C.C.,
Consultant Pediatrician / Neonatologist,
Registered Medical Practitioner,
Reg. No: 99456.

ЛОТНІВАМ ДІАГНОСТИС СЕНТРЕ

МР РАМА СУВРАМАЙІАІ І ЕТ У 3003 М 381213055 05:28 РМ

Р

RAMASUBRAMANIAN

ID: 552/05/2022

Male 67 yrs 64 Kg 158 cm

28/05/2022 14:36

25mm/s
10 mm/mV

BHARATH SCANS & LAB

LINKED MEDIANS

BRUCE Pre-Exercise Supine

PHASE TIME 00:49

STAGE TIME 00:10

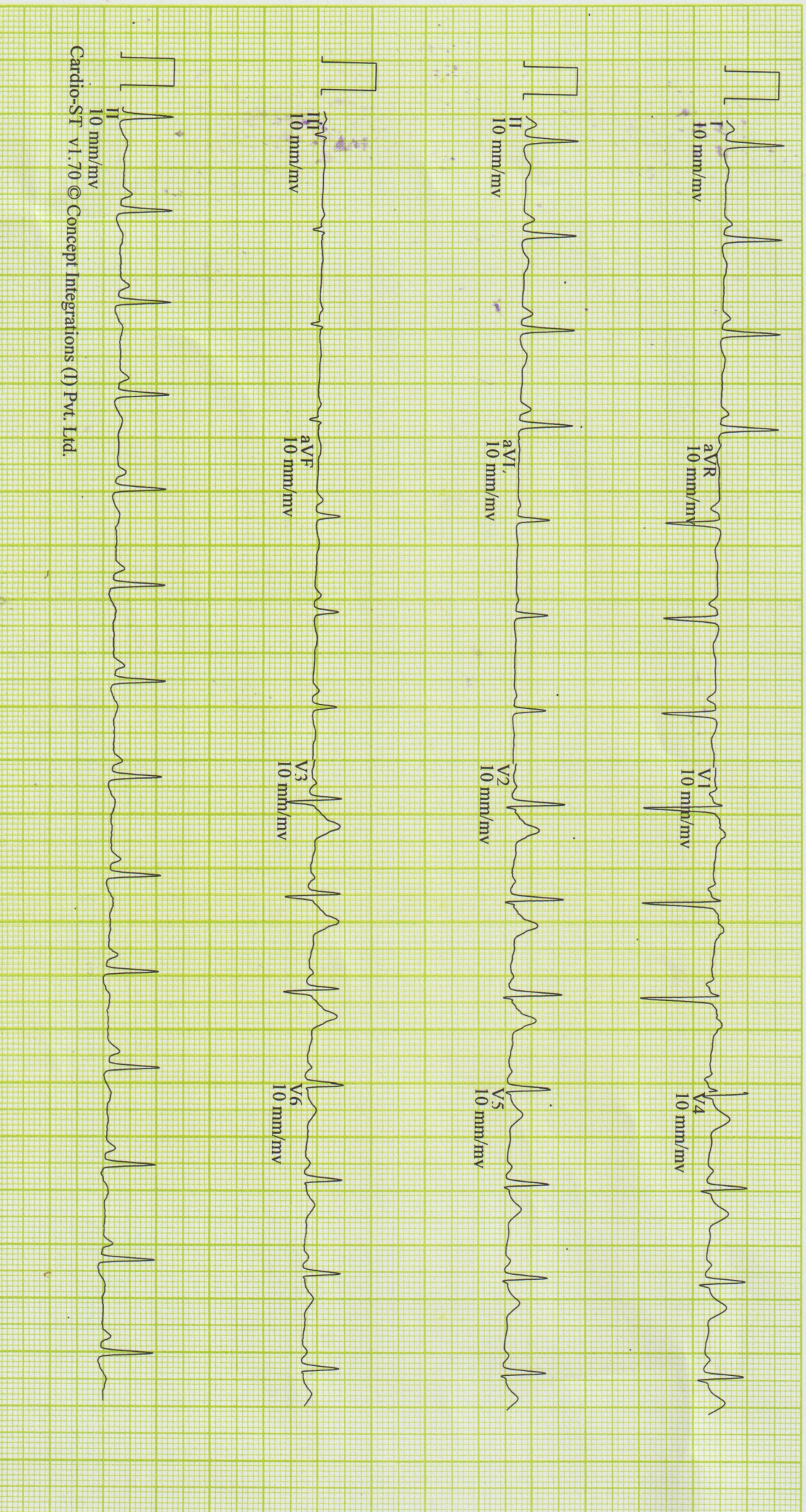
Speed : - km/h Grade : - %

WKLD : 1.0 METS

HR : 81

BP : 124/78

LEAD	ST (mm)	LEAD	ST (mm)
I	-0.1	V1	1.1
II	0.0	V2	1.7
III	0.2	V3	-2.4
aVR	0.0	V4	1.6
aVL	-0.1	V5	1.2
aVF	0.2	V6	0.8



10 mm/mv
10 mm/mv
10 mm/mv
10 mm/mv
10 mm/mv
10 mm/mv
10 mm/mv
10 mm/mv
10 mm/mv
10 mm/mv
10 mm/mv
10 mm/mv

P. Ramasubramanian

Cardio-ST v1.70 © Concept Integrations (I) Pvt. Ltd.