

ECHO Report

Date: 25/02/2023

Patient Details

Patient ID –

Name- MR GANESH KUMAR

Age- 31 YEARS

Gender- MALE

Referral BY - MEDIWHEEL

Doctor Incharge

DR. MAHESH PADSALGE

Clinical Status of Patient -

Finding description -

- 1. Poor Echo Window, Tachycardia During Study.**
- 2. Normal LV systolic function.**
- 3. No RWMA.**
- 4. All cardiac valves are structurally normal.**
- 5. Trivial MR, Trivial PR, NO AR.**
- 6. No PAH.**
- 7. Normal RV systolic function.**
- 8. No clot/vegetation/pericardial effusion.**
- 9. No coarctation of aorta.**

Chamber Dimensions-M mode Findings

LVID (Diastole) 35-56(mm) - 31.00
 IVS (Diastole) 8-12(mm) - 11.00
 LVPWT (Diastole) 6-11(mm) - 10.00
 LVEF (%) - 60%

LVID (Systole) 24-42(mm) - 21.00
 IVS (Systole) 14-42(mm) - 13.00
 EPSS - 3.00
 LVFS (%) - 32.00

LV Volume (Diastolic)(mm³)
 Meridional Wall Stress in System

LV Volume (Systolic)(mm³)
 Cubed LV Volume in Diastole (mm³)

Cubed LV+ myocardial volume (mm³)

Velocity of circumferential
 Shortening (mm)

Aortic root 22-37(mm) - 28.00
 Left Atrium Length (mm) - 30.00
 Left Atrium Volume (mm³)
 RV size Normal
 Normal
 RV volume (mm³)
 Normal
 Pericardium Normal
 Effusion None
 Resp Variation Present
 Predicted RV Systolic Pressure

Left Atrium Width (mm)
 Left Atrium Area (mm²)
 RV Function

RA Size

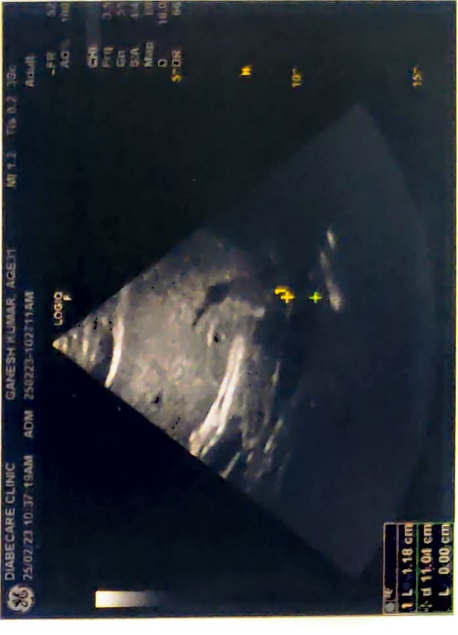
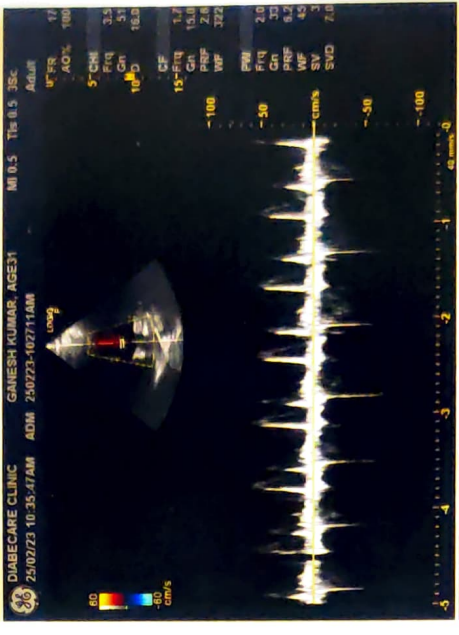
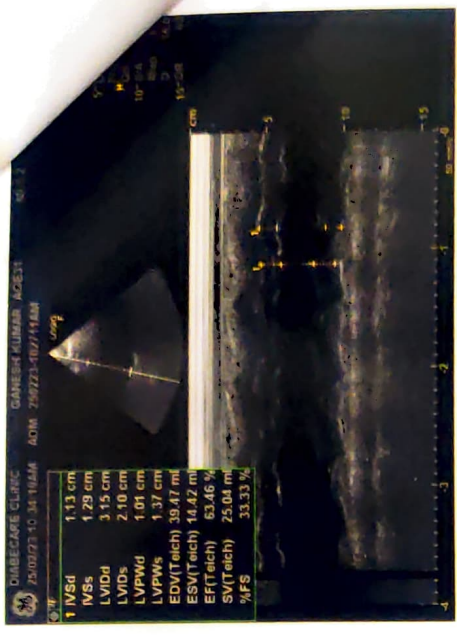
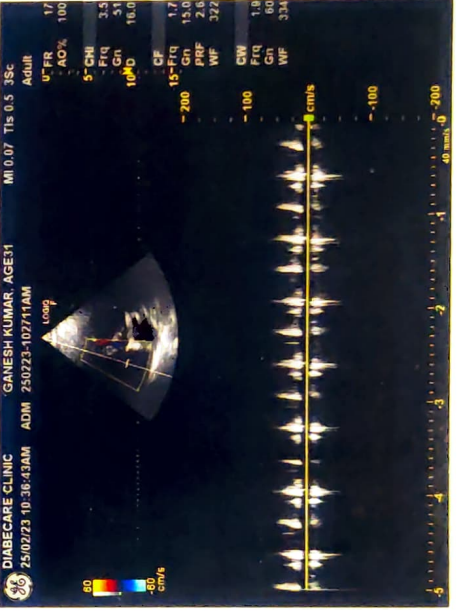
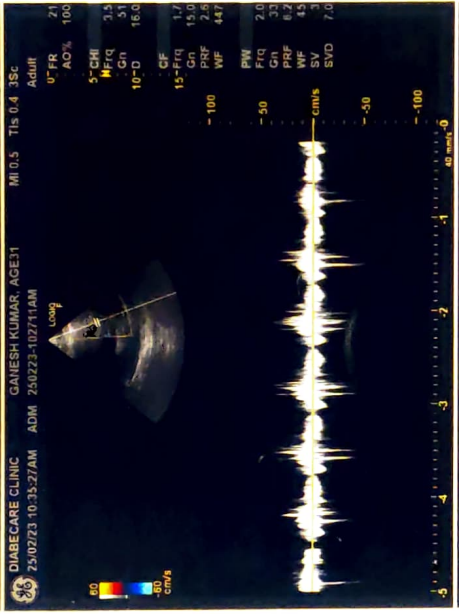

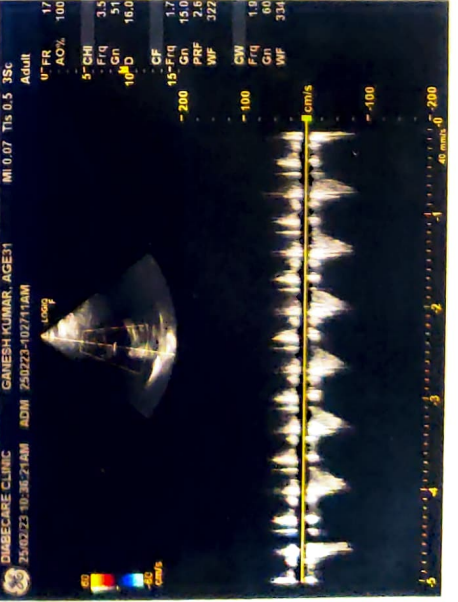
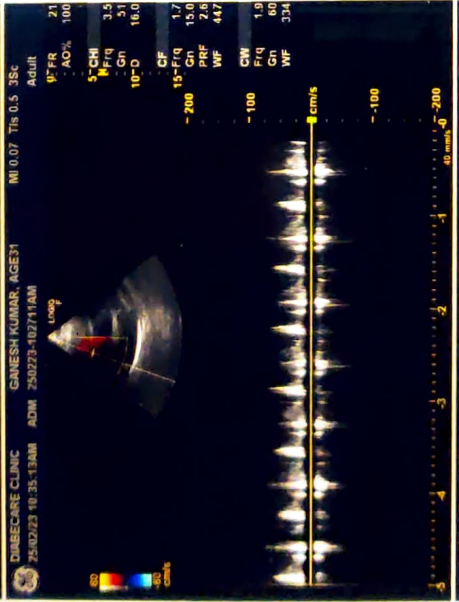
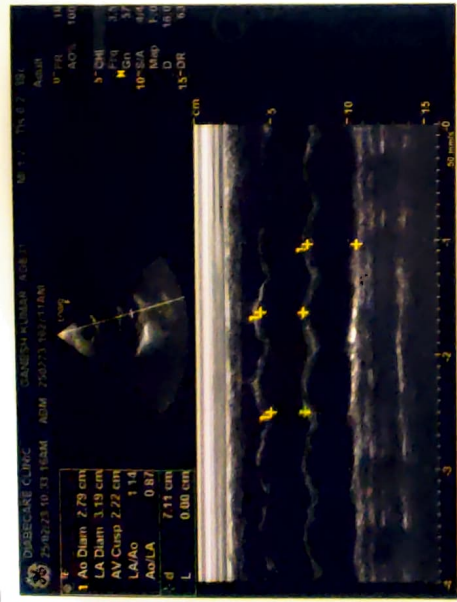
IVC Size (mm) – 12mm Collapsible

Doppler Findings- I



Dr. Mahesh Padsalge

Dr. Mahesh V. Padsalge
 MD. (Medicine)
 Consultant Physician
 Reg. No. 91424 (MMC)



 TN01 2014 0005946 TN NT

 Date of Issue 19-06-2014 validity 18-06-2034

Nationality INDIA

Date of Birth 01-08-1991 Blood Group B+

Name
GANESH KUMAR J

Father's Name
JAYA KUMAR K



Padh
Dr. Mahesh V. Padsalge
MD. (Medicine)
Consultant Physician
Reg. No. 91424 (MMC)

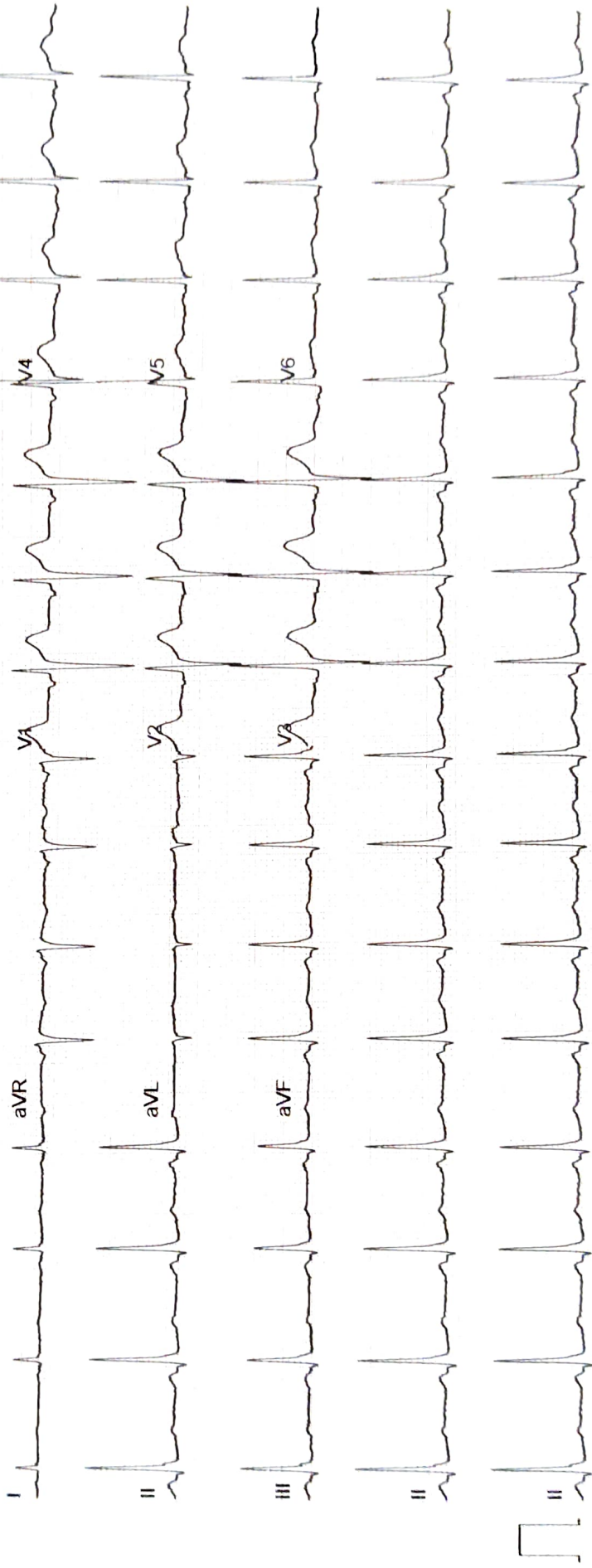
Male

QRS : 86 ms
QT / QTcBaz : 348 / 425 ms
PR : 126 ms
P : 88 ms
RR / PP : 666 / 666 ms
P / QRS / T : 69 / 69 / 66 degrees

Normal sinus rhythm
Minimal voltage criteria for LVH, may be normal variant
Borderline ECG

ECG in min normal

Dr. Mahesh V. Padsalge
MD. (Medicine)
Consultant Physician
Reg. No. 91424 (MMC)



Ⓢ Date - 25/02/23



Mr. Ganes Kumar

Age - 31 | M

Def. Mediwheel

glasses

Ⓡ

Ⓛ

VA

6/8

6/6

N6

N6

Antseg

Ⓢ

Ⓢ

Color Vn

Ⓢ

Ⓢ

Ⓢ

normal

normal

Ⓢ want

————— eyes

NAME- GANESH KUMAR

DATE-25/2/2023

AGE- 31/M

X-RAY CHEST PA

The Soft Tissues And Bony Thorax Are Normal.

Both The Costophrenic And Cardiophrenic Angles Are Clear.

Cardiac Shape And Size Appears Normal.

The Lung Field Appears Normal.

Both The Hila Are Normal In Density And Position.

Both The Domes Of Diaphragm And Mediastinum Are Normal.

Impression: - Normal Chest X-Ray.

For: 

DR.MRUDULA BABAR
CONSULTANT RADIOLOGIST

Dr. MRUDULA BABAR
DMRE.CPS Mumbai 2009
(RADIOLOGIST)
Reg. No. 2005/03/2139