

Health Check up Booking Request(bobE40427), Beneficiary Code-39535

1 message

Mediwheel <wellness@mediwheel.in>

7 June 2023 at 12:35

To: vidhidiagnostics@gmail.com

Cc: customercare@mediwheel.in

**Mediwheel**
...Your wellness partner**011-41195959**

Email:wellness@mediwheel.in

Dear **VIDHI DIAGNOSTICS,****City :** Ahmedabad . **Address :** L-86 Swatantra - Senani Nagar , Opp- Akhbarnagar Bus Terminals, New Wadaj , Ahmedabad -13,

We have received the confirmation for the following booking .

Name : MR. PARMAR GABHA
Age :
Gender : Male
Package Name : Medi-Wheel Metro Full Body Health Checkup Male Below 40
User Location : ,AHMEDABAD,Gujarat,380015
Contact Details : 9712074465
Booking Date : 07-06-2023
Appointment Date : 10-06-2023

Member Information			
Booked Member Name	Age	Gender	Cost(In INR)
MR. PARMAR GABHA	36	Male	Cashless
Total amount to be paid			Cashless

We will get back to you with confirmation update shortly. Please find the package details as attached for your reference.

Package Name : Medi-Wheel Metro Full Body Health Checkup Male Below 40 - Includes (37)Tests

Tests included in this Package : Ecg, TSH, X-ray Chest, Stress Test (tmt)/ 2d Echo, Blood Sugar Postprandial, A:g Ratio, Blood Group, Total Cholesterol, Triglycerides, Fasting Blood Sugar, Ultrasound Whole Abdomen , Glycosylated Haemoglobin (hba1c), Hdl, Vldl, Urine Analysis, LDL, Total Protine, General Consultation, HDL/ LDL ratio, GGT(Gamma-glutamyl Transferase), Eye Check-up consultation, ALP (ALKALINE PHOSPHATASE), Uric Acid, AST/ALT Ratio, Serum Protein, CBC with ESR, Stool Analysis, Urine Sugar Fasting, Urine Sugar PP, T3, T4, Cholesterol Total / HDL Ratio, BUN, BUN/Creatinine Ratio, Bilirubin Total & Direct and Indirect, Albumin, Globulin

10-06-2023 09:51:22

ID: 9609

Name: gabhabhai c parmar

Age: 38yrs

Sex: Male

Hospital:

Department:

HR : 83 bpm

PR : 140 ms

QRS : 88 ms

QT/QTc : 334/392 ms

P/QRS/T: 23/71/70 deg.

RV5/SV1: 1.970/-0.688 mv

RV5+SV1: 2.658 mv

<< Analysis Result >>

** abnormal ECG **

Sinus rhythm

Nonspecific T wave abnormality

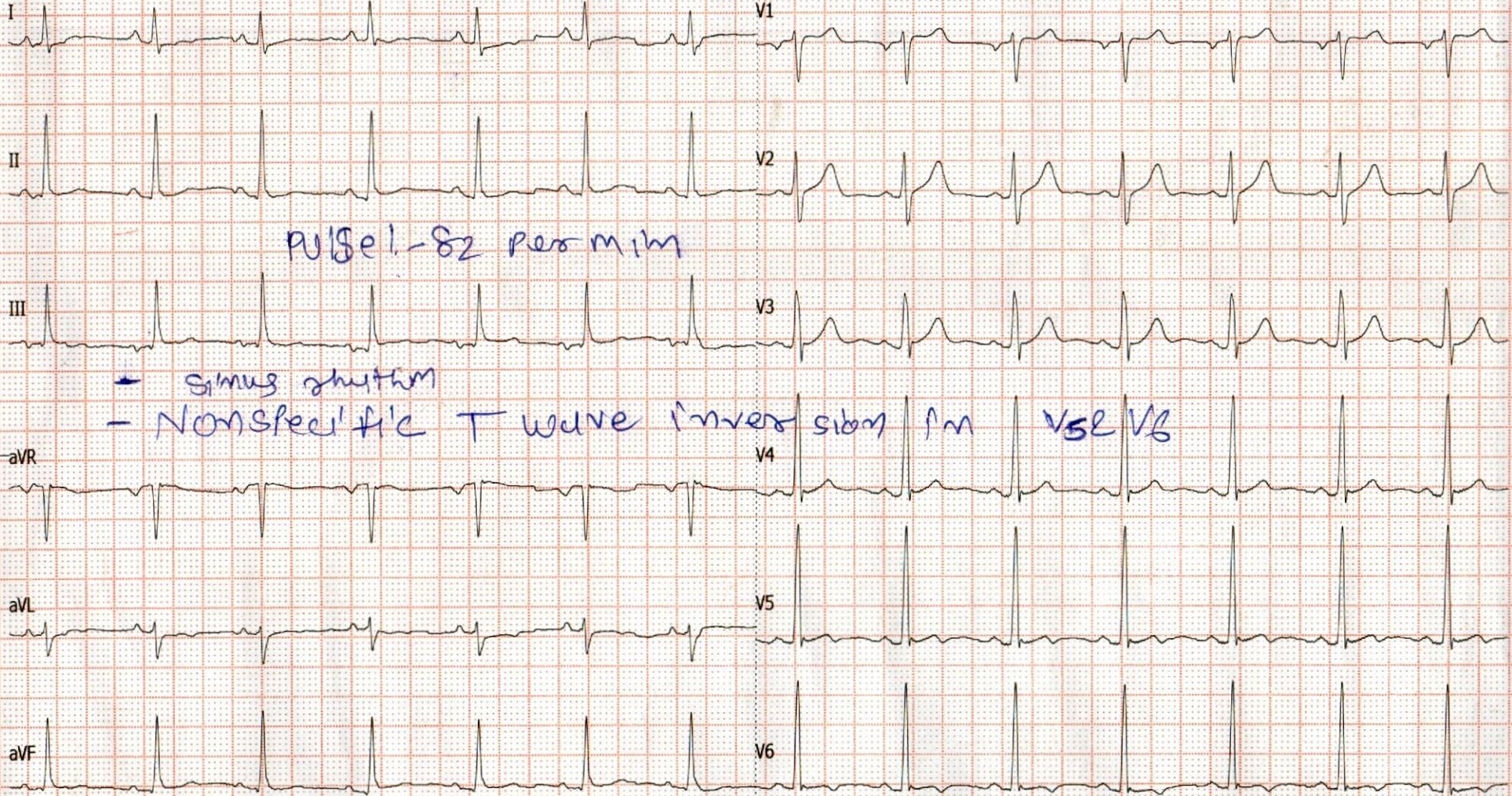
Possible left atrial enlargement

Vijhi Diagnostics
Swatantra-Senani Nagar,
Akhabnagar Bus Terminals,
Nr. Akhabnagar Circle,
New Wadaj, Ahmedabad-13.

Dr. Avinash Bhaskar
MBBS D-Cardio
G-45946

Need to be confirmed by doctor. Doctor Name: _____

0.67Hz - 35Hz AC 50Hz 25 mm/s 10 mm/mv



Pulse - 82 per min

*Sinus rhythm
- Nonspecific T wave inversion in V5 & V6*

Dr. Dinesh S. Modh

M.D., D.M.R.E. (Radiodiagnosis)

Consultant Radiologist & Sonologist

Ex. Junior Lecturer, B.J. Medical College, Civil Hospital, A'bad.

Panel Doctor of L.I.C.



Patient's name : PARMAR GABHABHAI CHAGANBHAI
Reg. ID : R-2852-23
Referred by : Dr. MEDIWHEEL

Age/Sex : 38 Years/Male
Accession : 7115
Date : 10/06/2023

USG ABDOMEN

LIVER:- Liver appears normal size and fatty echopattern grade1. No e/o focal lesion is seen. IHBR appear normal. PV & CBD appears normal. No e/o calculus is seen in bile duct.

GALL BLADDER:- Gall bladder is distended & appears normal. No e/o calculus or cholecystitis is seen. No evidence of pericholecystic fluid is seen.

SPLEEN:- Spleen appears normal in size & shows normal echotexture. No evidence of diffuse or focal lesion is seen.

PANCREAS:- Pancreas appears normal size and echopattern. No e/o diffuse or focal lesion is seen. Main pancreatic duct appears normal.

KIDNEY:- Both Kidneys appear normal in size & echotexture.

- Right kidney shows 6mm calculus in upper calyx.

No e/o hydronephrosis or hydroureter is seen in both sides.

Cortico-medullary differentiation is maintained on either side.

Both suprarenal regions appear normal.

No evidence of pre & para aortic lymphadenopathy is seen.

RIF & BOWEL (by high frequency probe-10Mhz): -Normal.

No evidence of free fluid is seen in abdomen.

No evidence of dilated or thickened bowel loops is seen.

Urinary bladder: - appear normal. No e/o calculus or mass lesion is seen in bladder.

Prostate appears normal size and echopattern.

Thanks for reference.

Dr. Dinesh S. Modh
MD DMRE (Radiodiagnosis)
G-23425

DR DINESH S. MODH

M.D. DMRE(RADIODIAGNOSIS)

ISO 9001:2015 Certified Diagnostics Center

Vidhi Imaging Center

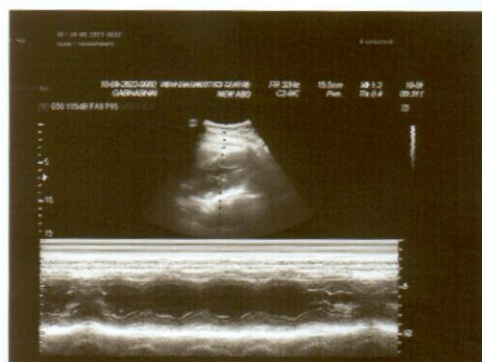
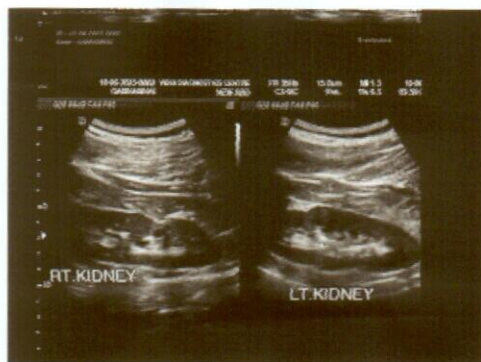
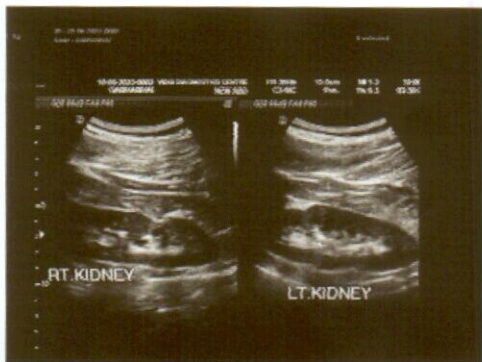
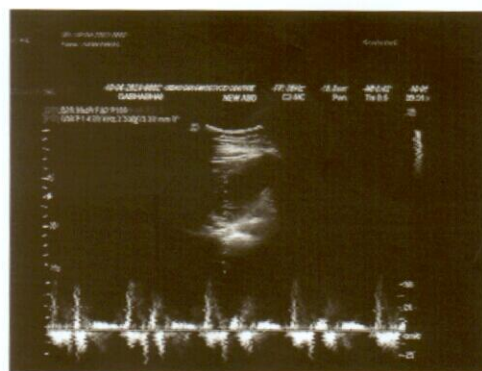
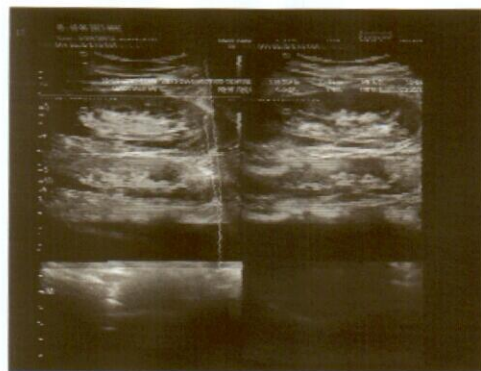
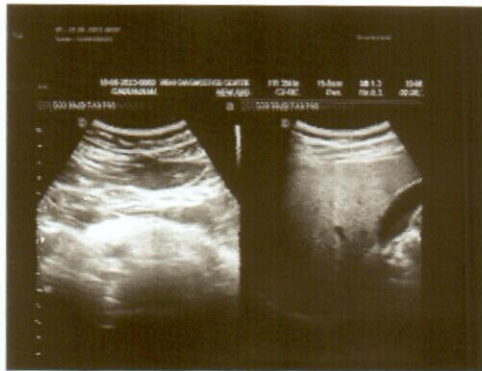
L-86, Swatantra Senani Nagar, Opp. Indian Oil Petrol Pump, Akhbarnagar Circle, Nava Vadaj, Ahmedabad - 380 013.

Phone : (Radiology) 079-2762 1406 | M. 98799 29406, 98250 09406 | Time (Radiology) : Mon. to Sat. 9 am to 2 pm, 5 to 9 pm, Sunday 9 am to 12 Noon

E-mail : vidhidiagnostics@gmail.com, Website : www.vidhidiagnostics.com

Multislice CT Scan | CBCT-Dental Scan | Live 3D-4D Sonography | Colour Doppler | Echo Cardiography | Interventional Radiology | Maxillofacial Radiology | Fetal Medicine
Digital X-Ray | Digital Mammography | Digital OPG/TMJ | ECG/TMT/PFT/EEG/EMG | Audiometry | Pathology Laboratory | Health Check Up Plans | Pre Employment Check Up

CT SCAN & CBCT FACILITY NOW AVAILABLE



Dr. Dinesh S. Modh

M.D., D.M.R.E. (Radiodiagnosis)

Consultant Radiologist & Sonologist

Ex. Junior Lecturer, B.J. Medical College, Civil Hospital, A'bad.

Panel Doctor of L.I.C.



Patient's name: PARMAR GABHABHAI CHAGANBHAI
Reg. ID : R-2852-23
Referred by : Dr. MEDIWHEEL

Age/Sex : 38 Years/Male
Accession : 7115
Date : 10/06/2023

X-RAY CHEST (PA VIEW)

Both lung fields appear normal.
No e/o consolidation or cavitations is seen.
Both costo-phrenic angles appear clear.
Cardiac size is with in normal limits.
Both domes of diaphragm appear normal.
Bony thoracic cage appears normal.

Thanks for reference.

Dr. Dinesh S. Modh
MD DMRE (Radiodiagnosis)
DR DINESH S. MODH
M.D. DMRE(RADIODIAGNOSIS)

ISO 9001:2015 Certified Diagnostics Center

Vidhi Imaging Center

L-86, Swatantra Senani Nagar, Opp. Indian Oil Petrol Pump, Akhbar Nagar Circle, Nava Vadaj, Ahmedabad - 380 013.

Phone : (Radiology) 079-2762 1406 | M. 98799 29406, 98250 09406 | Time (Radiology) : Mon. to Sat. 9 am to 2 pm, 5 to 9 pm, Sunday 9 am to 12 Noon

E-mail : vidhidiagnostics@gmail.com, Website : www.vidhidiagnostics.com

Multislice CT Scan | CBCT-Dental Scan | Live 3D-4D Sonography | Colour Doppler | Echo Cardiography | Interventional Radiology | Maxillofacial Radiology | Fetal Medicine
Digital X-Ray | Digital Mammography | Digital OPG/TMJ | ECG/TMT/PFT/EEG/EMG | Audiometry | Pathology Laboratory | Health Check Up Plans | Pre Employment Check Up

CT SCAN & CBCT FACILITY NOW AVAILABLE

Dr. Dinesh S. Modh

M.D., D.M.R.E. (Radiodiagnosis)
Consultant Radiologist & Sonologist
Ex. Junior Lecturer, B.J. Medical College, Civil Hospital, A'bad.
Panel Doctor of L.I.C.



Patient's name : PARMAR GABHABHAI CHAGANBHAI
Reg. ID : R-2852-23
Referred by : Dr. MEDIWHEEL

Age/Sex : 38 Years/Male
Accession : 7115
Date : 10/06/2023

2D- ECHO REPORT

FINAL CONCLUSION:

LV IS NORMAL SIZE. GOOD LV SYSTOLIC FUNCTION NO RWMA.
LVEF - 60%. NO CONCENTRIC LVH.
NORMAL LV COMPLANCE.
LA IS NORMAL SIZE. NO LA CLOT.
RV IS NORMAL SIZE. GOOD RV SYSTOLIC FUNCTION.
RA IS NORMAL SIZE.
MITRAL VALVE IS NORMAL. NO MS. MILD MR (15%). NO MVP.
AORTIC VALVE IS NORMAL. NO AS. NO AR.
TRICUSPID VALVE IS NORMAL. NO TR. RVSP-26 mmHg. NO PAH.

NO CLOT, NO VEGETATION, NO PERICARDIAL EFFUSION.

DIMENSIONS:

AORTA	2.6 C.M
LEFT ATRIUM	2.7 C.M
LVDD	4.1 C.M.
IVSD	1.0 C.M
PWD	1.0 C.M
LVDS	2.6 C.M.

COLOUR DOPPLER FINDING:

STRUCTURE	VELOCITY m/sec
	Max
PULMONARY VALVE	0.7
MITRAL VALVE	E : 0.7 A: 0.4
AORTIC VALVE	1.0

Dr. Avinash Bhaskar
MBBS. D Cardio

Reg. No. : G-45946
DR AVINASH BHASKAR
CLINICAL CARDIOLOGIST

ISO 9001:2015 Certified Diagnostics Center

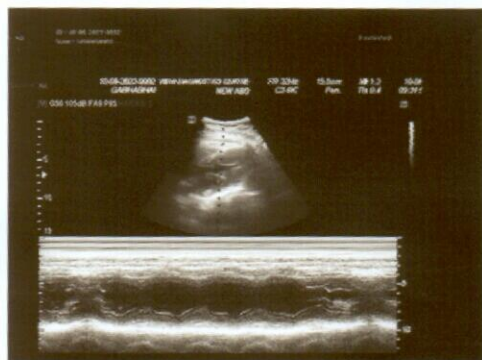
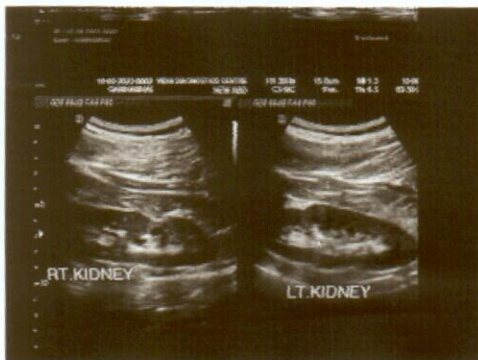
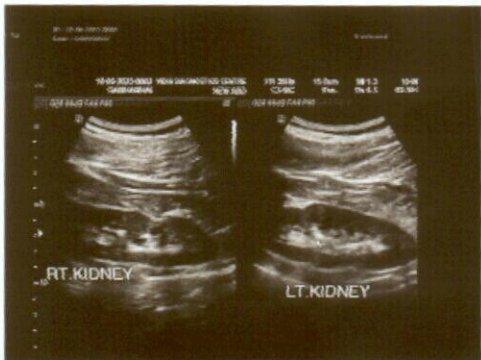
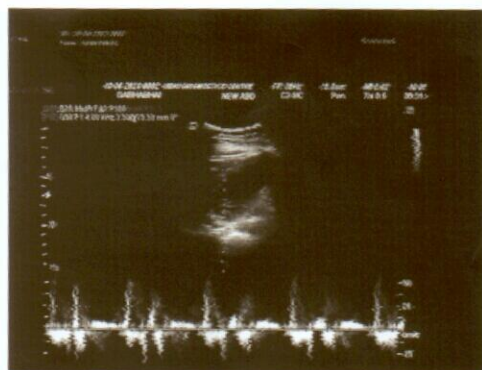
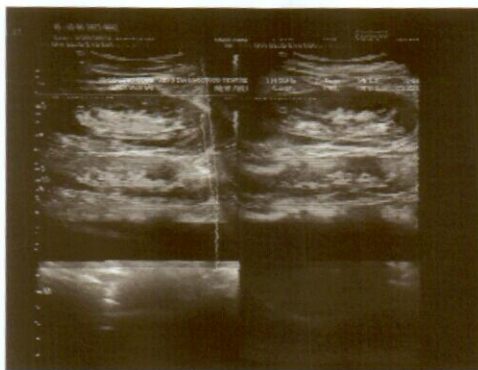
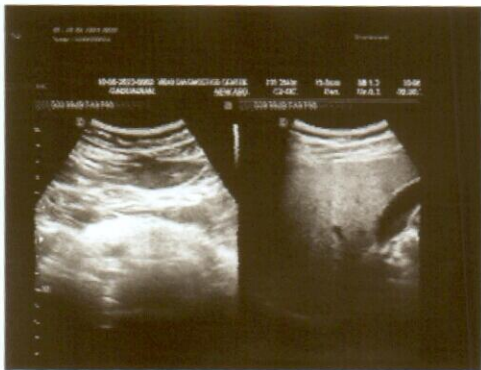
Vidhi Imaging Center

L-86, Swatantra Senani Nagar, Opp. Indian Oil Petrol Pump, Akharnagar Circle, Nava Vadaj, Ahmedabad - 380 013.

Phone : (Radiology) 079-2762 1406 | M. 98799 29406, 98250 09406 | Time (Radiology) : Mon. to Sat. 9 am to 2 pm, 5 to 9 pm, Sunday 9 am to 12 Noon
E-mail : vidhidiagnostics@gmail.com, Website : www.vidhidiagnostics.com

Multislice CT Scan | CBCT-Dental Scan | Live 3D-4D Sonography | Colour Doppler | Echo Cardiography | Interventional Radiology | Maxillofacial Radiology | Fetal Medicine
Digital X-Ray | Digital Mammography | Digital OPG/TMJ | ECG/TMT/PFT/EEG/EMG | Audiometry | Pathology Laboratory | Health Check Up Plans | Pre Employment Check Up

CT SCAN & CBCT FACILITY NOW AVAILABLE




Dr. Dinesh S. Modh

M.D., D.M.R.E. (Radiodiagnosis)

Consultant Radiologist & Sonologist

Ex. Junior Lecturer, B.J. Medical College, Civil Hospital, A'bad.

Panel Doctor of L.I.C.



જેલરીંગ સીપોલ નાજ સુપરવાઈઝર

ડૉ. દીનેશ મોઢ

Vidhi Diagnostics

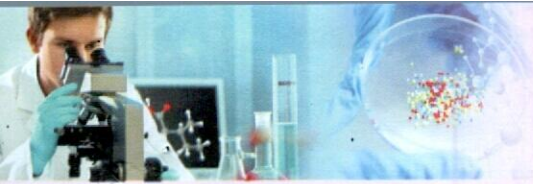L-86, Swatantra-Senani Nagar,
Opp. Akhbarnagar Bus Terminals,
Nr. Akhbarnagar Circle,
New Wadaj, Ahmedabad-13.

ISO 9001:2015 Certified Diagnostics Center

Vidhi Imaging Center, L-86, Swatantra Senani Nagar, Opp. Akhbarnagar Petrol Pump, Nr. Akhbarnagar Circle, Nava-Vadaj, Ahmedabad - 380 013.

Phone : 079-2762 1406, Mobile : 98799 29406, 98250 09406, E-mail : vidhidiagnostics@gmail.com, Website : www.vidhidiagnostics.com

FACILITIES : Live 3D-4D Sonography | Colour Doppler | Echo Cardiography | Interventional Radiology | Fetal Medicine | Digital X-Ray
Digital Mammography | Digital OPG/TMJ | ECG/TMT/PFT/EEG/EMG | Pathology Laboratory | Health Check Up Plans | Pre Employment Check Up



Pathology Department

VIDHI[®]
DIAGNOSTICS

Creating life in Images

Patient's name : PARMAR GABHABHAI CHAGANBHAI
Age/Sex : 38 Years/Male
Referred by : Dr. MEDIWHEEL
Collection Time : 08:58

Reg. ID : P-1287-23
Accession : 7101
Order Dt/time : 10/06/2023 08:58

Complete Blood Count

Sample Type: EDTA

Test Name	Result	Units	Biological Reference Interval
<u>Blood Counts</u>			
Haemoglobin :	15.1	Gms%	13.5 - 18.0
Total R.B.C. :	5.25	mill/c.mm	4.7 - 6.0
Total W. B. C. :	8240	/cu mm	4000 - 10500
Platelet Count :	328000	/cu.mm	1,50,000 - 4,50,000
<u>Differential Count</u>			
Neutrophils :	53	%	40 - 70
Lymphocytes :	40	%	20 - 40
Eosinophils :	03	%	1 - 4
Monocytes :	04	%	2 - 6
Basophils :	00	%	0 - 01
<u>Blood Indices</u>			
P. C. V :	44.8	%	42 - 52
M. C. V. :	85.3	fl	78 - 100
M.C.H :	28.7	pg	27 - 31
M. C. H. C :	33.6	%	32 - 36
R.D.W :	14.5	%	11.5 - 14.0
<u>E.S.R.(Westergren Method)</u>			
After one hour :	04	mm/hr	1 - 7

TESTS DONE ON FULLY AUTOMATED HEMATOLOGY ANALYZER.

Dr. Gayatri M. Mehta
M. D. (Patho)

Reg. No. G-32215

DR GAYATRI MEHTA
MD(PATHOLOGY)

DR. ANAND D. PARIKH
MD(PATHOLOGY)

LAB USE ONLY (Entered by :GM Enter Date/Time:10/06/2023 4:17:00 PM) (Verify by :GM Verify Date/Time:10/06/2023 4:17:00 PM)



Vidhi Imaging Center | Pathology Department

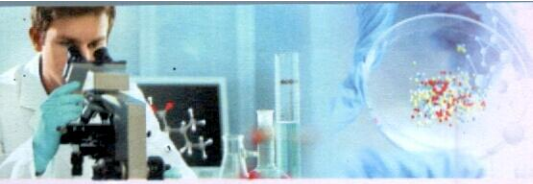L-86, Swatantra Senani Nagar, Opp. Akhbarnagar Petrol Pump, Nr. Akhbarnagar Circle, Nava-Vadaj, Ahmedabad - 380 013.

Ph. (Pathology) : 8849893954 M. 98799 29406, 98250 09406, E-mail : vidhidiagnostics@gmail.com, Web. : www.vidhidiagnostics.com

Time (Pathology) : Mon. to Sat. 8.30 am to 8.00 pm, Sunday 9 am to 12 Noon

Pathology means science behind medicine

CT SCAN & CBCT FACILITY NOW AVAILABLE



Pathology Department

VIDHI[®]
DIAGNOSTICS

Creating Life in Progress

Patient's name : PARMAR GABHABHAI CHAGANBHAI
Age/Sex : 38 Years/Male
Referred by : Dr. MEDIWHEEL
Collection Time : 08:58

Reg. ID : P-1287-23
Accession : 7101
Order Dt/time : 10/06/2023 08:58

Blood Group

Sample Type: EDTA sample.

Test Name	Result
BG :	" B "
RH :	NEGATIVE
Remarks	Done by forward grouping method.

Dr. Gayatri M. Mehta

M. D. (Patho)

Reg. No. G-32215

DR GAYATRI MEHTA
MD(PATHOLOGY)

DR. ANAND D. PARIKH
MD(PATHOLOGY)

LAB USE ONLY (Entered by :GM Enter Date/Time:10/06/2023 4:16:00 PM) (Verify by :GM Verify Date/Time:10/06/2023 4:16:00 PM)



Vidhi Imaging Center | Pathology Department

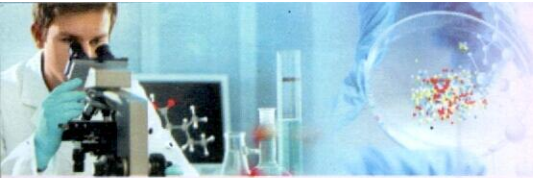L-86, Swatantra Senani Nagar, Opp. Akhbarnagar Petrol Pump, Nr. Akhbarnagar Circle, Nava-Vadaj, Ahmedabad - 380 013.

Ph. (Pathology) : 8849893954 M. 98799 29406, 98250 09406, E-mail : vidhidiagnostics@gmail.com, Web. : www.vidhidiagnostics.com

Time (Pathology) : Mon. to Sat. 8.30 am to 8.00 pm, Sunday 9 am to 12 Noon

Pathology means science behind medicine

CT SCAN & CBCT FACILITY NOW AVAILABLE



Patient's name : PARMAR GABHABHAI CHAGANBHAI
 Age/Sex : 38 Years/Male
 Referred by : Dr. MEDIWHEEL
 Collection Time : 08:58

Reg. ID : P-1287-23
 Accession : 7101
 Order Dt/time : 10/06/2023-08:58

Blood Glucose

Sample Type: Serum

Test Name	Result	Units	Biological Reference Interval
Fasting Blood Glucose : <i>GOD-POD Method.</i>	<u>111.3</u>	mg/dl	70 - 110

Blood Glucose

Sample Type: Serum

Test Name	Result	Units	Biological Reference Interval
Post Prandial Blood Glucose After 2hr. : <i>GOD-POD Method.</i>	<u>220.6</u>	mg/dl	80 - 140

Dr. Gayatri M. Mehta

M. D. (Patho)

Reg. No. G-32215

DR GAYATRI MEHTA
MD(PATHOLOGY)

DR. ANAND D. PARIKH
MD(PATHOLOGY)

LAB USE ONLY (Entered by :GM Enter Date/Time:10/06/2023 4:18:00 PM) (Verify by :GM Verify Date/Time:10/06/2023 4:18:00 PM)

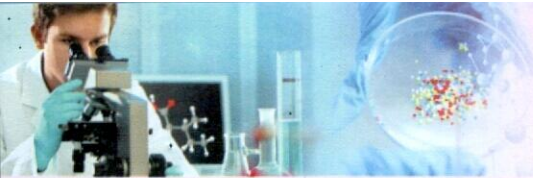

Vidhi Imaging Center | Pathology Department

L-86, Swatantra Senani Nagar, Opp. Akhbarnagar Petrol Pump, Nr. Akhbarnagar Circle, Nava-Vadaj, Ahmedabad - 380 013.
 Ph. (Pathology) : 8849893954 M. 98799 29406, 98250 09406, E-mail : vidhidiagnostics@gmail.com, Web. : www.vidhidiagnostics.com
 Time (Pathology) : Mon. to Sat. 8.30 am to 8.00 pm, Sunday 9 am to 12 Noon

Pathology means science behind medicine

CT SCAN & CBCT FACILITY NOW AVAILABLE



Creating Life in Images



Pathology Department

Patient's name : PARMAR GABHABHAI CHAGANBHAI
Age/Sex : 38 Years/Male
Referred by : Dr. MEDIWHEEL
Collection Time : 08:58

Reg. ID : P-1287-23
Accession : 7101
Order Dt/time : 10/06/2023 08:58

HbA1C

Sample Type: Serum

Table with 4 columns: Test Name, Result, Units, Biological Reference Interval. Rows include HbA1C (5.7%) and Mean Blood Glucose of Last 03 months (117 mg/dl).

Comment: *As per the new 2009 update of American Diabetes Association regarding HbA1C & Mean Blood Glucose relationship.
NOTE: This test is used to monitor diabetic patients compliance with the therapeutic regimen and logo It's level is proportional to both the average blood glucose concentration and the life span of the red blood cells (RBC) in circulation.

Dr. Gayatri M. Mehta
M. D. (Patho)
Reg. No. G-32215

DR GAYATRI MEHTA
MD(PATHOLOGY)

DR. ANAND D. PARIKH
MD(PATHOLOGY)

LAB USE ONLY (Entered by :GM Enter Date/Time:10/06/2023 4:18:00 PM) (Verify by :GM Verify Date/Time:10/06/2023 4:18:00 PM)

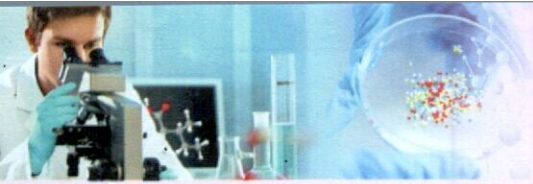

Vidhi Imaging Center | Pathology Department

L-86, Swatantra Senani Nagar, Opp. Akhbarnagar Petrol Pump, Nr. Akhbarnagar Circle, Nava-Vadaj, Ahmedabad - 380 013.
Ph. (Pathology) : 8849893954 M. 98799 29406, 98250 09406, E-mail : vidhidiagnostics@gmail.com, Web. : www.vidhidiagnostics.com
Time (Pathology) : Mon. to Sat. 8.30 am to 8.00 pm, Sunday 9 am to 12 Noon

Pathology means science behind medicine

CT SCAN & CBCT FACILITY NOW AVAILABLE



Pathology Department



Patient's name : PARMAR GABHABHAI CHAGANBHAI
Age/Sex : 38 Years/Male
Referred by : Dr. MEDIWHEEL
Collection Time : 08:58

Reg. ID : P-1287-23
Accession : 7101
Order Dt/time : 10/06/2023 08:58

Lipid Profile

Sample Type: Serum

Test Name	Result	Units	Biological Reference Interval
S. Cholesterol : Oxidase-esterase method.	174	mg/dl	0 - 200
S. Triglyceride : Enzymatic Colorimetry method	158.7	mg/dL	0 - 200
S. HDL - Cholesterol : Serum by Enzymatic method.	42.7	mg/dL	35 - 65
S. LDL - Cholesterol : Serum by Enzymatic method	102.9	mg/dL	0 - 130
S. VLDL - Cholesterol :	31.74	mg/dL	0 - 30
S. Chole/HDL.Ratio :	4.07		1 - 6
S. LDL / HDL Cholesterol Ratio :	2.41		0 - 3.5

Dr. Gayatri M. Mehta

M. D. (Patho)

Reg. No. G-32215

DR GAYATRI MEHTA
MD(PATHOLOGY)

DR.ANAND D.PARIKH
MD(PATHOLOGY)

LAB USE ONLY (Entered by :GM Enter Date/Time:10/06/2023 4:20:00 PM) (Verify by :GM Verify Date/Time:10/06/2023 4:20:00 PM)



Vidhi Imaging Center | Pathology Department

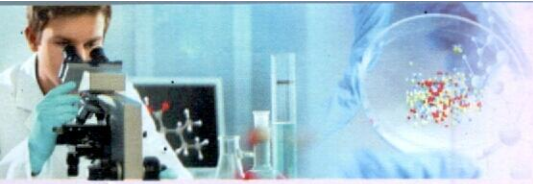L-86, Swatantra Senani Nagar, Opp. Akhbarnagar Petrol Pump, Nr. Akhbarnagar Circle, Nava-Vadaj, Ahmedabad - 380 013.

Ph. (Pathology) : 8849893954 M. 98799 29406, 98250 09406, E-mail : vidhidiagnostics@gmail.com, Web. : www.vidhidiagnostics.com

Time (Pathology) : Mon. to Sat. 8.30 am to 8.00 pm, Sunday 9 am to 12 Noon

Pathology means science behind medicine

CT SCAN & CBCT FACILITY NOW AVAILABLE



Patient's name : PARMAR GABHABHAI CHAGANBHAI
 Age/Sex : 38 Years/Male
 Referred by : Dr. MEDIWHEEL
 Collection Time : 08:58

Reg. ID : P-1287-23
 Accession : 7101
 Order Dt/time : 10/06/2023 08:58

BIOCHEMISTRY

Sample type :Serum

Test Name	Result	Units	Biological Reference Interval
Urea, (Serum by GLDH method) :	24.8	mg/dl	10 - 50
S.Uric acid, (Serum by Uricase method) :	4.8	mg/dl	3.4 - 7.0
Bun :	11.6	mg/dl	6-20
Creatinine, (Serum by Enzymatic reaction) :	0.92	mg/dl	0.5-1.2
BUN/CREATRATIO	12.60		13 - 20
S.G.P.T (ALT) : (Serum by IFCC method)	66.3	U/L	0 - 40
S.G.O.T (AST) : (Serum by IFCC method)	43.3	U/L	0 - 37
ALK.PHOSPHATASE : (Serum by PNP method)	109	U/L	40-129
G.G.T :	23.5	U/L	8 - 78
<u>BILIRUBIN</u>			
Total :	0.40	mg/dl	Up to 1.2
Direct :	0.18	mg/dl	0-0.7
Indirect :	0.22	mg/dl	0 - 0.5
<u>SERUM PROTEINS</u>			
Total Protein (Serum by Biuret method) :	7.06	gms/dl	6.4 - 8.5
Albumin (Serum by BCG method) :	4.35	gms/dl	3.97-4.94
Globulins :	2.71	gms/dl	2.3 - 3.5
A/G Ratio :	1.605		0.9 - 2.9

Dr. Gayatri M. Mehta
 M. D. (Patho)

Reg. No. G-32215

DR GAYATRI MEHTA
 MD(PATHOLOGY)



DR. ANAND D. PARIKH
 MD(PATHOLOGY)



(Entered by :GM Enter Date/Time:10/06/2023 4:14:00 PM) (Verify by :GM Verify Date/Time:10/06/2023 4:14:00 PM)

Vidhi Imaging Center | Pathology Department

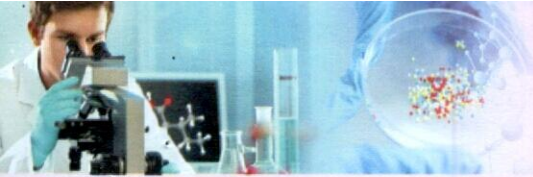L-86, Swatantra Senani Nagar, Opp. Akharnagar Petrol Pump, Nr. Akharnagar Circle, Nava-Vadaj, Ahmedabad - 380 013.

Ph. (Pathology) : 8849893954 M. 98799 29406, 98250 09406, E-mail : vidhidiagnostics@gmail.com, Web. : www.vidhidiagnostics.com

Time (Pathology) : Mon. to Sat. 8.30 am to 8.00 pm, Sunday 9 am to 12 Noon

Pathology means science behind medicine

CT SCAN & CBCT FACILITY NOW AVAILABLE



Pathology Department



Patient's name : PARMAR GABHABHAI CHAGANBHAI
Age/Sex : 38 Years/Male
Referred by : Dr. MEDIWHEEL
Collection Time : 08:58

Reg. ID : P-1287-23
Accession : 7101
Order Dt/time : 10/06/2023 08:58

Thyroid Function Test

Sample Type: Serum

Test Name	Result	Units	Biological Reference Interval
Serum T3:	1.11	ng/ml	0.6 to 1.80
Serum T4:	8.29	mcg/dl	4.5 to 10.9
Serum TSH:	5.079	microU/ml	0.35 to 5.55

Dr. Gayatri M. Mehta
M. D. (Patho)

Reg. No. G-32215

DR GAYATRI MEHTA
MD(PATHOLOGY)

DR. ANAND D. PARIKH
MD(PATHOLOGY)

LAB USE ONLY (Entered by :AP Enter Date/Time:10/06/2023 5:21:00 PM) (Verify by :GM Verify Date/Time:10/06/2023 5:21:00 PM)



Vidhi Imaging Center | Pathology Department

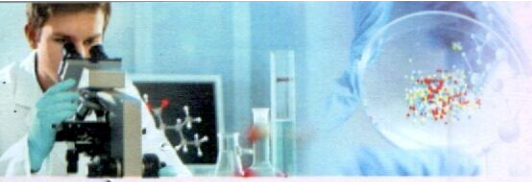L-86, Swatantra Senani Nagar, Opp. Akhbarnagar Petrol Pump, Nr. Akhbarnagar Circle, Nava-Vadaj, Ahmedabad - 380 013.

Ph. (Pathology) : 8849893954 M. 98799 29406, 98250 09406, E-mail : vidhidiagnostics@gmail.com, Web. : www.vidhidiagnostics.com


Time (Pathology) : Mon. to Sat. 8.30 am to 8.00 pm, Sunday 9 am to 12 Noon

Pathology means science behind medicine

CT SCAN & CBCT FACILITY NOW AVAILABLE



Pathology Department



Patient's name : PARMAR GABHABHAI CHAGANBHAI
Age/Sex : 38 Years/Male
Referred by : Dr. MEDIWHEEL
Collection Time : 08:58

Reg. ID : P-1287-23
Accession : 7101
Order Dt/time : 10/06/2023 08:58

Urine Analysis

Sample Type: Urine

Test Name	Result	Units	Biological Reference Interval
<u>Physical Examination</u>			
Quantity :	30	ml	0 - 500 ml
Colour :	Pale Yellow		Pale Yellow
Transparency :	Slight Turbid.		Clear
Reaction :	Acidic		4.6 - 8.0
Specific Gravity :	1.030		1.016 - 1.022
Sediment :	Present		
<u>Chemical Examination</u>			
Albumin :	Present (Faint Trace)		Absent
Sugar :	NIL		Absent
Acetone :	Absent		Absent
Bile Salts :	Absent		Absent
Bile Pigments :	Absent		Absent
Urobilogen :	Absent		Absent
Nitrites :	Absent		Absent
<u>Microscopic Examination</u>			
Red blood Cells :	1-2	/h.p.f	Absent
Pus Cells :	2-3	/h.p.f	Absent
Epithelial Cells :	1-2	/h.p.f	< 10.0
Amorphous :	Absent	/h.p.f	Absent
Bacteria :	Absent	/h.p.f	Absent
Crystals :	Absent	/h.p.f	Absent
Casts :	Absent	/h.p.f	Absent
Fungus :	Not seen	/h.p.f	Absent

Dr. Gayatri M. Mehta
M. D. (Patho)
Reg. No. G-32215



DR. ANAND D. PARIKH
MD(PATHOLOGY)

(Entered by :GM Enter Date/Time:10/06/2023 4:22:00 PM) (Verify by :GM Verify Date/Time:10/06/2023 4:22:00 PM)

Vidhi Imaging Center | Pathology Department

L-86, Swatantra Senani Nagar, Opp. Akhbarnagar Petrol Pump, Nr. Akhbarnagar Circle, Nava-Vadaj, Ahmedabad - 380 013.

Ph. (Pathology) : 8849893954 M. 98799 29406, 98250 09406, E-mail : vidhidiagnostics@gmail.com, Web. : www.vidhidiagnostics.com

Time (Pathology) : Mon. to Sat. 8.30 am to 8.00 pm, Sunday 9 am to 12 Noon

Pathology means science behind medicine

CT SCAN & CBCT FACILITY NOW AVAILABLE

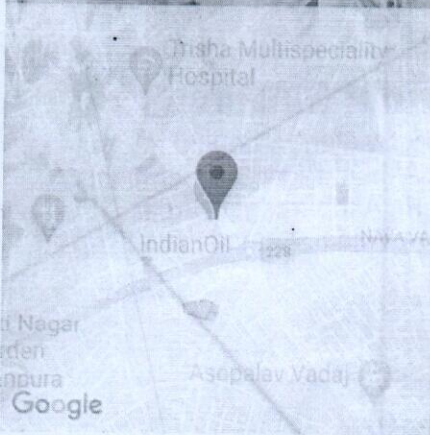

Handwritten signature in blue ink, appearing to read "Vidhi D. Modh".

Dr. Vidhi D. Modh
MBBS
Reg. No. G-74540

Vidhi Diagnostics
L-86, Swatantra-Senani Nagar,
Opp. Akhbarnagar Bus Terminals,
Nr. Akhbarnagar Circle,
New Wadaj, Ahmedabad-13.

Faint, illegible text at the bottom of the page, possibly a stamp or additional registration information.



Jun 10, 2023 10:13:07 AM

Nirnay Nagar

Ahmedabad

Gujarat

Vidhi Diagnostics

L-86, Swatantra-Senani Nagar,
Opp. Akhbarnagar Bus Terminals,
Nr. Akhbarnagar Circle,
New Wadaj, Ahmedabad-13.

Dr. Vidhi M. Modh
MBBS

Reg. No. G-74540