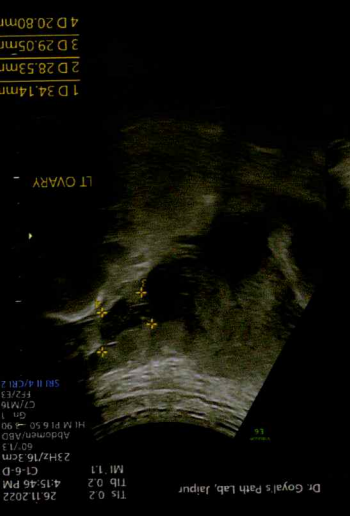
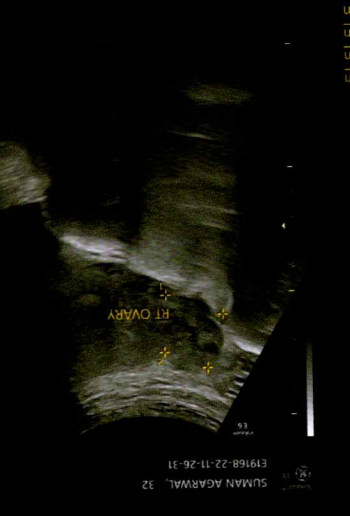
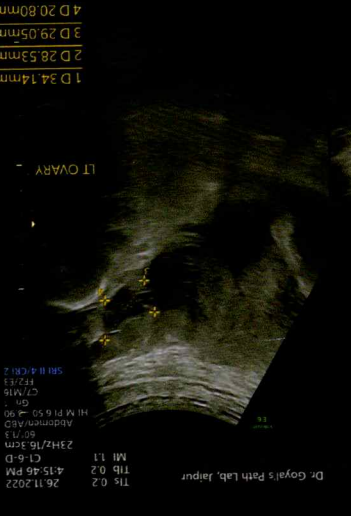
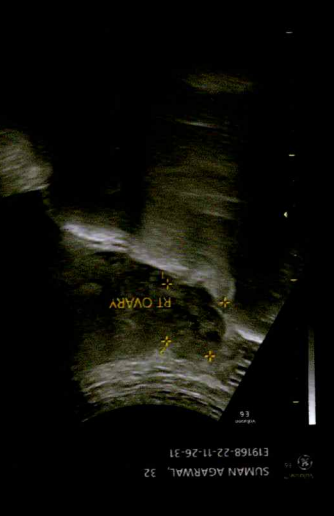
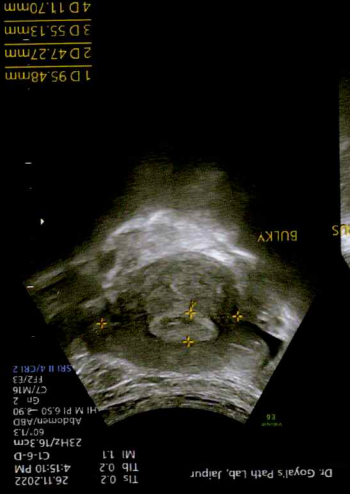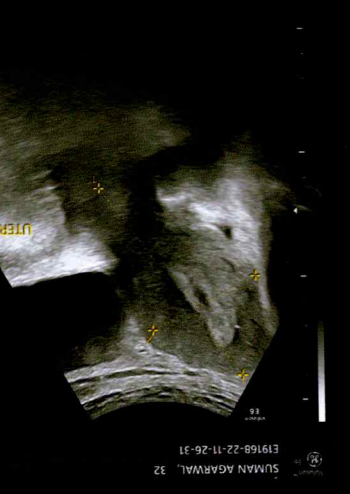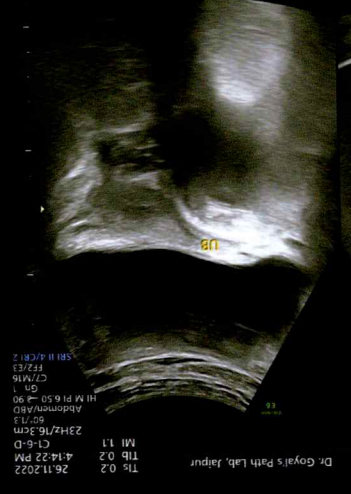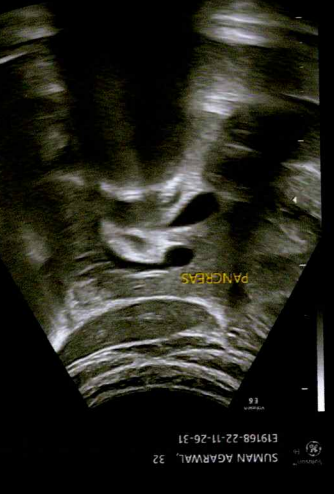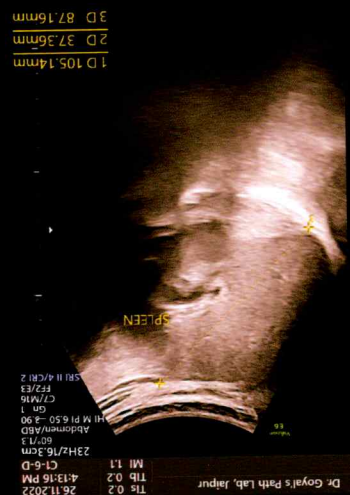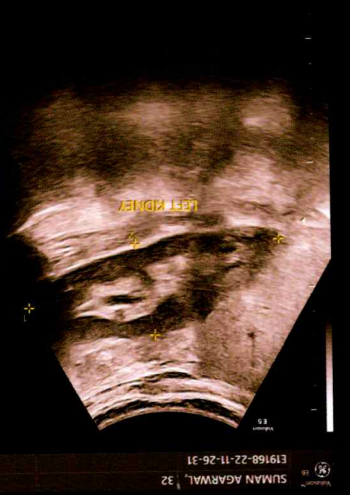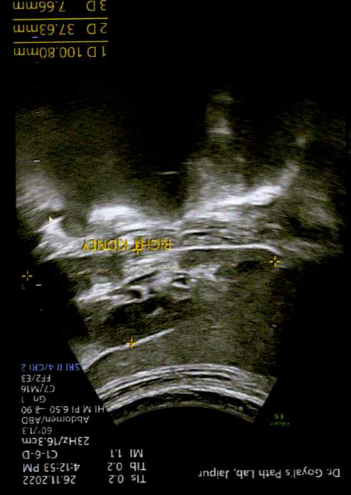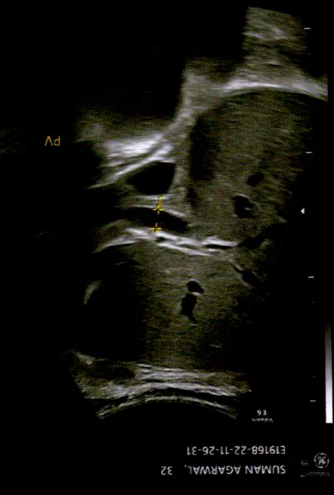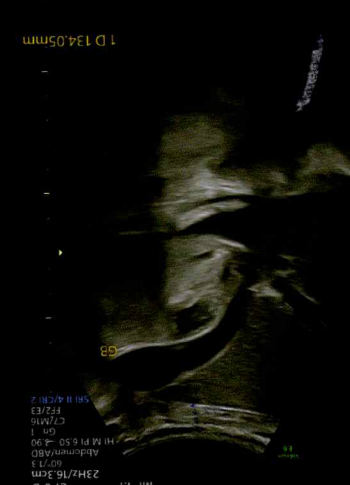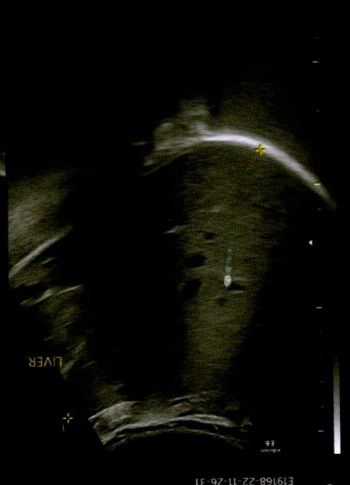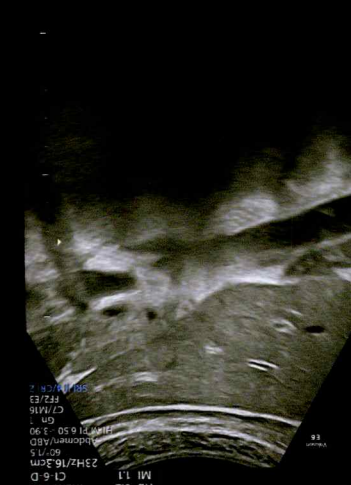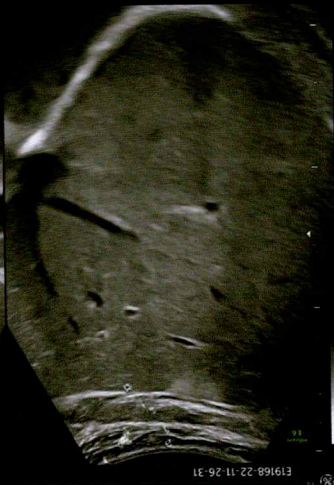1 D 34.14mm  
2 D 28.53mm  
3 D 29.05mm  
4 D 20.80mm

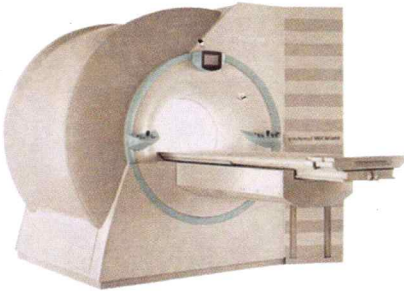
1 D 95.48mm  
2 D 47.27mm  
3 D 55.13mm  
4 D 11.70mm

1 D 100.80mm  
2 D 37.63mm  
3 D 7.66mm

1 D 105.14mm  
2 D 37.63mm  
3 D 87.16mm

1 D 134.05mm

1 D 134.05mm



# Dr. Goyal's

## Path Lab & Imaging Centre

B-51, Ganesh Nagar, Opp. Janpath Corner, New Sanganer Road, Jaipur  
Tele : 0141-2293346, 4049787, 9887049787  
Website : www.drgoyalpathlab.com | E-mail : drgoyalpiyush@gmail.com



Date :- 26/11/2022 10:40:26

**NAME :- Mrs. SUMAN AGRAWAL**

Sex / Age :- Female 32 Yrs

Company :- MediWHEEL

Patient ID :- 122228301

Ref. By Doctor:-BOB

Lab/Hosp :-

Final Authentication : 26/11/2022 16:31:20

BOB PACKAGEFEMALE BELOW 40

### ULTRA SOUND SCAN OF ABDOMEN

**Liver** is of normal size. Echo-texture is normal. No focal space occupying lesion is seen within liver parenchyma. Intra hepatic biliary channels are not dilated. Portal vein diameter is normal.

**Gall bladder** is of normal size. Wall is not thickened. No calculus or mass lesion is seen in gall bladder. Common bile duct is not dilated.

**Pancreas** is of normal size and contour. Echo-pattern is normal. No focal lesion is seen within pancreas.

**Spleen** is of normal size and shape. Echotexture is normal. No focal lesion is seen.

**Kidneys** are normally sited and are of normal size and shape. Cortico-medullary echoes are normal. No focal lesion is seen. Collecting system does not show any dilatation or calculus.

**Urinary Bladder:** is well distended and showing smooth wall with normal thickness. Urinary bladder does not show any calculus or mass lesion.

**Uterus is anteverted and bulky in size and measures ~97x47x55 mm.**

Myometrium shows normal echo - pattern. No focal space occupying lesion is seen. Endometrial echo is normal. Endometrial thickness is 11.7 mm.

**Both ovaries** are visualised and are normal. No adnexal mass is seen.

No enlarged nodes are visualised. No retro-peritoneal lesion is identified. No significant free fluid is seen in pouch of douglas.

### IMPRESSION:

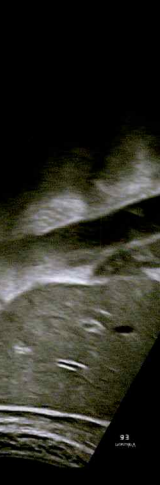
**\*Bulky uterus.**

*Needs clinical correlation & further evaluation*

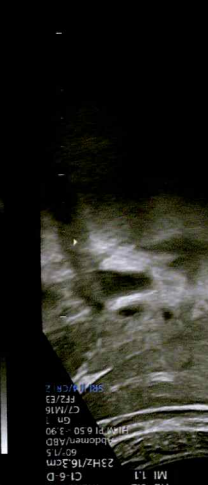\*\*\* End of Report \*\*\*



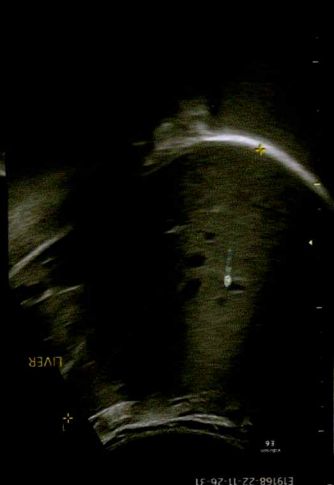SUMAN AGARWAL, 32  
E19168-22-11-26-31



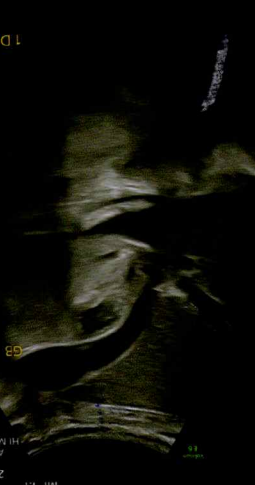Dr. Goyal's Path Lab, Jaipur  
TIS: 0.2  
TIB: 0.2  
MI: 1.1  
26.11.2022



SUMAN AGARWAL, 32  
E19168-22-11-26-31



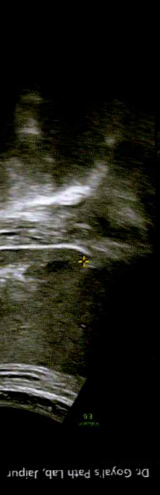Dr. Goyal's Path Lab, Jaipur  
TIS: 0.2  
TIB: 0.2  
MI: 1.1  
26.11.2022



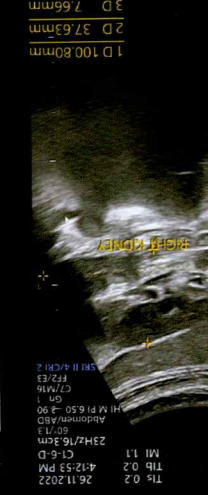SUMAN AGARWAL, 32  
E19168-22-11-26-31



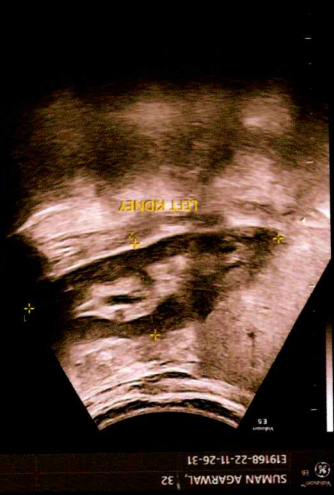SUMAN AGARWAL, 32  
E19168-22-11-26-31



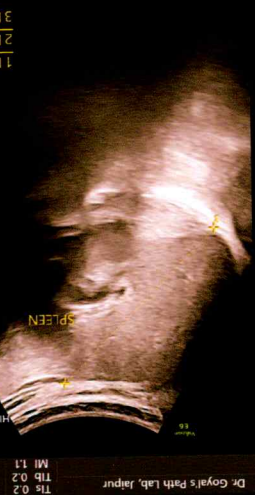Dr. Goyal's Path Lab, Jaipur  
TIS: 0.2  
TIB: 0.2  
MI: 1.1  
26.11.2022



SUMAN AGARWAL, 32  
E19168-22-11-26-31



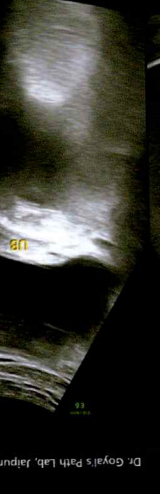Dr. Goyal's Path Lab, Jaipur  
TIS: 0.2  
TIB: 0.2  
MI: 1.1  
26.11.2022



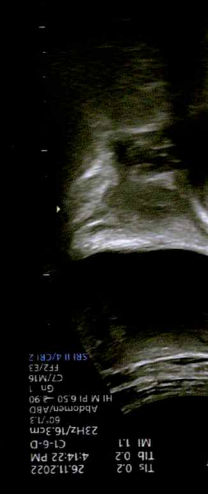SUMAN AGARWAL, 32  
E19168-22-11-26-31



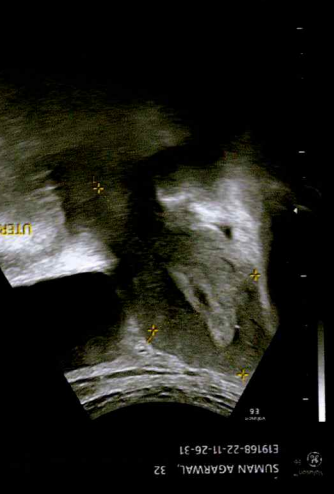SUMAN AGARWAL, 32  
E19168-22-11-26-31



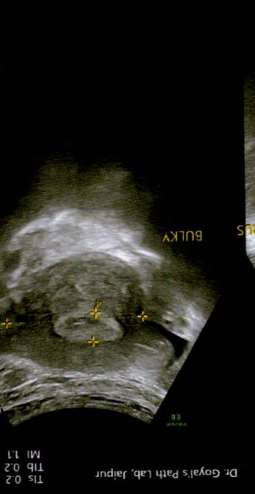
Dr. Goyal's Path Lab, Jaipur  
TIS: 0.2  
TIB: 0.2  
MI: 1.1  
26.11.2022



SUMAN AGARWAL, 32  
E19168-22-11-26-31



Dr. Goyal's Path Lab, Jaipur  
TIS: 0.2  
TIB: 0.2  
MI: 1.1  
26.11.2022



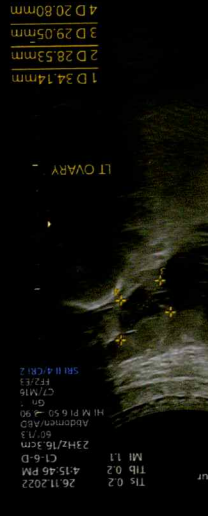
SUMAN AGARWAL, 32  
E19168-22-11-26-31



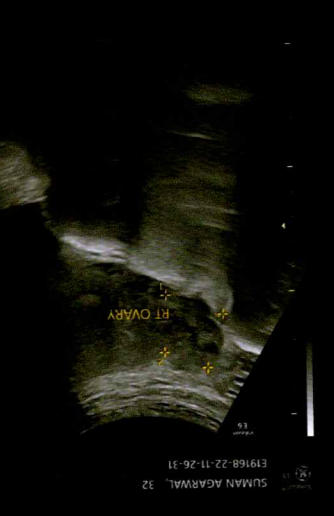SUMAN AGARWAL, 32  
E19168-22-11-26-31



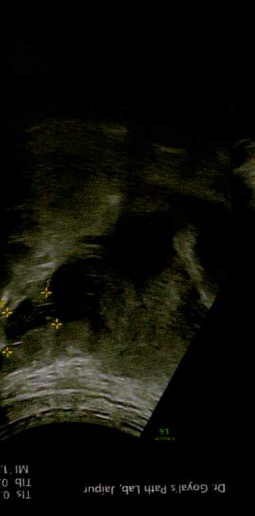
Dr. Goyal's Path Lab, Jaipur  
TIS: 0.2  
TIB: 0.2  
MI: 1.1  
26.11.2022



SUMAN AGARWAL, 32  
E19168-22-11-26-31

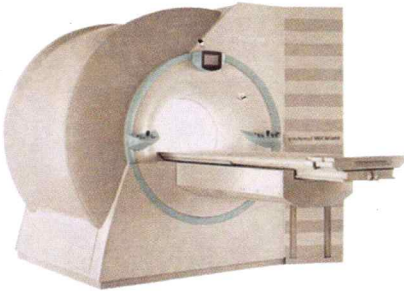


Dr. Goyal's Path Lab, Jaipur  
TIS: 0.2  
TIB: 0.2  
MI: 1.1  
26.11.2022



SUMAN AGARWAL, 32  
E19168-22-11-26-31

1 D 34.14mm  
2 D 28.53mm  
3 D 29.05mm  
4 D 20.80mm



# Dr. Goyal's

## Path Lab & Imaging Centre

B-51, Ganesh Nagar, Opp. Janpath Corner, New Sanganer Road, Jaipur  
Tele : 0141-2293346, 4049787, 9887049787  
Website : www.drgoyalpathlab.com | E-mail : drgoyalpiyush@gmail.com



Date :- 26/11/2022 10:40:26

**NAME :- Mrs. SUMAN AGRAWAL**

Sex / Age :- Female 32 Yrs

Company :- MediWHEEL

Patient ID :- 122228301

Ref. By Doctor:-BOB

Lab/Hosp :-

Final Authentication : 26/11/2022 16:31:20

BOB PACKAGEFEMALE BELOW 40

### ULTRA SOUND SCAN OF ABDOMEN

**Liver** is of normal size. Echo-texture is normal. No focal space occupying lesion is seen within liver parenchyma. Intra hepatic biliary channels are not dilated. Portal vein diameter is normal.

**Gall bladder** is of normal size. Wall is not thickened. No calculus or mass lesion is seen in gall bladder. Common bile duct is not dilated.

**Pancreas** is of normal size and contour. Echo-pattern is normal. No focal lesion is seen within pancreas.

**Spleen** is of normal size and shape. Echotexture is normal. No focal lesion is seen.

**Kidneys** are normally sited and are of normal size and shape. Cortico-medullary echoes are normal. No focal lesion is seen. Collecting system does not show any dilatation or calculus.

**Urinary Bladder:** is well distended and showing smooth wall with normal thickness. Urinary bladder does not show any calculus or mass lesion.

**Uterus is anteverted and bulky in size and measures ~97x47x55 mm.**

Myometrium shows normal echo - pattern. No focal space occupying lesion is seen. Endometrial echo is normal. Endometrial thickness is 11.7 mm.

**Both ovaries** are visualised and are normal. No adnexal mass is seen.

No enlarged nodes are visualised. No retro-peritoneal lesion is identified. No significant free fluid is seen in pouch of douglas.

### IMPRESSION:

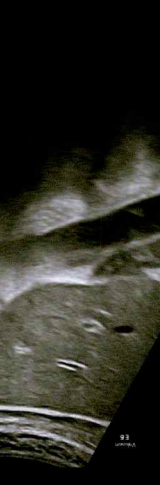
**\*Bulky uterus.**

*Needs clinical correlation & further evaluation*

\*\*\* End of Report \*\*\*



SUMAN AGARWAL, 32  
E19168-22-11-26-31



Dr. Goyal's Path Lab, Jaipur  
TIS: 0.2  
TIB: 0.2  
MI: 1.1  
26.11.2022



SUMAN AGARWAL, 32  
E19168-22-11-26-31



Dr. Goyal's Path Lab, Jaipur  
TIS: 0.2  
TIB: 0.2  
MI: 1.1  
26.11.2022



SUMAN AGARWAL, 32  
E19168-22-11-26-31



SUMAN AGARWAL, 32  
E19168-22-11-26-31



Dr. Goyal's Path Lab, Jaipur  
TIS: 0.2  
TIB: 0.2  
MI: 1.1  
26.11.2022



SUMAN AGARWAL, 32  
E19168-22-11-26-31



Dr. Goyal's Path Lab, Jaipur  
TIS: 0.2  
TIB: 0.2  
MI: 1.1  
26.11.2022



SUMAN AGARWAL, 32  
E19168-22-11-26-31



SUMAN AGARWAL, 32  
E19168-22-11-26-31



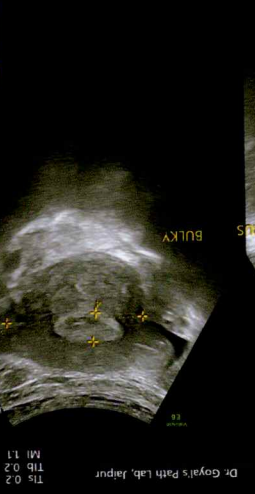
Dr. Goyal's Path Lab, Jaipur  
TIS: 0.2  
TIB: 0.2  
MI: 1.1  
26.11.2022



SUMAN AGARWAL, 32  
E19168-22-11-26-31



Dr. Goyal's Path Lab, Jaipur  
TIS: 0.2  
TIB: 0.2  
MI: 1.1  
26.11.2022



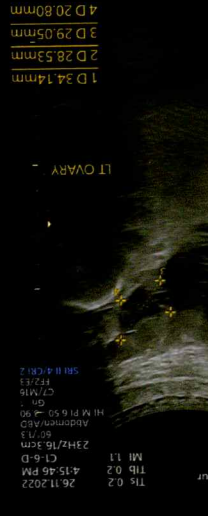
SUMAN AGARWAL, 32  
E19168-22-11-26-31



SUMAN AGARWAL, 32  
E19168-22-11-26-31



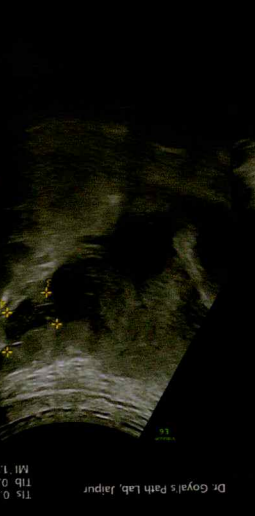
Dr. Goyal's Path Lab, Jaipur  
TIS: 0.2  
TIB: 0.2  
MI: 1.1  
26.11.2022



SUMAN AGARWAL, 32  
E19168-22-11-26-31



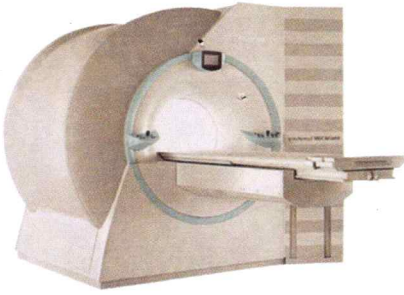
Dr. Goyal's Path Lab, Jaipur  
TIS: 0.2  
TIB: 0.2  
MI: 1.1  
26.11.2022



SUMAN AGARWAL, 32  
E19168-22-11-26-31

1 D 34.14mm  
2 D 28.53mm  
3 D 29.05mm  
4 D 20.80mm

1 D 34.14mm  
2 D 28.53mm  
3 D 29.05mm  
4 D 20.80mm



# Dr. Goyal's

## Path Lab & Imaging Centre

B-51, Ganesh Nagar, Opp. Janpath Corner, New Sanganer Road, Jaipur  
Tele : 0141-2293346, 4049787, 9887049787  
Website : www.drgoyalpathlab.com | E-mail : drgoyalpiyush@gmail.com



Date :- 26/11/2022 10:40:26

**NAME :- Mrs. SUMAN AGRAWAL**

Sex / Age :- Female 32 Yrs

Company :- MediWheel

Patient ID :- 122228301

Ref. By Doctor:-BOB

Lab/Hosp :-

Final Authentication : 26/11/2022 16:31:20

BOB PACKAGEFEMALE BELOW 40

### ULTRA SOUND SCAN OF ABDOMEN

**Liver** is of normal size. Echo-texture is normal. No focal space occupying lesion is seen within liver parenchyma. Intra hepatic biliary channels are not dilated. Portal vein diameter is normal.

**Gall bladder** is of normal size. Wall is not thickened. No calculus or mass lesion is seen in gall bladder. Common bile duct is not dilated.

**Pancreas** is of normal size and contour. Echo-pattern is normal. No focal lesion is seen within pancreas.

**Spleen** is of normal size and shape. Echotexture is normal. No focal lesion is seen.

**Kidneys** are normally sited and are of normal size and shape. Cortico-medullary echoes are normal. No focal lesion is seen. Collecting system does not show any dilatation or calculus.

**Urinary Bladder:** is well distended and showing smooth wall with normal thickness. Urinary bladder does not show any calculus or mass lesion.

**Uterus is anteverted and bulky in size and measures ~97x47x55 mm.**

Myometrium shows normal echo - pattern. No focal space occupying lesion is seen. Endometrial echo is normal. Endometrial thickness is 11.7 mm.

**Both ovaries** are visualised and are normal. No adnexal mass is seen.

No enlarged nodes are visualised. No retro-peritoneal lesion is identified. No significant free fluid is seen in pouch of douglas.

### IMPRESSION:

**\*Bulky uterus.**

*Needs clinical correlation & further evaluation*

\*\*\* End of Report \*\*\*