

Name : Mr. SUMIT KUMAR SAHU Age : 34Yr 9Mth 19Days Gender : Male
 UHID : ASHB.0000055867 / BPLAH11723 W/BNo/RefNo : AHC
 SIN \ LRN : 200929 \ 200930 \ 200931 \ 79958
 Specimen : Blood
 Ref Doctor : Dr. Akhil Kumar Tiwari



Collected on : 09-NOV-2024 09:45:42 AM Received on : 09-NOV-2024 10:21:21 AM Reported on : 09-NOV-2024 12:20:37 PM

MEDIWHEEL FULL BODY HEALTH PLUS BELOW 40 ADVANCED-MALE

<u>TEST NAME</u>	<u>RESULT</u>	<u>BIOLOGICAL REFERENCE INTERVALS</u>	<u>UNITS</u>
GLUCOSE - SERUM / PLASMA (FASTING)			
GLUCOSE - PLASMA (FASTING)	96	70-100	mg/dL
GLUCOSE - SERUM / PLASMA (POST PRANDIAL)			
GLUCOSE - PLASMA - (POST PRANDIAL)	123	70-140	mg/dL
CHOLESTEROL - SERUM / PLASMA	245 *	Desirable: <200 Borderline High: 200-239 High >240	mg/dL
HDL CHOLESTEROL - SERUM / PLASMA	44	>40	mg/dL
LDL CHOLESTEROL - SERUM / PLASMA	186 *	Optimal: <100 Above optimal: 100-129 Borderline high: 130-159 High: 160-189 Very high: >190	mg/dL
TRIGLYCERIDES - SERUM / PLASMA	156 *	Normal<150 Borderline high 150-199 High 200-499 Very high: ≥ 500	mg/dL
VLDL CHOLESTEROL - SERUM	31 *	15-30	
TOTAL CHOLESTEROL AND HDL RATIO			
INTERPRETATIVE[2]TOTAL CHOLESTEROL/HDL	5.6 *	3.5-5.0	
CHOLESTEROL RATIO (Calculated)			

Name : **Mr. SUMIT KUMAR SAHU** Age : **34Yr 9Mth 19Days** Gender : **Male**
 UHID : ASHB.0000055867 / BPLAH11723 W/BNo/RefNo : AHC
 SIN \ LRN : 200929 \ 200930 \ 200931 \ 79958
 Specimen : Blood
 Ref Doctor : Dr. Akhil Kumar Tiwari



Collected on : 09-NOV-2024 09:45:42 AM Received on : 09-NOV-2024 10:21:21 AM Reported on : 09-NOV-2024 12:20:37 PM

PROTEIN TOTAL - SERUM / PLASMA			
PROTEIN TOTAL - SERUM	7.0	6.6-8.3	g/dL
ALBUMIN - SERUM	4.7	3.5-5.2	g/dL
GLOBULIN - SERUM			
GLOBULIN	2.3 *	2.6 - 4.6	g/dL
ALBUMIN/GLOBULIN RATIO			
ALBUMIN AND GLOBULIN RATIO	2.0	0.9-2.0	
AST (SGOT) - SERUM	29	< 50	U/L
ALT(SGPT) - SERUM / PLASMA			
ALT(SGPT) - SERUM	43	<50	U/L
BILIRUBIN, TOTAL - SERUM			
BILIRUBIN TOTAL	0.5	0.3-1.2	mg/dL
BILIRUBIN CONJUGATED (DIRECT) - SERUM			
BILIRUBIN CONJUGATED (DIRECT)	0.1	<0.2	mg/dL
BILIRUBIN UNCONJUGATED (INDIRECT) - SERUM			
BILIRUBIN UNCONJUGATED (INDIRECT)	0.4	0.1-1.2	mg/dL
ALKALINE PHOSPHATASE - SERUM/PLASMA			
ALKALINE PHOSPHATASE - SERUM	56	30-120	U/L
GGTP: GAMMA GLUTAMYL TRANSPEPTIDASE - SERUM			
GAMMA GLUTAMYL TRANSPEPTIDASE - SERUM	19	0 - 55	U/L
CREATININE - SERUM / PLASMA	0.88	0.72 - 1.18	mg/dL
URIC ACID - SERUM / PLASMA	6.8	3.5-7.2	mg/dL
BUN (BLOOD UREA NITROGEN)	7.7	Male: <50yrs 8.87-20.5 mg/dl Male:>50yrs 8.41-25.7 mg/dl	mg/dL
TOTAL T3: TRI IODOTHYRONINE - SERUM	0.97	0.60-1.81	ng/ml

Name : Mr. SUMIT KUMAR SAHU Age : 34Yr 9Mth 19Days Gender : Male
UHID : ASHB.0000055867 / BPLAH11723 W/BNo/RefNo : AHC
SIN \ LRN : 200929 \ 200930 \ 200931 \ 79958
Specimen : Blood
Ref Doctor : Dr. Akhil Kumar Tiwari



Collected on : 09-NOV-2024 09:45:42 AM Received on : 09-NOV-2024 10:21:21 AM Reported on : 09-NOV-2024 12:20:37 PM

TOTAL T4: THYROXINE - SERUM	8.52	5.01 - 12.45	µg/dL
TSH: THYROID STIMULATING HORMONE - SERUM	2.27	0.35-5.50	µIU/mL

Report Status:Final

* END OF REPORT *

CHECKED BY 154494
727938

Printed On : 12-NOV-2024 10:46:05 AM

Dr. Shubhra Prasad
Consultant Pathologist

Name : **Mr. SUMIT KUMAR SAHU** Age : **34Yr 9Mth 19Days** Gender : **Male**
 UHID : ASHB.0000055867 / BPLAH11723 W/BNo/RefNo : AHC
 SIN \LRN : 200928 \ 200933 \ 79958
 Specimen : Urine
 Ref Doctor : Dr. Akhil Kumar Tiwari



Collected on : 09-NOV-2024 09:45:42 AM Received on : 09-NOV-2024 11:21:15 AM Reported on : 09-NOV-2024 01:54:43 PM

MEDIWHEEL FULL BODY HEALTH PLUS BELOW 40 ADVANCED-MALE

<u>TEST NAME</u>	<u>RESULT</u>	<u>BIOLOGICAL REFERENCE INTERVALS</u>	<u>UNITS</u>
CBC			
HAEMOGLOBIN	15.4	13.0-17.0	g/dL
Packed cell volume (Calculated)	48.1	38.3-48.6	%
RBC COUNT(Impedance)	5.54	4.50-5.90	Million/ul
MCV-	86.9	80-100	fl
MCH-	27.8	27-32	pg
MCHC-	32.1	32-36	g/dL
RDW (Derived from RBC histogram)	15.8 *	11.8 - 14.5	%
TLC COUNT	6.80	4.0-11.0	10 ³ /mm ³
DIFFERENTIAL COUNT			
Neutrophils	52	40-80	%
Lymphocytes	38	20-40	%
Monocytes	5	2-10	%
Eosinophils	5	1-6	%
Basophils	0	0-2	%
Platelet Count(Impedance)	166.0	150-450	10 ³ /mm ³
Mean Platelet Volume	11.92	6.5-12.0	fl
ERYTHROCYTE SEDIMENTATION RATE (ESR)	1	0-15	mm/1st hr
URINE ROUTINE (CUE)			
MACROSCOPIC EXAMINATION			
Specific Gravity(Automated – Reflectance Spectrometer)	1.010	1.005 - 1.025	
Colour:(Naked Eye Examination)	Pale-Yellow		

Name : **Mr. SUMIT KUMAR SAHU** Age : **34Yr 9Mth 19Days** Gender : **Male**
 UHID : ASHB.0000055867 / BPLAH11723 W/BNo/RefNo : AHC
 SIN \LRN : 200928 \ 200933 \ 79958
 Specimen : Urine
 Ref Doctor : Dr. Akhil Kumar Tiwari



Collected on : 09-NOV-2024 09:45:42 AM Received on : 09-NOV-2024 11:21:15 AM Reported on : 09-NOV-2024 01:54:43 PM

Transparency:(Naked Eye Examination)	Clear		
pH(Automated – Reflectance Spectrometer)	Neutral		
Protein :(Automated – Reflectance Spectrometer/Sulpho salicylic acid method)	Nil		
Sugar:(Automated - Reflectance Spectrometer/ Benedict's Test)	Nil		
Ketone(Automated – Reflectance Spectrometer/Rothera's test)	Nil		
Bilirubin: (Automated – Reflectance Spectrometer/Fouchet's method)	Nil		
Cells:			
RBC(Automated - Reflectance spectrometer/Microscopy/Flow cytometric)	Nil		
Pus Cells(Automated – Reflectance spectrometer/Microscopy/Flow cytometric)	1-2	0.0 - 5.0/HPF	/hpf
Epithelial Cells(Microscopic /Flow cytometric)	1-2	<20	/hpf
Yeast Cells	Absent		
Bacteria:	Absent		
Casts:(Microscopic /Flow cytometric)	Absent	ABSENT	
Crystals:(Microscopic /Flow cytometric)	Absent		

Name : **Mr. SUMIT KUMAR SAHU** Age : **34Yr 9Mth 19Days** Gender : **Male**
UHID : ASHB.0000055867 / BPLAH11723 W/BNo/RefNo : AHC
SIN \LRN : 200928 \ 200933 \ 79958
Specimen : Urine
Ref Doctor : Dr. Akhil Kumar Tiwari



Collected on : 09-NOV-2024 09:45:42 AM Received on : 09-NOV-2024 11:21:15 AM Reported on : 09-NOV-2024 01:54:43 PM

Report Status:Final

* END OF REPORT *

CHECKED BY : 727938
727938

A handwritten signature in black ink, appearing to read 'Dr. Shubhra Prasad', written over a light blue rectangular background.

Dr. Shubhra Prasad
Consultant Pathologist

Printed On : 12-NOV-2024 10:46:29 AM

Name : Mr. SUMIT KUMAR SAHU Age : 34Yr 9Mth 19Days Gender : Male
UHID : ASHB.0000055867 / BPLAH11723 W/BNo/RefNo : AHC
SIN \LRN : 200932 \ 79958
Specimen : Blood
Ref Doctor : Dr. Akhil Kumar Tiwari



Collected on : 09-NOV-2024 09:45:42 AM Received on : 09-NOV-2024 11:34:15 AM Reported on : 09-NOV-2024 11:47:12 AM

MEDIWHEEL FULL BODY HEALTH PLUS BELOW 40 ADVANCED-MALE

TEST NAME

RESULT

BLOOD GROUPING AND TYPING (ABO and Rh)

ABO Group:

B

Rh (D) Type:

Positive

Report Status:Final

* END OF REPORT *

CHECKED BY : 154612

725449

Dr. Samir Singh
Consultant Blood Bank

Printed On : 12-NOV-2024 10:46:45 AM

Dr. Siddharth Malaiya



M.B.B.S, M.S (Ophthalmology), F.L.V.P.E.I, Hyd. (Cornea & LASIK)

F.R.H.E.C, Australia (Ocular surface & Stem cells)

Fellow I. V Prasad Eye Institute, Hyderabad, Ex-Faculty ASG Eye Hospital, Jodhpur

Consultant Ophthalmologist & Cornea Super-specialist

Phaco-refractive & Cornea transplant surgeon

Name: Mrs. Samsit Karmar

Age/Sex: 34/M

Date: 9/11/24

Ch: His unmy glasses

Vision	UCVA	Glasses	Pinhole
RE	6/12		
LE	6/9 (P)		

AR	R	L
	-1.5	
	-0.5	-0.75 x 80

Eye	Sphere	Cylinder	Axis	BCVA
RE	-1.0			6/6
LE		-0.75	80	6/6
Add	No			

PG	R	L



Hu, Sumit Kumar
D. 30067

09/11/2024 11:35:30

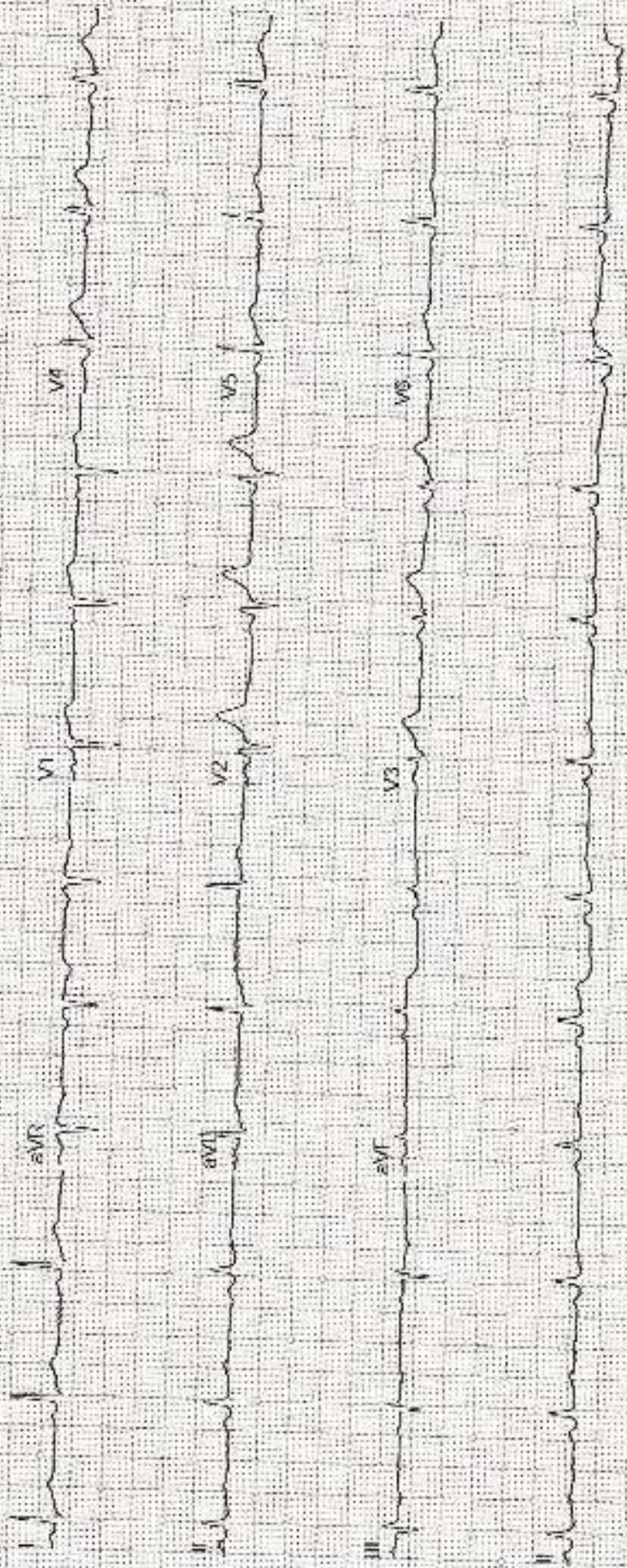
Location: Room: 71 bonn
Order Number: - / - / -
Indication: Arrhythmia
Medication 1:
Medication 2:
Medication 3:

Normal sinus rhythm
Normal ECG

QT/QTc Baz 84 ms
PR 366 / 387 ms
P 140 ms
RR/PP 106 ms
P/ORS/T 850 / 845 ms
44.7 / 2 / 16 degrees

Technician:
Operator: Ph.
Examiner: Ph.
Attending: Ph.

[Handwritten signature]



Patient's Name	Sumit Kumar Sahu	Date	09/11/2024
Age/Sex	34Y/M	UHID	HC -55867
Referred By	Health Check	Done By	Dr.Gaurav Khandelwal

M- Mode / 2D Measurements:

LA	31mm	Ao	23mm
IVSd	11mm	IVSs	15mm
LVEDd	46mm	LVEDs	27mm
PWd	11mm	PWs	15mm
RA	27mm	RV	22mm

Doppler Study :-


Valves	Measurements			
Mitral Valve	E : 1.0m/sec	A : 0.5m/sec	E/A : 1.8	E' : m/sec
Aortic Valve	AV Vmax : 1.08m/sec	-	-	-
Tricuspid Valve	TR PG : 09mmHg	-	-	-
Pulmonary Valve	PV Vmax : 1.1m/sec	-	-	-

2D ECHO Doppler

Dimensions : Normal Chamber Dimensions
Mitral Valve : Normal
Aortic Valve : Normal
Tricuspid Valve : Normal
Pulmonary Valve : Normal
Pericardium : Normal
IVC : Normal
Diastolic Function : Normal
IAS/ IVS : Intact
RWMA : No **LVEF : 60%**

Impression:

- Normal 2D ECHO & Doppler Study
- No RWMA at Rest (LVEF : 60%)


DR. GAURAV KHANDELWAL
 DM (Cardiology), FACC, FESC, FSCAI, FIC
 INTERVENTIONAL CARDIOLOGIST

Patient Name:	SUMIT KUMAR SAHU	Patient ID:	ASHB.0000055867
Age:	34 Years	Sex:	M
Accession Number:	17101.224013179	Modality:	US
Referring Physician:	Akhil Kumar Tiwari	Study:	ULTRASOUND - WHOLE ABDOMEN
Study Date:	09-Nov-2024		

ULTRA SONOGRAPHY ABDOMEN

Liver:- is normal in size and shows increased echotexture with preserved periportal echoes. Portal and hepatic venous system appears normal. Intra and extra hepatic biliary radicals are not dilated.

Gall Bladder:- is partially contracted (non fasting status).

Pancreas is normal in size outline and echopattern.

Spleen is normal in size and echopattern.

Both kidneys are normal in size, shape and echogenicity. Central pelvicalyceal sinus and corticomedullary ratio are normal.

Right kidney measures:- 9.8 x 4.3 cm

Left kidney measures:- 9.4 x 4.3 cm

Urinary bladder is normal in shape and contour. Its wall is normal.


Prostate is normal in size and shape and echotexture. Estimated volume is-14 cc.

No evidence of ascites is seen.

IMPRESSION:- Sonography Study Reveals:-

- **Grade I fatty liver changes .**

ADV:- Clinical Correlation.



DR. HARI SANTOSH
CONSULTANT RADIOLOGIST

Patient Name:	SUMIT KUMAR SAHU	Patient ID:	ASHB.0000055887
Age:	34 Years	Sex:	M
Accession Number:	17101 124019691	Modality:	DX
Referring Physician:	Akhil Kumar Tiwari	Study:	CHEST
Study Date:	09-Nov-2024		

X-RAY CHEST (PA VIEW)

Both lung fields are clear. No active pleural or parenchymal lesion is seen.

The hila, mediastinum, bony thoracic cage and the diaphragmatic domes are normal.


The costophrenic and cardiophrenic angles are clear.

The cardiac silhouette is unremarkable.

IMP:- RADIOGRAPHIC IMAGE REVEALS:-

No significant abnormality detected.

Thanks for Ref



DR. HARISANTOSH
CONSULTANT RADIOLOGIST

Date: 09-Nov-2024 12:29:33

