



नीयाम ट्रस्ट जनरल हॉस्पिटल
&
प्रसूतिगृह



 GPS Map Camera

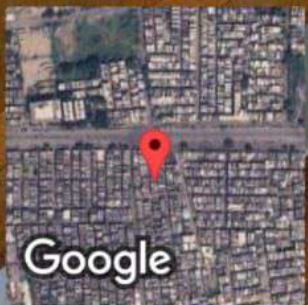Surat, Gujarat, India

A78, Keshar Bhawani Society, Maharana Pratap Nagar, Godadara, Surat, Gujarat
395012, India

Lat 21.174836°

Long 72.873823°

07/09/24 09:39 AM GMT +05:30



Google



भारत सरकार

GOVERNMENT OF INDIA



प्रीती सिंह

Preeti Singh

जन्म तिथि/ DOB: 05/08/1989

महिला / FEMALE



6333 4306 1430

मेरा आधार, मेरी पहचान



भारतीय विशिष्ट पहचान प्राधिकरण
UNIQUE IDENTIFICATION AUTHORITY OF INDIA

पता:

अर्धांगिनी: मधुकर सिंह,
594 घा/297, दुर्गापुरी
कॉलोनी नीलमथा, लखनऊ,
लखनऊ,
उत्तर प्रदेश - 226002

Address:

W/O: Madhukar Singh, 594
Gha/297, Durgapuri colony
Neelmata, Lucknow, Lucknow,
Uttar Pradesh - 226002

6333 4306 1430


MERA AADHAAR, MERI PEHACHAN

HAEMOGRAM PROFILE

<u>TEST</u>	<u>RESULT</u>	<u>UNIT</u>	<u>METHOD</u>	<u>REFERENCE INTERVAL</u>
<u>BLOOD COUNTS & INDICES</u>				
Haemoglobin	↓ : 10.90	(76 %gm%		12.0 - 16.0 gm%
Total RBC	↓ : 3.89	mill/cmm		4.2 - 5.4 mill/cmm
PCV	↓ : 34.00	%		37 - 47 %
MCV	: 87.40	fL		80 - 96 fL
MCH	: 28.02	pg		27 - 31 pg
MCHC	: 32.05	%		32 - 36 %
RDW	: 14.30	%		10 - 15 %
Total WBC	: 8,000	/cmm		4,000 - 11,000/cmm
Platelet Count	: 1,50,000	/cmm		1.5 - 4.0 Lac/cmm.
<u>DIFFERENTIAL LEUCOCYTES COUNT</u>				
Band Cells	: 00	%		00 - 06 %
Neutrophils	: 65	%		55 - 70 %
Lymphocytes	: 27	%		20 - 40 %
Eosinophils	: 04	%		01 - 06 %
Monocytes	: 04	%		02 - 08 %
Basophils	: 00	%		00 - 01 %
<u>ABSOLUTE COUNTS</u>				
Neutrophils	: 5200	/μL		2000 - 7000 /μL
Lymphocytes	: 2160	/μL		800 - 4000 /μL
Eosinophils	: 320	/μL		20 - 500 /μL
Monocytes	: 320	/μL		120 - 1200 /μL
Platelet In Smear	: ADEQUATE			
<u>ERYTHROCYTES SEDIMENTATION RATE</u>				
ESR After 1st Hour	: 12	mm	Westergren	03 - 12 mm

(Done on Fully Automated Cell Counter NIHON KOHDEN CELL TECH ALFA)

End Of Report




Dr. Krishna Vaghani



M.D.(Pathologist)

Reg No. G - 24342

Investigations have their limitations, Solitary Pathological and other investigations never confirm the final diagnosis of the disease. This only help in diagnosing the disease in correlation to clinical symptoms & other related tests. Please interpret accordingly.

 mailforuniversal@gmail.com

 Main Branch : 125-126, 1st Floor, La Citadell,
Near Kangaroo Circle, Beside CNG Pump,
Magob, Parvat Patiya, Surat - 395 010.

 98253 60243  82001 18966

UNIVERSAL LABORATORY

ESTD : 2013



 mailforuniversal1@gmail.com

 Mota Varachha Branch : Shop No. 109,
1st Floor, ABC Complex-2, ABC Circle,
Mota Varachha, Surat - 394 101.

 79844 42849



Report Of
PREETI SINGH

Date: **07/09/2024** Lab No.: **20** Age/Gender: **35 Yrs./F** Regi. No.:

Referring Dr.: **NIRAMAY TRUST GENERAL HOSPITAL & PRASUTIGRUH.**

Info. Code : 10/4500_0_4500_0

BLOOD GLUCOSE ANALYSIS

<u>TEST</u>	<u>RESULT</u>	<u>UNIT</u>	<u>REFERENCE INTERVAL</u>
<u>FASTING</u>			
Blood Glucose	: 80.0	mg/dl	70 - 110 mg/dl
Urine Glucose	: NIL		
Urine Acetone	: NIL		
<u>POST-PRANDIAL (PPBS)</u>			
Blood Glucose	: 110.0	mg/dl	up to 140 mg/dl
Urine Glucose	: NIL		
Urine Acetone	: NIL		

(Done on Automated Random Access Biochemistry Analyzer RX - 50)

End Of Report

Krishna V


Dr. Krishna Vaghani

M.D.(Pathologist)

Reg No. G - 24342

Investigations have their limitations, Solitary Pathological and other investigations never confirm the final diagnosis of the disease. This only help in diagnosing the disease in correlation to clinical symptoms & other related tests. Please interpret accordingly.

 mailforuniversal@gmail.com

 Main Branch : 125-126, 1st Floor, La Citadell,
Near Kangaroo Circle, Beside CNG Pump,
Magob, Parvat Patiya, Surat - 395 010.


 98253 60243  82001 18966


UNIVERSAL LABORATORY

ESTD : 2013



 mailforuniversal1@gmail.com

 Mota Varachha Branch : Shop No. 109,
1st Floor, ABC Complex-2, ABC Circle,
Mota Varachha, Surat - 394 101.

 79844 42849

LIPID PROFILE

TEST	RESULT	UNIT	REFERENCE INTERVAL
Total Lipid (Calculated)	: 524	mg/dL	350 - 750 mg/dL
Serum Cholesterol	: 176.0	mg/dL	130 - 200 mg/dL
Serum Triglyceride	: 100.0	mg/dL	<150 : Normal
HDL Cholesterol	: 38.0	mg/dL	30 - 70 mg/dL
LDL Cholesterol	: 118.0	mg/dL	Upto 150 mg/dL
CHOL./HDL Chol. Ratio	: 4.63	: 1	Less than 5
LDL Chol/HDL Chol Ratio	: 3.10	: 1	Less than 3.5
VLDL (Calculated)	: 20.00	mg/dL	Upto 30 mg/dL
Non HDL Cholesterol (Calculated)	: 138.00	mg/dL	

Interpretation Based On New N.C.E.P. Guidelines

Test	Result (mg/dL)	Interpretation
CHOLESTEROL	< 200	Desirable
	200 - 239	Borderline
	> = 240	High
TRIGLYCERIDES	< 170	Normal
	170 - 199	Borderline
	> 200	High
LDL CHOLESTEROL	< 100	Desirable
	100 - 129	Sub-Optional
	130 - 159	Borderline High
HDL CHOLESTEROL	> 160	High
	< 35	Low
	> 60	High

(Done on Automated Random Access Biochemistry Analyzer RX - 50)

End Of Report

Krishna V

Dr. Krishna Vaghani

M.D.(Pathologist)

Reg No. G - 24342

Investigations have their limitations, Solitary Pathological and other investigations never confirm the final diagnosis of the disease. This only help in diagnosing the disease in correlation to clinical symptoms & other related tests. Please interpret accordingly.

mailforuniversal@gmail.com

Main Branch : 125-126, 1st Floor, La Citadell,
Near Kangaroo Circle, Beside CNG Pump,
Magob, Parvat Patiya, Surat - 395 010.

98253 60243 82001 18966

UNIVERSAL LABORATORY

ESTD : 2013



mailforuniversal1@gmail.com

Mota Varachha Branch : Shop No. 109,
1st Floor, ABC Complex-2, ABC Circle,
Mota Varachha, Surat - 394 101.

79844 42849



Report Of
PREETI SINGH

Date: **07/09/2024** Lab No: **20** Age/Gender: **35 Yrs./F** Regi. No.

Referring Dr. **NIRAMAY TRUST GENERAL HOSPITAL & PRASUTIGRUH.**

Info. Code : 10/4500_0_4500_0

Hb A1C REPORT

TEST	RESULT	UNIT	REFERENCE INTERVAL
Hb A1C - Glycated Hb Glycated Haemoglobin	: 5.6	%	Non Diabetic : 4.3 - 6.3 % Good Control : 6.4 - 7.5 % Moderate Control : 7.5 - 9.0 % Poor Control : 9.0 % & Above
Avg. Blood Glucose Level	: 122	mg/dL	
Estimated Average Glucose eAG	: 114	mg%	

Notes :

Average Blood Glucose		Hemoglobin A1c%
421	-	14 %
385	-	13 %
350	-	12 %
314	-	11 %
278	-	10 %
243	-	09 %
207	-	08 %
171	-	07 %
136	-	06 %
100	-	05 %
065	-	04 %

End Of Report



Krishna V

Dr. Krishna Vaghani
M.D.(Pathologist)
Reg No. G - 24342

Investigations have their limitations, Solitary Pathological and other investigations never confirm the final diagnosis of the disease. This only help in diagnosing the disease in correlation to clinical symptoms & other related tests. Please interpret accordingly.

mailforuniversal@gmail.com

Main Branch : 125-126, 1st Floor, La Citadell,
Near Kangaroo Circle, Beside CNG Pump,
Magob, Parvat Patiya, Surat - 395 010.

98253 60243 82001 18966

UNIVERSAL LABORATORY
ESTD : 2013



mailforuniversal1@gmail.com

Mota Varachha Branch : Shop No. 109,
1st Floor, ABC Complex-2, ABC Circle,
Mota Varachha, Surat - 394 101.

79844 42849



Report Of
PREETI SINGH

Date: **07/09/2024** Lab No. **20** Age/Gender **35 Yrs./F** Regi. No.

Referrina Dr. **NIRAMAY TRUST GENERAL HOSPITAL & PRASUTIGRUH.**

Info. Code : 10/4500_0_4500_0

LIVER FUNCTION TEST

<u>TEST</u>	<u>RESULT</u>	<u>UNIT</u>	<u>REFERENCE INTERVAL</u>
<u>S. BILIRUBIN</u>			
Total	: 0.60	mg/dl	0 - 1.0 mg/dl
Direct	: 0.20	mg/dl	up to 0.3 mg/dl
Indirect	: 0.40	mg/dl	0.1 - 1.0 mg/dl
S. Alk. Phosphatase	: 102	U/L	Adult : up to 290 U/L Children: up to 1200 U/L
S.G.P.T.	: 24	U/L	10 - 40 U/L
S.G.O.T.	: 26	IU/L	up to 40 IU/L
<u>SERUM PROTEIN</u>			
Total Protein	: 6.90	g/dl	6.0 - 8.2 gm/dl
Albumin	: 4.20	g/dl	3.5 - 5.0 g/dl
Globulin	: 2.70	g/dl	2.3 - 3.5 g/dl
A.G. Ratio	: 1.6		2.5 - 1.2 : 1
S. Australia Antigen (HBs Ag)	: TEST IS NEGATIVE		Negative
Kit Used	: HEPACARD		
Bile Salts	: NIL		
Bile Pigments	: NIL		
<u>PROTHROMBIN TIME</u>			
Patient's P. T.	: 14.00	sec	
Control's P. T.	: 14.00	sec	
ISI	: 1.05		
P. Index	: 100.00	%	
P.Ratio	: 1.00		
INR	: 1.00		

(Done on Automated Random Access Biochemistry Analyzer RX - 50)

End Of Report

Dr. Krishna Vaghani

M.D.(Pathologist)

Reg No. G - 24342

Investigations have their limitations, Solitary Pathological and other investigations never confirm the final diagnosis of the disease. This only help in diagnosing the disease in correlation to clinical symptoms & other related tests. Please interpret accordingly.

mailforuniversal@gmail.com

Main Branch : 125-126, 1st Floor, La Citadell,
Near Kangaroo Circle, Beside CNG Pump,
Magob, Parvat Patiya, Surat - 395 010.

98253 60243 82001 18966

UNIVERSAL LABORATORY

ESTD : 2013



mailforuniversal1@gmail.com

Mota Varachha Branch : Shop No. 109,
1st Floor, ABC Complex-2, ABC Circle,
Mota Varachha, Surat - 394 101.

79844 42849



Report Of
PREETI SINGH

Date **07/09/2024** Lab No. **20** Age/Gender **35 Yrs./F** Regi. No.

Referring Dr.
NIRAMAY TRUST GENERAL HOSPITAL & PRASUTIGRUH.

Info. Code : 10/4500_0_4500_0

RENAL FUNCTION TEST

<u>TEST</u>	<u>RESULT</u>	<u>UNIT</u>	<u>METHOD</u>	<u>REFERENCE INTERVAL</u>
Blood Urea	: 29.30	mg/dl	DRY CHEMISTRY	10-50 mg/dl
Blood Urea Nitrogen	: 9.76	mg/dl		3.30 - 18.70 mg/dl
Serum Creatinine	: 0.68	mg/dl	DRYCHEMISTRY	0.6 - 1.4 mg %
Serum Sodium	: 139.00	mmol/L	I.S.E.	135-145 mmol/L
Serum Potassium	: 5.00	mmol/L	I.S.E.	3.50 - 5.10 mmol/L
Serum Chloride	: 103.00	mmol/L	I.S.E.	96 - 110 mmol/L
Serum Uric Acid	: 4.00	mg/dl		3.20 - 6.10 mg/dl
Serum Calcium	: 8.50	mg/dl	Dry Chemistry	8.5 - 10.5 mg/dl

Done on Fully Automated Random Access Biochemistry Analyzer; Mspa Nano.

End Of Report

Krishna


Dr. Krishna Vaghani



M.D.(Pathologist)

Reg No. G - 24342

Investigations have their limitations, Solitary Pathological and other investigations never confirm the final diagnosis of the disease. This only help in diagnosing the disease in correlation to clinical symptoms & other related tests. Please interpret accordingly.

 mailforuniversal@gmail.com

 Main Branch : 125-126, 1st Floor, La Citadell,
Near Kangaroo Circle, Beside CNG Pump,
Magob, Parvat Patiya, Surat - 395 010.

 98253 60243  82001 18966


UNIVERSAL LABORATORY

ESTD : 2013



 mailforuniversal1@gmail.com

 Mota Varachha Branch : Shop No. 109,
1st Floor, ABC Complex-2, ABC Circle,
Mota Varachha, Surat - 394 101.

 79844 42849



Report Of
PREETI SINGH

Date **07/09/2024** Lab No. **20** Age/Gender **35 Yrs./F** Regi. No.

Referring Dr. **NIRAMAY TRUST GENERAL HOSPITAL & PRASUTIGRUH.**

Info. Code : 10/4500_0_4500_0

THYROID FUNCTION TEST

TEST	RESULT	UNIT	METHOD	REFERENCE INTERVAL
Total Triiodothyronine(T3)	: 0.68	ng/ml	eCLIA	0.6-2.02 ng/ml
Total Thyroxine(T4)	: 9.53	ug/dl	eCLIA	5.13 - 12.60 ug/dl
Thyroid Stimulating Hormone (TSH)	: 3.250	uIU/ml	eCLIA	0.270 - 4.200 uIU/ml

NORMAL VALUES

Age	T3 ng/ml	T4 ug/dl	T.S.H. uIU/ml
01 - 12 Month	1.05 - 2.80	7.8 - 16.5	New Born : 1.3-19.0 3 Days : 1.1-17.0 10 weeks : 0.6-10.0 14 months: 0.4-7.0
01 - 05 Yrs	1.05 - 2.69	7.3 - 15.0	0.4-6.0
05 - 10 Yrs	0.94 - 2.41	6.04 - 13.3	0.25-5.25
10 - 15 Yrs	0.83 - 2.13	5.60 - 11.7	0.25-5.25
15 - 20 Yrs	0.80 - 2.00	4.20 - 11.8	0.25-5.25
> 20 Yrs	0.79 - 1.58	4.00 - 11.0	0.25-5.25

Done on Fully Automated Fluorescent Enzyme Immunoassay: TOSOH AIA 360; Japan.

End Of Report



Dr. Krishna Vaghani

M.D.(Pathologist)

Reg No. G - 24342

Investigations have their limitations, Solitary Pathological and other investigations never confirm the final diagnosis of the disease. This only help in diagnosing the disease in correlation to clinical symptoms & other related tests. Please interpret accordingly.

mailforuniversal@gmail.com

Main Branch : 125-126, 1st Floor, La Citadell,
Near Kangaroo Circle, Beside CNG Pump,
Magob, Parvat Patiya, Surat - 395 010.

98253 60243 82001 18966

UNIVERSAL LABORATORY

ESTD : 2013



mailforuniversal1@gmail.com

Mota Varachha Branch : Shop No. 109,
1st Floor, ABC Complex-2, ABC Circle,
Mota Varachha, Surat - 394 101.

79844 42849



NIRAMAY TRUST GENERAL HOSPITAL & PRASUTIGRUH
Reg No. G-0275 - Surat

NIRAMAY TRUST GENERAL HOSPITAL & PRASUTIGRUH



Dr. Tinish Nanavati

Date :- 7/9/21

Patient Name :- Preeti Singh.

Weight :- 67 - 90 kgs.

Age :- 35/48/F

B.P. :- 110/70

Height - 152.

Dr. Tinish Nanavati

M.D. (Medicine)

Consultant Physician, Intensivist,
Diabetologist and Cardiologist.

સામાન્ય ડિપાર્ટમેન્ટ, ઇન્ટેન્સિવ-કાર્ડિયોલોજી
& ડિયાબીટીસ સ્પેશિયાલિસ્ટ

Rx

To whom. See ever. it may concern.

Dr. Parul Parmar

MB, DGO (Obs & Gynec)

Senior Gyneacologist

(Fellowship in Infertility &

Laparoscopy & IUI Expert

સ્ત્રીરોગ અને પ્રસુતિના વિષયક

This is to Inform you that pt. name preeti Singh. age 35/F was

examined by me. and. All systemic.

R-S, CVS, P/A and. CNS examination was normal. pt is. physically fit.

Dr. Jignesh Savsaviya

M.S. (Surgeon) FMAS, FIAGES, FISC

Consultant General, Laparoscopic

& Gastrointestinal Surgeon

જનરલ, લેપ્રોસ્કોપીક અને ગેસ્ટ્રોઇન્ટેસ્ટલ સર્જન

Dr. Mayur Kalsariya

M.D. (Pediatrics)

(Consultant Pediatrician

& Neonatologist)

બાલક શીશુ અને ન્યોનેટોલોજીના વિષયક

Dr. Mahesh Ladumor

M.S. (Orthopaedics)

Orthopaedics Surgeon

Knee & Hip Replacement

Arthroscopy Specialist

કાંસળા રોગોના વિષયક (સર્જન)

Dr. Bhushan Dodia

M.S., M.Ch. (Urology)

Consultant Urologist, Andrologist

& Laparoscopic Surgeon

Dr. Haresh Balar

M.D. (Radiologist)

Tinish Nanavati
Dr. Tinish Nanavati
M.D. (Medicine)
Reg. No.: G-30362



42,76,77,78, Kesharbhavani Soc, Part-A, Opp. Dhur Park, Godadara Naher Road, Godadara, Surat. 395012

niramaygeneralhospital@gmail.com

Mo. 99799 85570



NIRAMAY TRUST GENERAL HOSPITAL & PRASUTIGRUH
Reg No. E-2075 - Surat

NIRAMAY TRUST GENERAL HOSPITAL & PRASUTIGRUH



Dr. Parul Parmar Date :- 7/9/24

Patient Name :- Prachi Singh Weight :-

Age :- B.P. :-

Dr. Tinish Nanavati

M.D. (Medicine)

Consultant Physician, Intensivist,

Diabetologist and Cardiologist.

અભ્યાસકેન્દ્ર ફિઝિશિયન, ઇન્ટેન્સિવિટી લોજીસ્ટ

& ડિયાબીટીસ અને હૃદયરોગોના સ્પેશિયાલિસ્ટ

Rx

Emp
3/9/24

Dr. Parul Parmar

MB, DGO (Obs & Gynec)

Senior Gynecologist

(Fellowship in Infertility &

Laparoscopy & IUI Expert

સ્ત્રીરોગ અને પ્રસુતિના વિભાગ

Dr. Jignesh Savsaviya

M.S. (Surgeon) FMAS, FIAGES, FISC

Consultant General, Laparoscopic

& Gastrointestinal Surgeon

જનરલ, લેપ્રોસ્કોપીક અને ગેસ્ટ્રોઇન્ટેસ્ટાલ સર્જન

Dr. Mayur Kalsariya

M.D. (Pediatrics)

(Consultant Pediatrician

& Neonatologist)

બાલકોના રોગો અને ન્યૂનેટોલોજીના વિભાગ

Dr. Mahesh Ladumor

M.S. (Orthopaedics)

Orthopaedics Surgeon

Knee & Hip Replacement

Arthroscopy Specialist

ઝાડાના રોગોના વિભાગ (સ્પર્શ)

Dr. Bhushan Dodia

M.S., M.Ch. (Urology)

Consultant Urologist, Andrologist

& Laparoscopic Surgeon

Dr. Haresh Balar

M.D. (Radiologist)

SIB. Dr. Parul

H10 ← 5th day of menses.

clo ← Nil

min ← Regular (28 days)
not painful

oin ← ♀ → 740 } Both
♂ → 2.5 years } Faluses

pin ← Nil significant


Adm

- Reassurance

- TO STOP Lactation

- Paps smear sent

UPS/O ←
2 small
Uterine
Fibroids



42,76,77,78, Kesharbhavani Soc, Part-A, Opp. Dhur Park, Godadara Naher Road, Godadara, Surat. 395012

niramaygeneralhospital@gmail.com

Mo. 99799 85570



NIRAMAY TRUST GENERAL HOSPITAL & PRASUTIGRUH
Reg No. C-8273 - Surat

NIRAMAY TRUST GENERAL HOSPITAL & PRASUTIGRUH



Dr. Date :- 9/9/21

Patient Name :- પ્રવેશ સુવર્ણ

Weight :- 67.300 kg.

Age :- 35 years

B.P. :- 110/70

Heart - 112

Dr. Tinish Nanavati

M.D. (Medicine)
Consultant Physician, Intensivist,
Diabetologist and Cardiologist.
ઉચ્ચશિક્ષિત ફિઝિશિયન, હાર્ટનો-સાથપિટીયોલોજીસ્ટ & ડિયાબીટોલોજિસ્ટ

Rx

Dietician consultation

સવારે વહેલી 5am થી...

ચોટા ખાંડ 30 min

1-2 hr ફરાર, 2. 1km ચાલવું.

7 am સવારે ઘણાં ઠાંડાં, ખાંડ,

મીઠાં જીરું, 1-2 ગ્લાસ ચાલવું,

મલાઈ વગર 2 દૈ, ઠાંડું 2-3 કમ.

10 am વાંટ 1-2 મીઠાં, 2-3 ગ્લાસ

ચાલવું,

12 pm :- ભોજન ભરવું, ઘણાં નાં

પ્રચારણાં કરવું.

3 pm - ઝીંક રી, 10-15 min ચાલવું.

7pm થી સવારે ચાલવું,

ફિટનેસ.

1 કમ નાં 20 ગ્લાસ ચાલવું,

1-2 hr ફરાર, વાહન ચાલવું

પ્રચારણાં થઈ ઇપેન્ડિંગ થવું.

Dr. Mahesh Ladumor

M.S. (Orthopaedics)
Orthopaedics Surgeon
Knee & Hip Replacement
Arthroscopy Specialist
ઘાંઠાના રોગોના નિષ્ણાંક (સર્જન)

Dr. Bhushan Dodia

M.S., M.Ch. (Urology)
Consultant Urologist, Andrologist
& Laparoscopic Surgeon

Dr. Haresh Balar

M.D. (Radiologist)

42,76,77,78, Kesharbhavani Soc, Part-A, Opp. Dhur Park, Godadara Naher Road, Godadara, Surat. 395012

niramaygeneralhospital@gmail.com

Mo. 99799 85570



NIRAMAY TRUST GENERAL HOSPITAL & PRASUTIGRUH
Reg No. 54271 - Surat

NIRAMAY TRUST GENERAL HOSPITAL & PRASUTIGRUH



Dr. Date :- 7/9/24

Patient Name :- Preeti S2wath

Weight :- 67.300 kg

Age :- 35 year / Female

B.P. :- 110/70 mmHg

Height - 152

Dr. Tinish Nanavati

M.D. (Medicine)
Consultant Physician, Intensivist,
Diabetologist and Cardiologist
અભ્યાસકક્ષા કિડનીશિયન, ઇન્ટેન્સિવ-કાર્યાલયોગ્ય
& હિટીસકેર સ્પેશ્યાલિસ્ટ

Rx

Dental consultation

Dr. Parul Parmar

MB, DGO (Obs & Gynec)
Senior Gynaecologist
(Fellowship in Infertility &
Laparoscopy & IUI Expert
સીસીસી અને પ્રજનન વિદ્યા

upper teeth - woman

lower teeth - woman

malocclusion - woman

Dr. Jignesh Savsaviya

M.S. (Surgeon) FMAS, FIAGES, FISC
Consultant General, Laparoscopic
& Gastrointestinal Surgeon
જનરલ, લેપ્રોસ્કોપીક અને ગેસ્ટ્રોઇન્ટેસ્ટીનલ સર્જન

no any teeth problem

⇒ ફાઇનલ ડાઇ ડાયગ્નોસીસ નો ઉપચાર

ફાઇનલ નહીં.

અચોર, ડાયગ્નોસીસ, અચોર, પિન્સાની

સિલિન્ડર નો ઉપચાર ફાઇનલ.

Dr. Mayur Kalsariya

M.D. (Pediatrics)
Consultant Pediatrician
& Neonatologist
બાલકો માટે શીશુ અને બાળરોગના વિદ્યા

Dr. Mahesh Ladumor

M.S. (Orthopaedics)
Orthopaedics Surgeon
Knee & Hip Replacement
Arthroscopy Specialist
ઔપચારિક રોગોના વિદ્યા (સર્જન)

Dr. Bhushan Dodia

M.S., M.Ch. (Urology)
Consultant Urologist, Andrologist
& Laparoscopic Surgeon

Dr. Haresh Balar

M.D. (Radiologist)



42,76,77,78, Kesharbhavani Soc, Part-A, Opp. Dhur Park, Godadara Naher Road, Godadara, Surat. 395012

niramaygeneralhospital@gmail.com

Mo. 99799 85570

Dr. Ronek Modi Date :- 19/04

Patient Name :- Preeti Singh

Weight :-

Age :-

B.P. :-

Dr. Tinish Nanavati

M.D. (Medicine)

Consultant Physician, Intensivist,
Diabetologist and Cardiologist.

કર્ણકેન્દ્ર શિડીકીયા, શરૂનો-કાયાપીડીઓજી
& શિડીકેન્દ્ર સ્પેશ્યાલિસ્ટ

Rx 2 DEchocardiography

• Good LV systolic function

• LVEF 60%.

• NO RWMA

• Normal diastolic dysfunction

• Trivial MR

• Normal aortic valve

• Trivial TR. Normal PA pressure

• IVC 10mm, collapsing

• NO clot, NO vegetation

• NO pericardial effusion

• Normal aortic root.

Conclusion:

• Good LV systolic function

• LVEF 60%.

• NO RWMA at rest

Dr. Parul Parmar

MB, DGO (Obs & Gynec)

Senior Gynaecologist

(Fellowship in Infertility &
Laparoscopy & IUI Expert
સર્જીકલ અને પ્રજનન વિષયક

Dr. Jignesh Savsaviya

M.S. (Surgeon) FMAS, FIAGES, FISCP

Consultant General, Laparoscopic
& Gastrointestinal Surgeon

જનરલ, લેપ્રોસ્કોપીક અને ગેસ્ટ્રોઇન્ટેસ્ટલ સર્જન

Dr. Mayur Kalsariya

M.D. (Pediatrics)

(Consultant Pediatrician
& Neonatologist)

બાલકોનો રોગો અને બાળકોનો વિષયક

Dr. Mahesh Ladumor

M.S. (Orthopaedics)

Orthopaedics Surgeon

Knee & Hip Replacement

Arthroscopy Specialist

કાસ્ટીકલ સર્જન વિષયક (સર્જન)

Dr. Bhushan Dodia

M.S., M.Ch. (Urology)

Consultant Urologist, Andrologist
& Laparoscopic Surgeon

Dr. Haresh Balar

M.D. (Radiologist)



Ronek Modi
Dr. Ronek Modi

નીરામય જનરલ હોસ્પિટલ & પ્રસુતિગૃહ

42,76,77,78, કેશરભવાની સોસાયટી, વિભાગ-A, ધુવપાર્ક ની સામે, ગોડાદરા નહેર રોડ, ગોડાદરા, સુરત. Mo. 99799 85570

Name:- _____ Date:- _____

Rx

Patient Name	: PREETI SINGH	Age / Sex	: 35/F
Ref. Doctor	: NIRAMAY TRUST GENERAL HOSPITAL & PRASUTIGRUH	Date	: 07/09/2024

USG: ABDOMEN & PELVIS

Liver is normal in size and echo texture. Surface is smooth and regular. No evidence of focal solid or cystic lesion seen. Intrahepatic biliary radicles are normal. Right and left portal veins, hepatic veins are normal. **Main portal vein** is normal in calibre.

Gall bladder is well distended and shows normal wall thickness. No evidence of calculus noted.

Pancreas is normal in size, shape and echo texture.

Spleen is enlarge in size(14.5cm) and with normal echo texture.

Both kidneys appear normal in size with homogenous echo pattern

Right kidney: 97x40 mm. **Left kidney:** 98x37 mm.

No evidence of calculus, hydronephrosis or hydroureter seen on either side.

CMD is preserved in both kidneys. No signs of renal abscess seen on any side.

Urinary bladder is partially distended and shows normal wall thickness. Lumen is echo free.

Uterus is retroverted measures 77 x 39 x47 mm in size. **Myometrial echo texture** is normal. **Approx 18x17mm size intramural fibroid** seen in posterior wall of uterus and **approx 26x24mm subserosal fibroid** seen in posterior wall of uterus. Cervix is normal. Endometrial thickness 8 mm. Endometrial cavity is empty.

Both ovaries are normal in size and show normal follicles.

No adnexal lesion seen on either side. No free fluid in POD.

Small and large bowel loops are unremarkable.

No evidence of abnormal bowel wall thickening or dilatation seen.

No evidence of mesenteric or retroperitoneal lymphadenopathy seen.


No evidence of ascites seen.

IMPRESSION:

- Mild splenomegaly.
- Uterine fibroids.

Thank you for the reference.



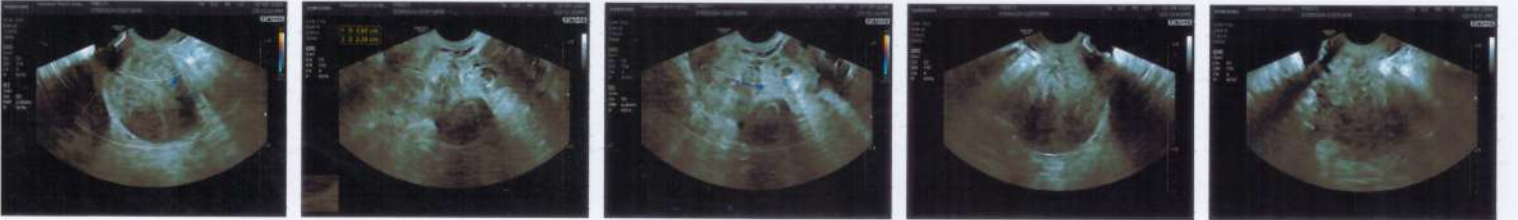
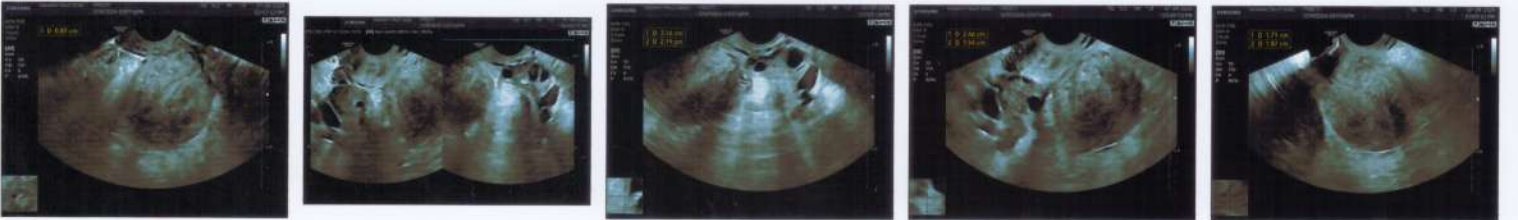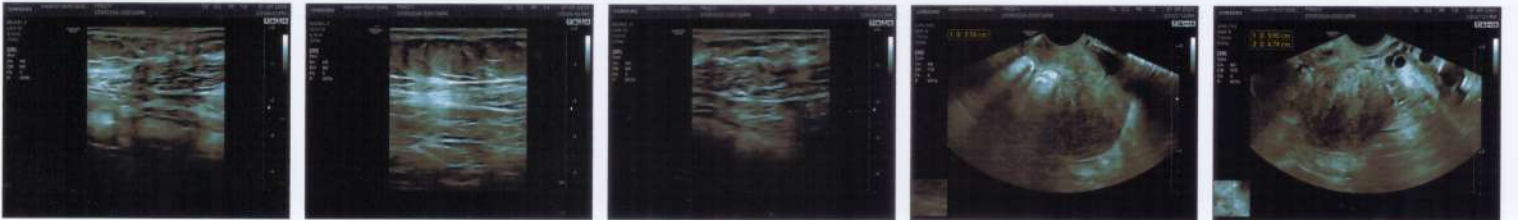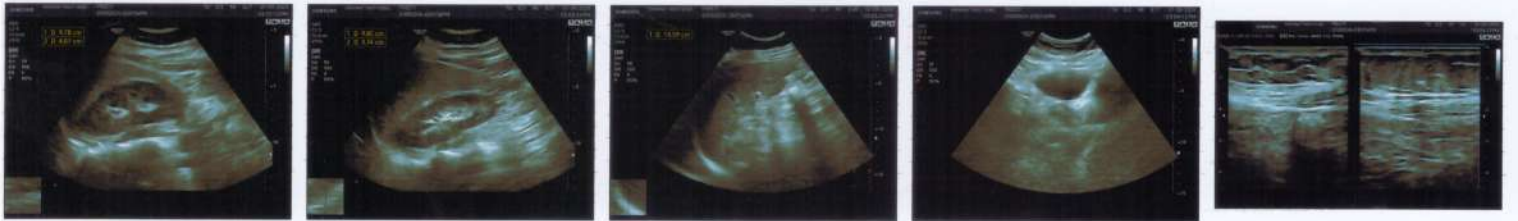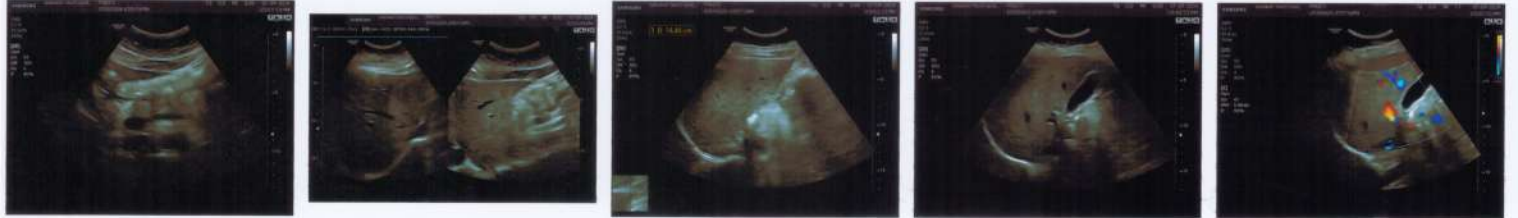DR. HARESH BALAR
CONSULTANT RADIOLOGIST
Dr. Haresh N. Balar
M.D. (Radiologist)
Reg. No.:- G-0517

Patient

ID 07092024-030116PM
Name PREETI
Birth Date
Gender Female

Exam

Accession #
Exam Date 07-09-2024
Description
Operator



નીરામય જનરલ હોસ્પિટલ & પ્રસુતિગૃહ

42,76,77,78, કેશરભવાની સોસાયટી, વિભાગ-A, ધુવપાર્ક ની સામે, ગોડાદરા નહેર રોડ, ગોડાદરા, સુરત. Mo. 99799 85570

Name:- _____ Date:- _____

Rx

Patient Name	:	PREETI SINGH	Age / Sex	:	34Y / F
Ref. Doctor	:	NIRAMAY TRUST GENERAL HOSPITAL & PRASUTIGRUH	Date	:	07/09/2024

USG BOTH BREAST

RIGHT BREAST

Right breast shows normal fibro fatty and glandular parenchymal echo pattern.
No evidence of focal solid or cystic lesion or calcification seen.
No evidence of abscess or hematoma seen.
No ductal ectasia.
Nipple and retro-areolar complex appear normal.
Right axillary region is unremarkable.

LEFT BREAST

Few prominent duct avz size 2.1-2.4mm seen in retro-areolar region at 2 o'clock position.
Rest of breast shows normal fibro fatty and glandular parenchymal echo pattern.
No evidence of focal solid or cystic lesion or calcification seen.
No evidence of abscess or hematoma seen.
No ductal ectasia.
Nipple appear normal.
Left axillary region is unremarkable.

CONCLUSION:

- Few prominent duct seen in retro-areolar region at 2 o'clock position.
- No other significant abnormality detected.

BI-RADS 0: inconclusive

BI-RADS 1: negative

BI-RADS 2: benign

BI-RADS 3: probably benign

BI-RADS 4: suspicious for malignancy

BI-RADS 5: highly suggestive of malignancy

BI-RADS 6: known biopsy-proven malignancy

Thank you for the reference.



Dr. Haresh Balar
Consultant Radiologist

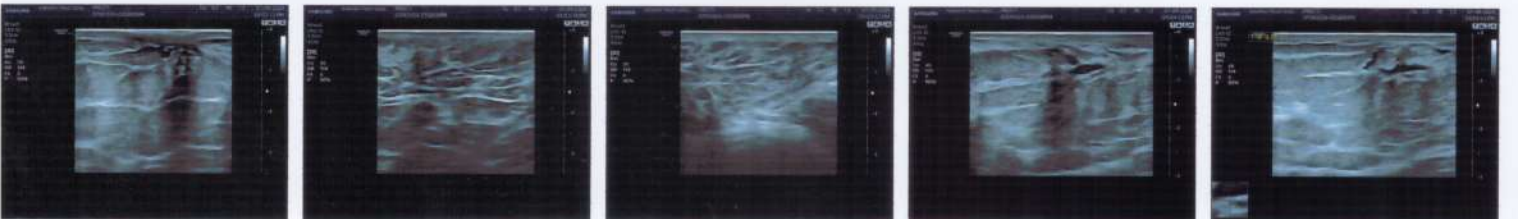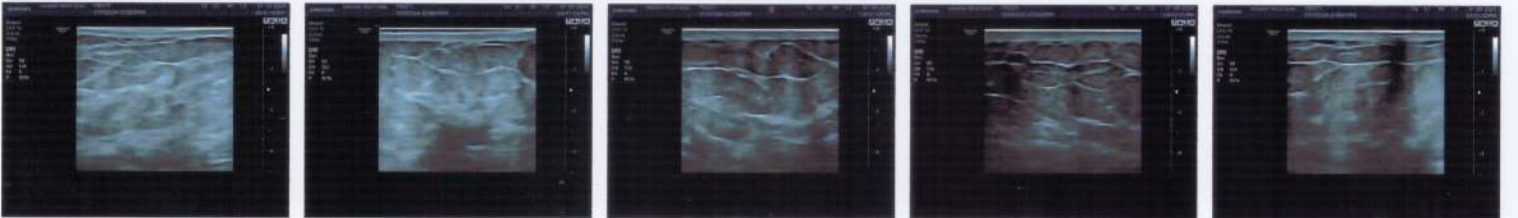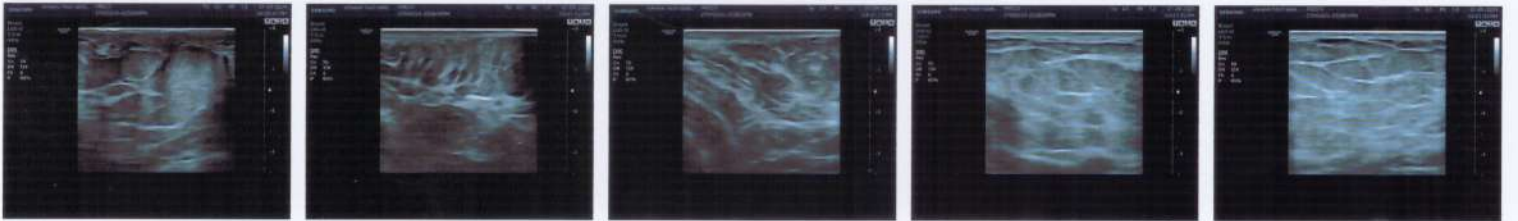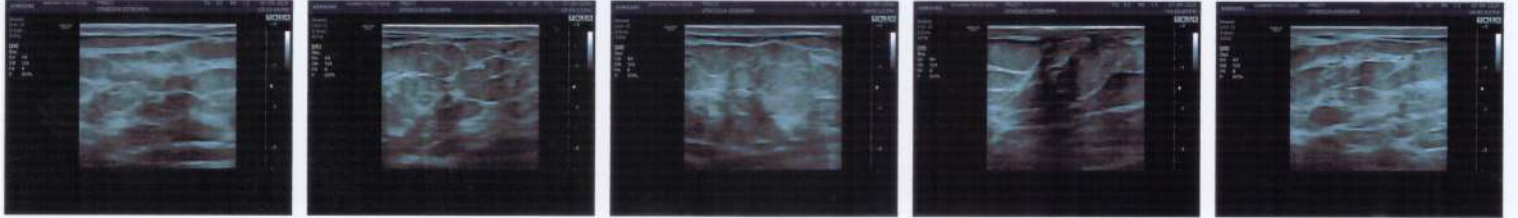Dr. Haresh N. Balar
M.D. (Radiologist)
Reg. No.:- G-0596

Patient

ID 07092024-035809PM
Name PREETI
Birth Date
Gender Female

Exam

Accession #
Exam Date 07-09-2024
Description
Operator



નીરામય જનરલ હોસ્પિટલ & પ્રસુતિગૃહ

42,76,77,78, કેશરભવાની સોસાયટી, વિભાગ-A, ધુવપાર્ક ની સામે, ગોડાદરા નહેર રોડ, ગોડાદરા, સુરત. Mo. 99799 85570

Name:- _____ Date:- _____

Rx

Patient Name	:	PREETI SINGH	Age / SeX	:	35/F
Ref. Doctor	:	NIRAMAY TRUST GENERAL HOSPITAL AND PRASUTI GRUH	Date	:	07/09/2024

CHEST RADIOGRAPH(PA VIEW)

Both lung fields appears clear.

Trachea is central in position.

Costophrenic angles are clear.

Cardio thoracic ratio is normal.

Mediastinal and hilar regions are normal.

Both diaphragmatic domes are well visualized and normal.

Visualized skeleton and soft tissues around thoracic cage appear normal.

IMPRESSION :

- No significant abnormality seen.

Please correlate clinically.

Report with thanks,



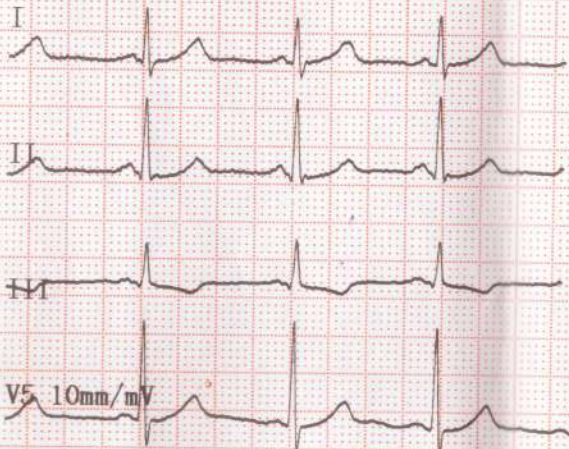
DR. HARESH BALAR
CONSULTANT RADIOLOGIST

Dr. Haresh N. Balar
M.D. (Radiologist)
Reg. No.: G-0596

PA

PREETI SINGH, 35 Y F, 07/09/2024 CHEST
NIRAMAY TRUST GENERAL HOSPITAL & PRASUTIGRUH

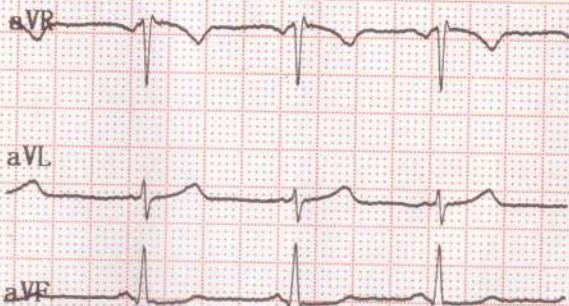AUTO 10mm/mV



V5 10mm/mV

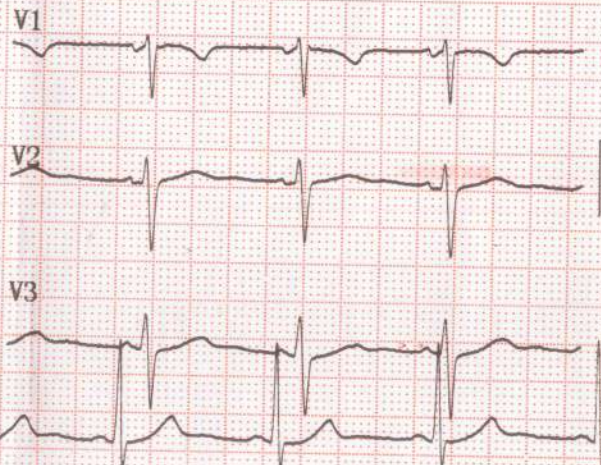
25mm/s EMC35Hz

10mm/mV

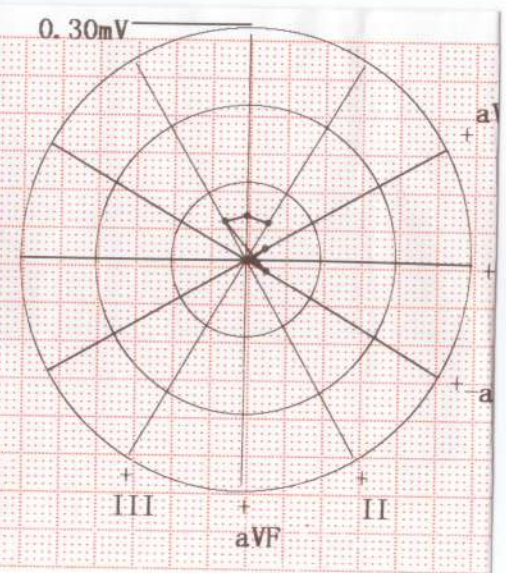
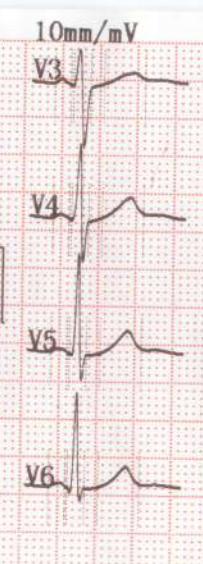
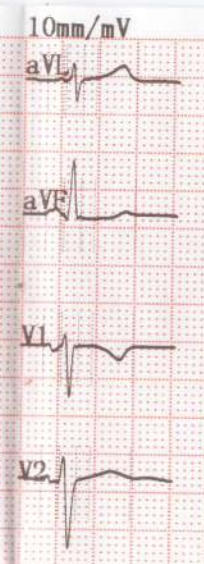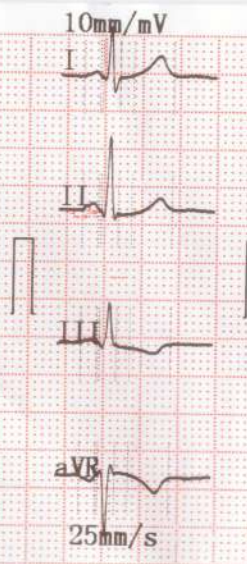
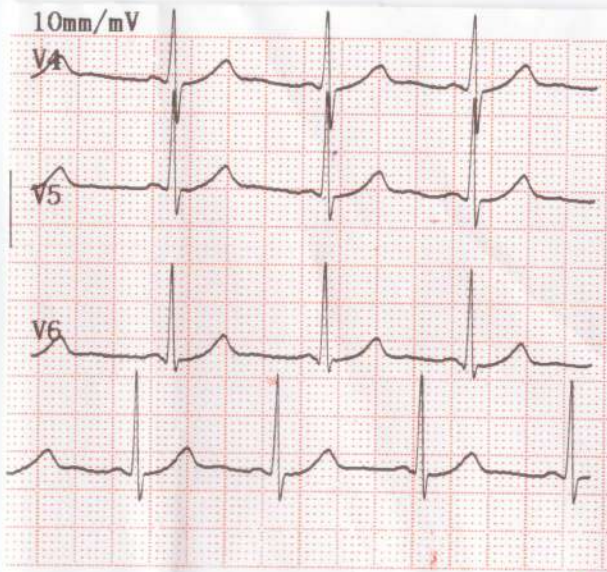


aVF

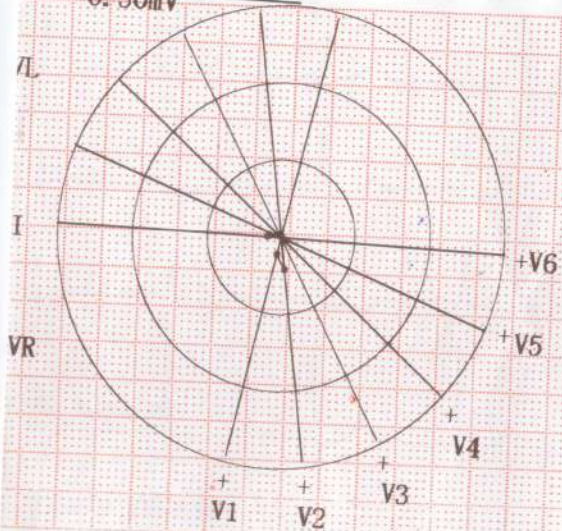
10mm/mV



V3



0.30mV



2024-09-07 10:11:23

<< Conclusions >>

aVL : 0.03 mV ID : 22532847
 I : 0.01 mV Name : Preeti Singh
 -aVR : 0.03 mV Sex : Female Age : 35
 II : -0.06 mV Height : 152 cm Weight : 67 kg
 aVF : -0.06 mV SYS : 110 mmHg
 III : -0.06 mV DIA : 70 mmHg

Cardiac electric axis normal,
 ST depression, mild inferior myocardial ischemia

V6 : -0.02 mV HR [bpm] : 74
 V5 : -0.01 mV PR Interval [ms] : 103
 V4 : 0.00 mV P Duration [ms] : 88
 V3 : 0.00 mV QRS Duration [ms] : 93
 V2 : 0.04 mV T Duration [ms] : 223
 V1 : 0.02 mV QT/QTc [ms] : 391/434
 P/QRS/T Axis deg : 48.4/63.0/-3.9
 R(V5)/S(V1) mV : 1.32/0.65
 R(V5)+S(V1) mV : 1.97

Dr. Tinish Nanavati
 Registrar
 (Signature)



Physician