



DEPARTMENT OF PATHOLOGY

Patient Name :	Mrs. SWATI GUPTA	Bill Date :	24/02/2024
MR No :	30107	Reporting Date :	24/02/2024
Age/Sex :	35 Years 1 Months 11 Days / Female	Sample ID :	68270
Type :	OPD	Bill/Req. No. :	24089977
TPA/Corporate :	MEDIWHEEL	Ref Doctor :	Dr.CONSULTANT

Test	Result	Bio. Ref. Interval	Units
BLOOD SUGAR 2 HR. PP			
BLOOD SUGAR P.P.	108.02	80 - 150	mg/dl

***** END OF THE REPORT *****



Sample no.

Dr. VAISHALI YADAV Dr.REETU JADHAV Dr. PARDIP KUMAR S.C.GAUR
CONS.PATHOLOGIST CONS.PATHOLOGIST MICROBIOLOGIST & ICO LAB INCHARGE USER NM/SUNIL

(This is only professional opinion and not the diagnosis, Please correlate clinically)

J-Block, Sector-10, Near Court, Faridabad - 121004, Haryana



DEPARTMENT OF PATHOLOGY

Patient Name : Mrs. SWATI GUPTA
MR No : 30107
Age/Sex : 35 Years 1 Months 11 Days / Female
Type : OPD
TPA/Corporate : MEDIWHEEL

Bill Date : 24/02/2024
Reporting Date : 24/02/2024
Sample ID : 68270
Bill/Req. No. : 24089977
Ref Doctor : Dr.CONULTANT

Test	Result	Bio. Ref. Interval	Units
CBC			
HAEMOGLOBIN	12.3	12 - 15	gm/dL
PACKED CELL VOLUME	41.0	35.0 - 50.0	%
RED BLOOD CELL COUNT	4.70	3.5 - 5.5	millions/ μ L
MEAN CORPUSCULAR VOLUME	87.2	83 - 101	fL
MEAN CORPUSCULAR HAEMOGLOBIN	26.2 L	27 - 31	pg
MEAN CORPUSCULAR HB CONC	30.0 L	33 - 37	g/dl
RDW	13.3	11.6 - 14.5	%
TOTAL LEUCOCYTE COUNT	8040	4000-11000	/ μ L
DIFFERENTIAL COUNT			
NEUTROPHILS	68	40.0 - 80.0	%
LYMPHOCYTES	25	20 - 40	%
MONOCYTES	05	2.0 - 10.0	%
EOSINOPHILS	02	0.0 - 5.0	%
BASOPHILS	00	0.0 - 2.0	%
PLATELET COUNT	3.44	1.50 - 4.50	lac/cumm

***** END OF THE REPORT *****



Sample no.

Dr. VAISHALI YADAV Dr.REETU JADHAV Dr. PARDIP KUMAR S.C.GAUR
CONS.PATHOLOGIST CONS.PATHOLOGIST MICROBIOLOGIST & ICO LAB INCHARGE USER NM PRIYANKA

(This is only professional opinion and not the diagnosis, Please correlate clinically)

J-Block, Sector-10, Near Court, Faridabad - 121004, Haryana

Tel.: 0129-4200000 E-mail : parkfaridabad@gmail.com



DEPARTMENT OF PATHOLOGY

Patient Name : Mrs. SWATI GUPTA
MR No : 30107
Age/Sex : 35 Years 1 Months 11 Days / Female
Type : OPD
TPA/Corporate : MEDIWHEEL

Bill Date : 24/02/2024
Reporting Date : 24/02/2024
Sample ID : 68270
Bill/Req. No. : 24089977
Ref Doctor : Dr. CONSULTANT

Test	Result	Bio. Ref. Interval	Units
BLOOD SUGAR FASTING			
PLASMA GLUCOSE FASTING	97.10	60 - 110	mg/dl

***** END OF THE REPORT *****



Sample no.

Dr. VAISHALI YADAV Dr. REETU JADHAV Dr. PARDIP KUMAR S.C. GAUR
 CONS. PATHOLOGIST CONS. PATHOLOGIST MICROBIOLOGIST & ICO LAB INCHARGE USER NM PRIYANKA
 (This is only professional opinion and not the diagnosis, Please correlate clinically)
 J-Block, Sector-10, Near Court, Faridabad - 121004, Haryana
 Tel.: 0129-4200000 E-mail : parkfaridabad@gmail.com



DEPARTMENT OF PATHOLOGY

Patient Name : Mrs. SWATI GUPTA
MR No : 30107
Age/Sex : 35 Years 1 Months 11 Days / Female
Type : OPD
TPA/Corporate : MEDIWHEEL

Bill Date : 24/02/2024
Reporting Date : 24/02/2024
Sample ID : 68270
Bill/Req. No. : 24089977
Ref Doctor : Dr. CONSULTANT

Test	Result	Bio. Ref. Interval	Units
------	--------	--------------------	-------

BLOOD GROUPING AND rh FACTOR

BLOOD GROUP	" B " Rh POSITIVE		
-------------	-------------------	--	--

***** END OF THE REPORT *****



Sample no.

Dr. VAISHALI YADAV Dr. REETU JADHAV Dr. PARDIP KUMAR S.C. GAUR
CONS. PATHOLOGIST CONS. PATHOLOGIST MICROBIOLOGIST & ICO LAB INCHARGE USER NM PRIYANKA
(This is only professional opinion and not the diagnosis, Please correlate clinically)

J-Block, Sector-10, Near Court, Faridabad - 121004, Haryana

Tel.: 0129-4200000 E-mail : parkfaridabad@gmail.com



DEPARTMENT OF PATHOLOGY

Patient Name : Mrs. SWATI GUPTA
 MR No : 30107
 Age/Sex : 35 Years 1 Months 11 Days / Female
 Type : OPD
 TPA/Corporate : MEDIWHEEL

Bill Date : 24/02/2024
 Reporting Date : 24/02/2024
 Sample ID : 68270
 Bill/Req. No. : 24089977
 Ref Doctor : Dr. CONSULTANT

Test	Result	Bio. Ref. Interval	Units
KFT (RENAL PROFILE)			
KFT			
SERUM UREA	20.0	10 - 45	mg/dL
SERUM CREATININE	0.8	0.4 - 1.4	mg/dL
SERUM URIC ACID	2.7	2.5 - 7.0	mg/dL
SERUM SODIUM	137.8	136 - 148	mmol/L
SERUM POTASSIUM	4.53	3.5 - 5.5	mmol/L
CHLORIDE	92.0 L	96 - 106	mmol/L

***** END OF THE REPORT *****



Sample no.

Dr. VAISHALI YADAV Dr. REETU JADHAV Dr. PARDIP KUMAR S.C. GAUR
 CONS. PATHOLOGIST CONS. PATHOLOGIST MICROBIOLOGIST & ICO LAB INCHARGE USER NM PRIYANKA
 (This is only professional opinion and not the diagnosis, Please correlate clinically)

J-Block, Sector-10, Near Court, Faridabad - 121004, Haryana

Tel.: 0129-4200000 E-mail : parkfaridabad@gmail.com



DEPARTMENT OF PATHOLOGY

Patient Name : Mrs. SWATI GUPTA
MR No : 30107
Age/Sex : 35 Years 1 Months 11 Days / Female
Type : OPD
TPA/Corporate : MEDIWHEEL

Bill Date : 24/02/2024
Reporting Date : 24/02/2024
Sample ID : 68270
Bill/Req. No. : 24089977
Ref Doctor : Dr.CONSULTANT

Test	Result	Bio. Ref. Interval	Units
LFT (LIVER FUNCTION TEST)			
LFT			
TOTAL BILIRUBIN	0.64	0 - 1.2	mg/dL
DIRECT BILIRUBIN	0.27	0 - 0.4	mg/dL
INDIRECT BILIRUBIN	0.37	0.10 - 0.6	mg/dL
SGOT (AST)	25.1	0 - 45	U/L
SGPT (ALT)	25.2	0 - 45	U/L
ALKALINE PHOSPHATASE	80.7	30 - 170	IU/L
TOTAL PROTEIN	7.5	6.4 - 8.0	g/dL
ALBUMIN	4.4	3.3 - 5.5	g/dL
GLOBULIN	3.1	2.3 - 4.5	g/dL
AVG RATIO	1.42	1.1 - 2.2	

***** END OF THE REPORT *****



Sample no.

Dr. VAISHALI YADAV Dr. REETU JADHAV Dr. PARDIP KUMAR S.C. GAUR
 CONS.PATHOLOGIST CONS.PATHOLOGIST MICROBIOLOGIST & ICO LAB INCHARGE USER NM PRIYANKA

(This is only professional opinion and not the diagnosis, Please correlate clinically)

J-Block, Sector-10, Near Court, Faridabad - 121004, Haryana
 Tel.: 0129-4200000 E-mail : parkfaridabad@gmail.com




DEPARTMENT OF PATHOLOGY

Patient Name : Mrs. SWATI GUPTA
MR No : 30107
Age/Sex : 35 Years 1 Months 11 Days / Female
Type : OPD
TPA/Corporate : MEDIWHEEL

Bill Date : 24/02/2024
Reporting Date : 24/02/2024
Sample ID : 68270
Bill/Req. No. : 24089977
Ref Doctor : Dr.CONSULTANT

Test	Result	Bio. Ref. Interval	Units
LIPID PROFILE			
LIPID PROFILE			
TOTAL CHOLESTEROL	157.18	120.0 - 200.0	mg/dL
SERUM TRIGLYCERIDES	115.62	40.0 - 160.0	mg/dl
HDL-CHOLESTEROL	65.14	30 - 70	mg/dl
VLDL CHOLESTEROL	23.12	6 - 32	mg/dL
LDL	68.92	50 - 135	mg/dl
LDL CHOLESTEROL/HDL RATIO	1.06	1.0 - 3.0	mg/dL
TOTAL CHOLESTEROL/HDL RATIO	2.41	2.0 - 5.0	mg/dl

***** END OF THE REPORT *****



Sample no.

Dr. VAISHALI YADAV Dr. REETU JADHAV Dr. PARDIP KUMAR S.C. GAUR
CONS. PATHOLOGIST CONS. PATHOLOGIST MICROBIOLOGIST & ICO LAB INCHARGE USER NM PRIYANKA
(This is only professional opinion and not the diagnosis, Please correlate clinically)
J-Block, Sector-10, Near Court, Faridabad - 121004, Haryana
Tel.: 0129-4200000 E-mail : parkfaridabad@gmail.com



DEPARTMENT OF PATHOLOGY

Patient Name : Mrs. SWATI GUPTA	Bill Date : 24/02/2024
MR No : 30107	Reporting Date : 24/02/2024
Age/Sex : 35 Years 1 Months 11 Days / Female	Sample ID : 68270
Type : OPD	Bill/Req. No. : 24089977
TPA/Corporate : MEDIWHEEL	Ref Doctor : Dr.CONSULTANT

Test	Result	Bio. Ref. Interval	Units
------	--------	--------------------	-------

URINE ROUTINE AND MICROSCOPY

PHYSICAL CHARACTERSTICS

QUANTITY	40.0 ML	5 - 100	ML
COLOUR	Pale Yellow		
TURBIDITY	Clear	clear	
SPECIFIC GRAVITY	1.010	1.003 - 1.030	
PH	6.0	Acidic	

CHEMICAL EXAMINATION-1

URINE PROTEIN	NIL	NIL	
GLUCOSE	NIL	NIL	

MICRO.EXAMINATION

PUS CELL	0 - 1/HPF		CELLS/HPF
RED BLOOD CELLS	Nil	0-2	CELLS/HPF
EPITHELIAL CELLS	4 - 5/HPF	0-5	CELLS/HPF
CASTS	NIL	NIL	CELLS/HPF
CRYSTALS	NIL	NIL	CELLS/HPF
OTHER	NIL		

***** END OF THE REPORT *****



Sample no.

Dr. VAISHALI YADAV Dr.REETU JADHAV Dr. PARDIP KUMAR S.C.GAUR
CONS.PATHOLOGIST CONS.PATHOLOGIST MICROBIOLOGIST & ICO LAB INCHARGE USER NM PRIYANKA

(This is only professional opinion and not the diagnosis, Please correlate clinically)

J-Block, Sector-10, Near Court, Faridabad - 121004, Haryana

Tel.: 0129-4200000 E-mail : parkfaridabad@gmail.com



DEPARTMENT OF PATHOLOGY

Patient Name :	Mrs. SWATI GUPTA	Bill Date :	24/02/2024
MR No :	30107	Reporting Date :	25/02/2024
Age/Sex :	35 Years 1 Months 11 Days / Female	Sample ID :	68270
Type :	OPD	Bill/Req. No. :	24089977
TPA/Corporate :	MEDIWHEEL	Ref Doctor :	Dr.CONSULTANT

Test	Result	Bio. Ref. Interval	Units
HB A1C GLYCOSYLATED HAEMOGLOBIN			
HBA1C	6.3		%

Note : Non-Diabetics 4.0 - 6.0 %

In Diabetics
 Good Control 6.1 - 6.8 %
 Fair Control 6.9 - 7.6 %
 Poor Control > 7.6 %

***** END OF THE REPORT *****

OUT SOURCE
PARK HOSPITAL



Sample no.

(Handwritten signature)

(Handwritten signature)

Dr. VAISHALI YADAV Dr.REETU JADHAV Dr. PARDIP KUMAR S.C.GAUR
 CONS.PATHOLOGIST CONS.PATHOLOGIST MICROBIOLOGIST & ICO LAB INCHARGE USER NM RAJU

(This is only professional opinion and not the diagnosis, Please correlate clinically)

J-Block, Sector-10, Near Court, Faridabad - 121004, Haryana

Tel.: 0129-4200000 E-mail : parkfaridabad@gmail.com



DEPARTMENT OF PATHOLOGY

Patient Name : Mrs. SWATI GUPTA
MR No : 30107 **Bill Date** : 24/02/2024
Age/Sex : 35 Years 1 Months 11 Days / Female **Reporting Date** : 26/02/2024
Type : OPD **Sample ID** : 68270
TPA/Corporate : MEDIWHEEL **Bill/Req. No.** : 24089977
Ref Doctor : Dr.CONSULTANT

Test	Result	Bio. Ref. Interval	Units
THYROID PROFILE			
TRI-iodothyronine (T3)	1.25	0.60 - 1.81	ng/ml
Thyroxine (T4)	10.3	5.01 - 12.45	µg/dL
Thyroid Stimulating Hormone	2.74	0.5-5.50 ,	µIU/ml

***** END OF THE REPORT *****

OUT SOURCE
PARK HOSPITAL
GGN



Sample no.

Dr. VAISHALI YADAV Dr. REETU JADHAV Dr. PARDIP KUMAR S.C. GAUR
 CONS. PATHOLOGIST CONS. PATHOLOGIST MICROBIOLOGIST & ICO LAB INCHARGE USER NM SAMAY

(This is only professional opinion and not the diagnosis, Please correlate clinically)

J-Block, Sector-10, Near Court, Faridabad - 121004, Haryana

Tel.: 0129-4200000 E-mail : parkfaridabad@gmail.com



ECHO REPORT

Name of the patient: MRS. SWATI GUPTA Age: 35 Sex: Male Female

UHID No: 30102 IPD No: 24089977 Date: 24/02/24

Refer By Doctor: DR R. Arora

LVEF% 60 - 1

2D ECHO

> Mitral Value Normal Pulmonary Value N Pulm
 > Artery N
 > Aortic avive N Tricuspid valve N

2D RWMA

> N RWMA (Regional wall motion abnormality) at rest

COLD DOPPLER

> N Significant Vavular stenosis / Regurgiation

COMMENTS AND SUMMARY

> All cardiac chambers of N size and shape N dilatation or hypertrophy.
 > N RWMA (Regional wall motion abnormality) at rest
 > N Cloth / Vegetation/ pericardial effusion
 > LV 60 - 1 Systolic function
 > N Significant Vavular stenosis / Regurgiation

Final Impression

> EF at Rest 60 - 1

COMMENTS 2DECHO & Color Doppler Study
WNL

Consultant Cardiology

Doctor Name : Dr.
Date :

Dr. Rakish Kumar Arora
MBBS, (Diploma in Cardiology)
Signature
Time :
Cardiology
Park Hospital, Faridabad

12 Lead + Comparison

PARK HOSPITAL
J BLOCK SEC-10, FARIDABAD
 30107/MRS. SWATI GUPTA
 35 Yrs/Female
 65 Kg/164 Cms
 Date: 24-Feb-2024 11:02:53 AM

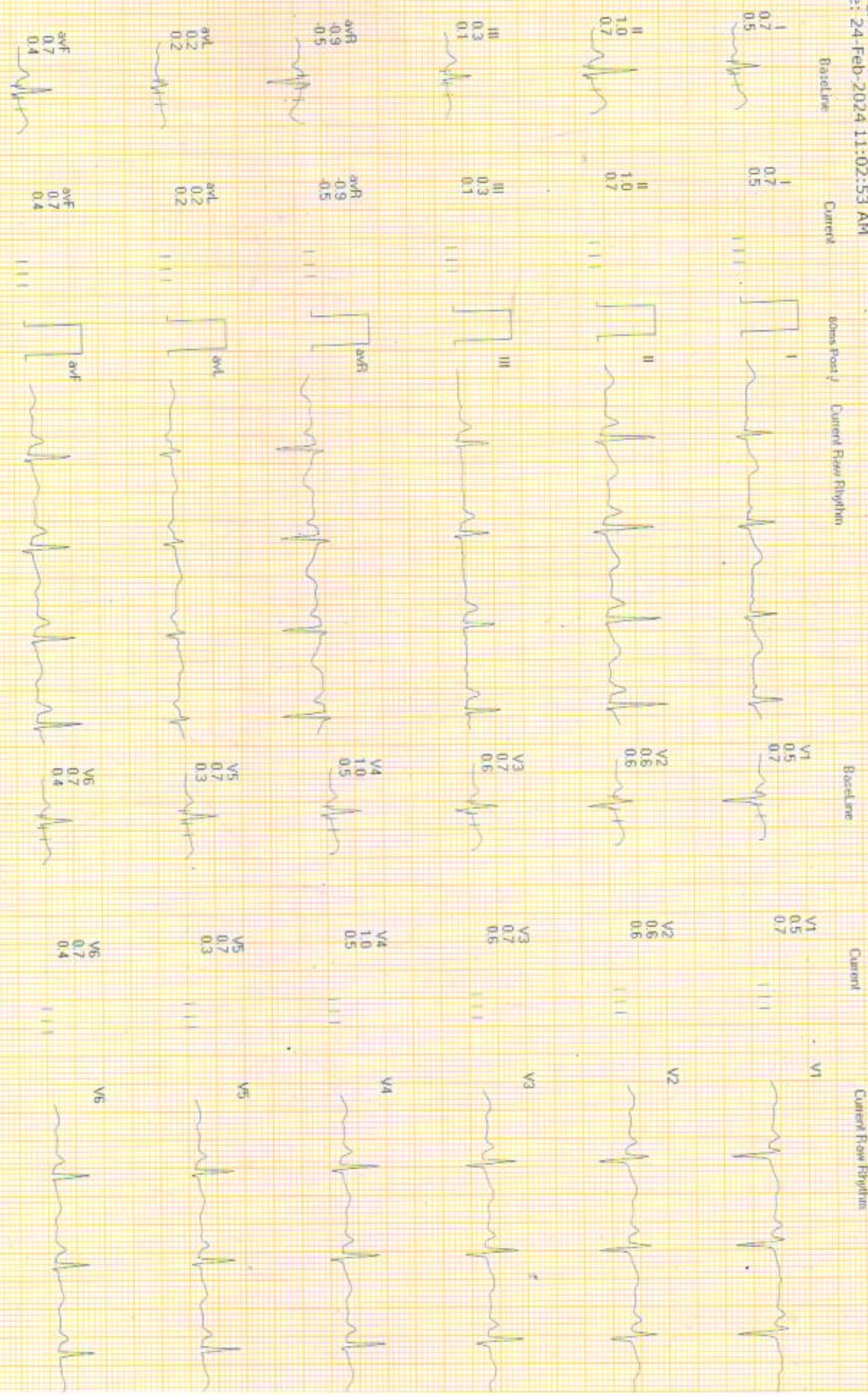
HR: 97 bpm
 METS: 1.0
 BP: 120/80

MPHR: 52% of 185
 Speed: 0.0 mph
 Grade: 0.0%

Raw ECG
 □□□□□□□□□□
 (0.05-100)Hz

Ex Time 00:00
 BLC : On
 Notch : On

INRIDDORV
ExStt
 10.0 mm/mV
 25 mm/Sec

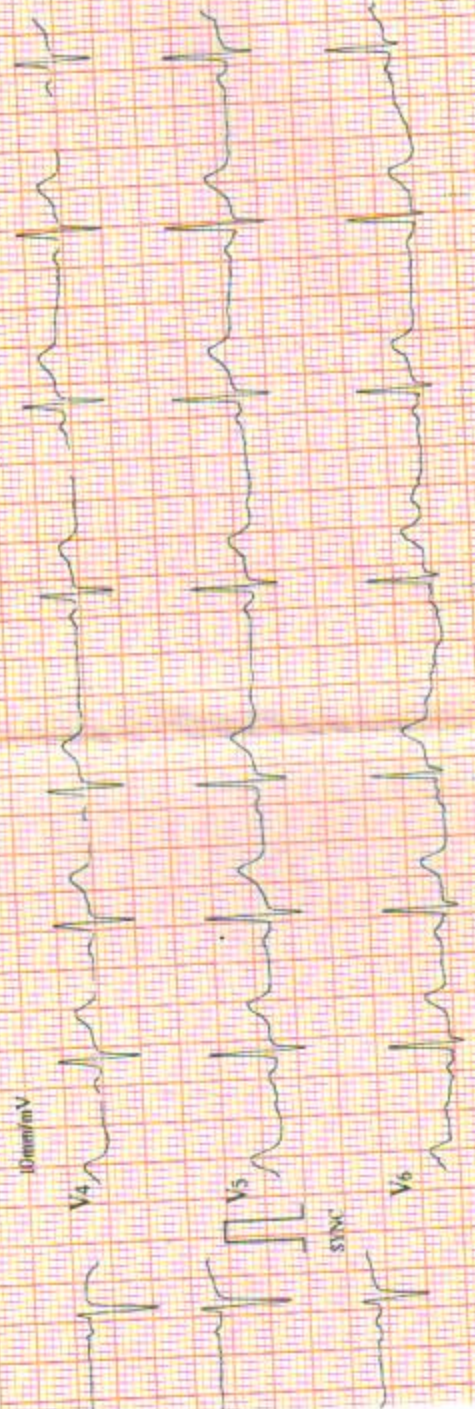

dr. raki

ID : 4116
 Name: ~~Swadi~~ **Swadi**
 Sex: ~~Female~~ **Female**
 Age:

HR : 110
 PR : 150
 QRS : 90
 QT/QTc : 360/384
 ST-T : 35/22.41
 RV5/RSI : 0.87/0.900 ab
 RV5/RSI : 1.770 ab

--- Sinus Arrhythmia
 --- Mild Left Axis Devial 100



Unconfirmed report verified by:

ECARDIO



DEPARTMENT OF RADIOLOGY

Patient Name	Mrs. SWATI GUPTA	Billed Date	: 24/02/2024	9.24 AM
Reg No	30107	Reported Date	: 24/02/2024	
Age/Sex	35 Years 1 Months 11Days / Female	Req. No.	: 24089977	
Type	OPD	Consultant Doctor	: Dr. CONSULTANT	

X-RAY CHEST AP/PA

Bilateral lungs appears normal.

Both hila are normal in size, have equal density and bear normal relationship.

The heart and trachea are central in position and no mediastinal abnormality is visible.

The cardiac size is normal for patient age and view.

The domes of the diaphragms are normal in position and show smooth outline.

To be correlated clinically

DR BINOD KR CHAUDHARY
MBBS,MD
CONSULTANT RADIOLOGIST

(This is only professional opinion and not the diagnosis, Please correlate clinically)

J-Block, Sector-10, Near Court, Faridabad - 121004, Haryana

Tel.: 0129-4200000 E-mail : parkfaridabad@gmail.com



DEPARTMENT OF RADIOLOGY

Patient Name	Mrs. SWATI GUPTA	Billed Date	: 24/02/2024	9.24 AM
Reg No	30107	Reported Date	: 24/02/2024	
Age/Sex	35 Years 1 Months 11Days / Female	Req. No.	: 24089977	
Type	OPD	Consultant Doctor	: Dr. CONSULTANT	

USG WHOLE ABDOMEN

LIVER : The liver is normal in size, shape and echotexture. No evidence of any focal lesion. IHBR is not dilated.

GALL BLADDER : The gall bladder is well distended. No evidence any calculus or mass seen. GB wall thickness within normal limits. No evidence of pericholecystic fluid is seen. The common bile duct is normal.

SPLEEN : The spleen is normal in size and shape. Its echotexture is homogeneous. No evidence of focal lesion is noted.

PANCREAS : The pancreas is normal in size, shape, contours and echotexture.


BILATERAL KIDNEYS : The bilateral kidneys are normal in size and echotexture. Cortico-medullary differentiation is maintained. There is no evidence of obvious calculus or hydronephrosis seen.

URINARY BLADDER : The urinary bladder is well distended. Wall thickness within normal limits. No evidence of calculus is seen. No evidence of mass or diverticulum is noted.

UTERUS : The uterus is normal in size, shape and echopattern. Endometrium echo is normal in thickness.

BILATERAL OVARIES are normal in size and echotexture. No adnexal mass lesion seen. A ruptured follicle of 26mm is seen in right ovary. No free fluid is seen in peritoneal cavity. No evidence of obvious retroperitoneal or mesenteric lymphadenopathy is seen.

IMPRESSION: USG WHOLE ABDOMEN REVEALS NO OBVIOUS ABNORMALITY.


DR BINOD KR CHAUDHARY
MBBS, MD
CONSULTANT RADIOLOGIST

(This is only professional opinion and not the diagnosis, Please correlate clinically)

J-Block, Sector-10, Near Court, Faridabad - 121004, Haryana

Tel.: 0129-4200000 E-mail : parkfaridabad@gmail.com