



Dr. NITIN AGARWAL
MBBS, MD
Regn. No. DMC-R-1436

ONEPLUS ULTRASOUND LAB
47 Harsh Vihar, Pitam Pura,
Delhi-110034
Ph. 011-42480101, 9599913051
E-mail onepusul@gmail.com

भारत सरकार
भारतीय प्रजासत्ताक

Issue Date: 11/09/2020



संजीव कुमार
Sanjeev Kumar
जन्म तिथि/DOB: 27/10/1970
पुरुष/MALE

3721 4649 8781
VID : 9145 4357 6784 3863

मेरा आधार, मेरी पहचान

Download Date: 11/09/2020

[Signature]
Dr. NITIN AGARWAL
MBBS, MD
Regn. No. DMC-R-1435

भारतीय विशिष्ट पहचान प्राधिकरण
UNIQUE IDENTIFICATION AUTHORITY OF INDIA

जो वार पता:
S/O: एस सी अग्रवाल, 10 पहल फ्लोर, जे पी ब्लॉक,
पितामपुरा, सरस्वती विहार, उत्तर पश्चिम,
दिल्ली - 110034

Address :
S/O: S.C Aggarwal, 10 1st Floor, J.P
Block, Pitampura, Saraswati Vihar,
North West Delhi,
Delhi - 110034

3721 4649 8781
VID : 9145 4357 6784 3863

1947
1900 300 1947

help@uidai.gov.in www.uidai.gov.in

www

P.O. Box No. 1947,
Bangalore-560 091

ONEPLUS ULTRASOUND LAB
47 Harsh Vihar, Pitam Pura,
Delhi-110034
Ph. 011-42480101, 9599913051
E-mail oneplusul@gmail.com

[Signature]



OnePLUS
Ultrasound Lab



NABL
MC - 6036

Dr. Nitin Agarwal

Pathologist & Director
MBBS, MD, FAGE
Ex. Chief of Lab
Dr. Lal Path labs.

Dr. Pooja (Garg) Agarwal

Radiologist & Director
MBBS (MAMC) DMRD (MAMC)
Imaging Expert In Fetal And Maternal Medicine,
University of Barcelona, Spain
Fetal Medicine Foundation (UK) Accreditation



QUALITY FIRST... ALWAYS!			
NAME	:Mr. SANJEEV KUMAR	Barcode No	:10170614
AGE/GENDER	:53 YRS/Male	SPECIMEN DATE	:27/Apr/2024 08:41AM
PATIENT ID	:134866	SPECIMEN RECEIVED	:27/Apr/2024 08:50AM
REFERRED BY	:Dr. MEDIWHEEL	REPORT DATE	:27/Apr/2024 03:55PM
CENTRE NAME	:ONEPLUS ULTRASOUND LAB	LAB NO.	:012404270003

Test Name	Result	Unit	Ref. Range
-----------	--------	------	------------

HAEMATOLOGY

MediWheel Health Checkup >40 Male

Sample Type:EDTA Blood

Glycosylated Hemoglobin (HbA1c) HPLC	4.6	%	Non Diabetic adults <5.7 Prediabetic (at risk) 5.7-6.4 Diabetes >6.4
Estimated average blood glucose (eag) CALCULATED	85		

Reference range (mg/dl):

90 - 120:Excellent control, 121 - 150:Good Control, 151 - 180:Average Control, 181 - 210:Action Suggested

>211: Panic value

Dr NITIN AGARWAL
MBBS, MD (Path)
DMC/KVU1436

DR. NITIN AGARWAL
MBBS, MD (PATHOLOGIST)

ONEPLUS ULTRASOUND LAB
47 Harsh Vihar, Pitam Pura,
Delhi-110034
Ph. 011-42480101, 9599913051
E-mail: oneplusul@gmail.com

Checked By.

47, Harsh Vihar, Pitampura, Delhi-34 ☎ 011-4248 0101, 9599913051

✉ Email: oneplusul@gmail.com 🌐 www.oneplusul.in

- Clinical correlation is essential for final diagnosis. • If test results are unsatisfactory please contact personally or on phone.
- This report is for perusal of doctors only. • All disputes are subject to Delhi jurisdiction only. • Not for medico legal case.
- All congenital anomalies in a foetus may not be diagnosed in routine obstetric ultrasound.



OnePLUS Ultrasound Lab

Dr. Nitin Agarwal

Pathologist & Director
MBBS, MD, FAGE
Ex. Chief of Lab
Dr. Lal Path labs.

Dr. Pooja (Garg) Agarwal

Radiologist & Director
MBBS (MAMC) DMRD (MAMC)
Imaging Expert In Fetal And Maternal Medicine
University of Barcelona, Spain
Fetal Medicine Foundation (UK) Accreditation



NAME (FIRST... ALWAYS): MR. SANJEEV KUMAR		Barcode No	:10170614
AGE/GENDER	:53 YRS/Male	SPECIMEN DATE	:27/Apr/2024 08:41AM
PATIENT ID	:134866	SPECIMEN RECEIVED	:27/Apr/2024 08:50AM
REFERRED BY	:Dr. MEDIWHEEL	REPORT DATE	:27/Apr/2024 03:55PM
CENTRE NAME	:ONEPLUS ULTRASOUND LAB	LAB NO.	:012404270003

Test Name	Result	Unit	Ref. Range
-----------	--------	------	------------

HAEMATOLOGY

BLOOD GROUP (ABO)

Forward and Reverse grouping (Slide & Tube)

B

Rh typing

POSITIVE

NOTE :

- * Apart from major A,B,H antigens which are used for ABO grouping and Rh typing, many minor blood group antigens exist. Agglutination may also vary according to titre of antigen and antibody.
- * So before transfusion, reconfirmation of blood group as well as cross-matching is needed.
- * Presence of maternal antibodies in newborns, may interfere with blood grouping.
- * Auto agglutination (due to cold antibody, falciparum malaria, sepsis, internal malignancy etc.) may also cause erroneous result.

Checked By.

ONEPLUS ULTRASOUND LAB
47 Harsh Vihar, Pitam Pura,
Delhi-110034
Ph. 011-42480101, 9599913051
E-mail onepplusul@gmail.com

DR. NITIN AGARWAL
MBBS,MD(PATHOLOGIST)

Dr. NITIN AGARWAL
MBBS, MD
Regn. No. DMG-R-1436

47, Harsh Vihar, Pitampura, Delhi-34 ☎ 011-4248 0101, 9599913051

✉ Email: onepplusul@gmail.com 🌐 www.oneplusul.in

- Clinical correlation is essential for final diagnosis. • If test results are unsatisfactory please contact personally or on phone.
- This report is for perusal of doctors only. • All disputes are subject to Delhi jurisdiction only. • Not for medico legal case.
- All congenital anomalies in a foetus may not be diagnosed in routine obstetric ultrasound.



OnePLUS
Ultrasound Lab



NABL
MC - 6036

Dr. Nitin Agarwal

Pathologist & Director
MBBS, MD, FAGE
Ex. Chief of Lab
Dr. Lal Path labs.

Dr. Pooja (Garg) Agarwal

Radiologist & Director
MBBS (MAMC) DMRD (MAMC)
Imaging Expert In Fetal And Maternal Medicine,
University of Barcelona, Spain
Fetal Medicine Foundation (UK) Accreditation



NAME (FIRST... ALWAYS)	: Mr. SANJEEV KUMAR	Barcode No	: 10170614
AGE/GENDER	: 53 YRS/Male	SPECIMEN DATE	: 27/Apr/2024 08:41AM
PATIENT ID	: 134866	SPECIMEN RECEIVED	: 27/Apr/2024 08:50AM
REFERRED BY	: Dr. MEDIWHEEL	REPORT DATE	: 27/Apr/2024 03:55PM
CENTRE NAME	: ONEPLUS ULTRASOUND LAB	LAB NO.	: 012404270003

Test Name	Result	Unit	Ref. Range
-----------	--------	------	------------

HAEMATOLOGY

CBC

Haemoglobin Non cyanide Hb analysis	15.4	g/dl	13.0-17.0
Total Leucocyte Count Electrical Impedance	8200	/cumm	4000-10000
Differential leucocyte count			
Neutrophils Electrical Impedance & Microscopic	61.7	%	40-80
Lymphocyte Electrical Impedance & Microscopic	30.90	%	20-40
Monocytes Electrical Impedance & Microscopic	5.40	%	2-10
Eosinophils Electrical Impedance & Microscopic	1.6	%	1-6
Basophils Electrical Impedance & Microscopic	0.4	%	0-2
RBC Count Electrical Impedance	5.00	million/cumm	4.5 - 5.5
Hematocrit(PCV) Flow Cytometry	48.1	%	40-50
MCV Calculated	93.1	f	83-101
MCH Calculated	31.1	pg	27-32
MCHC Calculated	33.4	g/dL	31.5-34.5
RDW-CV Calculated	13.5	%	11.4-14.0
Platelet count Electrical Impedance	198000	/cumm	150000-410000

BIOCHEMISTRY

Sample Type: Fluoride F

Blood sugar fasting
GOD-POD

87	mg/dl	70-100 mg/dl
----	-------	--------------

Checked By:

DR. NITIN AGARWAL
MBBS, MD (PATHOLOGIST)

ONEPLUS ULTRASOUND LAB
47 Harsh Vihar, Pitam Pura,
Delhi-110034
Ph. 011-42480101, 9599913051
E-mail: onepplusul@gmail.com

Dr. NITIN AGARWAL
Page 3 of 8
MBBS MD
Regn. No. DMC-1436

47, Harsh Vihar, Pitampura, Delhi-34 ☎ 011-4248 0101, 9599913051

✉ Email: onepplusul@gmail.com 🌐 www.oneplusul.in

- Clinical correlation is essential for final diagnosis. • If test results are unsatisfactory please contact personally or on phone.
- This report is for perusal of doctors only. • All disputes are subject to Delhi jurisdiction only. • Not for medico legal case.
- All congenital anomalies in a foetus may not be diagnosed in routine obstetric ultrasound.



OnePLUS
Ultrasound Lab



NABL
MC - 6036

Dr. Nitin Agarwal

Pathologist & Director
MBBS, MD, FAGE
Ex. Chief of Lab
Dr. Lal Path labs.

Dr. Pooja (Garg) Agarwal

Radiologist & Director
MBBS (MAMC) DMRD (MAMC)
Imaging Expert In Fetal And Maternal Medicine,
University of Barcelona, Spain
Fetal Medicine Foundation (UK) Accreditation



QUALITY FIRST... ALWAYS!

NAME	:Mr. SANJEEV KUMAR	Barcode No	:10170614
AGE/GENDER	:53 YRS/Male	SPECIMEN DATE	:27/Apr/2024 08:41AM
PATIENT ID	:134866	SPECIMEN RECEIVED	:27/Apr/2024 08:50AM
REFERRED BY	:Dr. MEDIWHEEL	REPORT DATE	:27/Apr/2024 03:55PM
CENTRE NAME	:ONEPLUS ULTRASOUND LAB	LAB NO.	:012404270003

Test Name	Result	Unit	Ref. Range
Sample Type:Fluoride PP			
Blood sugar pp GOD-PGD	132	mg/dL	70.0-140.0
Sample Type:Serum			
Bun (blood urea nitrogen) Calculated	11.20	mg/dl	8.4-25.7
Uric Acid, serum Uricase- PAP	4.2	mg/dl	3.5-7.2
Creatinine, serum Enzymatic	0.90	mg/dl	0.71-1.16
LFT(LIVER FUNCTION TEST)			
Bilirubin Total Modified Jco	0.64	mg/dl	0.1-1.2
Bilirubin Conjugated Diazoed sulfanilic acid	0.22	mg/dL	0.11-0.42
Bilirubin Unconjugated Calculated	0.42	mg/dl	up to 0.7
SGOT (AST) Tris buffer	18	U/L	0-46
SGPT (ALT) Tris buffer	32	U/L	0-49
Alkaline phosphatase Amp buffer	98	U/L	40-129
GAMMA GT Scaer Method	22	U/L	10-45
Total Protein Buret	7.6	gm/dl	6.60 - 8.70
Albumin serum BCG	4.4	g/dL	3.0-5.2
Globulin Calculated	3.20	gm/dl	1.8-3.4
Albumin/Globulin Ratio Calculated	1.38		1.10 - 2.50
LIPID PROFILE			
Cholesterol CHOD-PAP	210	mg/dl	50-200

Checked By.

DR. NITIN AGARWAL
MBBS,MD(PATHOLOGIST)

ONEPLUS ULTRASOUND LAB
47 Harsh Vihar, Pitam Pur, B,
Delhi-110034
Ph. 011-42480101, 9599913051
E-mail oneplusul@gmail.com

Dr. NITIN AGARWAL
MBBS, MD
Regn. No. DMC-K-1436

47, Harsh Vihar, Pitampura, Delhi-34 ☎ 011-4248 0101, 9599913051

✉ Email: oneplusul@gmail.com 🌐 www.oneplusul.in

- Clinical correlation is essential for final diagnosis. • If test results are unsatisfactory please contact personally or on phone.
- This report is for perusal of doctors only. • All disputes are subject to Delhi jurisdiction only. • Not for medico legal case.
- All congenital anomalies in a foetus may not be diagnosed in routine obstetric ultrasound.



OnePLUS
Ultrasound Lab



NABL
MC - 6036

Dr. Nitin Agarwal

Pathologist & Director
MBBS, MD, FAGE
Ex. Chief of Lab
Dr. Lal Path labs.

Dr. Pooja (Garg) Agarwal

Radiologist & Director
MBBS (MAMC) DMRD (MAMC)
Imaging Expert in Fetal And Maternal Medicine
University of Barcelona, Spain
Fetal Medicine Foundation (UK) Accreditation



QUALITY FIRST... ALWAYS!

NAME	:Mr. SANJEEV KUMAR	Barcode No	:10170614
AGE/GENDER	:53 YRS/Male	SPECIMEN DATE	:27/Apr/2024 08:41AM
PATIENT ID	:134866	SPECIMEN RECEIVED	:27/Apr/2024 08:50AM
REFERRED BY	:Dr. MEDIWHEEL	REPORT DATE	:27/Apr/2024 03:55PM
CENTRE NAME	:ONEPLUS ULTRASOUND LAB	LAB NO.	:012404270003

Test Name	Result	Unit	Ref. Range
Triglycerides GPO-PAP	155	mg/dL	25-150
HDL Cholesterol Selective Inhibition	58	mg/dL	40 - 60
LDL cholesterol Calculated	121	mg/dL	<100
VLDL cholesterol Calculated	31.0	mg/dL	5-40
Cholesterol/HDL Ratio Calculated	3.6		Low Risk 3.3-4.97 Average Risk 4.4-7.1 Moderate Risk 7.1-11.0 High Risk >11.0
LDL/HDL Ratio Calculated	2.1		0 - 3.55

LDL Cholesterol	Total Cholesterol	HDL Cholesterol
<100 Optimal	<200 Desirable	<40 Low
100-129 Near optimal	200-239 Borderline high	>60 High
130-159 Borderline high	>240 High	
160-189 High		
>190 Very high		

According to NCEP, ATP-III Guidelines

	BUN/Creatinine ratio		
UREA UREASE-GLDH	24.00	mg/dl	15-45
Bun (blood urea nitrogen) Calculated	11.21	mg/dl	8.4-25.7
CREATININE ENZYMATIC	0.90	mg/dl	0.30-1.10
Bun/Creatinine Ratio Calculated	12.46		10.0 - 20.0

Checked By.

ONEPLUS ULTRASOUND LAB
47 Harsh Vihar, Pitam Pura,
Delhi-110034
Ph. 011-42480101, 9599913051
E-mail: oneplusul@gmail.com

DR. NITIN AGARWAL
MBBS, MD (PATHOLOGIST)

Dr. NITIN AGARWAL
MBBS, MD
Regn. No. DMC-R-1436

47, Harsh Vihar, Pitampura, Delhi-34 ☎ 011-4248 0101, 9599913051

✉ Email: oneplusul@gmail.com 🌐 www.oneplusul.in

- Clinical correlation is essential for final diagnosis. • If test results are unsatisfactory please contact personally or on phone.
- This report is for perusal of doctors only. • All disputes are subject to Delhi jurisdiction only. • Not for medico legal case.
- All congenital anomalies in a foetus may not be diagnosed in routine obstetric ultrasound.



OnePLUS
Ultrasound Lab

Dr. Nitin Agarwal

Pathologist & Director
MBBS, MD, FAGE
Ex. Chief of Lab
Dr. Lal Path labs.

Dr. Pooja (Garg) Agarwal

Radiologist & Director
MBBS (MAMC) DMRD (MAMC)
Imaging Expert In Fetal And Maternal Medicine
University of Barcelona, Spain
Fetal Medicine Foundation (UK) Accreditation



QUALITY FIRST... ALWAYS!

NAME	: Mr. SANJEEV KUMAR	Barcode No	: 10170614
AGE/GENDER	: 53 YRS/Male	SPECIMEN DATE	: 27/Apr/2024 08:41AM
PATIENT ID	: 134866	SPECIMEN RECEIVED	: 27/Apr/2024 08:50AM
REFERRED BY	: Dr. MEDIWHEEL	REPORT DATE	: 27/Apr/2024 03:55PM
CENTRE NAME	: ONEPLUS ULTRASOUND LAB	LAB NO.	: 012404270003

Test Name	Result	Unit	Ref. Range
-----------	--------	------	------------

ENDOCRINOLOGY

PSA TOTAL

Prostatic specific antigen, Total	1.61	ng/ml	<4.0
< 40 years	0.21 to 1.72 ng/ml		
40 - 49	0.27 to 2.19 ng/ml		
50 - 59	0.27 to 3.42 ng/ml		
60 - 69	0.22 to 6.16 ng/ml		
> 69	0.21 to 6.77 ng/ml		

Notes:

PSA is principally produced by the glandular epithelium of the prostate, and is secreted in the seminal fluid. PSA is also present in urine and blood. PSA acts on seminal fluid to fluidify and increase sperm mobility. PSA levels rise in prostatic pathologies such as benign prostatic hyperplasia (BPH) or prostate cancer.

THYROID PROFILE(T3,T4,TSH)

Triiodothyronine total [t3] ECLIA	0.64	ng/dl	0.52-1.9
Thyroxine total [t4] ECLIA	7.62	µg/dl	4.4 - 10.8
TSH (Thyroid Stimulating Hormone) Enzyme linked fluorescent assay	2.54	µIU/ml	0.25-5.0

AGE WISE VARIATION IN TSH

AGE	TSH(µIU/ml)	AGE	TSH(µIU/ml)
1-4 weeks	1.00 - 19.0	16-20 yrs	0.25 - 5.0
1-12 mths	1.70 - 9.1	21 - 80 yrs	0.25 - 5.0
1-5 yrs	0.80 - 8.2	I st trimester	0.25 - 5.0
6-10 yrs	0.25 - 5.0	II nd trimester	0.50 - 5.0
11-15 yrs	0.25 - 5.0	II nd trimester	0.4 - 6.0

Reference ranges - Interpretation of Diagnostic tests - (Jacques Wallach)

Checked By.

DR. NITIN AGARWAL
MBBS,MD(PATHOLOGIST)

ONEPLUS ULTRASOUND LAB
47 Harsh Vihar Pitam Pura,
Delhi-110034
Ph: 011-4248 0101, 9599913051
www.oneplusul.com

Dr. NITIN AGARWAL

Page 1 of 1 MF MD
Reg. No. DM - 136

47, Harsh Vihar, Pitampura, Delhi-34 ☎ 011-4248 0101, 9599913051

✉ Email: oneplusul@gmail.com 🌐 www.oneplusul.in

- Clinical correlation is essential for final diagnosis. • If test results are unsatisfactory please contact personally or on phone.
- This report is for perusal of doctors only. • All disputes are subject to Delhi jurisdiction only. • Not for medico legal case.
- All congenital anomalies in a foetus may not be diagnosed in routine obstetric ultrasound.



OnePLUS Ultrasound Lab

Dr. Nitin Agarwal

Pathologist & Director
MBBS, MD, FAGE
Ex. Chief of Lab
Dr. Lal Path labs.

Dr. Pooja (Garg) Agarwal

Radiologist & Director
MBBS (MAMC) DMRD (MAMC)
Imaging Expert In Fetal And Maternal Medicine,
University of Barcelona, Spain
Fetal Medicine Foundation (UK) Accreditation



QUALITY FIRST... ALWAYS!

NAME	:Mr. SANJEEV KUMAR	Barcode No	:10170614
AGE/GENDER	:53 YRS/Male	SPECIMEN DATE	:27/Apr/2024 08:41AM
PATIENT ID	:134866	SPECIMEN RECEIVED	:27/Apr/2024 08:50AM
REFERRED BY	:Dr. MEDIWHEEL	REPORT DATE	:27/Apr/2024 03:55PM
CENTRE NAME	:ONEPLUS ULTRASOUND LAB	LAB NO.	:012404270003

Test Name	Result	Unit	Ref. Range
<p>1. Primary hypothyroidism is accompanied by depressed serum T3 and T4 values and elevated serum TSH level. 2. Primary hyperthyroidism is accompanied by elevated serum T3 and T4 levels along with depressed TSH values. 3. Slightly elevated T3 levels may be found in pregnancy and estrogen therapy, while depressed levels may be encountered in severe illness, renal failure and during therapy with drugs like propranolol and propyl thiouracil. 4. Although elevated TSH levels are nearly always indicative of primary hypothyroidism, and may be seen in secondary thyrotoxicosis</p>			

Checked By.

DR. NITIN AGARWAL
MBBS,MD(PATHOLOGIST)

ONEPLUS ULTRASOUND LAB
47 Harsh Vihar, Pitam Pura,
Delhi-110034
Ph. 011-42480101, 9599913051
E-mail onepusul@gmail.com

DR. NITIN AGARWAL
MBBS, MD
Delhi-110034

47, Harsh Vihar, Pitampura, Delhi-34 ☎ 011-4248 0101, 9599913051

✉ Email: onepusul@gmail.com 🌐 www.oneplusul.in

- Clinical correlation is essential for final diagnosis. • If test results are unsatisfactory please contact personally or on phone.
- This report is for perusal of doctors only. • All disputes are subject to Delhi jurisdiction only. • Not for medico legal case.
- All congenital anomalies in a foetus may not be diagnosed in routine obstetric ultrasound.



OnePLUS
Ultrasound Lab



NABL
MC - 6036

Dr. Nitin Agarwal

Pathologist & Director
MBBS, MD, FAGE
Ex. Chief of Lab
Dr. Lal Path labs.

Dr. Pooja (Garg) Agarwal

Radiologist & Director
MBBS (MAMC) DMRD (MAMC)
Imaging Expert In Fetal And Maternal Medicine,
University of Barcelona, Spain
Fetal Medicine Foundation (UK) Accreditation



QUALITY FIRST... ALWAYS!

NAME	:Mr. SANJEEV KUMAR	Barcode No	:10170614
AGE/GENDER	:53 YRS/Male	SPECIMEN DATE	:27/Apr/2024 08:41AM
PATIENT ID	:134866	SPECIMEN RECEIVED	:27/Apr/2024 08:50AM
REFERRED BY	:Dr. MEDIWHEEL	REPORT DATE	:27/Apr/2024 03:55PM
CENTRE NAME	:ONEPLUS ULTRASOUND LAB	LAB NO.	:012404270003

Test Name	Result	Unit	Ref. Range
-----------	--------	------	------------

CLINICAL PATHOLOGY

URINE ROUTINE (Strip/microscopy)

Sample Type:Urine

Physical examination

Colour	PALE YELLOW	PALE YELLOW
Transparency	CLEAR	CLEAR
Sp. gravity	1.015	1.005-1.030
BROMOTHYMOLO BLUE		
pH	6.50	5.0-8.0
Dual Indicator Test		
Reaction	ACIDIC	ACIDIC

Chemical examination

Urine protein	NL	NL
Protein estimation		
Urine sugar	NL	NL
Oxidation Reaction		
Bilirubin, urine	NEGATIVE	NEGATIVE
Urobilinogen	NORMAL	NORMAL
P-Aminobenzoic Acid and Phenacetopyridine Reaction		
Ketones	NEGATIVE	NEGATIVE
Acetoacetate and Dichlorobenzene Reaction		

Microscopic examination

Pus cells.	1-2	/HPF	0-2
Microscopy			
Epithelial cells	1-2	/HPF	NL
Microscopy			
R.B.C.	NL	/HPF	NL
Microscopy			
Casts	NL	/HPF	NL
Microscopy			
Crystals	NL	/HPF	NL
Microscopy			
Bacteria	NL	/HPF	NL
Microscopy			

Checked By.

DR. NITIN AGARWAL
MBBS,MD(PATHOLOGIST)

ONEPLUS ULTRASOUND LAB
47 Harsh Vihar, Pitam Pura,
Delhi-110034
Ph. 011-42480101, 9599913051
E-mail: oneplusul@gmail.com

Dr. NITIN AGARWAL
MBBS, MD
Ph. No. 011-42480101

47, Harsh Vihar, Pitampura, Delhi-34 ☎ 011-4248 0101, 9599913051

✉ Email: oneplusul@gmail.com 🌐 www.oneplusul.in

- Clinical correlation is essential for final diagnosis. • If test results are unsatisfactory please contact personally or on phone.
- This report is for perusal of doctors only. • All disputes are subject to Delhi jurisdiction only. • Not for medico legal case.
- All congenital anomalies in a foetus may not be diagnosed in routine obstetric ultrasound.



OnePLUS Ultrasound Lab

QUALITY FIRST... ALWAYS!



NABL
MC - 6036

Dr. Nitin Agarwal

Pathologist & Director
MBBS, MD, FAGE
Ex. Chief of Lab
Dr. Lal Path labs.

Dr. Pooja (Garg) Agarwal

Radiologist & Director
MBBS (MAMC) DMRD (MAMC)
Imaging Expert In Fetal And Maternal Medicine,
University of Barcelona, Spain
Fetal Medicine Foundation (UK) Accreditation



NAME	:Mr. SANJEEV KUMAR	Barcode No.	:10170614
AGE/GENDER	:53 YRS/Male	SPECIMEN DATE	:27/Apr/2024 08:41AM
PATIENT ID	:134866	SPECIMEN RECEIVED	:27/Apr/2024 08:50AM
REFERRED BY	:Dr. MEDIWHEEL	REPORT DATE	:27/Apr/2024 03:55PM
CENTRE NAME	:ONEPLUS ULTRASOUND LAB	LAB NO.	:012404270003

Test Name	Result	Unit	Ref. Range
Others.	NIL	NL	NIL

*** End Of Report ***

Checked By.

DR. NITIN AGARWAL
MBBS,MD(PATHOLOGIST)

ONEPLUS ULTRASOUND LAB
47 Harsh Vihar, Pitam Pura,
Delhi-110034
Ph. 011-42480101, 9599913051
E-mail: onepplusul@gmail.com

Dr. NITIN AGARWAL
MBBS, MD
Regn. No. DMC-R-1436

47, Harsh Vihar, Pitampura, Delhi-34 ☎ 011-4248 0101, 9599913051

✉ Email: onepplusul@gmail.com 🌐 www.oneplusul.in

- Clinical correlation is essential for final diagnosis. • If test results are unsatisfactory please contact personally or on phone.
- This report is for perusal of doctors only. • All disputes are subject to Delhi jurisdiction only. • Not for medico legal case.
- All congenital anomalies in a foetus may not be diagnosed in routine obstetric ultrasound.

ONEPLUS ULTRASOUND LAB

47, HARSH VIHAR PTAMPURA DELHI 110034

MR. SANJEEV KUMAR
 Age/Sex : 53M
 Ref by : MEDIWHEEL
 Indication1 :
 Indication2 :
 Indication3 :

ID : 998
 HWVI : 169/68
 Recorded : 27-4-2024 9:08

TREADMILL TEST SUMMARY REPORT
 Protocol: BRUCE
 History:
 Medication1 :
 Medication2 :
 Medication3 :

PHASE *	PHASE TIME	STAGE TIME	SPEED (Km./hr.)	GRADE (%)	H.R. (BPM)	B.P. (mmHg)	RPP X100	II	ST LEVEL (mm) V2	V5 *	METS
SUPINE											
STANDING											
STAGE 1	2:59	2:59	2.70	10.00	113	122/80	137	0.2	2.6	0.7	4.80
STAGE 2	5:59	2:59	4.00	12.00	134	134/82	179	0.0	2.4	0.4	7.10
STAGE 3	8:59	0:59	5.40	14.00	156	148/86	230	-0.3	2.0	0.2	8.05
PEAK EXER	7:01	1:01			155	148/86	229	-0.4	2.0	0.0	8.09
RECOVERY	2:59	2:59	0.00	0.00	91	116/80	106	-0.3	1.1	-0.1	

RESULTS

Exercise Duration: 7:01 Minutes
 Max Heart Rate: 156 bpm 93 % of target heart rate 167 bpm
 Max Blood Pressure: 148/86 mmHg
 Max Work Load: 8.09 METS
 Reason of Termination:

None for other

IMPRESSIONS


Dr. P.K. GUPTA
 MBBS, MD
 Reg. No-1071
 Cardiologist

ONEPLUS ULTRASOUND LAB
 47 Harsh Vihar, Pitampura
 Delhi-110034
 Ph: 011-42480101, 9599913051
 E-mail: oneplusul@gmail.com



ONEPLUS ULTRASOUND LAB

SUPINE
PRETEST

ST @ 10mm/mV
80ms/PostU

MR. SANJEEV KUMAR

I.D. : 998

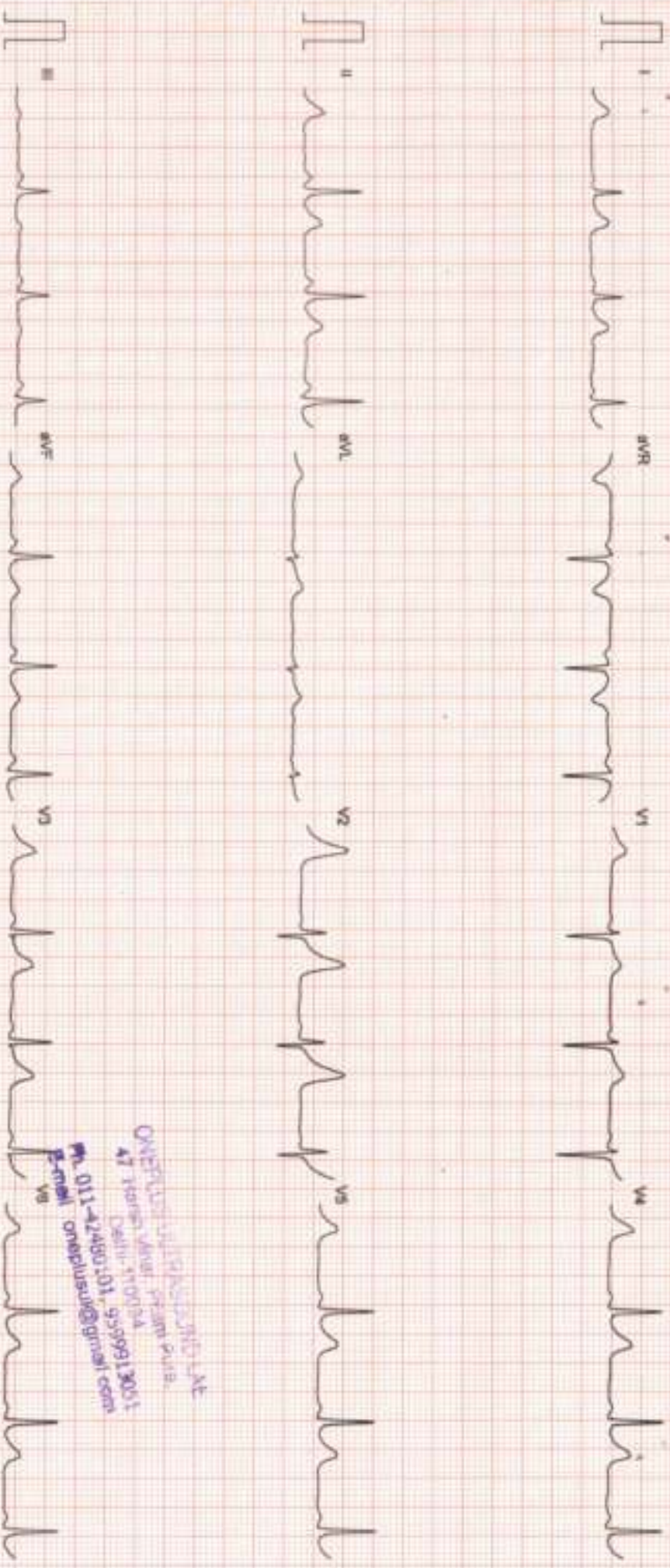
AGE/SEX : 53M

RECORDED : 27-4-2024 9:08

RATE : 82 BPM

B.P. : 110/76 mmHg

RAW ECG



ONEPLUS ULTRASOUND LAB
47 HANDEE WALK PREMISES,
DELHI-110034

Ph. 011-42490101, 9599913001
E-mail: oneplusul@gmail.com

Filtered

25mm/sec 10mm/mV

CardiCom, INDIA Ph. 091-731-2920740, Telefax:091-731-2431214

ONEPLUS ULTRASOUND LAB

STANDING
PRETEST

ST @ 10mm/IV
80ms PostU

LINKED MEDIUM

Mr. SANJEEV KUMAR

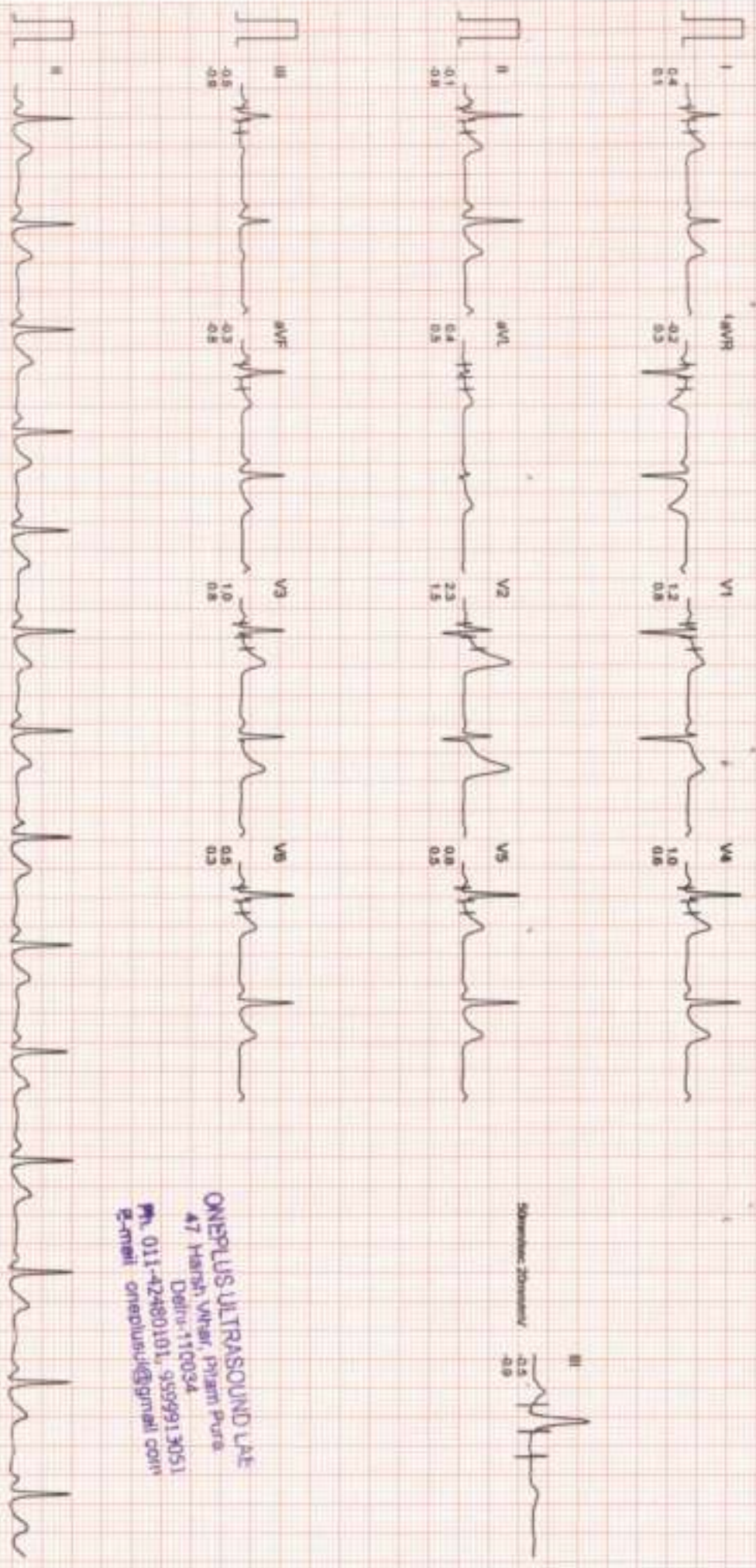
ID : 998

AGE/SEX : 53/M

RECORDED - 27. 4.2024 9:08

RATE : 85 BPM

S.P. : 110/76 mmHg



ONEPLUS ULTRASOUND LAB
47 Hansi Vihar, Pylam Puru
Delhi-110034
Ph. 011-42460101, 9559913051
e-mail: onepplusul@gmail.com

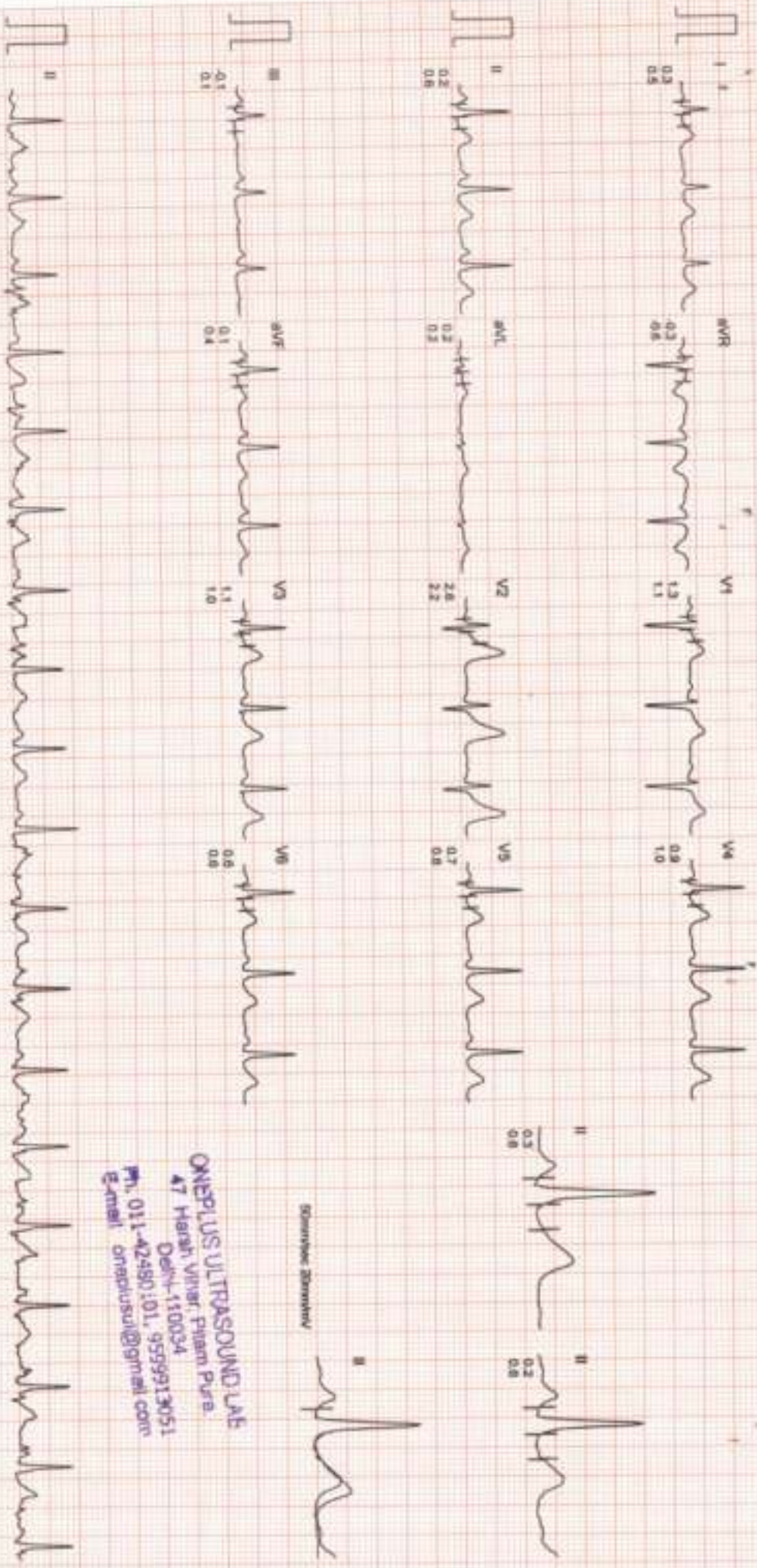
ONEPLUS ULTRASOUND LAB

Mr. SANJEEV KUMAR
I.D. : 998
AGE/SEX : 53/M
RECORDED : 27-4-2024 9:06

RATE : 113 BPM
B.P. : 122/80 mmHg

BRUCE
EXERCISE 1
PHASE TIME : 2:59
STAGE TIME : 2:59

ST @ 10mm/mv
80ms PostJ
SPEED : 2.7 Km./Hr.
GRADE : 10.0 %
LINKED MEDIAN



ONEPLUS ULTRASOUND LAB
47 Harnal Vihar, Pitam Pura,
Delhi-110034
Ph. 011-424580101, 9559913051
E-mail onepusul@gmail.com

ONEPLUS ULTRASOUND LAB

BRUCE

EXERCISE 2

PHASE TIME : 5:59

STAGE TIME : 2:59

ST @ 10mm/mV

80ms/Sec

SPEED : 4.0 KM/HR

GRADE : 12.0 %

LINKED MEDIUM

Mr. SANJEEV KUMAR

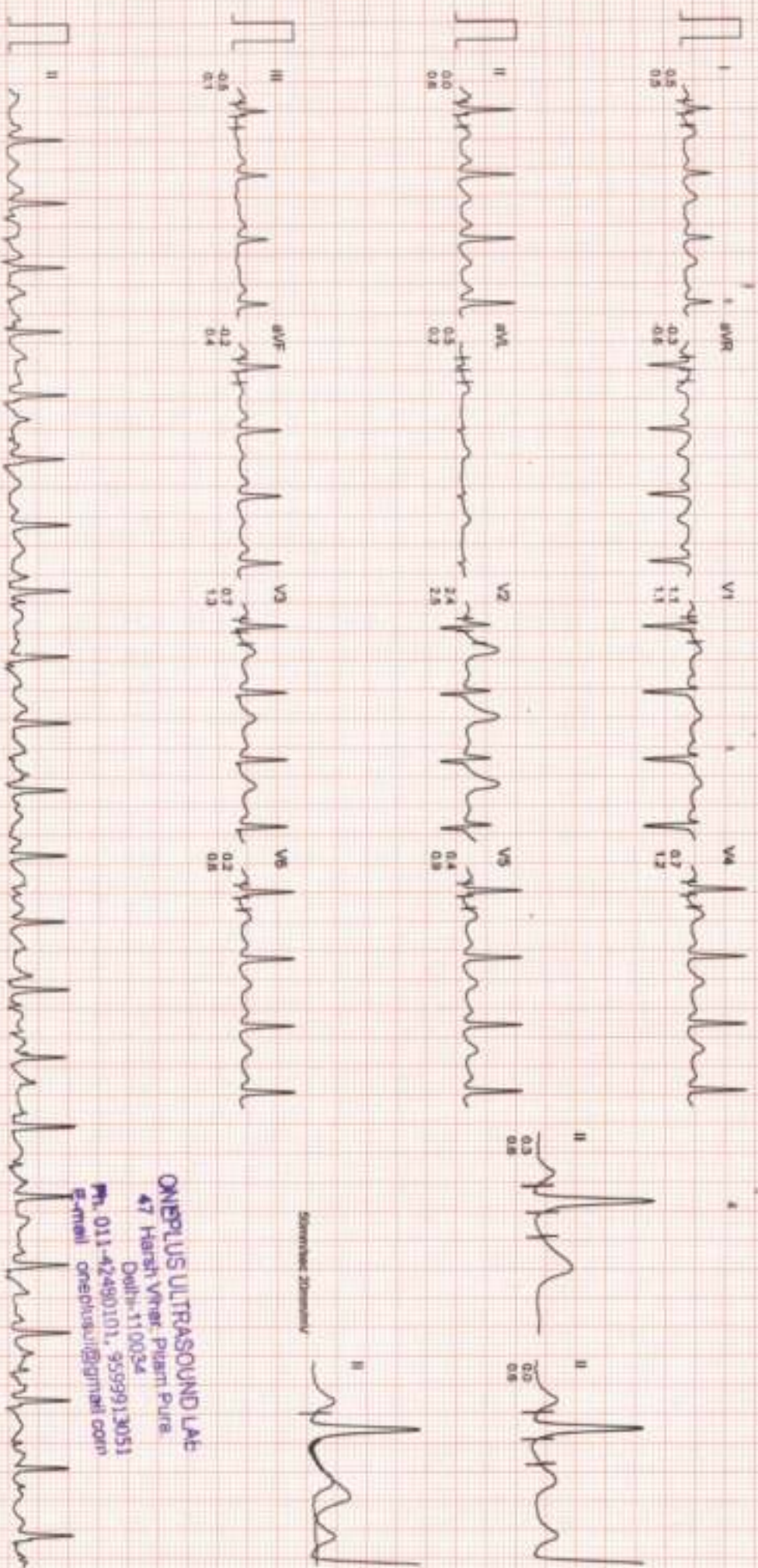
ID : 998

AGE/SEX : 53/M

RECORDED - 27-4-2024 9:08

RATE : 134 BPM

B.P. : 134/82 mmHg



50mm/sec 10mm/mV

ONEPLUS ULTRASOUND LAB
47 Harsh Vihar, Puriam Pura
Delhi-110034

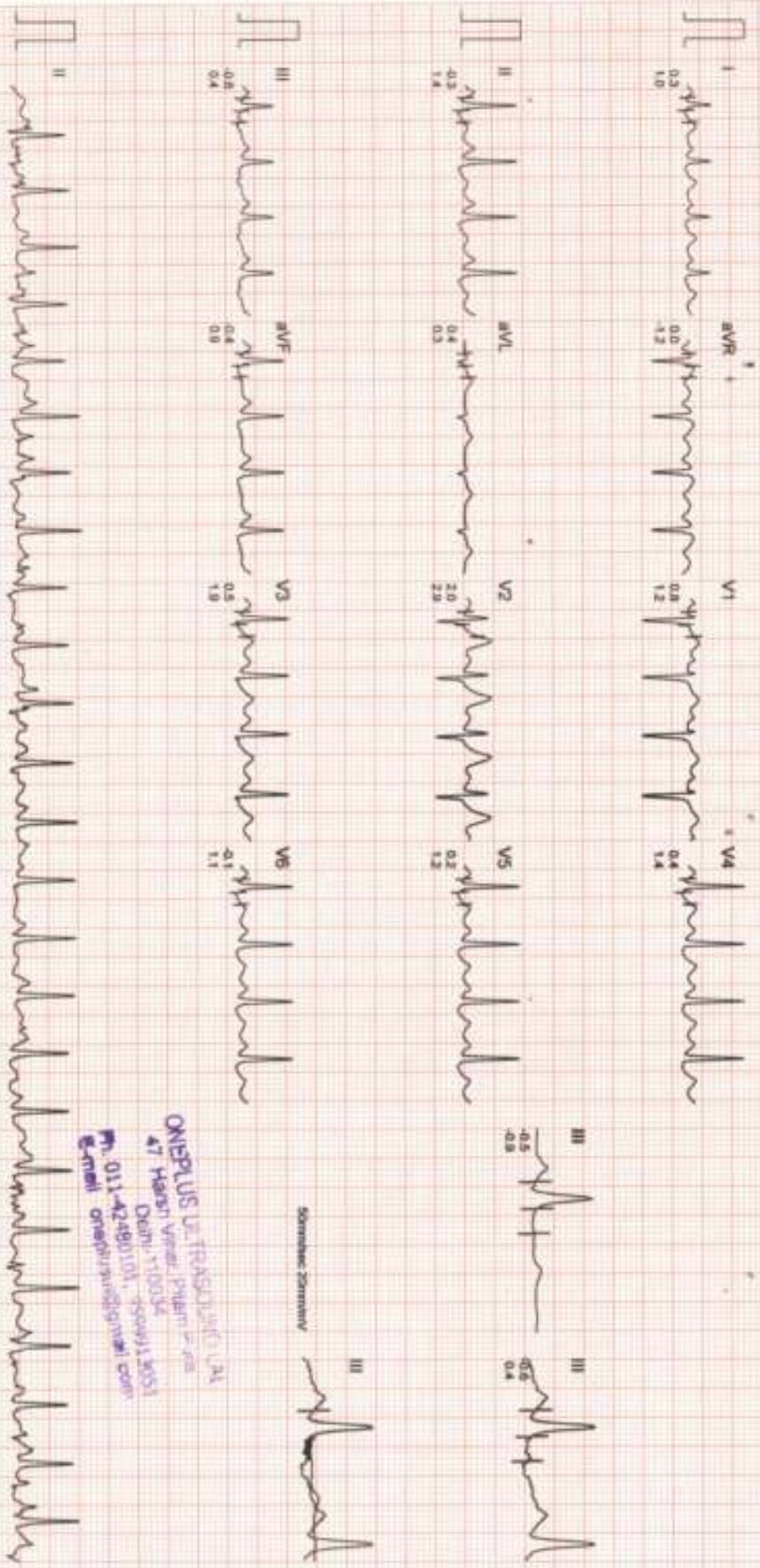
Ph. 011-42490101, 9599913051
E-mail oneplusul@gniffai.com

ONEPLUS ULTRASOUND LAB

MR. SANJEEV KUMAR
ID : 998
AGESEX : 53/M
RECORDED : 27-4-2024 9:08

BRUCE
EXERCISE 3
PHASE TIME : 6:59
STAGE TIME : 0:59

ST @ 10mm/mV
Roma PostL
SPEED : 5.4 Km./Hr.
GRADE : 14.0 %
LINKED MEDIAN



Somnolent Exertively

ONEPLUS ULTRASOUND LAB
47 Hansi Vihar, Pitam Pura
Delhi-110034
Ph. 011-42480101, 4504913053
E-mail onepuls@rediffmail.com

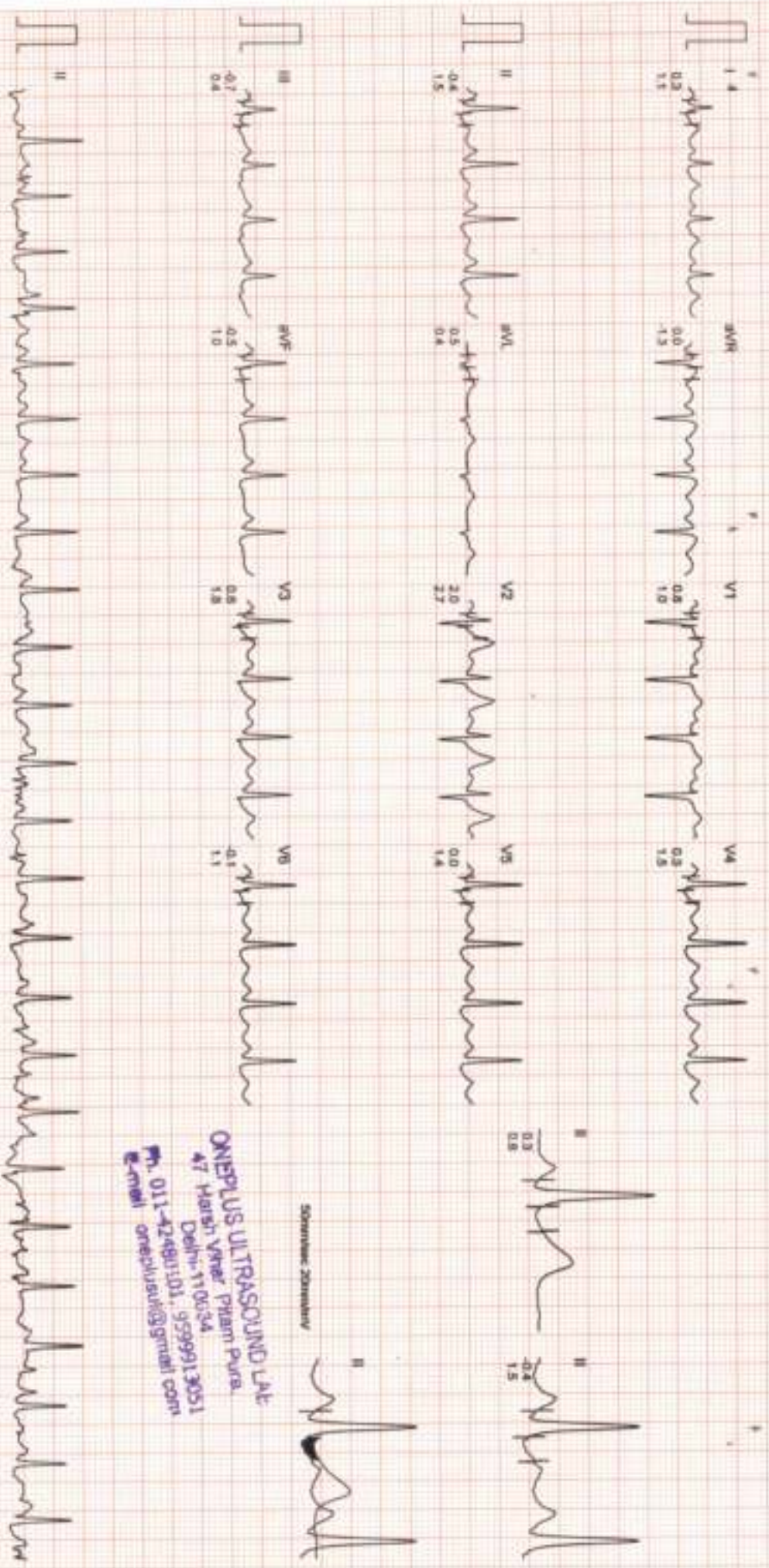
ONEPLUS ULTRASOUND LAB

MR. SANJEEV KUMAR
I.D. : 998
AGE/SEX : 53M
RECORDED : 27-4-2024 9:08

RATE : 155 B/P/M
B.P. : 148/86 mmHg

BRUCE
PEAK EXER
PHASE TIME : 7:01
STAGE TIME : 1:01

ST @ 10mm/mV
80ms PostJ
SPEED : 5.4 Km/HR
GRADE : 14.0 %
LINKED MEDIAN



Scale: 20mm/mV

ONEPLUS ULTRASOUND LAB
47 Harsh Vihar Pitam Pura,
Delhi-110034
Ph. 011-42481101, 9599913051
e-mail onepplusul@gmail.com

ONEPLUS ULTRASOUND LAB

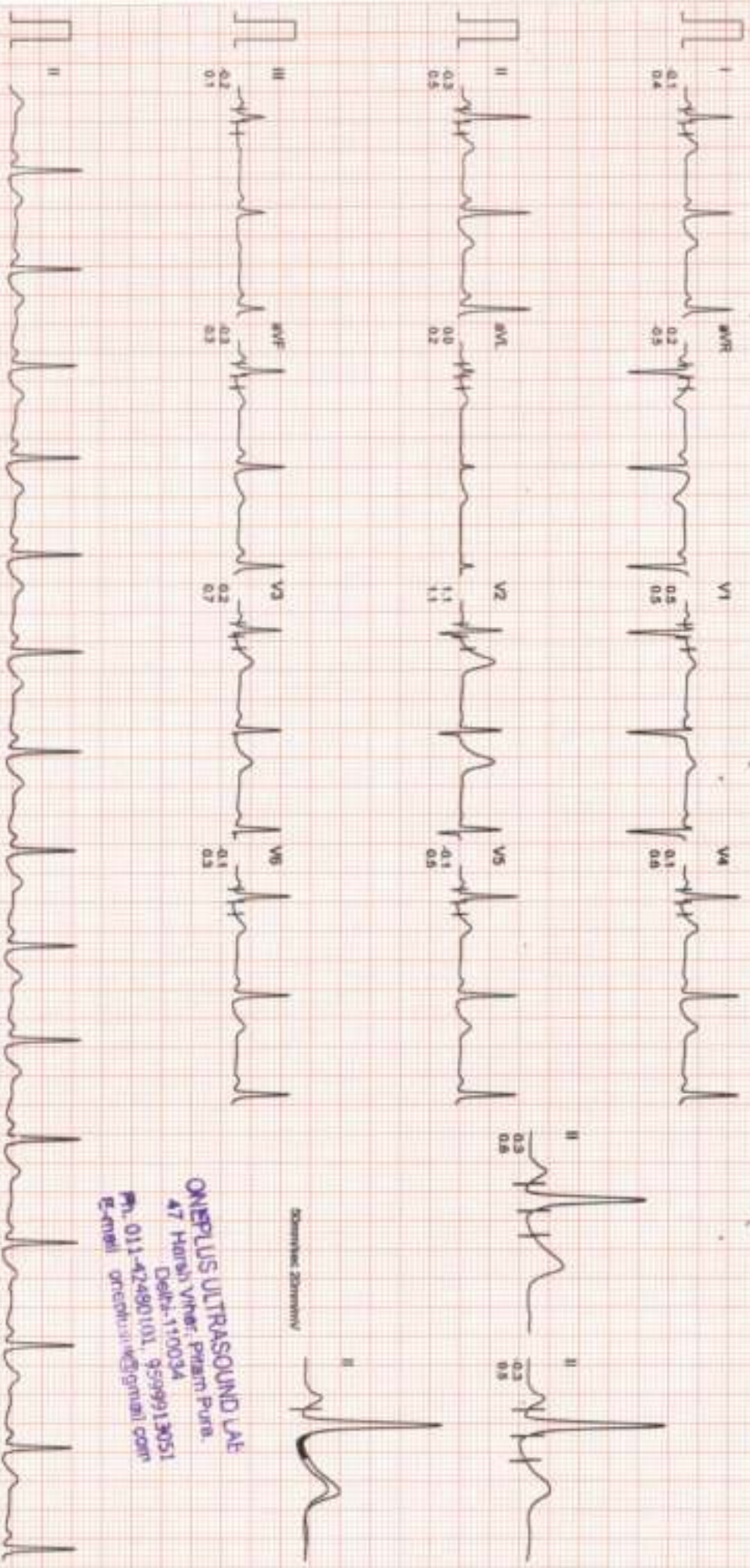
MR. SANJEEV KUMAR
I.D. : 998
AGE/SEX : 53/M
RECORDED : 27-4-2024 9:08

RATE : 91 BPM

B.P. : 116/80 mmHg

BRUCE
RECOVERY
PHASE TIME : 2:59

ST @ 10mm/mV
80ms PostJ
SPEED : 0.0 Km/HR
GRADE : 0.0 %
LINKED MEDIAN



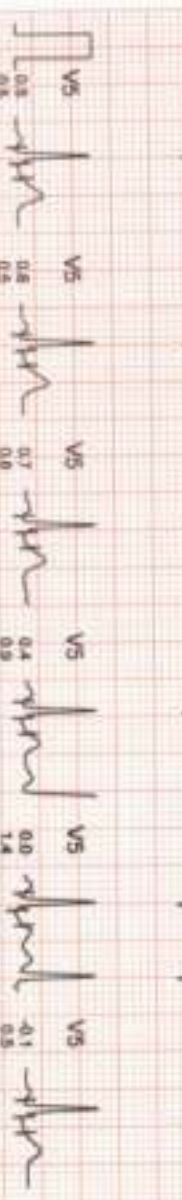
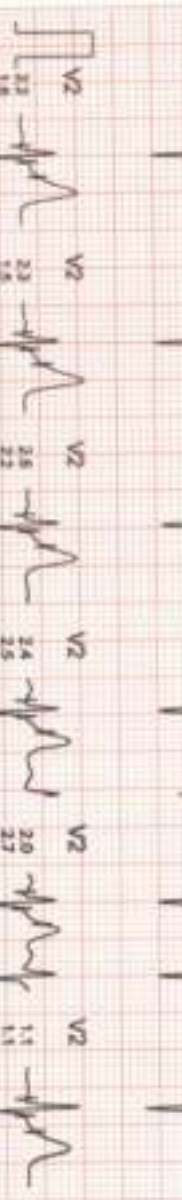


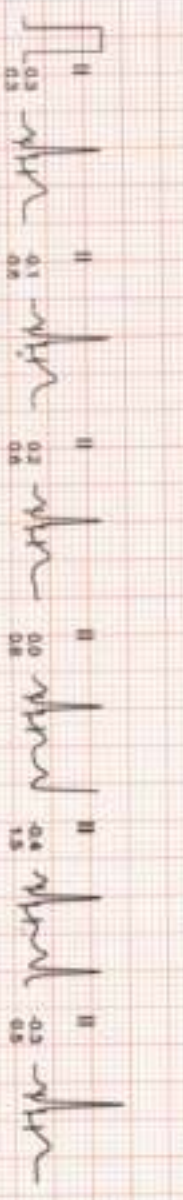
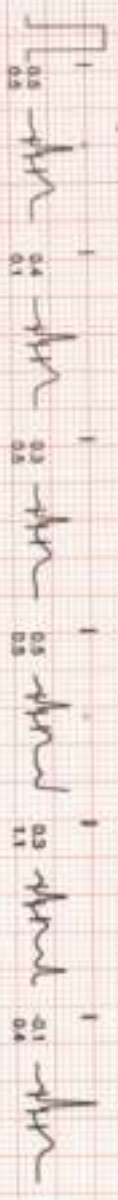
Zoom: 20mm/mV

ONEPLUS ULTRASOUND LAB
47 Harsh Vihar, Pitam Pura,
Delhi-110034
Ph. 011-42490101, 9599913051
E-mail: oneplus@icloud.com

ONEPLUS ULTRASOUND LAB

AVG E.C.G.

STAGE	STAGE 1	STAGE 2	PEAK EXERCISE	RECOVERY
SUPINE	0.00/min 0.0%	5.50 2.50	7.01 1.91	0.00/min 0.0%
SITTING	0.00/min 0.0%	2.50 1.00	3.40/min 14.0%	0.00/min 0.0%
	82 bpm B.P. 100/70 SOMN POUND	100 bpm B.P. 120/80 SOMN POUND	150 bpm B.P. 140/85 SOMN POUND	91 bpm B.P. 100/80 SOMN POUND



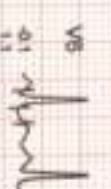
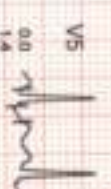
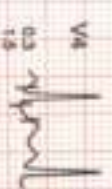


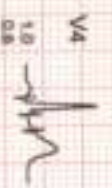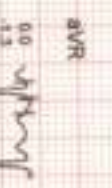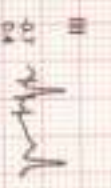



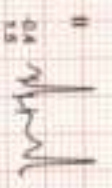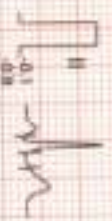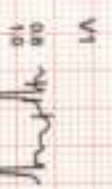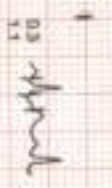
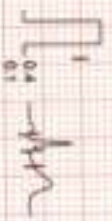
ONEPLUS ULTRASOUND LAB
 47 Harsh Vihar, Pitampura
 Delhi-110034
 Ph. 011-42480101, 9599913051
 E-mail: onepplus@gmail.com

STANDING
0.0k/mph
0.0%
85 bpm
BP-110/75
80mm Hg(1)

PEAK EXERCISE
7.01
1.01
5.4k/mph
14.0%
150 bpm
BP-145/95
80mm Hg(1)

STANDING
0.0k/mph
0.0%
86 bpm
BP-110/75
80mm Hg(1)

PEAK EXERCISE
7.01
1.01
5.4k/mph
14.0%
150 bpm
BP-145/95
80mm Hg(1)



ONEPLUS ULTRASOUND LAB
47 Harihar Vihar, Piplim Pura,
Delhi-110034
Ph. 011-42480101, 9599913051
E-mail onecplusul@gmail.com

Name	: Mr. SANJEEV KUMAR	Age/Sex	: 53 YRS/Male
Ref. By	: Dr. MEDIWHEEL	Lab No	: 012404270003
Date	: 27-Apr-2024	Patient ID	: LSHHI134866

ULTRASOUND EXAMINATION—WHOLE ABDOMEN

Liver is normal in size (13.4 cm) and outline with altered echopattern. Diffuse increase in echogenicity of liver parenchyma is noted, suggestive of fatty infiltration (grade I). No abscess or mass lesion seen. Hepatic veins, portal vein, IVC and aorta are normal. Intrahepatic biliary radicles are not dilated. CBD is normal in caliber.

Gall bladder is well distended with anechoic lumen. Wall thickness is normal.

Both kidneys are normal in size, shape, position, outline and echopattern. Corticomedullary differentiation is maintained. No pelvicalyceal dilation or calculus or mass lesion is seen.

Renal measurements are —

Rt. Kidney – 8.4 x 3.7 cm.

Lt. kidney – 9.3 x 4.6 cm.

Spleen is normal in size and echotexture. No mass lesion seen.

Pancreas is normal in size, outline and echotexture.

Urinary bladder is normal in shape and position. No evidence of intravesical stone or mass seen.

Prostate is normal in size, shape and echopattern.

Prostate measures 3.6 x 3.6 x 3.6 cm. **Weight of prostate is 25.4 grams.**

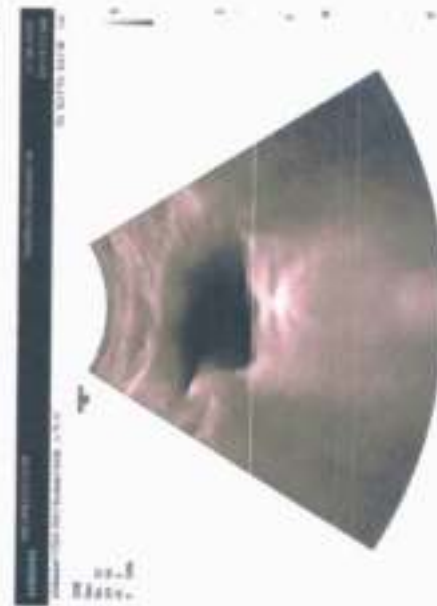
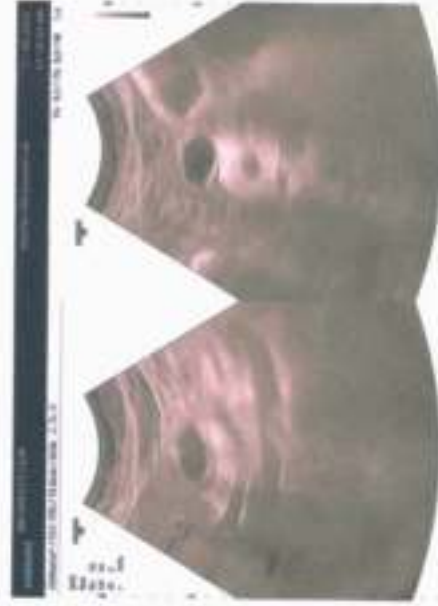No abnormal bowel wall thickening seen in right iliac fossa.

No free fluid seen anywhere in abdomen.

IMPRESSION: Fatty infiltration of liver (grade I) with no hepatomegaly.

DR. POOJA GARG
RADIOLOGIST
REG NO- DMC/R/03398

Dr. POOJA GARG
MBBS, D.M.R.D
Reg No DMC/R/03398
Radiologist





OnePLUS
Ultrasound Lab
— QUALITY FIRST... ALWAYS! —

Dr. Nitin Agarwal

Pathologist & Director
MBBS, MD, FAGE
Ex. Chief of Lab
Dr. Lal Path labs.

Dr. Pooja (Garg) Agarwal

Radiologist & Director
MBBS (MAMC) DMRD (MAMC)
Imaging Expert In Fetal And Maternal Medicine
University of Barcelona, Spain
Fetal Medicine Foundation (UK) Accreditation

Name	: Mr. SANJEEV KUMAR	Age/Sex	: 53 YRS/Male
Ref. By	: Dr. MEDIWHEEL	Lab No	: 012404270003
Date	: 27-Apr-2024	Patient ID	: LSHHI134866

X-ray-Chest PA view

Bony cage and soft tissues are normal.

Cardiothoracic ratio is normal.

Mediastinum is normal.

Both hila are normal.


Both costophrenic angles are clear.

Both domes of diaphragm are normal.

Prominent bronchovascular markings are noted in bilateral lung fields. Mild peribronchial thickening is seen in right perihilar region ? bronchitis. Few fibronodular opacities are seen in right upper zone.

No parenchymal lesion seen.

Please correlate clinically and with related lab tests.


DR. POOJA GARG
RADIOLOGIST
REG NO- DMC/R/03398

Dr. POOJA GARG
M.B.B.S., D.M.R.D
Reg No DMC/R/03398
Radiologist

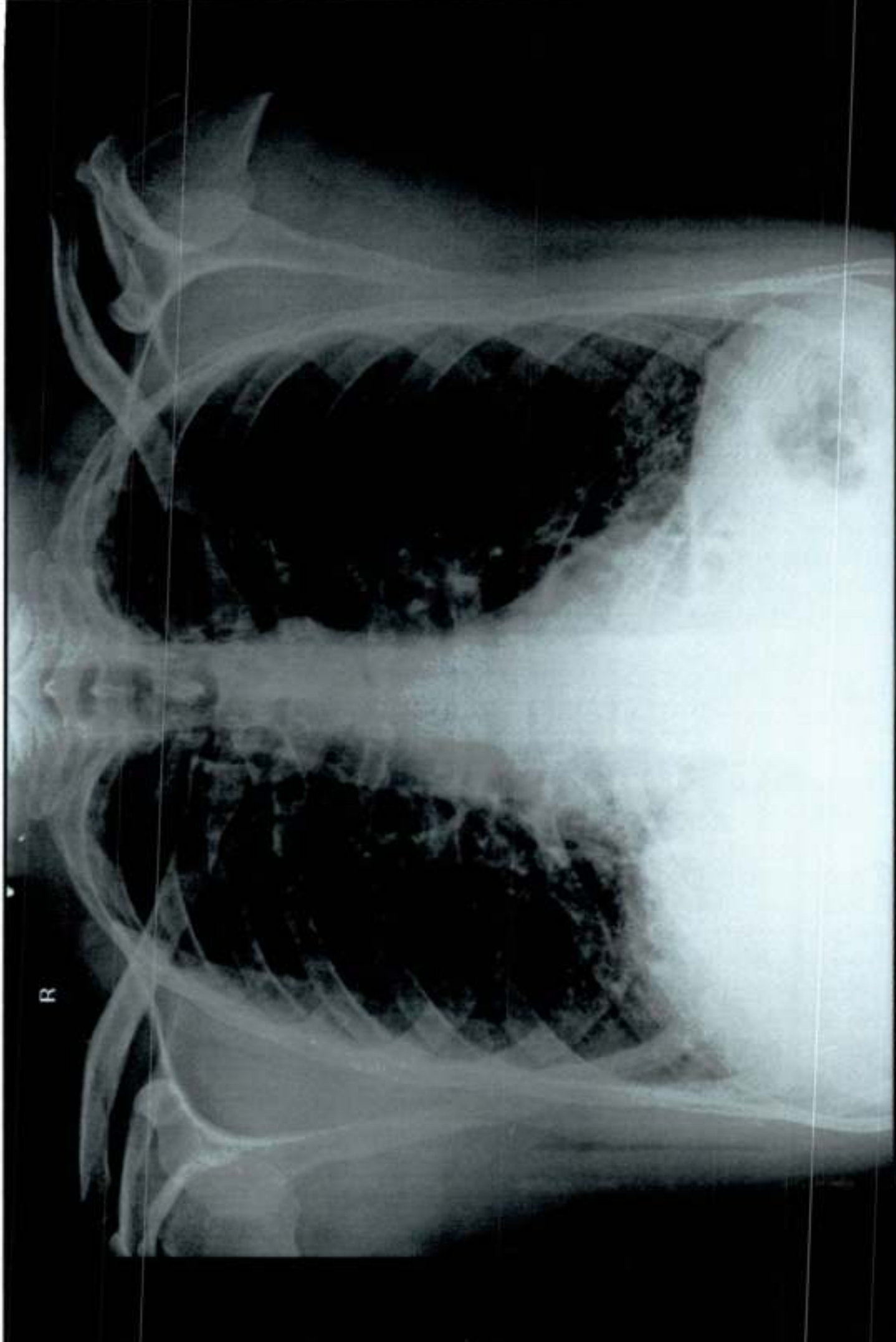
Type By : darshita

47, Harsh Vihar, Pitampura, Delhi-34 ☎ 011-4248 0101, 9599913051

✉ Email: oneplusul@gmail.com 🌐 www.oneplusul.in

- Clinical correlation is essential for final diagnosis. • If test results are unsatisfactory please contact personally or on phone.
- This report is for perusal of doctors only. • All disputes are subject to Delhi jurisdiction only. • Not for medico legal case.
- All congenital anomalies in a foetus may not be diagnosed in routine obstetric ultrasound.

R



MR SANJEEV KUMAR 53YRS 27/04/2024 CHEST PA VIEW 4/27/2024

ONEPI IIS I I I TRASOIND I AR 47 HARSH VIHAR PITAMPIIRA