

<b>Name:</b> DHANVIJAY ATOOL NILCHAND	<b>Exam Date:</b> 16-Sep-2024
<b>Age &amp; Sex:</b> 034 Year /M	<b>Accession:</b> 143178120025
<b>Exam:</b> ABDOMEN AND PELVIS	<b>PID:</b> P00000698984
<b>Physician:</b> HOSPITAL CASE	<b>OP/IP:</b> OP /«extrafield1»

### ULTRASOUND OF ABDOMEN AND PELVIS

Liver appears normal in size, shape and echotexture. No focal lesion is seen. No intrahepatic biliary radicle dilatation seen. The portal vein and CBD appear normal.

Gall bladder is well distended with normal wall thickness. No calculus or sludge is seen. Pancreas appears normal in size and echotexture. No focal lesion is seen. Spleen appears normal in size and echotexture. No focal lesion is seen.

Both kidneys appear normal in size, shape & echotexture. They show good cortico-medullary differentiation. There is no hydronephrosis, hydroureter or calculus seen on either side.

The urinary bladder is empty.

Visualised bowel loops are non-dilated and show normal peristalsis. There is no ascites or significant lymphadenopathy seen.

**IMPRESSION : No significant abnormality noted.**

**Suggest : Clinical Correlation.**



DR. YATIN R. VISAVE  
CONSULTANT RADIOLOGIST  
MBBS, DMRD  
Regd. No. 090812

16-Sep-2024 01:02:52 PM



<b>Name:</b> DHANVIJAY ATOOL NILCHAND	<b>Study Date:</b> 16-Sep-2024
<b>Age &amp; Sex:</b> 034 Year /M	<b>Accession:</b> 143178120025
<b>Exam:</b> CHEST X RAY	<b>PID:</b> P00000698984
<b>Physician:</b> HOSPITAL CASE	<b>OP</b> OP /«extrafield1»

Health Check

**Radiograph Chest PA View :**

Both lung fields normal.

Both costo-phrenic angles are clear.

Cardiac silhouette and aortic knuckle are normal.

Both hilar shadows and the diaphragmatic contours are normal.

Thoracic soft tissues and the rib cage normal.

**Impression :**

No significant abnormality noted.

DR. YATIN R. VISAVE  
CONSULTANT RADIOLOGIST  
MBBS, DMRD  
Regd. No. 090812

16-Sep-2024 01:01:25 PM

**2DECHO&DOPPLER REPORT**

**NAME: MR. DHANVIJAY ATOOL N AGE: 34 Yrs/M DATE: 16 /09/2024**

MITRAL VALVE: has thin leaflets with normal subvalvar motion.

No mitral regurgitation .

AORTIC VALVE : has three thin leaflets with normal opening

No aortic regurgitation.

PULMONARY VALVE; NORMAL,

LEFT VENTRICLE : is normal , has normal wall thickness, No RWMA at rest .

Normal LV systolic function. EF - 60%.

LEFT ATRIUM: is normal.

RIGHT ATRIUM & RIGHT VENTRICLE: normal in size.

TRICUSPID VALVE & PULMONARY VALVES : normal.

Trivial TR, No PH.

No pericardial effusion

**IMP :            Normal LV Systolic function. EF-60%.**  
**No diastolic dysfunction**  
**No RWMA at rest**  
**Normal Valves and Chambers**  
**IAS & IVS Intact**  
**No clot / vegetation / thrombus / pericardial effusion.**



**DR. YATIN VISAVE**  
**MBBS,DMRD(RADIOLOGY)**



Grant Medical Foundation  
**Ruby Hall Clinic**  
Hinjawadi

MR. DHANVIJAY ATOOL NILCHAND



Ref: PS010166- Reg: OPS00008963  
34.8.22/M - NH - 16/09/2024  
P00000698984 -

Dental

O/E →

\* Caries → T

\* Stomatitis, Colitis →

Adm:

① Oral prophylaxis

② Resto → T

H. Anand





MR. DHANVIJAY ATOOL NILCHAND  
 Ref: PS010166- Reg: OPS00006963  
 34.8.22/M - NH - 16/09/2024  
 P00000698984-

OPHTHALMOLOGY

AGE: 34/M

R

L

- 1) Vision  $\left\{ \begin{array}{l} \text{unaided} \quad 6/6 \quad 6/6 \\ \text{c glasses} \end{array} \right.$
- 2) Near Vision  $\left\{ \begin{array}{l} \text{unaided} \quad N6 \quad N6 \\ \text{c glasses} \end{array} \right.$
- 3) Binocular Vision  $\rightarrow$  NIP
- 4) Colour Vision  $\rightarrow$  NIP
- 5) Tension  $\rightarrow$  OK OK
- 6) Anterior Segment
- 7) Pupils
- 8) Lens  $\rightarrow$  BE: WNL
- 9) Media & Fundus
- 10) Remarks  $\rightarrow$  ~~⊕~~ No Refractive error

Date: 16/09/24

  
 (Signature)



MR. DHANVIJAY ATOOL NILCHAND  
 Ref: P5010166- Reg: OP3000006963  
 34.8.22/M - NH - 16/09/2024  
 P00000696964 -

ID: \_\_\_\_\_  
 Name: \_\_\_\_\_

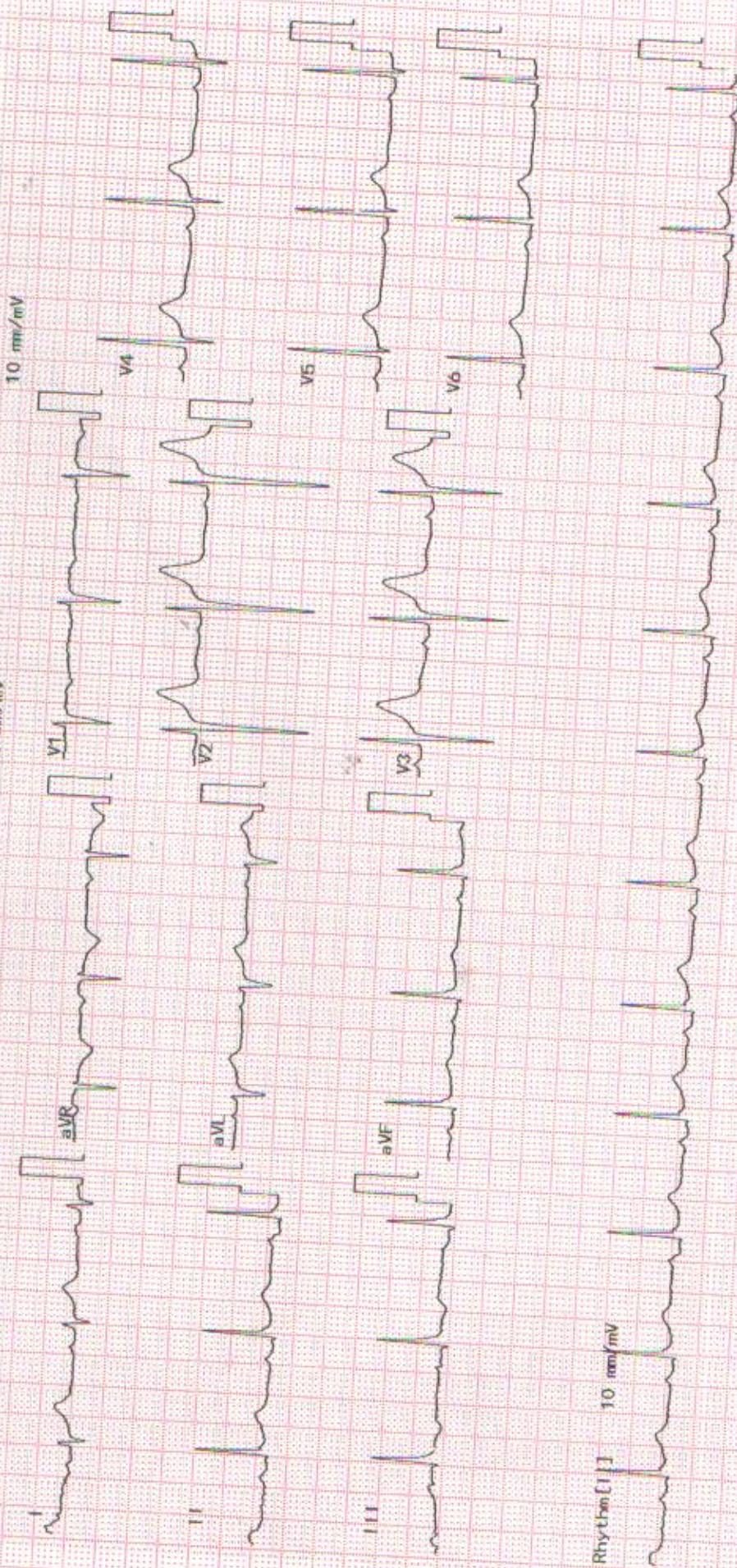
Sex: M  
 cm  
 Medication:  
 Symptoms:  
 History:  
 Vent. rate  
 PR int  
 QRS dur  
 QT/QTc(E) int  
 P/ORS/T axis  
 RV5/SV1 amp  
 RV5+SV1 amp

72 bpm  
 164 ms  
 84 ms  
 364/389 ms  
 42/ 92/ 21  
 1.69/ 0.91 mV  
 2.60 mV

years  
 1100 Sinus rhythm  
 1102 Sinus arrhythmia  
 7102 Moderate right axis deviation  
 9110 \*\* normal ECG \*\*

Unconfirmed Report  
 Reviewed by:

10 mm/mV 25 mm/s Filter: H50 D 35 Hz 10 mm/mV



Rhythm [ ] 10 mm/mV

2350K 02-03 04-05

Dept.:

Exam: RUBY HALL CLINIC HINJEWADI

16-Sep-2024 9:20