



PANACEA HOSPITAL

B 36/44 F.K KABIR NAGAR, DURGAKUND
TOLLFREE NO-18001233070. Whatsapp No - 8795832852
www.piire.org
panaceaquery@gmail.com | panceahospitalit@gmail.com



OP Slip

Print Date : 10-Feb-2024 12:14PM



UHID No :- UD-23240006039	OP No :- OP-23240018604	OP Date :- 10 Feb 2024 12:13PM
Patient Name :- Mr SHRI RAM ARYA	Age/Sex :- 57 Y/Male	Mobile No :- 9450708812
Father :- MAHAVEER	Department :- GENERAL MEDICINE	
Pay Type :- Cr	Consultant :- Dr ASHUTOSH MISHRA (MBBS MD IMS BHU,MD)	
Token No :- NOR. - 12	Paid/Bal :- 0.00 /600.00	
Patient Type :- Normal		
Address :- 126/2 MALVIYA NAGAR COLONY, SUSAWAHI, 221001, varanasi		

BP :- 140/90
height :- 171
Weight (kg) :- 94
BMI :- 32.14

Rx

T2DM
HTN
COPD
obesity.

NC - 38
WC - 120
CH - 114
PR - 68
SPO₂ - 96
PEFR - 250

Adv
CRF, setges
PRR

Rotalde - 1 tablet 250mg 1 time
 TS - Dobutyl 4mg 2 times
 TS - Metformin 1000 1 time
 TS - Ramipril 2mg 1 time
 TS - Citrus ment (40/10) 1/2
 TS - Cur (30/30)

Printed By : Mr Nitin Kumar Yadav
Created By : Mr Nitin Kumar Yadav

Tab. Dichems (10mg) 1 time
 Tab. Imligin (500)
 Ros & Sy 1 time

DR. ASHUTOSH MISHRA
MBBS, MD (GENERAL MEDICINE)
MGL Reg. No. 45695



PANACEA HOSPITAL

B 36/44 F.K KABIR NAGAR, DURGAKUND
TOLLFREE NO-18001233070. Whatsapp No - 8795832852
www.paire.org
panaceaquery@gmail.com|panaceahospitalit@gmail.com



OP Slip

Print Date : 10-Feb-2024 12:14PM



UHID No	:- UD-23240006039	OP No	:- OP-23240018605	OP Date	:- 10 Feb 2024 12:14PM
Patient Name	:- Mr SHRI RAM ARYA	Age/Sex	:- 57 Y/Male	Mobile No	:- 9450708812
Father	:- MAHAVEER	Department	:- OPHTHALMOLOGY		
Pay Type	:- Cr	Consultant	:- Dr SANTOSH VERMA (MBBS,MS)		
Token No	:- NOR. - 4	Paid	:- 0.00		
Patient Type	:- Normal				
Address	:- 126/2 MALVIYA NAGAR COLONY, SUSAWAHI, 221001, varanasi				

BP :- 140/90
 height :- 171
 Weight (kg) :- 94
 BMI :- 32.14
 NC - 38
 WC - 120
 CH - 114
 PR - 68
 SPO2 - 96
 PEFK - 250

Rx

VA { 8/9
 6/9

Near { +2.50 DS
 +2.50 DS } NB

d - locally BIG

l - Cr. Lubstone ultra - 200
 0000

Printed By : Mr Nitin Kumar Yadav

Created By : Mr Nitin Kumar Yadav

Dr. SANTOSH VERMA
 MBBS, MS (Ophthalmologist)
 MCI Reg. No. 09-34327



PANACEA HOSPITAL

B 36/44 F.K KABIR NAGAR, DURGAKUND
TOLLFREE NO-18001233070. Whatsapp No - 8795832852
www.piire.org
panaceaquery@gmail.com|panceahospitalit@gmail.com



OP Slip

Print Date : 10-Feb-2024 11:02AM



UHID No :- UD-23240006039	OP No :- OP-23240018598	OP Date :- 10 Feb 2024 11:01AM
Patient Name :- Mr SHRI RAM ARYA	Age/Sex :- 57 Y/Male	Mobile No :- 9450708812
Father :- MAHAVEER	Department :- DERMATOLOGY	
Pay Type :- Cr	Consultant :- Dr RAVI BHUSHAN (MBBS,MD)	
Token No :- NQR. - 8	Paid/Bal :- 0.00 /630.00	
Patient Type :- Normal		
Address :- 126/2 MALVIYA NAGAR COLONY,SUSAWAHI,221001,varanasi		

BP :- 140/90
height :- 171
Weight (kg) :- 94
BMI :- 32.14

NL-38
WL-120
CH-114
PR-68
SP02-96
PEFR-250

Rx

SUB / Regd Swer

No swim Poolatory



Printed By : Ms. Renuka
Created By : Ms. Renuka



PANACEA HOSPITAL

B 36/44 F.K KABIR NAGAR, DURGAKUND
TOLLFREE NO-18001233070. Whatsapp No - 8795832852
www.piire.org
panaceaquery@gmail.com|panceahospitalit@gmail.com



OP Slip

Print Date : 10-Feb-2024 12:15PM



UHID No :- UD-23240006039 OP No :- OP-23240018606 OP Date :- 10 Feb 2024 12:15PM
Patient Name :- Mr SHRI RAM ARYA Age/Sex :- 57 Y/Male Mobile No :- 9450708812
Father :- MAHAVEER Department :- DENTAL
Pay Type :- Cr Consultant :- Dr SHRUTI MISHRA (AA)
Token No :- NOR. - 8 Paid :- 0.00
Patient Type :- Normal
Address :- 126/2 MALVIYA NAGAR COLONY,SUSAWAHI,221001,varanasi

BP :- 140/90
height :- 171
Weight (kg) :- 94
BMI :- 32.14

NC- 38
WC- 120
CH- 114
PR- 68
SPO₂- 96
PEFR- 250

Rx → Patient came for routine dental check up.

O/E ⇒ stain/calculus - ++/+++

P/D ⇒ chronic gen gingivitis

T/A ⇒ Scaling & Polishing

Shruti
Dr. SHRUTI MISHRA
BDS, (DENTIST)
MCI Reg. No. (A-09784)

Printed By : Mr Nitin Kumar Yadav

Created By : Mr Nitin Kumar Yadav

Facilities:

All clinical Biomedical & Hematology Investigations including Bone Marrow Examination
 VPT, Podiascan & Complete Foot Care (First Time in Purvanchal)
 All Hormonal Investigation by Chemiluminescent Method
 Visceral Fat by (AB-140) Ambulatory BP Monitoring
 CGMS & Insulin Pump Available
 PFT, 2D-ECHO (Color Doppler), Holter, TMT, Cardiac-3 available
 VIA, VILI, Colposcopy available
 Special Endocrinological Investigation Protocols.

ISO 9001:2008 Certified
 Mobile: 9389994334, 9554572190, 9453837595



Panacea Pathology

Clinical Reference Lab

Persistence, Preparedness and Precision
 EQAS (CMC Vellore Attached) & IQAS System
 पूर्वांचल की सर्वोत्तम गुणवत्ता वाली पैथोलॉजी

UHID No :- UD-23240006039 **Booking No/Date** :- 58 / 10-Feb-2024 01:10 PM
Patient Name :- Mr SHRI RAM ARYA **Age/Sex** :- 57 Y/M
Father :- MAHAVEER **OP No** :- OP-23240018598
Address :- 126/2 MALVIYA NAGAR COLONY, SUSAWAHI, 221001, varanasi **Mobile No** :- 9450708812
Consultant :- Dr ASHUTOSH MISHRA (MBBS MD IMS BHU)

Investigations	Observations	Biological Ref. Interval	Unit
----------------	--------------	--------------------------	------

HAEMATOLOGY

Investigations	Observations	Biological Ref. Interval	Unit
CBC			
HAEMOGLOBIN <i>DefaultMethod / test Machine</i>	14.4	13.00 - 16.00	gm/dl
TLC <i>Methology / Carm</i>	5,000	4000.00 - 11000.00	Cells/cumm.
DLC DIFFERENTIAL LEUCOCYTE COUNT			
NEUTROPHILS	51	40.00 - 75.00	%
LYMPHOCYTES	41	20.00 - 45.00	%
EOSINOPHILS	03	1.00 - 6.00	%
MONOCYTES	05	2.00 - 10.00	%
BASOPHILS	00	<1-2	%
PLATELET COUNT	1.78	1.50 - 4.10	lacs /cumm
PCV	43.8	33.00 - 42.00	%
RBC <i>Methology / Carm</i>	4.91	4.50 - 5.50	million/cumm
MCV(MEAN CELL VOLUME)	89.2	83.00 - 101.00	fl
MCH(MEAN CELL HAEMOGLOBIN)	29.4	27.00 - 32.00	pg
MCHC	32.9	31.50 - 35.00	gm%
RDW-CV	12.9	11.00 - 16.00	%
RDW-SD	46.8	37.00 - 57.00	fl

Consulting Pathologist

DR. UMESH KUMAR
 MBBS (MD PATHOLOGIST)
 MCI Reg. No. 41413

Lab Technician

Timing : 24/7 hrs

This Report is not valid for medico legal purpose

Note: These tests have technical limitations. Clinico-pathological interpretation is necessary. In case of any disparity test may be repeated immediately.

Facilities:

All clinical Biomedical & Hematology Investigations including Bone Marrow Examination
 VPT, Podiascan & Complete Foot Care (First Time in Purvanchal)
 All Hormonal Investigation by Chemiluminescent Method
 Visceral Fat by (AB-140) Ambulatory BP Monitoring
 CGMS & Insulin Pump Available
 PFT, 2D-ECHO (Color Doppler), Holter, TMT, Cardiac-3 available
 VIA, VILI, Colposcopy available
 Special Endocrinological Investigation Protocols.

ISO 9001:2008 Certified
 Mobile: 9389994334, 9554572190, 9453837595



Panacea Pathology

Clinical Reference Lab

Persistence, Preparedness and Precision
 EQAS (CMC Vellore Attached) & IQAS System
 पूर्वांचल की सर्वोत्तम गुणवत्ता वाली पैथोलॉजी

UHID No	:- UD-23240006039	Booking No/Date	:- 58 / 10-Feb-2024 01:10 PM
Patient Name	:- Mr SHRI RAM ARYA	Age/Sex	:- 57 Y/M
Father	:- MAHAVEER	OP No	:- OP-23240018598
Address	:- 126/2 MALVIYA NAGAR COLONY, SUSAWAHI, 221001, varanasi	Mobile No	:- 9450708812
Consultant	:- Dr ASHUTOSH MISHRA (MBBS MD IMS BHU)		

Investigations	Observations	Biological Ref. Interval	Unit
----------------	--------------	--------------------------	------

URINE EXAMINATION

URINE ROUTINE EXAMINATION

PHYSICAL EXAMINATION

QUANTITY	25		ml
COLOR	STRAW	CLEAR YELLOW	
<i>Methology</i>			
APPEARANCE	CLEAR	CLEAR	
<i>DefaultMethod</i>			

CHEMICAL EXAMINATION

SPECIFIC GRAVITY	1.015	1.01 - 1.03	
PH	6.5	4.60 - 8.00	
GLUCOSE	NIL	60.00 - 100.00	mg/dl
PROTEIN-	NIL		

MICROSCOPIC EXAMINATION

PUS CELLS	NIL	2.00 - 3.00	/HPF
RBCS (RED BLOOD CELLS)	NIL	4.50 - 5.50	/HPF
EPITHELIAL CELLS	02-03		/HPF
CASTS	ABSENT	ABSENT	
CRYSTALS	ABSENT	ABSENT	

Consulting Pathologist

Dr. UMESH KUMAR
 MBBS MD (PATHOLOGIST)
 MCI Reg. No. 41413

Lab Technician

Timing : 24/7 hrs

This Report is not valid for medico legal purpose

Note: These tests have technical limitations. Clinico-pathological interpretation is necessary. In case of any disparity test may be repeated immediately.

Facilities:

All clinical Biomedical & Hematology Investigations
 including Bone Marrow Examination
 VPT, Podiascan & Complete Foot Care (First Time in Purvanchal)
 All Hormonal Investigation by Chemiluminescent Method
 Visceral Fat by (AB-140) Ambulatory BP Monitoring
 CGMS & Insulin Pump Available
 PFT, 2D-ECHO (Color Doppler), Holter, TMT, Cardiac-3 available
 VIA, VILI, Colposcopy available
 Special Endocrinological Investigation Protocols.

ISO 9001:2008 Certified
 Mobile: 9389994334, 9554572190, 9453837595



Panacea Pathology

Clinical Reference Lab

Persistence, Preparedness and Precision
 EQAS (CMC Vellore Attached) & IQAS System
 पूर्वांचल की सर्वोत्तम गुणवत्ता वाली पैथोलॉजी

UHID No :- UD-23240006039
Booking No/Date :- 58 / 10-Feb-2024 01:10 PM
Patient Name :- Mr SHRI RAM ARYA
Age/Sex :- 57 Y/M
Father :- MAHAVEER
OP No :- OP-23240018598
Address :- 126/2 MALVIYA NAGAR
 COLONY,SUSAWAHI,221001 , varanasi
Mobile No :- 9450708812
Consultant :- Dr ASHUTOSH MISHRA (MBBS MD IMS BHU)

Investigations	Observations	Biological Ref. Interval	Unit
----------------	--------------	--------------------------	------

HAEMATOLOGY

ESR	18.0	0.00 - 15.00	mm at 1 hr
BLOOD GROUP ABO & RH FACTOR			
BLOOD GROUP	"B"		
RH FACTOR	POSITIVE		
HBA1C -(BY GOLD STANDARD METHOD :HPLC)	7.0	Normal: 4.0 - 5.4 Prediabetic : 5.5 -6.3 Diabetes mellitus := 6.4	%

BIOCHEMISTRY

BLOOD SUGAR FASTING			
GLUCOSE	122.0	60.00 - 100.00	mg/dl
PRE-DIABETICS(IMPAIRED FASTING TOLER)	-	100.00 - 125.00	mg/dl
DIABETICS	-	upto 126	mg/dl
TARGET IN DM	-	80.00 - 130.00	mg/dl

BIOCHEMISTRY

PPBS(POST PRANDIAL BLOOD SUGAR)			
POST PRANDIAL BLOOD GLUCOSE(2 HR AFTER MEAL)	190.0	110.00 - 150.00	mg/dl
IGT(2 HR 75GM GLUCOSE)	-	140.00 - 199.00	mg/dl
DIABETES	-	upto200	mg/dl

Consulting Pathologist

DR. UMESH KUMAR
 MBBS MD (PATHOLOGIST)
 MCI Reg. No. 41413

Lab Technician

Timing : 24/7 hrs

This Report is not valid for medico legal purpose

Note: These tests have technical limitations. Clinico-pathological interpretation is necessary. In case of any disparity test may be repeated immediately.

Facilities:

All clinical Biomedical & Hematology Investigations
including Bone Marrow Examination
VPT, Podiascan & Complete Foot Care (First Time in Purvanchal)
All Hormonal Investigation by Chemiluminescent Method
Visceral Fat by (AB-140) Ambulatory BP Monitoring
CGMS & Insulin Pump Available
PFT, 2D-ECHO (Color Doppler), Holter, TMT, Cardiac-3 available
VIA, VILI, Colposcopy available
Special Endocrinological Investigation Protocols.

ISO 9001:2008 Certified
Mobile: 9389994334, 9554572190, 9453837595



Panacea Pathology


Clinical Reference Lab

Persistence, Preparedness and Precision
EQAS (CMC Vellore Attached) & IQAS System
पूर्वांचल की सर्वोत्तम गुणवत्ता वाली पैथोलॉजी

UHID No :- UD-23240006039 **Booking No/Date** :- 58 / 10-Feb-2024 01:10 PM
Patient Name :- Mr SHRI RAM ARYA **Age/Sex** :- 57 Y/M
Father :- MAHAVEER **OP No** :- OP-23240018598
Address :- 126/2 MALVIYA NAGAR COLONY, SUSAWAHI, 221001, varanasi **Mobile No** :- 9450708812
Consultant :- Dr ASHUTOSH MISHRA (MBBS MD IMS BHU)

Investigations	Observations	Biological Ref. Interval	Unit
TARGET IN DM	-	80.00 - 130.00	mg/dl
<u>BIOCHEMISTRY</u>			
YGGT	21.0	10.00 - 50.00	U/L
BUN	14.0	7.00 - 21.00	mg/dl
LFT (LIVER FUNCTION TESTS)			
TOTAL BILIRUBIN	0.44	0.00 - 1.20	mg/dl
DIRECT BILIRUBIN	0.21	0.00 - 0.30	
INDIRECT BILIRUBIN	0.23	0.20 - 0.70	mg/dl
SGOT	26.0	2.00 - 31.00	U/L
SGPT	29.0	10.00 - 45.00	U/L
ALKALINE PHOSPHATASE	79.0	25.00 - 140.00	U/L
TOTAL PROTIENS	7.3	6.60 - 8.70	g/dl
ALBUMIN	4.2	3.50 - 5.20	gm%
GLOBULIN	3.1	1.50 - 3.60	gms/dl
A/G RATIO	1.35	2:1	RATIO
RFT (RENAL FUNCTION TESTS)			
SERUM CREATININE	1.0	0.60 - 1.60	mg/dl

Lab Technician


Consulting Pathologist
DR. UMESH KUMAR
MBBS, MD (PATHOLOGIST)
MCI Reg. No. 41483

Timing : 24/7 hrs

This Report is not valid for medico legal purpose

Note: These tests have technical limitations. Clinico-pathological interpretation is necessary. In case of any disparity test may be repeated immediately.

Facilities:

All clinical Biomedical & Hematology Investigations
 including Bone Marrow Examination
 VPT, Podiascan & Complete Foot Care (First Time in Purvanchal)
 All Hormonal Investigation by Chemiluminescent Method
 Visceral Fat by (AB-140) Ambulatory BP Monitoring
 CGMS & Insulin Pump Available
 PFT, 2D-ECHO (Color Doppler), Holter, TMT, Cardiac-3 available
 VIA, VILI, Colposcopy available
 Special Endocrinological Investigation Protocols.

ISO 9001:2008 Certified
 Mobile: 9389994334, 9554572190, 9453837595



Panacea Pathology

Clinical Reference Lab

Persistence, Preparedness and Precision
 EQAS (CMC Vellore Attached) & IQAS System
 पूर्वांचल की सर्वोत्तम गुणवत्ता वाली पैथोलॉजी

UHID No :- UD-23240006039 **Booking No/Date** :- 58 / 10-Feb-2024 01:10 PM
Patient Name :- Mr SHRI RAM ARYA **Age/Sex** :- 57 Y/M
Father :- MAHAVEER **OP No** :- OP-23240018598
Address :- 126/2 MALVIYA NAGAR COLONY,SUSAWAHI,221001 , varanasi **Mobile No** :- 9450708812
Consultant :- Dr ASHUTOSH MISHRA (MBBS MD IMS BHU)

Investigations	Observations	Biological Ref. Interval	Unit
URIC ACID	4.33	3.60 - 7.70	mg/dl
LIPID PROFILE			
TOTAL CHOLESTROL	151.0	Desirable : - < 200 mg/dL Borderline: - 200 - 239 mg/dL High : - > 240mg/dL	mg/dl
TRIGLYCERIDES	172.0	35.00 - 160.00	mg/dl
HDL CHOLESTROL	44.0	35.30 - 79.50	mg/dl
LDL CHOLESTROL	72.6	<130	mg/dl
VLDL	34.40	<40	mg/dl
CHOLESTROL/ HDL RATIO	3.43	<3.0 LOW RISK, 3.0-5.0 AVG RISK, >5.0 HIGH RISK	ratio
LDL/HDL RATIO	1.65	<3	ratio
IMMUNOLOGY			
PSA, TOTAL	0.92	0.00 - 4.00	ng/ml
THYROID PROFILE (T3,T4,TSH)			
T3	0.91	0.60 - 1.81	ng/ml
T4	6.2	4.50 - 10.90	ug/dl
TSH	1.82	0.39 - 6.10	uIU/mL

* END OF REPORT *

Consulting Pathologist
DR. UMESH KUMAR
 M.D. (PATHOLOGIST)
 M.C. Reg. No. 4113

Lab Technician

Timing : 24/7 hrs

This Report is not valid for medico legal purpose

Note: These tests have technical limitations. Clinico-pathological interpretation is necessary. In case of any disparity test may be repeated immediately.



PANACEA HOSPITAL



A shelter for many hearts A Home for many lives

(An ISO 9001:2008 Certified Organisation)

Lab Attached with CMC Under EQAS Scheme

Dept. of Radiodiagnosis - 32 Slice CT Scan, 3D/4D USG, 2D ECHO, Colour Doppler, Intervention Procedures, Digital X-Ray

NAME: MR.SHRI RAM ARYA

AGE/SEX: 57 YRS / MALE

REF BY: DR.ASHUTOSH MISHRA(MD)

DATE: 10/02/2024

Echo - Cardiography

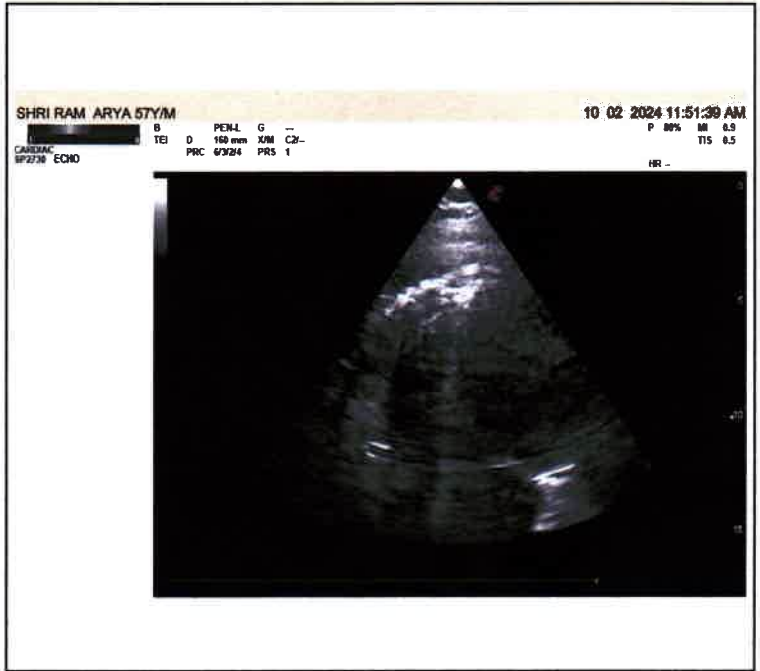
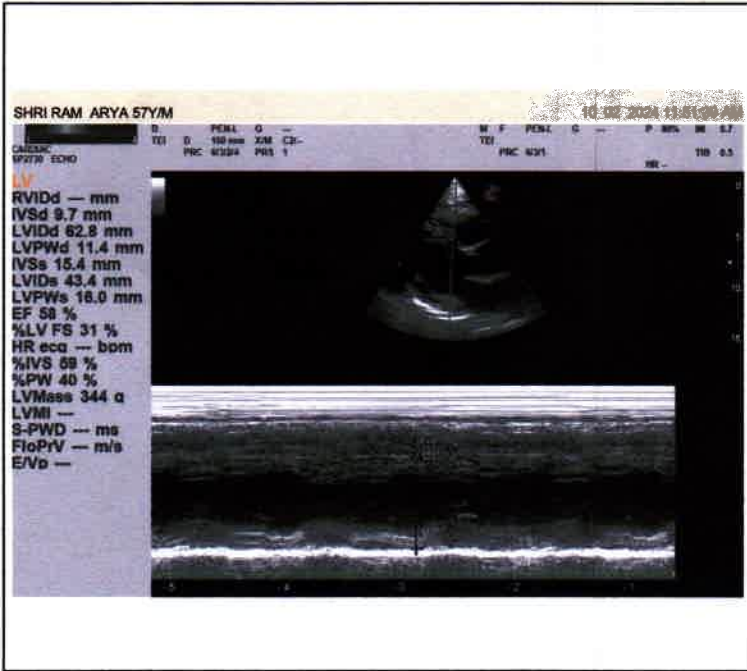
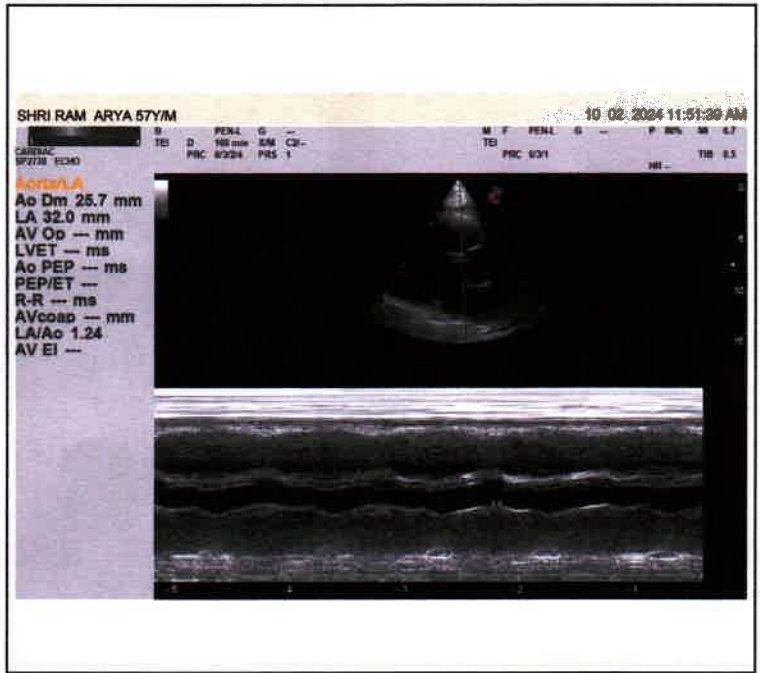
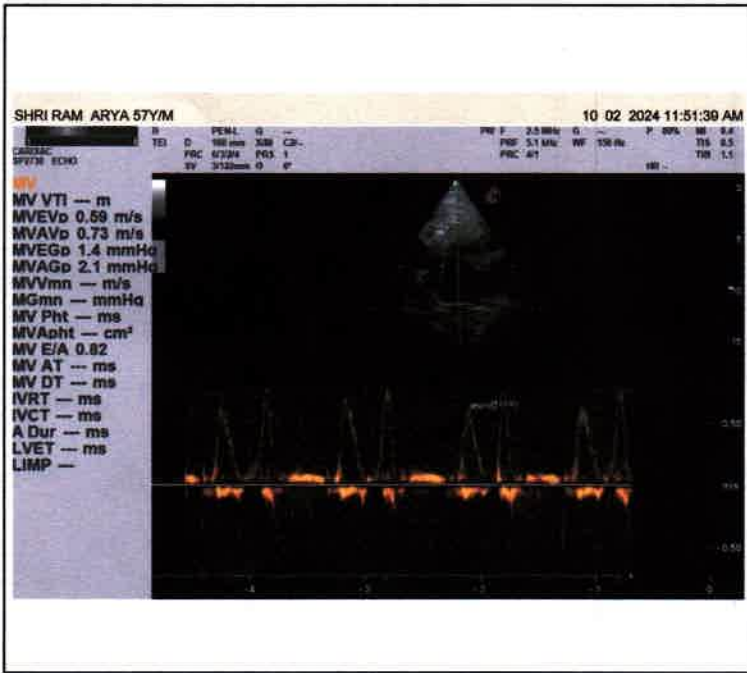MITRAL VALVE Doppler	AML - Normal morphology MV Flow - E - 0.5 A-0.7 E/A=0.82	PML - Normal morphology MVA - 3.0 cm ² Mitral Regurgitation - Trivial MR
TRICUSPID VALVE Doppler	Normal TV Flow -No	Tricuspid Regurgitation -No
PULMONARY VALVE Doppler	Normal PV Flow -No	Pulmonary Regurgitation - No
AORTIC VALVE Doppler	Trileaflet-No AV Flow - no	Aortic Regurgitation - No
MEASUREMENT	Aorta - 25.7 (20-38) mm IVS ed - 9.7 (6-12) mm LVID ed - 62.8 (35-55) mm LVPW ed - 11.4 (6-12) mm OA - 7 (> 5) mm	LA -32.0 (24-32) mm IVS es -15.4 (6-12) mm LVID es - 43.4 (24-40) mm LVPW es - 16.0 (6-12) mm EPSS - 7 (< 9) mm

CONCLUSION All cardiac chamber dimensions are WNL
Trivial MR Is present, rest other valve are WNL
 Good LV systolic function present Modified Simpson's method (4C, 2C) (LVEF-58%)
Grade II diastolic dysfunction present (E/A = 0.82)
 No RWMA
 No pericardial effusion
 Intact IAS / IV
 No PAH
 No intra cardiac mass /thrombus /vegetation

IMPRESSION All cardiac chamber dimensions are WNL
Trivial MR Is present, rest other valve are WNL
 Good LV systolic function present Modified Simpson's method (4C, 2C) (LVEF-58%)
Grade II diastolic dysfunction present (E/A = 0.82)
 Rest all other finding are WNL


 Nishu Mishra
 Physician Assistant
 (PARE)


 Dr. Pallavi Misra
 MBBS, MD (GENERAL MEDICINE)
 MCI Reg. No. 52033
 Women Cardiologist
 Diabetocardiologist





PANACEA HOSPITAL



A shelter for many hearts A Home for many lives

(An ISO 9001:2008 Certified Organisation)
Lab Attached with CMC Under EQAS Scheme

Dept. of Radiodiagnosis - 32 Slice CT Scan, 3D/4D USG, 2D ECHO, Colour Doppler, Intervention Procedures, Digital X-Ray

PATIENT'S NAME : SHRI RAM ARYA **AGE/SEX: 57 Y/M**
REF. BY : Dr. ASHUTOSH MISHRA (MD) **Saturday, February 10, 2024**

U/S. WHOLE ABDOMEN

- LIVER** : Liver is enlarged in size measuring approx 156mm with Diffuse increased echogenicity of liver parenchyma - Grade I fatty liver. Intra hepatic biliary radicals are normal. Portal venous channels are normal.
- G. B.** : Gall bladder is contracted.
- C.B.D.** : C.B.D. is normal in caliber.
- PANCREAS** : Pancreas is normal in size, shape and echotexture. No evidence of any inflammatory disease or mass.
- SPLEEN** : Spleen is mild enlarged in size measuring approx 123mm
- Rt. KIDNEY** : Normal in size, shape and echotexture. Renal sinus is normal
Cortico medullary differentiation is normal. P. C. system is normal.
Few right renal cortical cyst largest at upper pole measuring approx 46x57mm.
- Lt. KIDNEY** : Normal in size, shape and echotexture. Renal sinus is normal
Cortico medullary differentiation is normal. P. C. system is normal.
Few left renal cortical cyst largest at mid pole measuring approx 38x31mm.
- URL. BLADDER** : Urinary bladder is normal in size, position. Wall thickness normal.
- PROSTATE** : Prostate is normal in size 26x41x38mm Vol 22.0ml.
No ascites & retro peritoneal lymphadenopathy seen.

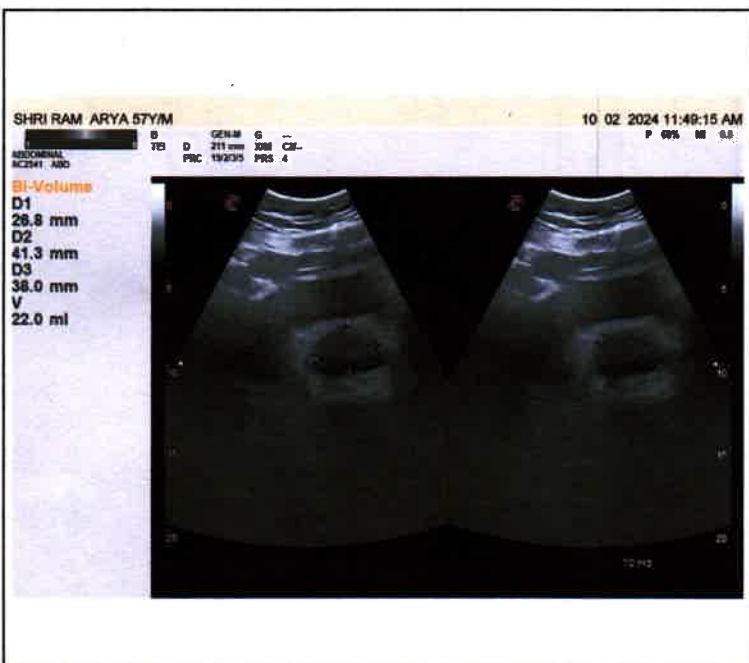
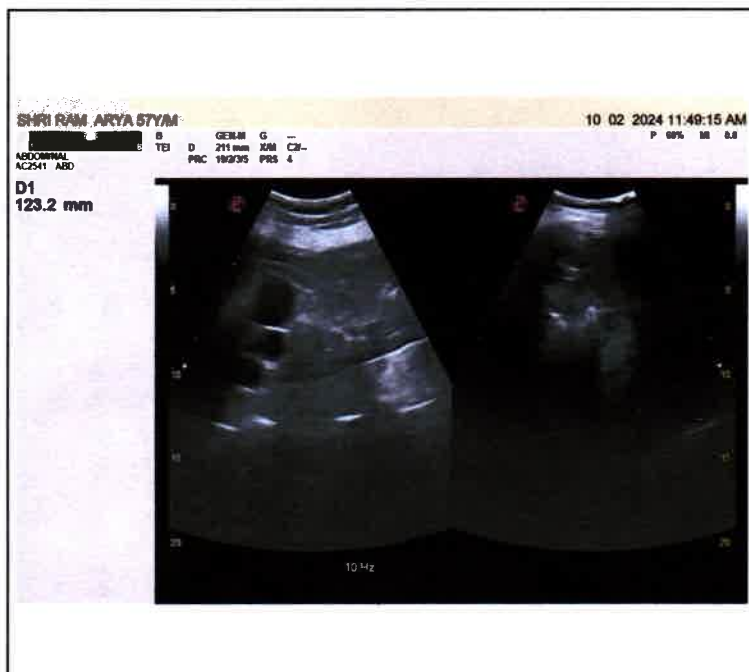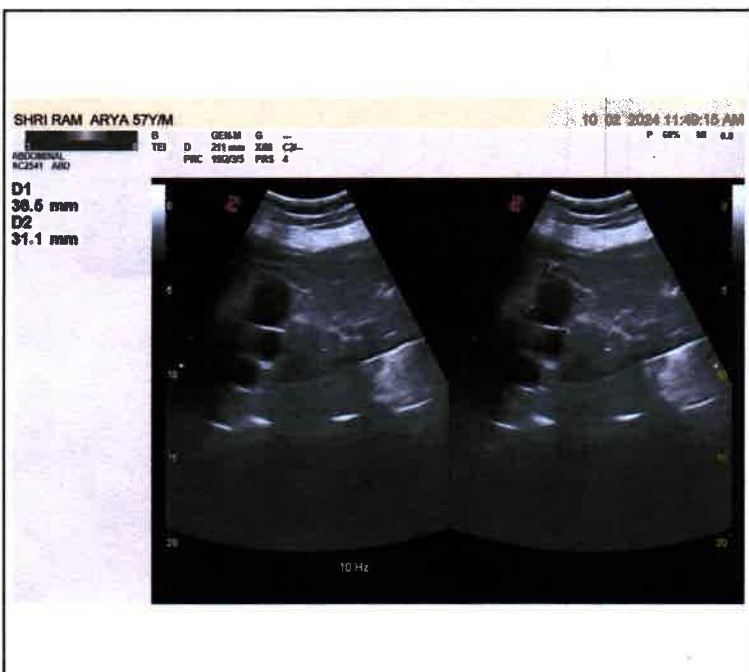
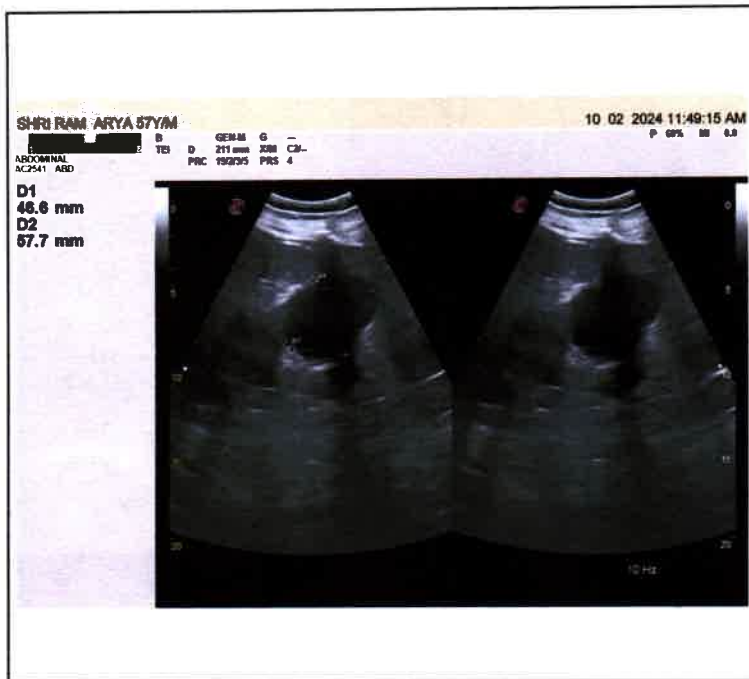
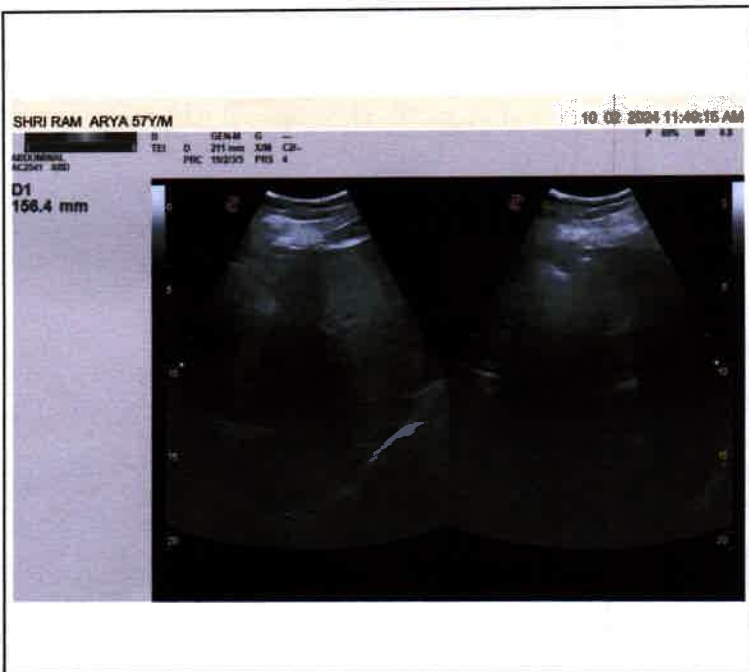
IMPRESSION :

- HEPATOMEGALY WITH GRADE I FATTY LIVER.
- MILD SPLENOMEGALY
- BILATERAL RENAL CORTICAL CYST.

Sonologist
Dr. Ashutosh Kumar Tiwari
MBBS, MD (Radio Diagonosis),
Reg. No. 57557

Disclaimer: This report is not valid for Madicolegal or Judicial Purpose. Radiological diagnosis is solely interpretation of images produced by tissue & may not be always conclusive.

Address : B36/44 B4 Kabir Nagar (Near Sanjay Shiksha Niketan), Durgakund, Varanasi
Mobile : 9554572190 / 9453837595 / Recpn, 9389994334
Email : dramishra@gmail.com, drpallaviojha@gmail.com, Website : www.piire.org





Call Now - 1800-123-3070

PANACEA HOSPITAL



A shelter for many hearts A Home for many lives

(An ISO 9001:2008 Certified Organisation)
Lab Attached with CMC Under EQAS Scheme

Dept. of Radiodiagnosis - 32 Slice CT Scan, 3D/4D USG, 2D ECHO, Colour Doppler, Intervention Procedures, Digital X-Ray

PATIENT'S NAME : SHRI RAM ARYA

AGE/SEX: 57Y/M

REF. BY : Dr. ASHUTOSH MISHRA(MD)

DATE 10-02-2024

X-RAY CHEST (AP VIEW)

- Lung fields show hazy opacities in both parahilar, basal zone with mild prominent brochopulmonary markings findings suggestive of MILD BRONCHITIS.
- Rest visualized lung fields appear normal.
- Trachea appear normal in position and course.
- Both CP angles appear clear.
- Bony rib cage and soft tissue shadows appear normal.

Thanks for reference.

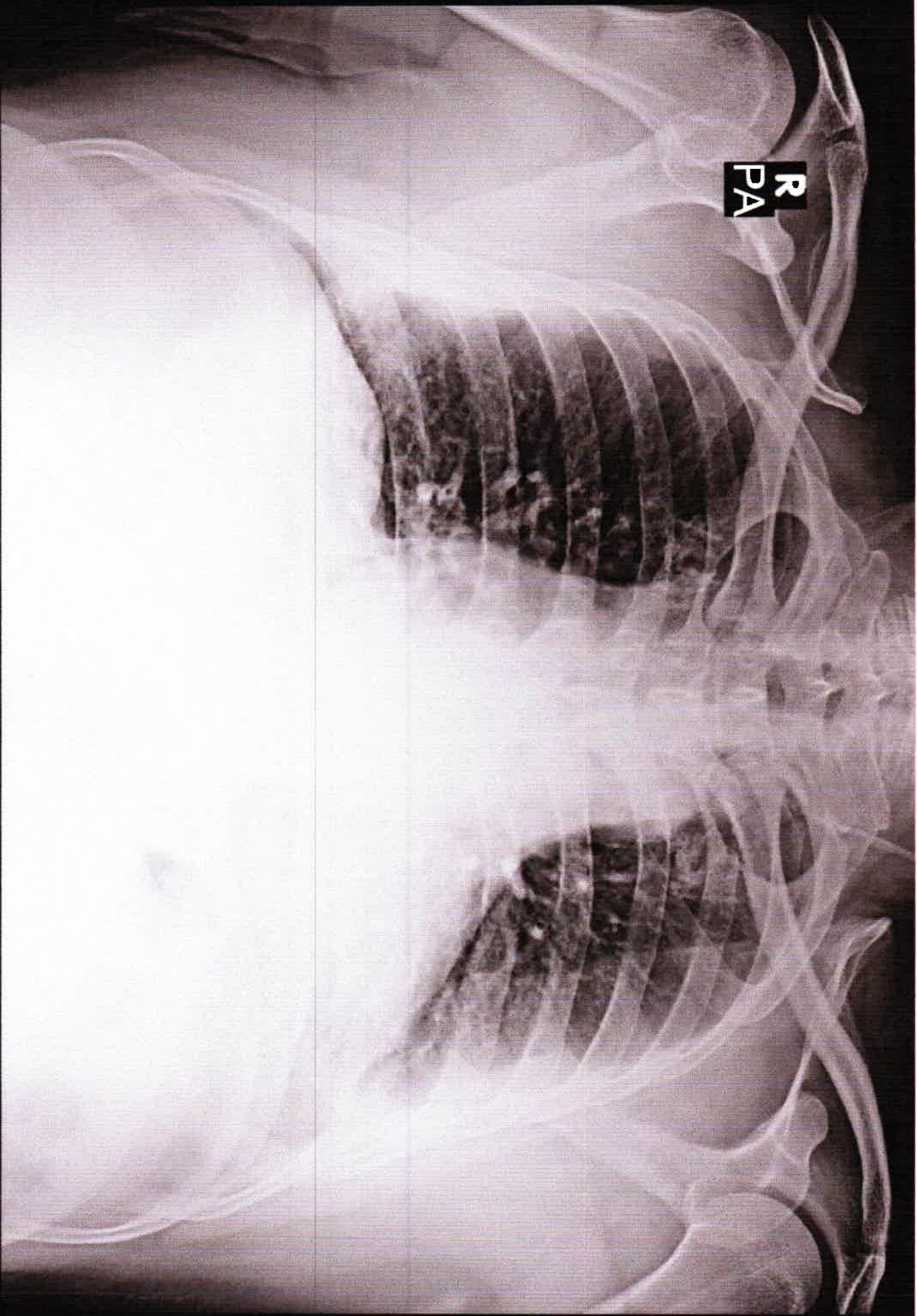
Radiologist
Dr. K. K. Tiwari
MBBS, MD (Radio Diagonosis)
Reg. No. 57557

Disclaimer: This report is not valid for Madicolegal or Judicial Purpose. Radiological diagnosis is solely Interpretation of images produced by tissue & may not be always conclusive.

Address : B36/44 B4 Kabir Nagar (Near Sanjay Shiksha Niketan), Durgakund, Varanasi

Mobile : 9554572190 / 9453837595 / Recpn, 9389994334

Email ; dramishra@gmail.com, drpallaviojha@gmail.com, Website : www.piire.org



R
PA

SHRI RAM ARYA 57Y/M 6039 M CHEST P.A. 10-Feb-24 11:07 AM

PANACEA HOSPITAL, KABIR NAGAR, DURGAKUND, VARANASI

