



DEPARTMENT OF RADIOLOGY

Patient Name	Mr AJAYPAL SINGH	Billed Date	: 21/03/2024	9.29 AM
Reg No	30512	Reported Date	: 21/03/2024	
Age/Sex	40 Years 2 Months 28Days / Male	Req. No.	: 24096946	
Type	OPD	Consultant Doctor	: Dr. CONSULTANT	

USG WHOLE ABDOMEN

LIVER : The liver is normal in size, shape and **shows increased echotexture**. No evidence of any focal lesion. IHBR is NOT dilated. Portal vein is normal.

GALL BLADDER : The gall bladder is well distended. No evidence any calculus or mass seen. GB wall thickness with in normal limits. No evidence of pericholecystic fluid is seen. The common bile duct is normal.

SPLEEN : The spleen is normal in size and shape. Its echotexture is homogeneous. No evidence of focal lesion is noted. Splenic vein is normal.

PANCREAS : The pancreas is normal in size, shape, contours and echotexture.

BILATERAL KIDNEYS : The bilateral kidneys are normal in size and echotexture. Cortico-medullary differentiation is maintained. There is no evidence of obvious calculus or hydronephrosis seen.


URINARY BLADDER : The urinary bladder is well distended. Wall thickness within normal limits. No evidence of calculus is seen. No evidence of mass or diverticulum is noted.

PROSTATE : Prostate appears normal in size, shape and echotexture.

No free fluid is seen in peritoneal cavity.
No evidence of obvious retroperitoneal or mesenteric lymphadenopathy is seen.

IMPRESSION:- USG WHOLE ABDOMEN REVEALS Grade I fatty liver.

TO BE CORRELATED CLINICALLY.


DR BINOD KR CHAUDHARY
MBBS, MD
CONSULTANT RADIOLOGIST

(This is only professional opinion and not the diagnosis, Please correlate clinically)

J-Block, Sector-10, Near Court, Faridabad - 121004, Haryana

Tel.: 0129-4200000 E-mail : parkfaridabad@gmail.com



DEPARTMENT OF RADIOLOGY

Patient Name	Mr AJAYPAL SINGH	Billed Date	: 21/03/2024	9.29 AM
Reg No	30512	Reported Date	: 21/03/2024	
Age/Sex	40 Years 2 Months 28Days / Male	Req. No.	: 24096946	
Type	OPD	Consultant Doctor	: Dr. CONSULTANT	

X-RAY CHEST AP/PA

Bilateral lungs appears normal.

Both hila are normal in size, have equal density and bear normal relationship.

The heart and trachea are central in position and no mediastinal abnormality is visible.

The cardiac size is normal for patient age and view.

The domes of the diaphragms are normal in position, and show smooth outline.

To be correlated clinically

DR BINOD KR CHAUDHARY
MBBS, MD
CONSULTANT RADIOLOGIST



DEPARTMENT OF PATHOLOGY

Patient Name : Mr. AJAYPAL SINGH
MR No : 30512
Age/Sex : 40 Years 2 Months 28 Days / Male
Type : OPD
TPA/Corporate : MEDIWHEEL

Bill Date : 21/03/2024
Reporting Date : 21/03/2024
Sample ID : 73733
Bill/Req. No. : 24096946
Ref Doctor : Dr.CONULTANT

Test	Result	Bio. Ref. Interval	Units
------	--------	--------------------	-------

STOOL ROUTINE AND MICROSCOPY

STOOL ROUTINE AND MICROSCOPY

COLOUR	BROWNISH		
CONSISTENCY	Semi Solid	Formed	
PH	ALKALINE	>= 5.5	
RBCS	NIL	NIL	
CYSTS	NIL	NIL	
OVA	NIL	Nil	
FAT GLOBULE	NIL	Nil	
PARASITES	NIL	Nil	
PUS CELLS	1-2/hpf	NIL	
MUCUS	NIL	NIL	

***** END OF THE REPORT *****



Sample no.

Dr.VIGYAN MISHRA
CONS.PATHOLOGIST

Dr. VAISHALI YADAV Dr. REETU JADHAV Dr. PARDIP KUMAR S.C. GAUR
CONS.PATHOLOGIST CONS.PATHOLOGIST MICROBIOLOGIST & ICO LAB INCHARGE USER:NM DEEPCHAND

(This is only professional opinion and not the diagnosis, Please correlate clinically)

J-Block, Sector-10, Near Court, Faridabad - 121004, Haryana
Tel.: 0129-4200000 E-mail : parkfaridabad@gmail.com



DEPARTMENT OF PATHOLOGY

Patient Name : Mr. AJAYPAL SINGH
MR No : 30512
Age/Sex : 40 Years 2 Months 28 Days / Male
Type : OPD
TPA/Corporate : MEDIWHEEL

Bill Date : 21/03/2024
Reporting Date : 21/03/2024
Sample ID : 73733
Bill/Req. No. : 24096946
Ref Doctor : Dr.CONSULTANT

Test	Result	Bio. Ref. Interval	Units
URINE ROUTINE AND MICROSCOPY			
PHYSICAL CHARACTERSTICS			
QUANTITY	40.0 ML		
COLOUR	Pale Yellow	5 - 100	ML
TURBIDITY	Clear	clear	
SPECIFIC GRAVITY	1.010	1.003 - 1.030	
PH	6.0	Acidic	
CHEMICAL EXAMINATION-1			
URINE PROTEIN	NIL	NIL	
GLUCOSE	NIL	NIL	
MICRO.EXAMINATION			
PUS CELL	0 - 1/HPF		
RED BLOOD CELLS	Nil	0-2	CELLS/HPF
EPITHELIAL CELLS	0 - 1/HPF	0-5	CELLS/HPF
CASTS	NIL	NIL	CELLS/HPF
CRYSTALS	NIL	NIL	CELLS/HPF
OTHER	NIL	NIL	CELLS/HPF

***** END OF THE REPORT *****



Sample no.

Dr.VIGYAN MISHRA
CONS.PATHOLOGIST

Dr. VAISHALI YADAV
CONS.PATHOLOGIST

Dr.REETU JADHAV
CONS.PATHOLOGIST

Dr. PARDIP KUMAR
MICROBIOLOGIST & ICO LAB INCHARGE

S.C.GAUR

USER NM DEEPCHAND

(This is only professional opinion and not the diagnosis, Please correlate clinically)

J-Block, Sector-10, Near Court, Faridabad - 121004, Haryana

Tel.: 0129-4200000 E-mail : parkfaridabad@gmail.com



DEPARTMENT OF PATHOLOGY

Patient Name : Mr. AJAYPAL SINGH

MR No : 30512

Age/Sex : 40 Years 2 Months 28 Days / Male

Type : OPD

TPA/Corporate : MEDIWHEEL

Bill Date : 21/03/2024

Reporting Date : 21/03/2024

Sample ID : 73733

Bill/Req. No. : 24096946

Ref Doctor : Dr.CONSULTANT

Test	Result	Bio. Ref. Interval	Units
CBC			
HAEMOGLOBIN	14.8	12 - 16	gm/dL
PACKED CELL VOLUME	47.3	35.0 - 50.0	%
RED BLOOD CELL COUNT	5.31	3.5 - 5.5	millions/ μ L
MEAN CORPUSCULAR VOLUME	89.0	83 - 101	fL
MEAN CORPUSCULAR HAEMOGLOBIN	27.9	27 - 31	pg
MEAN CORPUSCULAR HB CONC	31.3 L	33 - 37	g/dl
RDW	12.3	11.6 - 14.5	%
TOTAL LEUCOCYTE COUNT	5820	4000-11000	/ μ L
DIFFERENTIAL COUNT			
NEUTROPHILS	55	40.0 - 80.0	%
LYMPHOCYTES	35	20 - 40	%
MONOCYTES	07	2.0 - 10.0	%
EOSINOPHILS	03	0.0 - 5.0	%
BASOPHILS	00	0.0 - 2.0	%
PLATELET COUNT	2.08	1.50 - 4.50	lac/cumm

***** END OF THE REPORT *****



Sample no. ✓

Dr.VIGYAN MISHRA
CONS.PATHOLOGIST

Dr. VAISHALI YADAV
CONS.PATHOLOGIST

Dr. REETU JADHAV
CONS.PATHOLOGIST

Dr. PARDIP KUMAR
MICROBIOLOGIST & ICO

S.C.GAUR
LAB INCHARGE

USER NM
SEHDEV

(This is only professional opinion and not the diagnosis, Please correlate clinically)

J-Block, Sector-10, Near Court, Faridabad - 121004, Haryana

Tel.: 0129-4200000 E-mail : parkfaridabad@gmail.com



DEPARTMENT OF PATHOLOGY

Patient Name : Mr. AJAYPAL SINGH
MR No : 30512
Age/Sex : 40 Years 2 Months 28 Days / Male
Type : OPD
TPA/Corporate : MEDIWHEEL


Bill Date : 21/03/2024
Reporting Date : 21/03/2024
Sample ID : 73733
Bill/Req. No. : 24096946
Ref Doctor : Dr.CONSULTANT

Test	Result	Bio. Ref. Interval	Units
------	--------	--------------------	-------

BLOOD GROUPING AND rh FACTOR

BLOOD GROUP	" A " Rh NEGATIVE		
-------------	-------------------	--	--

***** END OF THE REPORT *****



Sample no

Dr.VIGYAN MISHRA
CONS.PATHOLOGIST

Dr. VAISHALI YADAV
CONS.PATHOLOGIST

Dr.REETU JADHAV
CONS.PATHOLOGIST

Dr. PARDIP KUMAR
MICROBIOLOGIST & ICO

S.C.GAUR

LAB INCHARGE

USER NM SEHDEV

(This is only professional opinion and not the diagnosis, Please correlate clinically)

J-Block, Sector-10, Near Court, Faridabad - 121004, Harvana
Tel : 0129-420000



DEPARTMENT OF PATHOLOGY

Patient Name : Mr. AJAYPAL SINGH
 MR No : 30512
 Age/Sex : 40 Years 2 Months 28 Days / Male
 Type : OPD
 TPA/Corporate : MEDIWHEEL
 Bill Date : 21/03/2024
 Reporting Date : 21/03/2024
 Sample ID : 73733
 Bill/Req. No. : 24096946
 Ref Doctor : Dr. CONSULTANT

Test	Result	Bio. Ref. Interval	Units
LFT (LIVER FUNCTION TEST)			
LFT			
TOTAL BILIRUBIN	0.8	0 - 1.2	mg/dL
DIRECT BILIRUBIN	0.3	0 - 0.4	mg/dL
INDIRECT BILIRUBIN	0.5	0.10 - 0.6	mg/dL
SGOT (AST)	43.7	0 - 45	U/L
SGPT (ALT)	91.4 H	0 - 45	U/L
ALKALINE PHOSPHATASE	105.2	30 - 170	IU/L
TOTAL PROTEIN	7.2	6.4 - 8.0	g/dL
ALBUMIN	4.1	3.3 - 5.5	g/dL
GLOBULIN	3.1	2.3 - 4.5	g/dL
A/G RATIO	1.32	1.1 - 2.2	

***** END OF THE REPORT *****



Sample no.

Dr. VIGYAN MISHRA
CONS. PATHOLOGIST

Dr. VAISHALI YADAV Dr. REETU JADHAV Dr. PARDIP KUMAR S.C. GAUR
 CONS. PATHOLOGIST CONS. PATHOLOGIST MICROBIOLOGIST & ICO LAB INCHARGE USER NM SEHDEV

(This is only professional opinion and not the diagnosis, Please correlate clinically)

J-Block, Sector-10, Near Court, Faridabad - 121004, Haryana
 Tel.: 0129-4200000 E-mail : parkfaridabad@gmail.com



DEPARTMENT OF PATHOLOGY

Patient Name : Mr. AJAYPAL SINGH
MR No : 30512
Age/Sex : 40 Years 2 Months 28 Days / Male
Type : OPD
TPA/Corporate : MEDIWHEEL
Bill Date : 21/03/2024
Reporting Date : 21/03/2024
Sample ID : 73733
Bill/Req. No. : 24096946
Ref Doctor : Dr.CONSULTANT

Test	Result	Bio. Ref. Interval	Units
KFT (RENAL PROFILE)			
KFT			
SERUM UREA	33.9	10 - 45	mg/dL
SERUM CREATININE	1.2	0.4 - 1.4	mg/dL
SERUM URIC ACID	6.0	2.5 - 7.0	mg/dL
SERUM SODIUM	136.0	136 - 148	mmol/L
SERUM POTASSIUM	3.7	3.5 - 5.5	mmol/L
CHLORIDE	96.0	96 - 106	mmol/L

***** END OF THE REPORT *****



Sample no.

Dr.VIGYAN MISHRA
CONS.PATHOLOGIST

Dr. VAISHALI YADAV Dr.REETU JADHAV Dr. PARDIP KUMAR S.C.GAUR
CONS.PATHOLOGIST CONS.PATHOLOGIST MICROBIOLOGIST & ICO LAB INCHARGE USER NM SEHDEV

(This is only professional opinion and not the diagnosis, Please correlate clinically)

J-Block, Sector-10, Near Court, Faridabad - 121004, Haryana

Tel.: 0129-4200000 E-mail : parkfaridabad@gmail.com



DEPARTMENT OF PATHOLOGY

Patient Name : Mr. AJAYPAL SINGH
MR No : 30512
Age/Sex : 40 Years 2 Months 28 Days / Male
Type : OPD
TPA/Corporate : MEDIWHEEL

Bill Date : 21/03/2024
Reporting Date : 21/03/2024
Sample ID : 73733
Bill/Req. No. : 24096946
Ref Doctor : Dr. CONSULTANT

Test	Result	Bio. Ref. Interval	Units
LIPID PROFILE			
LIPID PROFILE			
TOTAL CHOLESTEROL	210.73 H	120.0 - 200.0	mg/dL
SERUM TRIGLYCERIDES	108.33	40.0 - 160.0	mg/dl
HDL-CHOLESTEROL	49.05	30 - 70	mg/dl
VLDL CHOLESTEROL	21.67	6 - 32	mg/dL
LDL	140.01 H	50 - 135	mg/dl
LDL CHOLESTEROL/HDL RATIO	2.85	1.0 - 3.0	mg/dL
TOTAL CHOLESTEROL/HDL RATIO	4.3	2.0 - 5.0	mg/dl

***** END OF THE REPORT *****



Sample no.

Dr. VIGYAN MISHRA
CONS. PATHOLOGIST

Dr. VAISHALI YADAV Dr. REETU JADHAV Dr. PARDIP KUMAR S.C. GAUR
CONS. PATHOLOGIST CONS. PATHOLOGIST MICROBIOLOGIST & ICO LAB INCHARGE USER NM SEHDEV

(This is only professional opinion and not the diagnosis, Please correlate clinically)

J-Block, Sector-10, Near Court, Faridabad - 121004, Haryana
Tel.: 0129-4200000 E-mail : parkfaridabad@gmail.com



DEPARTMENT OF PATHOLOGY

Patient Name : Mr. AJAYPAL SINGH
MR No : 30512
Age/Sex : 40 Years 2 Months 28 Days / Male
Type : OPD
TPA/Corporate : MEDIWHEEL

Bill Date : 21/03/2024
Reporting Date : 21/03/2024
Sample ID : 73733
Bill/Req. No. : 24096946
Ref Doctor : Dr.CONSULTANT

Test	Result	Bio. Ref. Interval	Units
BLOOD SUGAR FASTING			
PLASMA GLUCOSE FASTING	100.03	60 - 110	mg/dl

***** END OF THE REPORT *****



Sample no

Dr.VIGYAN MISHRA
CONS.PATHOLOGIST

Dr. VAISHAL YADAV Dr.REETU JADHAV Dr. PARDIP KUMAR S.C.GAUR
CONS.PATHOLOGIST CONS.PATHOLOGIST MICROBIOLOGIST & ICO LAB INCHARGE USER NM SEHDEV

(This is only professional opinion and not the diagnosis, Please correlate clinically)



DEPARTMENT OF PATHOLOGY

Patient Name : Mr. AJAYPAL SINGH
MR No : 30512
Age/Sex : 40 Years 2 Months 28 Days / Male
Type : OPD
TPA/Corporate : MEDIWHEEL

Bill Date : 21/03/2024
Reporting Date : 21/03/2024
Sample ID : 73733
Bill/Req. No. : 24096946
Ref Doctor : Dr. CONSULTANT

Test	Result	Bio. Ref. Interval	Units
BLOOD SUGAR 2 HR. PP			
BLOOD SUGAR P.P.	141.52	80 - 150	mg/dl

***** END OF THE REPORT *****



Sample no.

Dr. VIGYAN MISHRA
CONS. PATHOLOGIST

Dr. VAISHALI YADAV
CONS. PATHOLOGIST

Dr. REETU JADHAV
CONS. PATHOLOGIST

Dr. PARDIP KUMAR - S.C. GAUR
MICROBIOLOGIST & ICO LAB INCHARGE

USER NM PRIYANKA

(This is only professional opinion and not the diagnosis, Please correlate clinically)

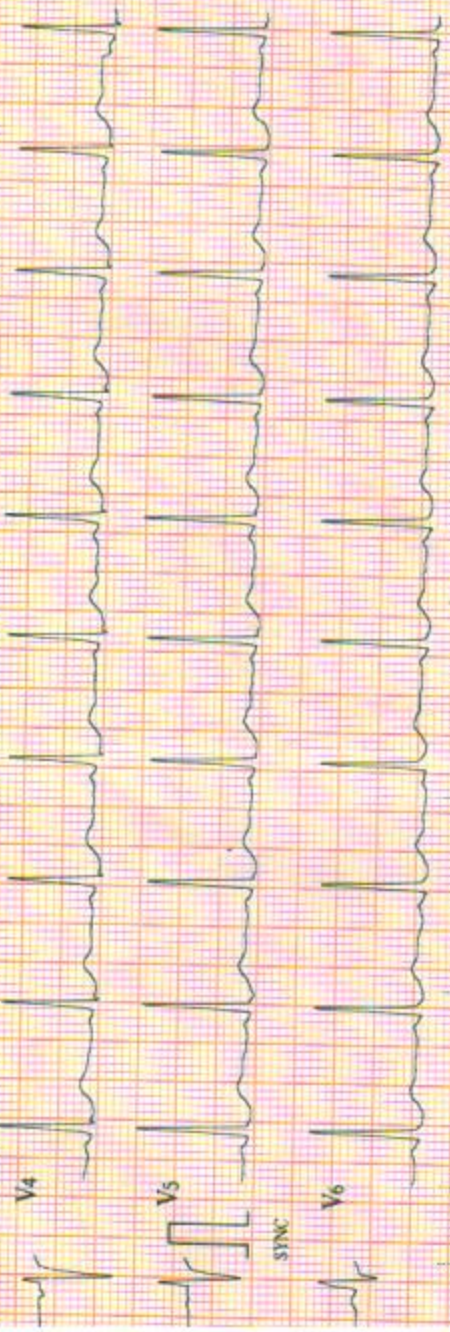
J-Block, Sector-10, Near Court, Faridabad - 121004, Haryana
Tel.: 0129-4200000 E-mail : parkfaridabad@gmail.com

21 July at 12:24 AM

ID : 4480
 Name: Aty Pel Sath
 Sex : Yo/M
 Age :

HR : 96
 P-R : 622
 QRS : 98
 QT/QTc : 322/408
 P/QRS/T : 50/52/51
 RV5/SV1 : 1-360/0-930 mV
 RV5/SV1 : 2-310 mV

10mm/mV



----- Sinus Rhythm
 ----- Short P-R Interval
 ----- T Abnormality (Flat T)

Unconfirmed report Verified by:

(S)

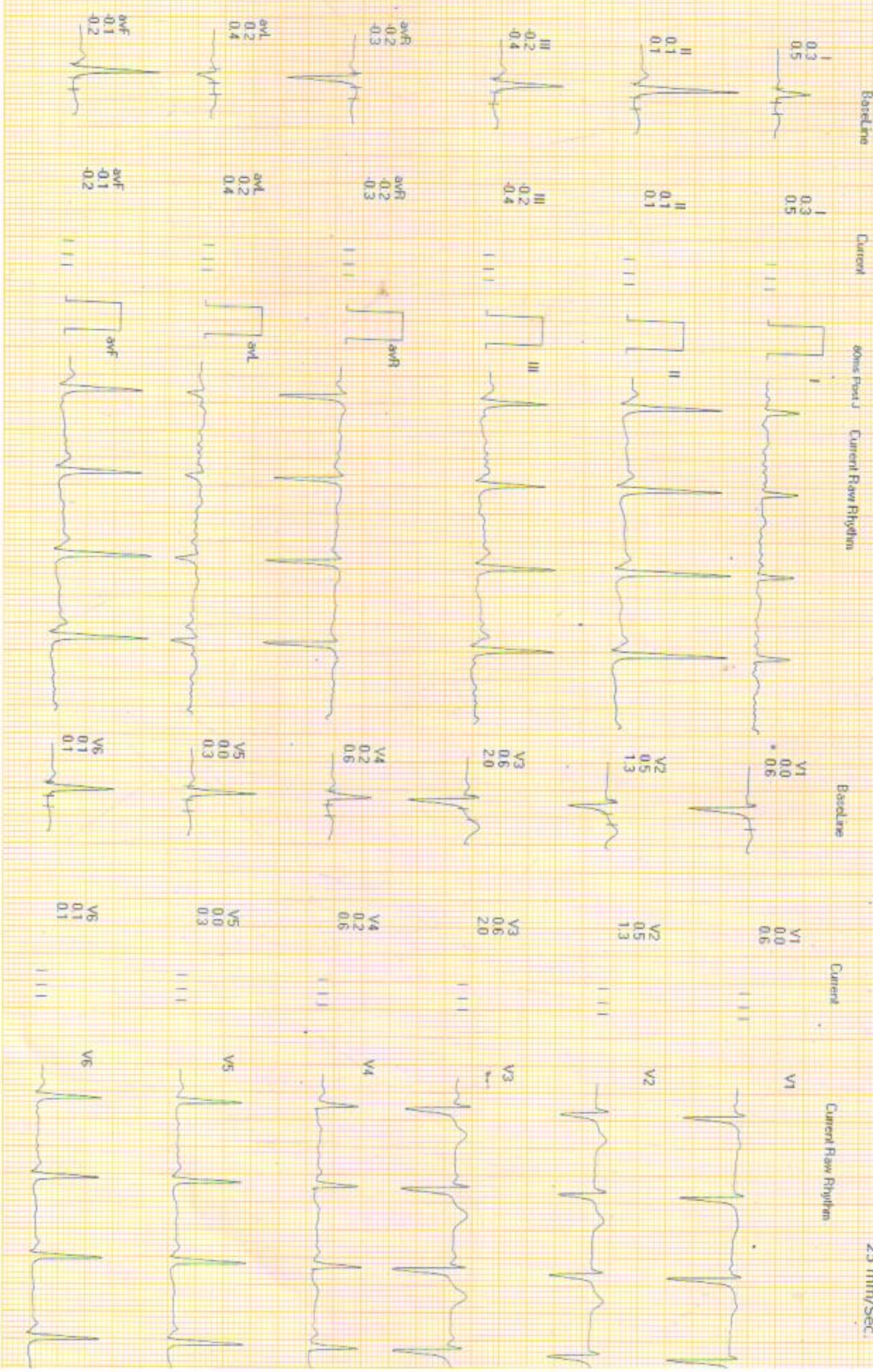
HR: 99 bpm
METS: 1.0
BP: 120/80

MPHR: 55% of 180
Speed: 0.0 mph
Grade: 0.0%

Raw ECG
[Progressive bar chart]
(0.05-100)Hz

Ex Time 00:00
BLC: On
Notch: On

ExStt
10.0 mm/mV
25 mm/Sec





ECHO REPORT

Name of the patient: MR. ASAY PAL SINGH Age: 40 Sex: Male Female

UHID No: 30512 IPD No: 24096946 Date: 21/03/2024

Refer By Doctor: DR. RAKESH ARORA

LVEF% 60%

2D ECHO

> Mitral Value Normal Pulmonary Value NI Pulm
 > Artery NI
 > Aortic avive NI Tricuspid valve NI

2D RWMA

> NO RWMA (Regional wall motion abnormality) at rest

COLD DOPPLER

> NO Significant Vavular stenosis / Regurgiation

COMMENTS AND SUMMARY

> All cardiac chambers of NI size and shape NO dilatation or hypertrophy.
 > NO RWMA (Regional wall motion abnormality) at rest
 > NO Cloth / Vegetation/ pericardial effusion
 > LV 60% Systolic function
 > NO Significant Vavular stenosis / Regurgiation

Final Impression

> EF at Rest 60%

COMMENTS 2D Echo & Color Doppler Study with

Consultant Cardiology
 Doctor Name : Dr.
 Date :

Full
 Signature
 Time
 Dr. Rakesh Kumar Arora
 MBBS, MD, DM (Cardiology)
 Reg. No. DMC - 10390
 Consultant - Cardiology
 Park Hospital, Faridabad