


Name : Miss. Y SWARNAREKHA	Age: 33 Y	UHID:CELE.0000053775
	Sex: F	
Address : E CITY		* CELE . 0 0 0 0 0 5 3 7 7 5 *
Plan : ARCOFEMI MEDIWHEEL FEMALE AHC CREDIT PAN INDIA OP AGREEMENT		OP Number:CELEOPV340861
		Bill No :CELE-OCR-55308
		Date : 02.03.2024 08:08

Sno	Service Type/ServiceName	Department
1	ARCOFEMI - MEDIWHEEL - FULL BODY HEALTH ANNUAL PLUS CHECK - FEMALE - 2D ECHO - PAN INDIA - FY2324	
1	GAMMA GLUTAMYL TRANSFERASE (GGT) 12	
2	2D ECHO 10	
3	LIVER FUNCTION TEST (LFT)	
4	GLUCOSE, FASTING	
5	HEMOGRAM + PERIPHERAL SMEAR	
6	GYNAECOLOGY CONSULTATION - 16	
7	DIET CONSULTATION	
8	COMPLETE URINE EXAMINATION	
9	URINE GLUCOSE(POST PRANDIAL)	
10	PERIPHERAL SMEAR	
11	HECG 13 2	
12	LBC PAP TEST- PAPSURE - 16	
13	RENAL PROFILE/RENAL FUNCTION TEST (RFT/KFT)	
14	DENTAL CONSULTATION 15/20	
15	GLUCOSE, POST PRANDIAL (PP), 2 HOURS (POST MEAL)	
16	URINE GLUCOSE(FASTING)	
17	HbA1c, GLYCATED HEMOGLOBIN	
18	X-RAY CHEST PA 9	
19	ENT CONSULTATION 6	
20	FITNESS BY GENERAL PHYSICIAN 25	
21	BLOOD GROUP ABO AND RH FACTOR	
22	LIPID PROFILE	
23	BODY MASS INDEX (BMI)	
24	OPHTHAL BY GENERAL PHYSICIAN 05	
25	ULTRASOUND - WHOLE ABDOMEN 8	
26	THYROID PROFILE (TOTAL T3, TOTAL T4, TSH)	

Physio - 14

Audilo - 3

NAME:	Miss. Y SWARNAREKHA
AGE / SEX:	33 YRS/ FEMALE
DATE:	01/03/2024
REFERRED BY:	ARCOFEMI

ABDOMINAL ULTRASONOGRAPHY REPORT

LIVER: Appear normal in size and echogenicity. No focal lesion seen. The intra hepatic biliary and portal venous radicals are normal. Portal vein and CBD is normal.

GALL BLADDER: moderately distended and appears normal. No abnormal wall thickening / pericholecystic fluid seen.

Pancreas: normal to the extend visualized.

SPLEEN: Normal in size and echo texture. No focal lesion noted

KIDNEYS: Both kidneys are normal in position, size and echo texture. Normal cortico-medullary differentiation is maintained. No calculus/ hydronephrosis on both sides.

PELVIC ORGANS:

Urinary bladder well distended and appears normal in size, contour and wall thickness.

Uterus retroverted appear normal in size and echo texture . Myometrial echoes appear normal. ET measures ~ 7 mm.


Bilateral ovaries are normal in size, shape and echo texture.

No free fluid in the abdomen and pelvis.

IMPRESSION:

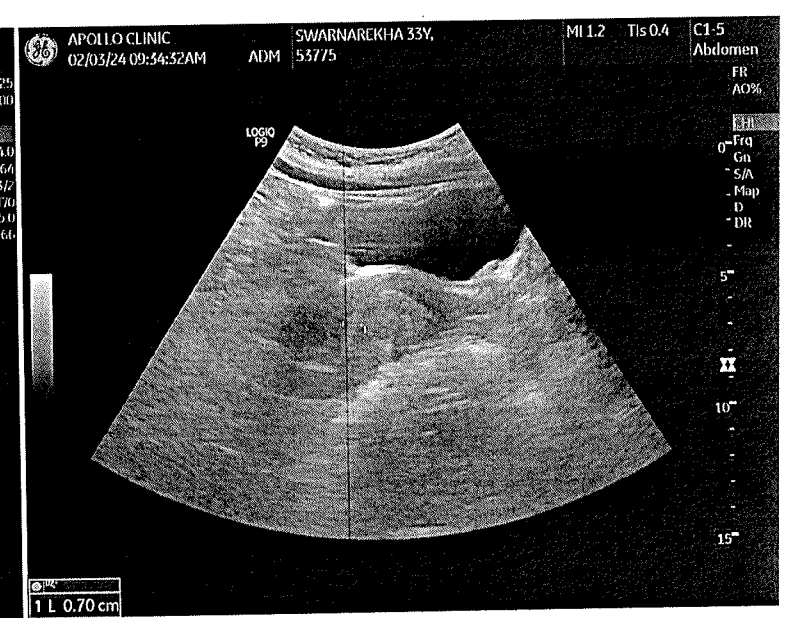
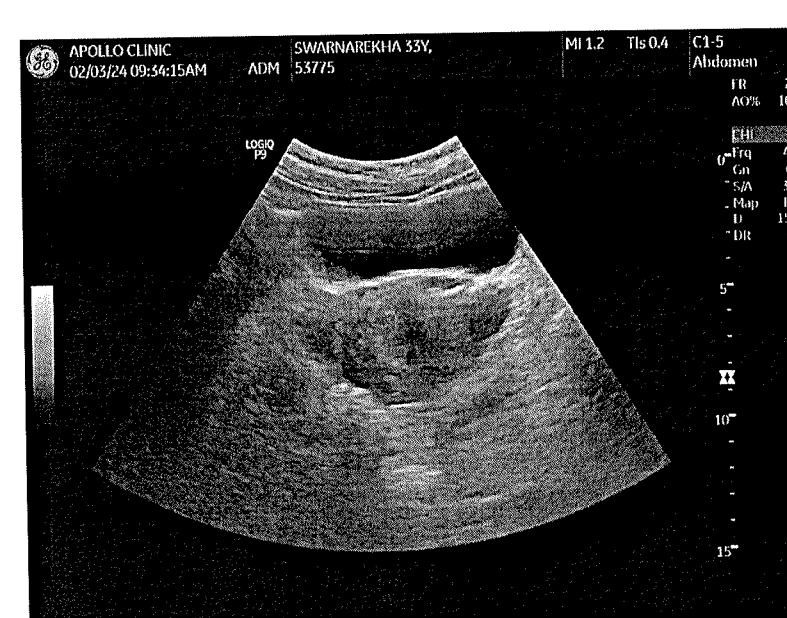
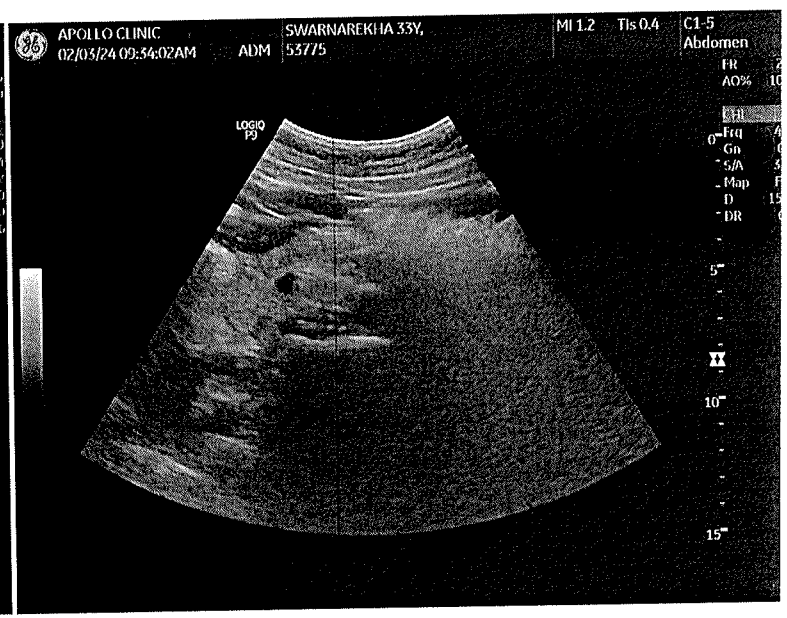
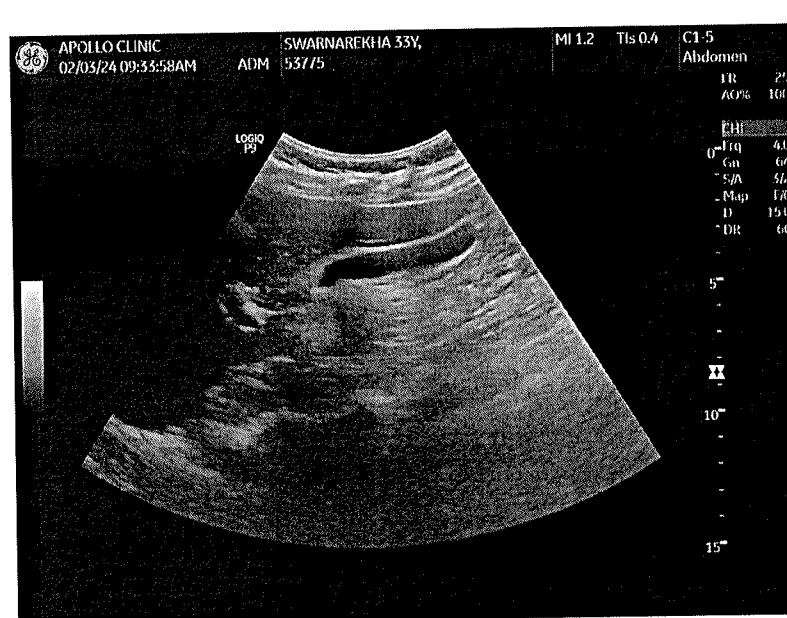
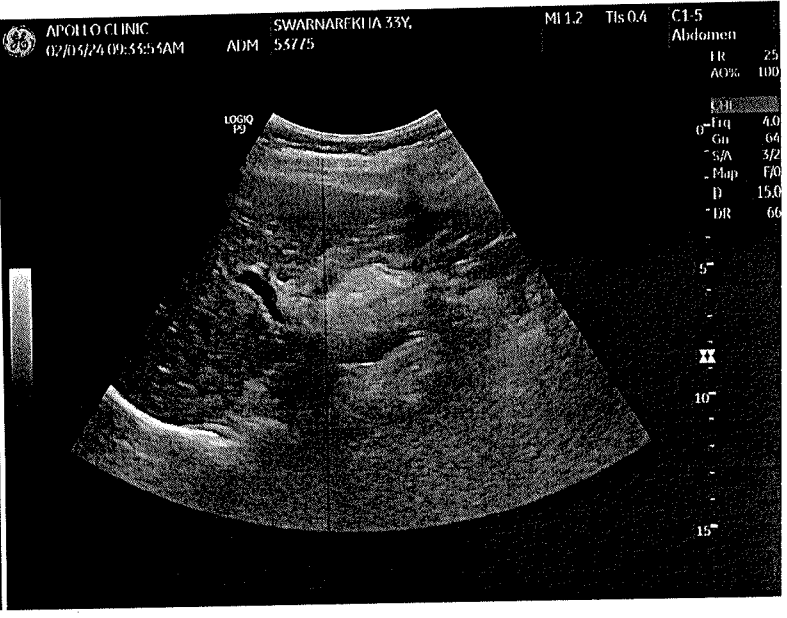
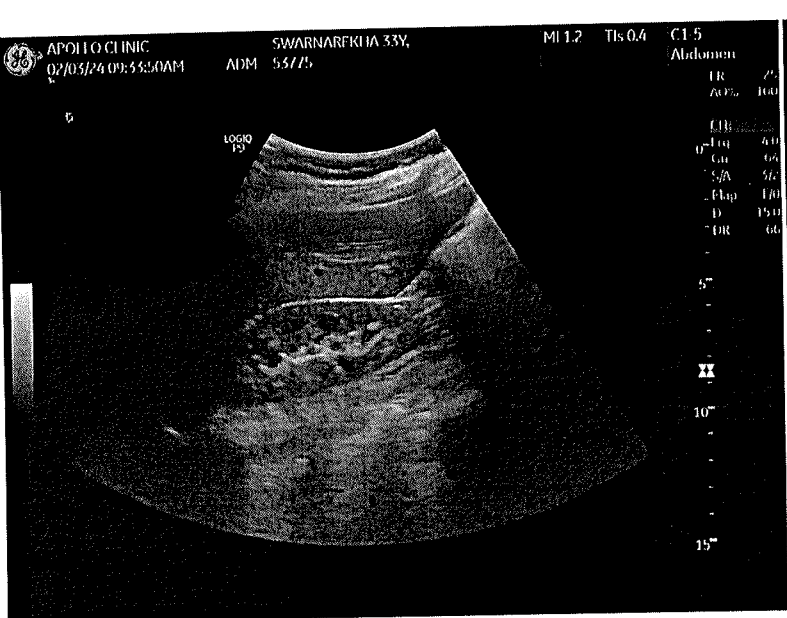
- ***No definitive sonological abnormality detected in present scan .***

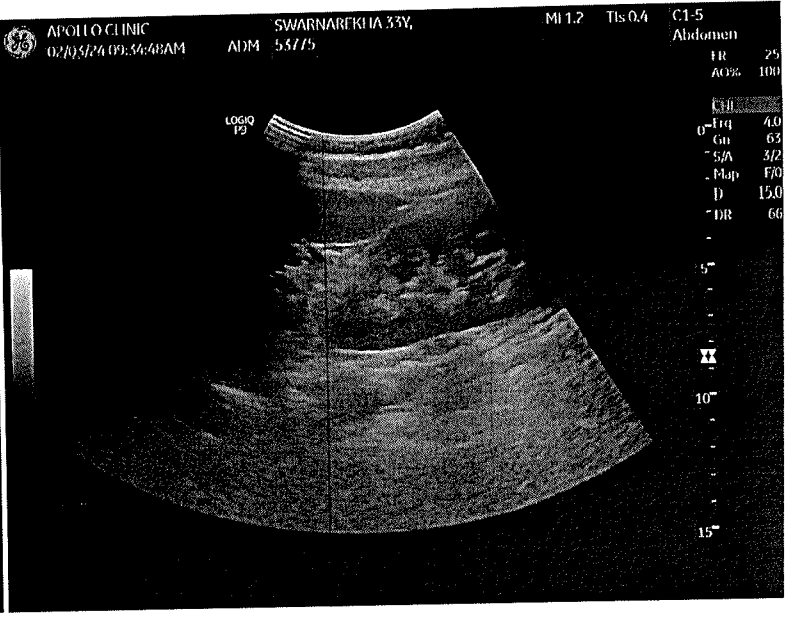
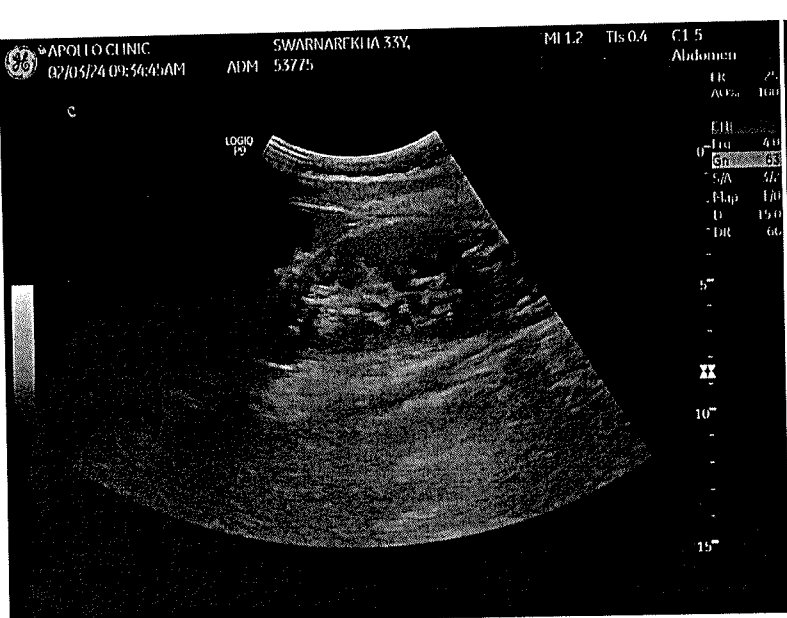
*To correlate clinically & with other investigations.
Not for medico-legal purpose*



DR. VIGNESH K

CONSULTANT RADIOLOGIST





Patient Name	: Miss. Y SWARNAREKHA	Age	: 33 Y F
UHID	: CELE.0000053775	OP Visit No	: CELEOPV340861
Reported on	: 02-03-2024 20:17	Printed on	: 02-03-2024 20:17
Adm/Consult Doctor	:	Ref Doctor	: SELF

DEPARTMENT OF RADIOLOGY

X-RAY CHEST PA

Both lung fields and hila are normal .

No obvious active pleuro-parenchymal lesion seen .

Both costophrenic and cardiophrenic angles are clear .

Both diaphragms are normal in position and contour .


Thoracic wall and soft tissues appear normal.

CONCLUSION :

No obvious abnormality seen

Printed on:02-03-2024 20:17

---End of the Report---


Dr. VIGNESH K
MBBS, MD Radio-Diagnosis
Radiology

Personal Details

UHID: 00XHE1PU6T80NH1

PatientID: 53775

Name: Miss Y Swamarekha

Age: 33

Gender: Female

Mobile: 8801132210

Pre-Existing Medical- Symptoms

Conditions

Vitals

Measurements

HR: 65 BPM

PR: 126 ms

PD: 110 ms

QRSD: 108 ms

QRS Axis: 64 deg

QT/QTc: 380/380 ms

Report ID: AHLLP_00XHE1PU6T80NH1_V6T80NID

Interpretation

Normal sinus rhythm

Normal axis

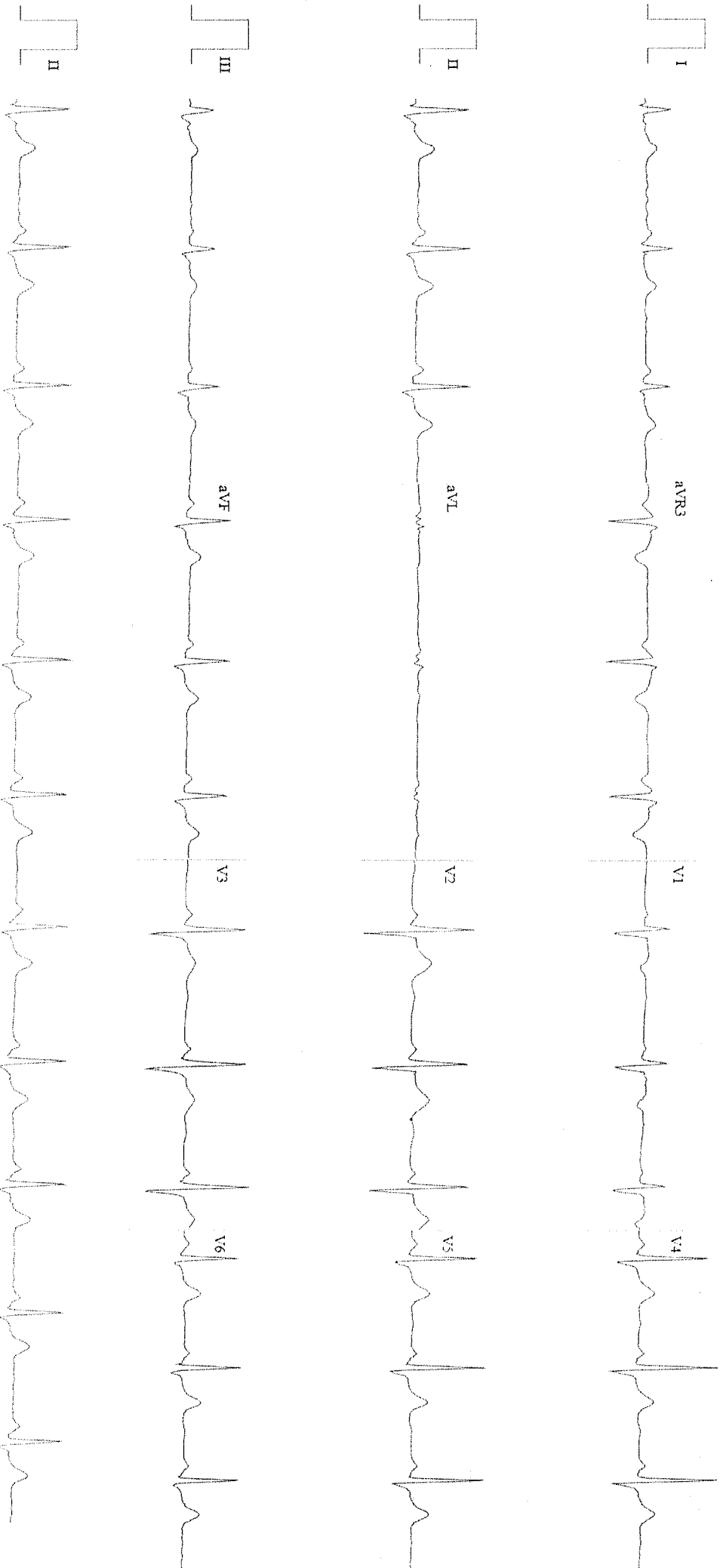
Normal axis

ApolloMed
Group

Authorized by

Yogesh

Dr. Yogesh Kothari
MD, DNB, FESC, FEP
Reg No- KMC 44065



Speed: 25 mm/sec F: 0.05 - 40 Hz Limb: 10 mm/mV Chest: 10 mm/mV

2-D ECHO-CARDIOGRAPHY DOPPLER & COLOUR DOPPLER REPORT

NAME : MRS Y SWARNAREKHA

DATE:02/03/2024

AGE/SEX: 33 Y/ F

REF : ARCOFEMI – MEDIWHEEL

UHID:53775/03/

***** MEASUREMENTS & FLOW VELOCITIES AS DEPICTED IN IMAGES OVERLEAF.**

1. NORMAL VALVES.
2. NORMAL FLOW ACROSS ALL VALVES.
3. NO MR/ AR/ TR.
4. NORMAL GREAT VESSELS.
5. NORMAL SYSTEMIC VEINS & AT LEAST 3 PULMONARY VEINS SEEN DRAINING INTO LA.
6. NORMAL SIZED CHAMBERS.
7. NO REGIONAL WALL MOTION ABNORMALITIES.
8. INTACT SEPTAE (IVS & IAS).
9. GOOD LV & RV SYSTOLIC FUNCTION.
10. PERICARDIUM : NORMAL
11. NO OBVIOUS VEGETATION / CLOTS.



DR (CAPT.)S.V KRISHNA RAO

MD (PGI), DNB (Card)

Senior Consultant – Cardiologist

Reg No : ANP 19780000746KTK

To correlate with clinical findings & other relevant investigations .

Apollo Health and Lifestyle Limited

(CIN - U85110TG2000PLC115819)

Regd. Office: 1-10-60/62, Ashoka Raghupathi Chambers, 5th Floor, Begumpet, Hyderabad, Telangana - 500 016.

Ph No: 040-4904 7777, Fax No: 4904 7744 | Email ID: enquiry@apollohl.com | www.apollohl.com

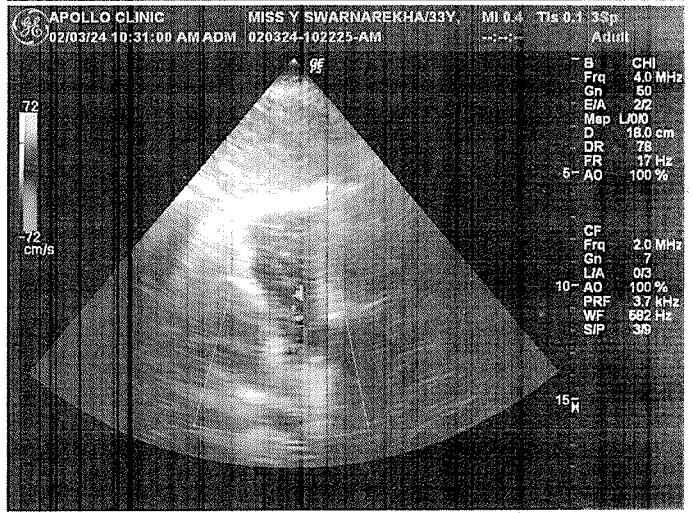
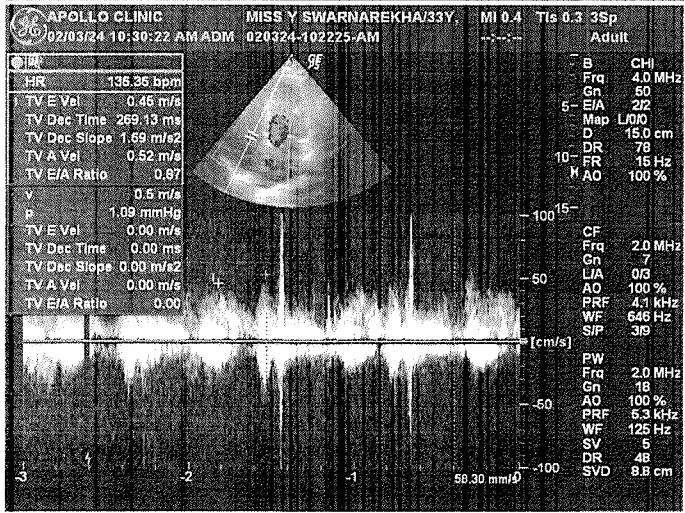
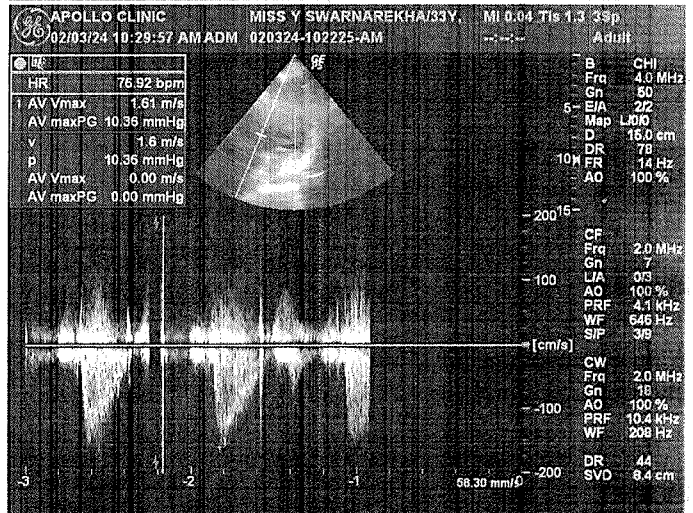
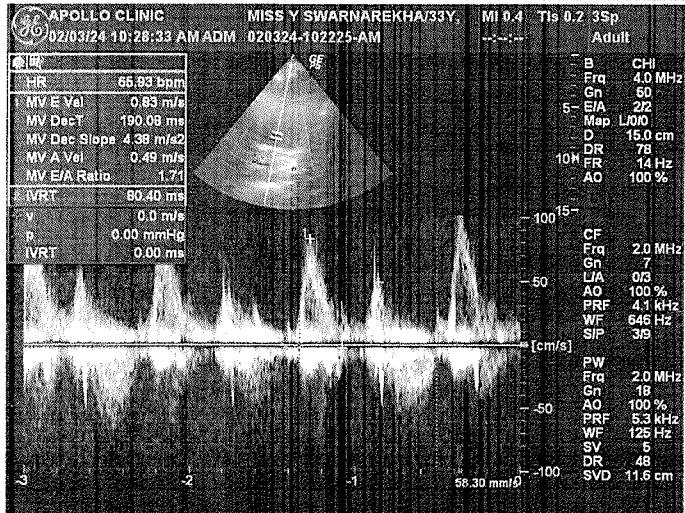
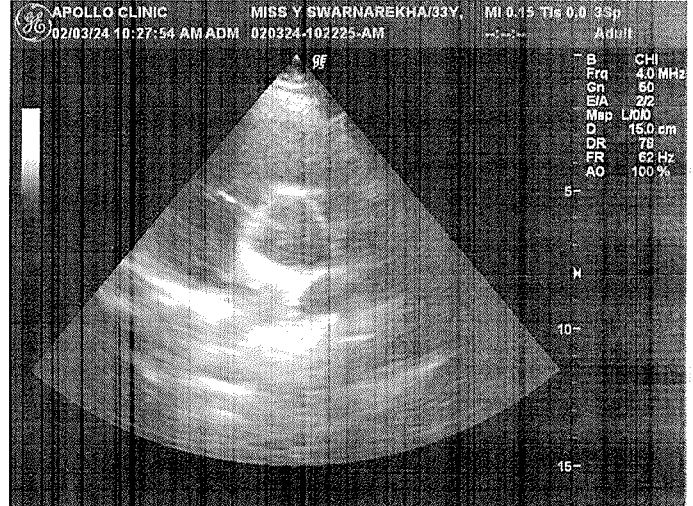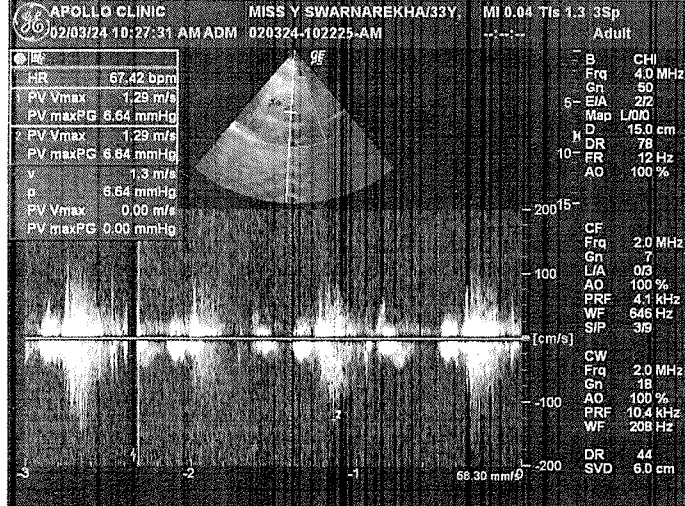
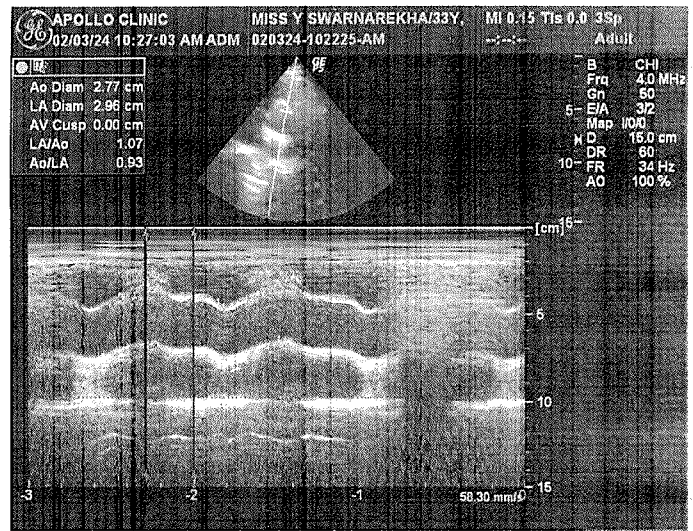
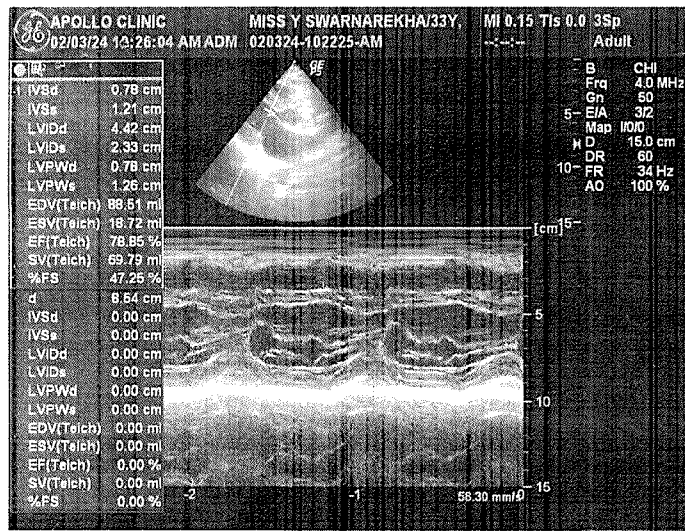
APOLLO CLINICS NETWORK KARNATAKA

Bangalore (Basavanagudi | Bellandur | Electronic City | Fraser Town | HSR Layout | Indira Nagar | JP Nagar | Kundalahalli | Koramangala | Sarjapur Road) **Mysore** (VV Mohalla)

Online appointments: www.apolloclinic.com

TO BOOK AN APPOINTMENT

 **1860 500 7788**



Apollo Clinic

CONSENT FORM

Patient Name: Mrs. Swagora Relche Age: 33y


UHID Number: 537H Company Name: Arcofem

I Mr/Mrs/Ms. Swagora Relche Employee of Arcofem: ENT, Dental, Eyecare
Diet consultation, physiotherapy, physio consult, audio
(Company) want to inform you that I am not doing pop smear procedure due
to discomfort which is a part of my health package,
tabu

And I claim the above statement in my full consciousness.

Patient Signature: S Swagora Date: 2/03/24


53775 - Y Swarnarekha
Rekha




If you face any problem with the Lab Centre during the appointment day please call us immediately at 08045684250 to resolve the issue.

Please note that all consumable i.e. : Films/Plates, Blood test (Not included in test) , Doctor consultation(Not included) will charged as per actual mentioned by Lab centre or hospital

This is a system generated correspondence. Please do not reply to this email.



Download app 

© 2023 MediBuddy

This e-mail and any files transmitted with it are for the sole use of the intended recipient(s) and may contain confidential and privileged information. If you are not the intended recipient(s), please reply to the sender and destroy all copies of the original message. Any unauthorized review, use, disclosure, dissemination, forwarding, printing or copying of this email, and/or any action taken in reliance on the contents of this e-mail is strictly prohibited and may be unlawful. Where permitted by applicable law, this e-mail and other e-mail communications sent to and from Cognizant e-mail addresses may be monitored.

Patient First Name

MS.

Patient Last Name

SWARNAREKHA Y

Patient Mobile Number

8801132210

Patient E-mail ID

swarnarekha90@gmail.com

Date of Birth

01-04-1990

Gender

female

Client

ARCOFEMI HEALTHCARE LIMITED

Agreement Name

(1) ARCOFEMI MEDIWHEEL FEMALE AHC

Package Name

**(1) ARCOFEMI - MEDIWHEEL - FULL
BODY HEALTH ANNUAL PLUS CHECK -**

Visit Type

in-clinic

Visit Status

Report Status

Order Confirmed

City

Clinic

ELECTRONIC CITY

Order Date

29-02-2024

Appointment Date

Fwd: Health Check up Booking Confirmed Request(bobE12172),Package Code-PKG10000377, Beneficiary Code-301261

SwarnaRekha <swarnarekha90@gmail.com>

Thu 29-Feb-24 3:37 PM

To:Chandapura,Bangalore , Bengaluru South Region <VJCHPU@bankofbaroda.com>

****सावधान:** यह मेल बैंक डोमेन के बाहर से आया है. अगर आप प्रेषक को नहीं जानते तो मेल में दी गर्थ
****CAUTION:** THIS MAIL IS ORIGINATED FROM OUTSIDE OF THE BANK'S DOMAIN. DO N

----- Forwarded message -----

From: **Mediwheel** <wellness@mediwheel.in>

Date: Thu, 29 Feb, 2024, 3:02 pm

Subject: Health Check up Booking Confirmed Request(bobE12172),Package Code-PKG10000377, Beneficiary Code-301261

To: <swarnarekha90@gmail.com>

Cc: <customercare@mediwheel.in>

011-41195959

Dear Y swarnarekha,

We are pleased to confirm your health checkup booking request with the following details.

Hospital Package Name : Mediwheel Full Body Health Annual Plus Check
Patient Package Name : Mediwheel Full Body Health Checkup Female Below 40
Name of Diagnostic/Hospital : Apollo Clinic - Electronic City
Address of Diagnostic/Hospital- : Apollo Clinic, 323/100, Opp.Ajmera infinity Apartment, Neeladri Nagar, Electronic city Phase -1, Electronic city - 560100
City : Bangalore
State :
Pincode : 560100
Appointment Date : 02-03-2024
Confirmation Status : Booking Confirmed
Preferred Time : 8:00am
Booking Status : Booking Confirmed

Member Information		
Booked Member Name	Age	Gender
MS. SWARNAREKHA Y	34 year	Female