



இந்திய அரசாங்கம்

Government of India




கோபிநாத் வே

Gopinath V

பிறந்த நாள்/DOB: 18/10/1984

ஆண்/ MALE



6060 6563 9841

எனது **ஆதார்**, எனது அடையாளம்



இந்திய தனிப்பட்ட அடையாள ஆணைய அமைப்பு

Unique Identification Authority of India

Address:

S/O: Vedachalam, 123,
Varatharajapuram, ATHIPATTU,
Tiruvallur,
Tamil Nadu - 600120

முகவரி:

தந்தை / தாய் பெயர்: வேதாசலம், 123
வரதராஜபுரம், அத்திப்பட்டு,
திருவள்ளூர்,
தமிழ் நாடு - 600120

6060 6563 9841



1947



help@uidai.gov.in

WWW

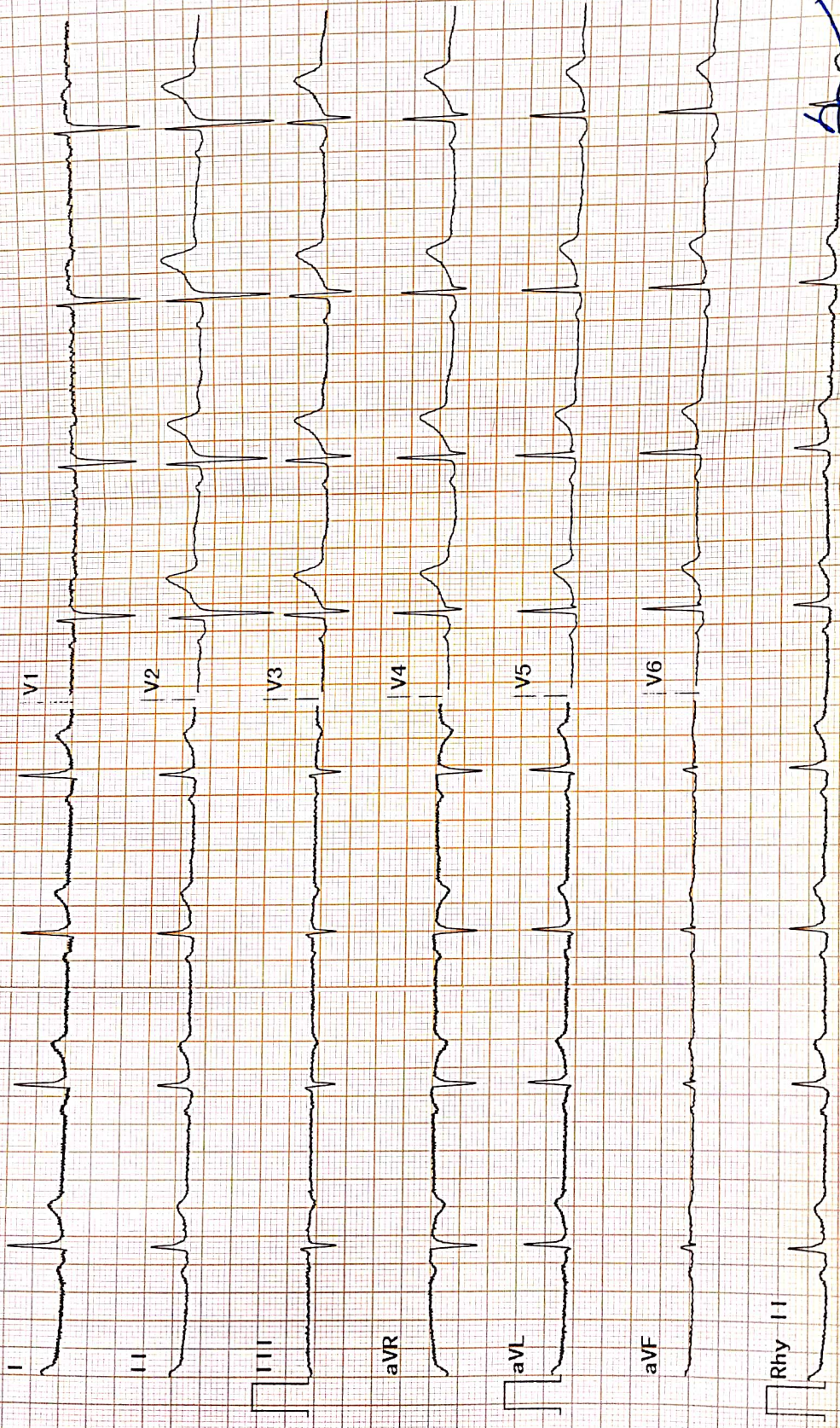
www.uidai.gov.in

ID : 2407270000
 Name: GOPINATH
 Sex : Male
 Divisions:

DataTime: 2024-07-27 08:26
 Age : 39
 BP : 120/80 mmHg
 Bed No. :
 HR 52 bpm
 P Dur/PR int 100/172ms
 QRS Dur 100ms
 QT/QTc int 420/391 ms
 P/QRS T axis 28/16/18°

Patient ID: 58714
 Height : 160 cm
 Weight : 66 kg
 Hospital No. :
 Minnesota Code
 8-8-3
 9-4-1 (V3)

Hospital: MURUGAN HOSPITAL
 Diagnosis Info
 811: Sinus Bradycardia
 Normal ECG



Diagnosis for reference, ask your doctor to confirm
 AUTO PRINT 6X2+1R 52bpm, 10 mm/mV 0.50Hz-35Hz AC 50Hz 25 mm/sec

SIDHARTHAN MD
 Consultant Cardiologist
 Confirmed By: **COMED C REP No 62979**



MURUGAN HOSPITALS

HEALING HANDS



SCAN REPORT

NAME	:MR.V.GOPINATH	PATIENT ID	:MH20240058714
AGE/SEX	:39 Years / MALE	IP / OP NO	:OP21090594
CONSULTANT	:DR.ARUN PRAKASH	DATE	:27/07/2024

ULTRA SOUND SCAN OF ABDOMEN

LIVER: Mildly enlarged in size and measures- 15.1 cm and increased in echotexture. No focal lesions are seen. No dilatation of intra-hepatic biliary radicals present. Hepatic veins and IVC appear normal. Portal vein is normal in caliber. Common bile duct is normal in caliber.

GALL BLADDER: Normal in size and wall thickness. No evidence of any calculus or mass present. No evidence of pericholecystic collections.

PANCREAS: Head and body normal tail obscured by bowel gas.

PARA AORTIC AREAS: Aorta and IVC appear normal. No evidence of para aortic lymphadenopathy.

SPLEEN: Normal in size and measures-9.0 cm. Normal in echotexture. No evidence of focal lesions.

Healing Hearts and Lives

264/125, Kilpauk Garden Road, Kilpauk, Chennai - 600 010. Phone : +91 44 4644 8989 / 75500 53335
Email : muruganhosp@gmail.com | Website : www.muruganhospitals.in

RIGHT KIDNEY: Measures 10.9 x 5.1 cm and is normal in size and echotexture. Cortico medullary differentiation is well maintained. There is no hydronephrosis or mass. **A calculus of size 4.9 mm seen in mid pole of right kidney.**

LEFT KIDNEY: Measures 9.5 x 5.3 cm and is normal in size and echotexture. Cortico medullary differentiation is well maintained. There is no calculus or hydronephrosis or mass.

URINARY BLADDER: Empty.

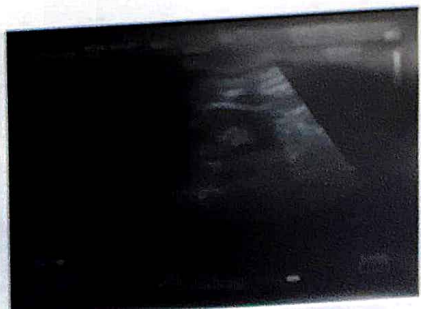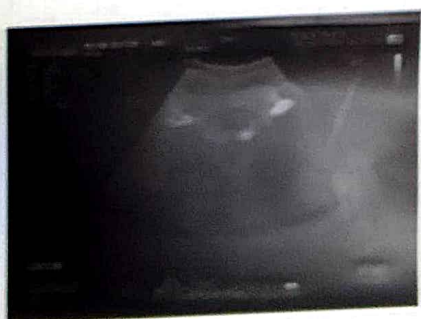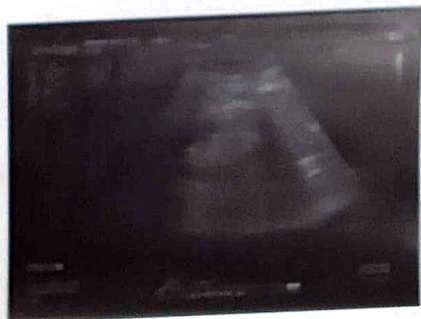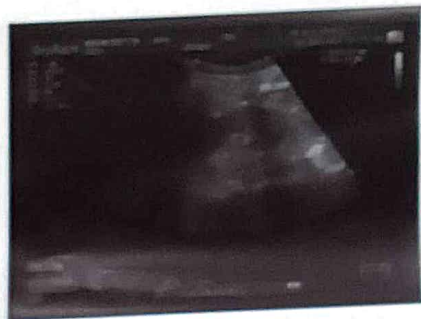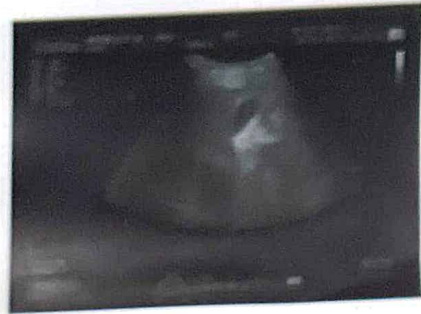PROSTATE: Could not be assessed.

No ascites present. No retroperitoneal lymphadenopathy present.

IMPRESSION:

- **Hepatomegaly with fatty infiltration**
- **Right renal calculus**
- **No other significant abnormality detected in the visualized abdominal organs.**


CONSULTANT RADIOLOGIST,





MURUGAN HOSPITALS

HEALING HANDS



ECHO CARDIOGRAM REPORT

NAME: MR.V.GOPINATH

UHIDNO:MH20240058714

AGE&SEX : 39-Years / Male

IP/OP : OP

CONSULTANT: DR. RAMESH KUMAR

DATE : 27/07/2024

2D PLAX (mm)

RV - 35 mm
AO - 29 mm
LA - 32 mm

COLOR DOPPLER

Normal

M-Mode (mm)

IVS - 10 mm
PW - 09 mm
LVD - 42 mm
LVS - 27 mm
EF - 64 %
FS - 35 %

DOPPLER (m/sec)

MITRAL E - 0.6 m/s
MITRAL A - 0.4 m/s
PULMONARY - 0.9 m/s
AORTIC - 1.0 m/s
TRICUSPID - 0.5 m/s

IMPRESSION:

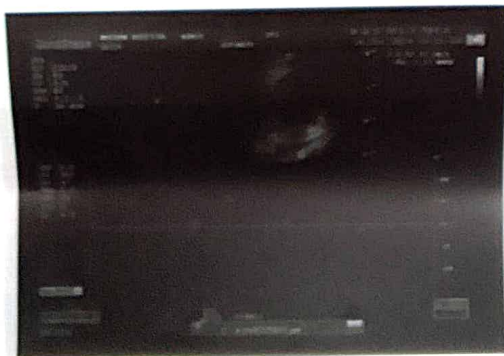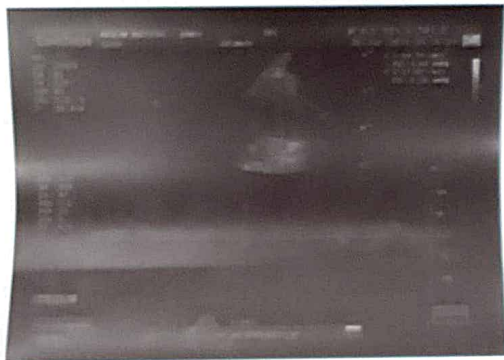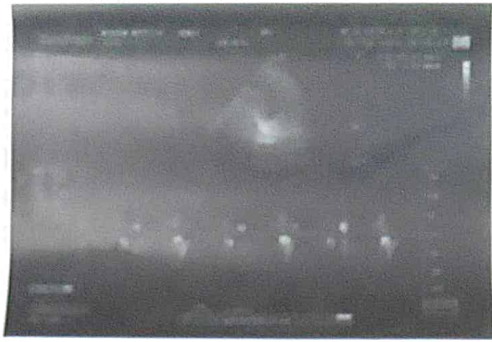
Bradycardia during Study

No regional wall motion abnormality
Normal LV Systolic function
Grade I left ventricular diastolic dysfunction
Normal RV function
No pulmonary hypertension
No pericardial effusion
No obvious clot/ Vegetation.

DR. SIDHARTHAN, MD., DM.,
Consultant Cardiologist

Healing Hearts and Lives

264/125, Kilpauk Garden Road, Kilpauk, Chennai - 600 010.
Phone : +91 44 4644 8989 / 75500 53335 | Email : muruganhosp@gmail.com
Website : www.muruganhospitals.in





MURUGAN HOSPITALS

HEALING HANDS



LAB REPORT

Patient Name : Mr. V.GOPINATH
Age / Gender : 39-Years / Male
UHID ID : MH20240058714
Doctor Name : Dr. ARUN PRAKASH

OP Report No. : INVA2116061
Bill No. : INV2404453
Sample Date : 27/07/2024 - 09:00 AM
Report Date : 27/07/2024 - 01:30 PM

Test Name	Result	Units	Reference Interval
-----------	--------	-------	--------------------

HAEMATOLOGY

COMPLETE BLOOD CELL COUNT(CBC)

HAEMOGLOBIN	<u>11.1</u>	gms/dl	male :13.0 - 17.0 female :12.0 - 15.0
PACKED CELL VOLUME	<u>34.8</u>	%	male : 40 - 50 female : 36 - 46
RBC COUNT	4.50	millions cells/cu.mm	female: 3.8 - 4.8 male : 4.5 - 5.5
TOTAL WBC	5,230	Cells/Cumm	4,000 - 11,000
Differential Count			
NEUTROPHILS	51.7	%	40 - 65
LYMPHOCYTES	38.6	%	30-50
EOSINOPHILS	3.8	%	01-06
MONOCYTES	5.9	%	1-10
BASOPHILS	00	%	0-2
ESR 60 MTS	12	mm	5 - 20
PLATELET COUNT	2.50	Lakhs/cumm	1.5 - 4.5
MCV	77.3	fL	76 - 96
MCH	<u>24.6</u>	pg	27 - 32
MCHC	31.9	gms/dl	30 - 36
BLOOD GROUPING & RH TYPING	"O" POSITIVE		

Page 1 of 4

Healing Hearts and Lives

264/125, Kilpauk Garden Road, Kilpauk, Chennai - 600 010.
Phone : +91 44 4644 8989 / 75500 53335 | Email : muruganhosp@gmail.com
Website : www.muruganhospitals.in



MURUGAN HOSPITALS

HEALING HANDS



LAB REPORT

Patient Name : Mr. V.GOPINATH
Age / Gender : 39-Years / Male
UHID ID : MH20240058714
Doctor Name : Dr. ARUN PRAKASH

OP Report No. : INVA2116061
Bill No. : INV2404453
Sample Date : 27/07/2024 - 09:00 AM
Report Date : 27/07/2024 - 01:30 PM

Test Name	Result	Units	Reference Interval
-----------	--------	-------	--------------------

BIO CHEMISTRY

BLOOD SUGAR FASTING	84	mg/dl	70-110
BLOOD SUGAR POST PRANDIAL	101	mg/dl	80- 160
SERUM URIC ACID	6.2	mg/dl	male 3.1-7.0 , female 2.5-5.6
SERUM CREATININE	0.9	mg/dl	0.6-1.4
LIPID PROFILE			
TOTALCHOLESTEROL	151	mg/dl	< 200
TRIGLYCERIDE	<u>153</u>	mg/dl	< 150
HDL	39	mg/dl	35 - 80
VLDL	30	mg/dl	2 to 30
LDL	82	mg/dl	<130
CHOLESTEROL/ HDL RATIO	3.8	mg/dl	

Page 2 of 4

Healing Hearts and Lives

264/125, Kilpauk Garden Road, Kilpauk, Chennai - 600 010.
Phone : +91 44 4644 8989 / 75500 53335 | Email : muruganhosp@gmail.com
Website : www.muruganhospitals.in



MURUGAN HOSPITALS

HEALING HANDS



LAB REPORT

Patient Name : Mr. V.GOPINATH
Age / Gender : 39-Years / Male
UHID ID : MH20240058714
Doctor Name : Dr. ARUN PRAKASH

OP Report No. : INVA2116061
Bill No. : INV2404453
Sample Date : 27/07/2024 - 09:00 AM
Report Date : 27/07/2024 - 01:30 PM

Test Name	Result	Units	Reference Interval
LIVER FUNCTION TEST			
BILLIRUBIN(TOTAL)	0.5	mg/dl	0.0 -1.0
BILLIRUBIN(DIRECT)	0.2	mg/dl	0.1- 0.30
BILLIRUBIN(INDIRECT)	0.3	mg/dl	0.2-0.8
SGOT	19	IU/L	0-38
SGPT	22	IU/L	0.0-40
ALKALINE PHOSPHATASE	76	IU/L	40-140
			4-6Years 93-309
			13-15Years 74-390
TOTAL PROTEIN	7.8	gm/dl	6.6-8.7
ALBUMIN	4.4	gm/dl	3.5 - 5.5
GLOBULIN	3.4	gm/dl	2.0-3.5
AG RATIO	1.2		
GAMMA G T	41.2	U/L	< 55 U/ L
BLOOD UREA NITROGEN	12.9	mg/dl	7-21
HBA1C	5.7	%	normal: <6.0 good control: 6.1-7.0 fair control: 7.1- 8.0 poor control:8.1 -10.0 unsatisfactory: >10.0

Healing Hearts and Lives

264/125, Kilpauk Garden Road, Kilpauk, Chennai - 600 010.
Phone : +91 44 4644 8989 / 75500 53335 | Email : muruganhosp@gmail.com
Website : www.muruganhospitals.in



MURUGAN HOSPITALS

HEALING HANDS



LAB REPORT

Patient Name : Mr. V.GOPINATH
 Age / Gender : 39-Years / Male
 UHID ID : MH20240058714
 Doctor Name : Dr. ARUN PRAKASH

OP Report No. : INVA2116061
 Bill No. : INV2404453
 Sample Date : 27/07/2024 - 09:00 AM
 Report Date : 27/07/2024 - 01:30 PM

Test Name	Result	Units	Reference Interval
-----------	--------	-------	--------------------

CLINICAL PATHOLOGY

URINE SUGAR (F) NIL

URINE SUGAR (PP) NIL

URINE ROUTINE

COLOUR PALE YELLOW

APPEARANCE CLEAR

REACTION ACIDIC

SUGAR NIL

ALBUMIN NIL

DEPOSITES

PUS CELLS 2 - 3 / HPF

EPI CELLS 1 - 2 / HPF

RBC COUNT NIL / HPF

CAST NIL

CRYSTALS NIL

OTHERS NIL

SHENBAGWALLI
 Verified by

*** End of Report ***



Healing Hearts and Lives

264/125, Kilpauk Garden Road, Kilpauk, Chennai - 600 010.

Phone : +91 44 4644 8989 / 75500 53335 | Email : muruganhosp@gmail.com

Website : www.muruganhospitals.in



MURUGAN HOSPITALS

HEALING HANDS



LAB REPORT

NAME : MR. GOPINATH V
PIN : AND24380083558
AGE/GENDER : 39 Year(s)/Male
REFERRED BY : Dr. ARUN PRAKASH .
CLIENT NAME : MURUGAN HOSPITAL

SAMPLE NO : 382466110
COLLECTED ON : 27/07/2024 03:45 PM
RECEIVED ON : 27/07/2024 03:45 PM
REPORTED ON : 27/07/2024 06:09 PM
REPRINT DATE : 27/07/2024 06:09 PM

Test	Obtained Value	Units	Bio.Ref.Intervals
CLINICAL PATHOLOGY			
Stool Routine			
General Examination (Stool)			
Colour	Brownish yellow		Yellow to Brown
Form & Consistency	Semi solid		Semi solid
Mucus	Absent		Absent
Blood	Absent		Absent
Chemical Examination (Stool)			
pH(pH strip test)	ACIDIC		Variable depending on food
Microscopy (Saline and Iodine mount) (Stool)			
Cyst	Not Present		Absent
Ova	Not Present		Absent
Trophozoites	Not Present		
Red Blood Cells	Not Present	/hpf	Absent
Pus Cells	2-3	/hpf	0-5
Epithelial Cells	Not Present	/hpf	0-4
OTHER	Not present		

-- End of Report --

Dr. Sarangan
Dr Sarangan A MD Pathology

Healing Hearts and Lives

Consultant Pathology
Reg. No : 84981

264/125, Kilpauk Garden Road, Kilpauk, Chennai - 600 010.
Phone : +91 44 4644 8989 / 75500 53335 | Email : muruganhosp@gmail.com
Website : www.muruganhospitals.in



MURUGAN HOSPITALS

HEALING HANDS



LAB REPORT

Patient Name : Mr. V.GOPINATH
Age / Gender : 39-Years / Male
UHID ID : MH20240058714
Doctor Name : Dr. ARUN PRAKASH

OP Report No. : INVA2116061
Bill No. : INV2404453
Sample Date : 27/07/2024 - 09:00 AM
Report Date : 27/07/2024 - 05:18 PM

Test Name	Result	Units	Reference Interval
-----------	--------	-------	--------------------

ENDOCRINOLOGY

T3	1.320	ng/ml	0.52-1.85
T4	6.078	ug/dl	5.0 -13.0 ug/dl
TSH	4.125	uIU/ml	0.39 - 6.16 uiu/ml

KAVIYARASAN

Verified by

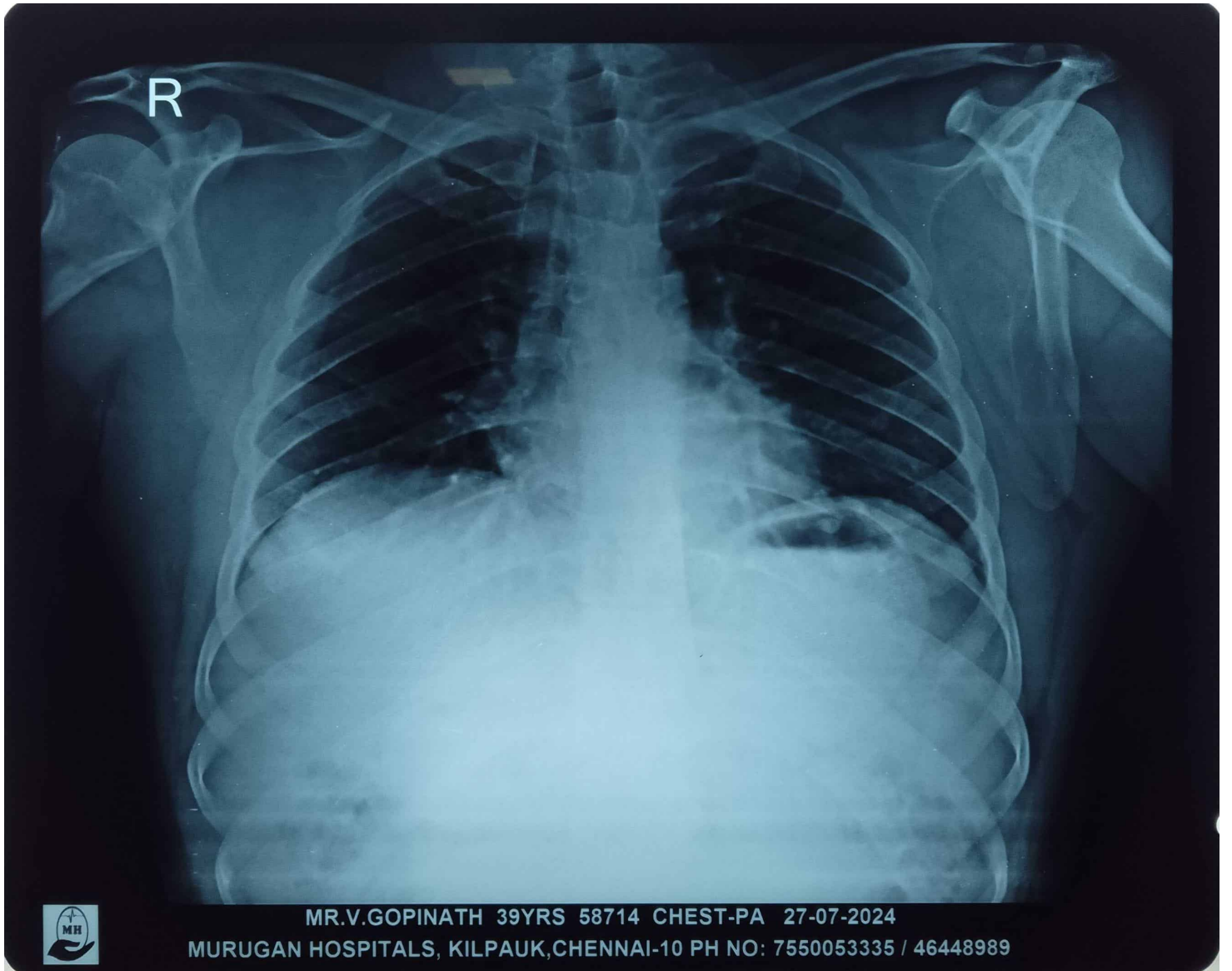
*** End of Report ***

Authorized Signature



MH

Healing Hearts and Lives



R

MR.V.GOPINATH 39YRS 58714 CHEST-PA 27-07-2024

MURUGAN HOSPITALS, KILPAUK, CHENNAI-10 PH NO: 7550053335 / 46448989

