

MYSORE-BALLAL CIRCLE

MEDALL HEALTHCARE PVT LTD

CUSTOMER CHECKLIST



MED112068838

Print Date : 10/02/2024 10:27 AM

Customer Name : **MRS.LEELAVATHI**Ref Dr Name : **MediWheel**Customer Id : **MED112068838** Visit ID : **712404669**Age : **56Y/FEMALE** Phone No : **8892355710**DOB : **10 Feb 1968** Visit Date : **10/02/2024**Company Name : **MediWheel**Package Name : **Mediwheel Full Body Health Checkup Female Above 40**

S.No	Modality	Study	AccessionNo	Time	Signature
1	LAB	BLOOD UREA NITROGEN (BUN)			
2	LAB	GLUCOSE - FASTING			
3	LAB	GLUCOSE - POSTPRANDIAL (2 HRS)			
4	LAB	GLYCOSYLATED HAEMOGLOBIN (HbA1c)			
5	LAB	LIPID PROFILE			
6	LAB	LIVER FUNCTION TEST (LFT)			
7	LAB	URIC ACID			
8	LAB	URINE GLUCOSE - FASTING			
9	LAB	URINE GLUCOSE - POSTPRANDIAL (2 Hrs)			
10	LAB	COMPLETE BLOOD COUNT WITH ESR			
11	LAB	THYROID PROFILE/ TFT(T3, T4, TSH)			
12	LAB	STOOL ANALYSIS - ROUTINE			
13	LAB	URINE ROUTINE			
14	LAB	PAP SMEAR BY LBC (LIQUID BASED CYTOLOGY)			
15	LAB	CREATININE			
16	LAB	BUN/CREATININE RATIO			
17	LAB	BLOOD GROUP & RH TYPE (Forward Reverse)			
18	OTHERS	physical examination	MYS2873291102651		
19	US	ULTRASOUND ABDOMEN	MYS2873291103462		
20	MAMMOGRAPHY	MAMMOGRAPHY-BOTH BREASTS	MYS2873291116678		
21	OTHERS	Treadmill / 2D Echo	MYS2873291127528		
22	OTHERS	Gynecologist consultation	MYS2873291128083		
23	OTHERS	Dental Consultation	MYS2873291134969		
24	OTHERS	EYE CHECKUP	MYS2873291135592		
25	X-RAY	X RAY CHEST	MYS2873291145199		
26	OTHERS	Consultation Physician	MYS2873291148004		
27	ECHO	ELECTROCARDIOGRAM ECG	MYS2873291149333		

Registered By
(ABHISHEK.N)

h - 154 CM
 wt: 54kg
 BP - 130/80mmHg
 DI - Fk6/mt



Customer Name	MRS.LEELAVATHI	Customer ID	MED112068838
Age & Gender	56Y/FEMALE	Visit Date	10/02/2024
Ref Doctor	MediWheel		

ABDOMINO-PELVIC ULTRASONOGRAPHY

LIVER is normal in shape, size and has uniform echopattern.
 No evidence of focal lesion or intrahepatic biliary ductal dilatation.
 Hepatic and portal vein radicals are normal.

GALL BLADDER is partially distended. CBD is of normal calibre.

PANCREAS has normal shape, size and uniform echopattern.
 No evidence of ductal dilatation or calcification.

SPLEEN show normal shape, size and echopattern.
 No demonstrable Para-aortic lymphadenopathy.

KIDNEYS move well with respiration and have normal shape, size and echopattern.
 Cortico- medullary differentiations are well madeout.
 No evidence of calculus or hydronephrosis. *Left renal lower pole cortical cyst measuring 2cms.*

	Bipolar length (cms)	Parenchymal thickness (cms)
Right Kidney	9.0	1.3
Left Kidney	9.2	1.4


URINARY BLADDER is partially distended.

UTERUS & OVARIES are atrophic.
 No evidence of ascites.

IMPRESSION:

➤ **NO SIGNIFICANT ABNORMALITY DETECTED.**

CONSULTANT RADIOLOGISTS



DR. ANITHA ADARSH
 AA/mm

DR. MOHAN B



Ref Doctor	MRS.LEELAVATHI	Customer ID	MED112068838
Age & Gender	56Y/FEMALE	Visit Date	10/02/2024
Ref Doctor	MediWheel		

X-ray mammogram (mediolateral oblique and craniocaudal views) followed by Sonomammography was performed.

BILATERAL MAMMOGRAPHY

Bilateral breasts show symmetrical fibroglandular fatty tissue.

No evidence of focal soft tissue lesion.

No evidence of cluster microcalcification.

Subcutaneous fat deposition is within normal limits.

BILATERAL SONOMAMMOGRAPHY

Both the breasts show normal echopattern.

No evidence of focal solid / cystic areas.

No evidence of ductal dilatation.


No evidence of axillary lymphadenopathy on both sides.

IMPRESSION:

➤ **ESSENTIALLY NORMAL STUDY.**

ASSESSMENT: BI-RADS CATEGORY - 1

1 Negative. Routine mammogram in 1 year recommended.



**DR. ANITHA ADARSH
CONSULTANT RADIOLOGIST**

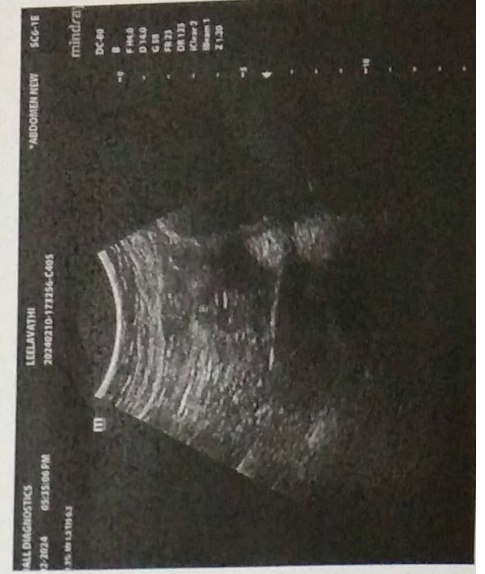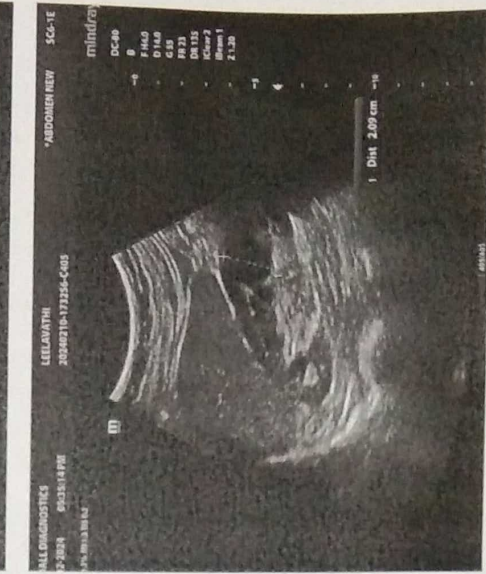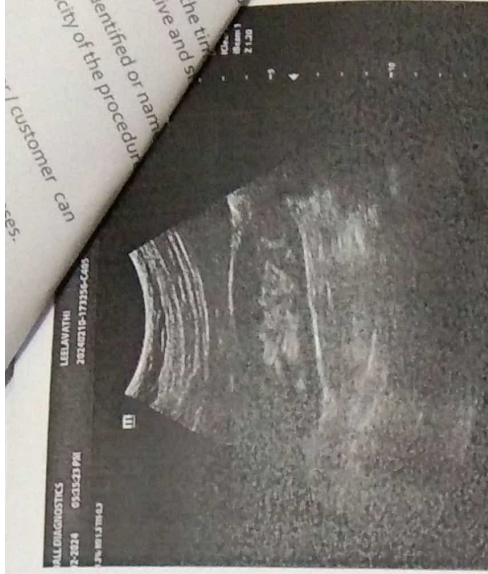
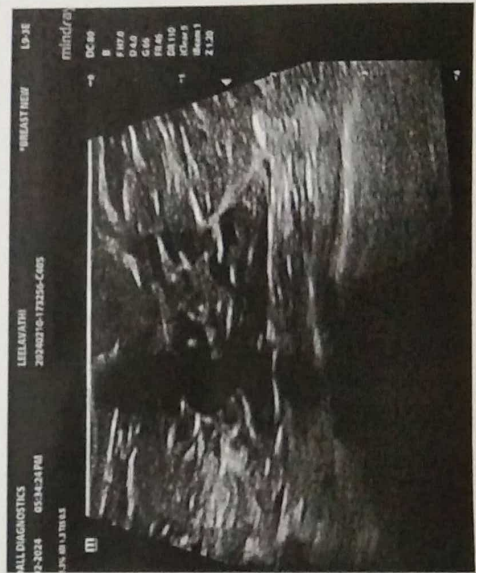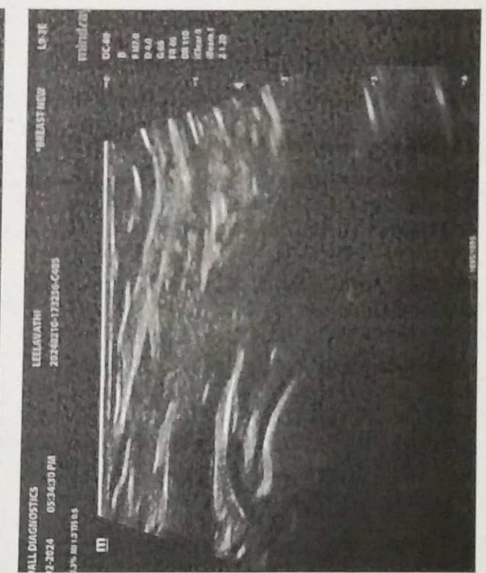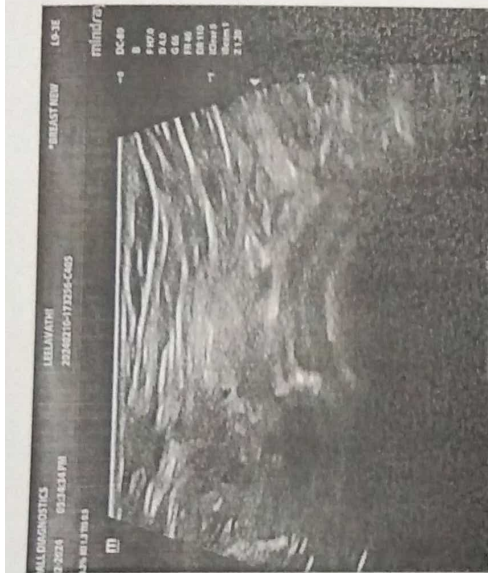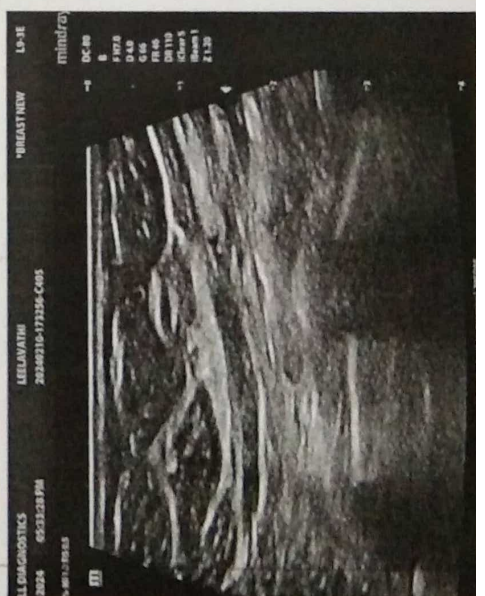
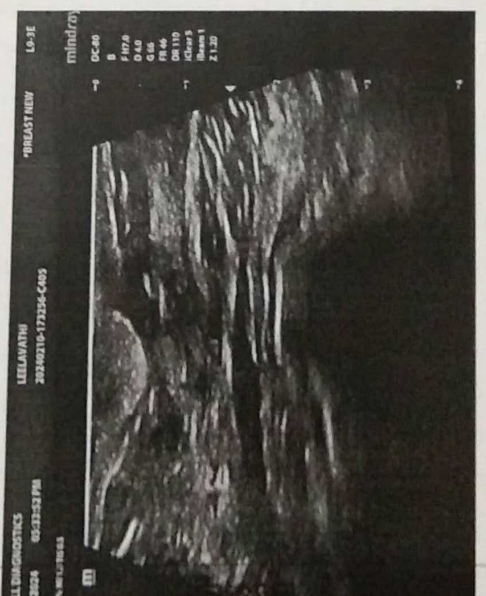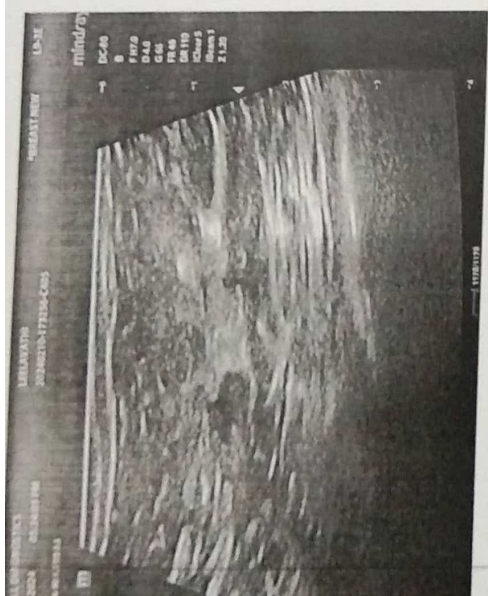AA/mm

You can also conveniently view the reports and trends through our App. Scan QR code to download the App.



Please produce bill copy at the time of collecting the reports. Request you to provide your mobile number customer id during your subsequent visits.

...the patient identified or named...
...representative and...
...condition at the time...
...ive and show...
...ions indic...
...customer can



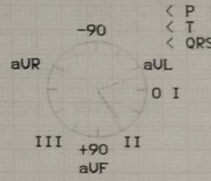
GE MAC1200 ST LEELAUATHI, 112068838, CLUMAX DIAGNOSTICS, MYSORE
Female

HR 74 bpm

AGE: 56

Measurement Results:

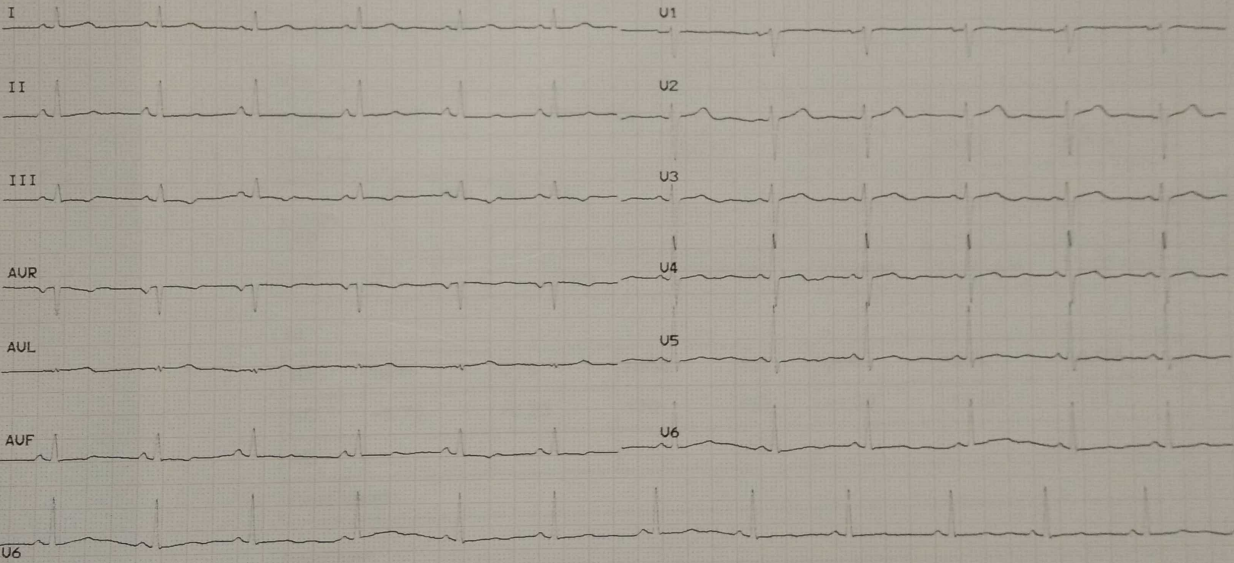
QRS : 90 ms
QT/QTcB : 384 / 429 ms
PR : 124 ms
P : 96 ms
RR/PP : 800 / 800 ms
P/QRS/T : 60 / 55 / -20 degrees
QTd/QTcBD : 72 / 81 ms
Sokolow : 1.7 mV
NK : 10



Interpretation:
normal ECG

Normal sinus rhythm
AB

Unconfirmed report.





NETHRADHAMA SUPER SPECIALITY EYE HOSPITAL

NO 1118 GEETHA ROAD, CHAMARAJAPURAM

MYSORE-570005, KARNATAKA

CASE SHEET

Name: LEELAVATHI . OP No: 6OP1286508 Gender: Female Age: 56 Date : 10/02/2024

Complaint

S.No	Eye	Complaint	Duration	Type	Remarks
2	BE	FOR MEDICAL CERTIFICATE	1	Days	

Diagnosis

Eye	ICDCode	ICD	Version	Remarks
BE	H52.7	Disorder of refraction - H52.7 - 10	10	
BE	25692	REFRACTIVE ERROR - 25692 - 9	9	

SCHIRMER'S Test & TBUT

IOP

Type	NCT			DVT Flag				
Target					DVT1	DVT2	DVT3	DVT4
	BD	AD	CL	RE				
RE	12			LE				
LE	15			Time	12:00 AM	12:00 AM	12:00 AM	12:00 AM

AR

RE	SPH	CYL	AXIS	LE	SPH	CYL	AXIS
BD	+0.75	+0.25	170	BD	+1.00	+0.50	175
AD				AD			

Drug Used:

GlassPower

	SPH	CYL	AXIS	ADD
RE	NB			
LE				

Glass Type:

VisionDetail

RE	UCVA	PG	PH	LE	UCVA	PG	PH
DV	6/18+3			DV	6/12P		
NV	N10			NV	N10		

Subjective

RE	SPH	CYL	AXIS	VA	LE	SPH	CYL	AXIS	VA
Dist	+0.75			6/9+2	Dist	+0.75	+0.50	175	6/9+2
Near	+3.00			N6	Near	+3.00	+0.50	175	N6

Color Vision

Chart Type	1
RE	38/38
LE	38/38
Remarks	WNL

Recommendations

User Name	Recommendations
Dr RICHA .	ANT SEG- BE- CLEAR CORNEA, VH-GRADE 3, LENS- EARLU NS CHANGES FUNDUS- UNDIL- BE- CD-0.3, FR+ ADV- DILATATION DUE

This visit was Electronically Signed by DEEKSHITHA on 2/10/2024 4:02:23 PM.

This visit was Electronically Signed by Dr RICHA . on 2/10/2024 4:33:33 PM.

NETHRADHAMA
Super Speciality Eye Hospital
(A Unit of Netradhama Hospitals Pvt. Ltd.)
No. 1118, Geetha Road, Chamaraajapuram
Mysore-570006 Ph : 0821-4293000

FITNESS CERTIFICATE

NAME: <i>Hee Deenan</i>	AGE: <i>56</i>
Hi: <i>154</i> CMS	Wt: <i>54</i> KGS
	SEX: <i>Female</i>

PARAMETERS	MEASUREMENTS
PULSE / BP (supine)	<i>130/80</i> /mt / /mmHg
INSPIRATION	<i>32</i>
EXPIRATION	<i>32</i>
CHEST CIRCUMFERENCE	<i>33</i>
PREVIOUS ILLNESS	<i>Nil</i>
VISION	
FAMILY HISTORY	FATHER: <i>Nil</i> MOTHER: <i>Nil</i>

REPORTS: *Normal Fit*

DATE: *10/2/24*

PLACE: *Mysor*

Hee Deenan

CONSULTANT PHYSICIAN

Dr. NIKHIL. B.

M.D., D.M.(Cardiologist)
Interventional Cardiologist
KMC Reg. No.: 90111