

भारत सरकार





सुनील कुमार  
**Sunil Kumar**  
 जन्म तिथि / DOB : 11/12/1990  
 पुरुष / MALE



**4497 5288 8153**  
 VID : 9131 3978 3109 1678

**मेरा आधार, मेरी पहचान**

*Sunil Kumar*

*Abhi In*

भारतीय विधिद्वारा पहचान प्रामाणिकरण  
 AUTHENTICATED BY LAW ENFORCEMENT AGENCIES IN INDIA

पता:  
 S/O: हंसराज, गानव-जट बहरोर  
 जट, अलवर,  
 राजस्थान - 301714

**Address:**  
 S/O: Hansraj, ganv-jat  
 mundawar, Behror jat,  
 Rajasthan - 301714

**Address**  
 S/O: Hansraj tehsi-  
 mundawar ganv-jat behror  
 Behror Jat Behror Jat Alwar  
 Rajasthan - 301714

1847

1800 300 1847    help@citst.gov.in    www.citst.gov.in    P.O. Box No. 1847, Bangalore-560 001



# THAREJA NURSING HOME



DIGITAL X-RAY, OPG, COMPUTERISED ECG & EEG, DIAGNOSTIC  
LABORATORY EQUIPED WITH COMPUTERISED AUTO ANALYZER & CBC

1, Ram Kuteer, Company Bagh Road, ALWAR - 301001 (Raj.) Ph: 0144-2700184, 2331842

PROPOSAL NO. PKG10000227  
Patient Name **SUNIL KUMAR**  
Ref. By Dr. **M. N. THAREJA**

Date **02/10/2021**  
Age **30 Yrs.**  
Sex **M**

Details of packages		Patients report	Units	Normal value
	HB	14.4	gm%	M-11.5-18
	TRBC	5.42	million /cu mm	M-4.0-5.5, F-3.9-5.6
	TWBC	7900	cu mm	4000-11000
DLC	Polymorphs	55	%	42-75
	Lymphocytes	40	%	20-50
	Eosinophil	05	%	1-6
	ESR	02	mm 1 <sup>st</sup> Hr.	M-0-9, F-0-20
	Platelets	231000	Lack / cu mm	1.5-4
	PCV	43.5	%	37-54
	MCV	73.0	Cubicmicrons	86-96
	MCH	24.5	Picograms	26-34
	MCHC	33.6	%	32-36
Blood Grouping & Rh Factor		"AB"Rh+Ve(Positive)		
	Blood BUN	13.0	Mg%	7-21
	S.Creatinine	0.87	Mg/100ml	0.9-1.4 mg /100 ml
	VDRL	-		
	HIV I & II	-	Elisa Method	
	HbA1C	4.8	%	4-6%
	PSA	-	Ng/ml	Less Than 4.0 Ng/ml

Details of packages		Patients report	Units	Normal value	
LFT	GGTP	25	U/L	5-60	
	SGOT	15	Units / ml	Upto 40	
	SGPT	24	Units / ml	Upto 40	
	Total	0.51	mg%	Upto 1.2	
	S. Bilirubin	Direct	0.27	mg%	0-0.25
		Indirect	0.24	mg%	
	T. Protein	7.78	Gm%	6.2-8.3	
	S. Albumin	4.50	Gm%	3.2-5.3	
	Globulin	3.28	Gm%		
	Alkaline phosphate	135	IU/L	60 - 170	
	S. Calcium	-	Gm%	8.5-10.5	
	Uric Acid	-	Mg%	2.5-7 mg%	
	Blood Sugar Fasting	83	Mg%	60-110 mg %	
Blood Sugar PP	105	Mg%	Upto 160		
Lipid Profile	S. Cholesterol	189	mg%	120-220	
	S. Triglycerides	130	mg/ml	Upto 170	
	HDL Cholesterol	58	IU/L		
	LDL cholesterol	105	IU/L	450 at 37° C	
VLDL	26	mg %	Upto 35		

### Routine Urine Analysis

Physical/ Chemical		Microscopic:	
Appearance	Clear	RBCs	Nil
Specific Gravity	1010	WBCs	1-2/HPF
Ph	ACIDIC	Epith. Cells	2-3/HPF
Albumin	Nil	Casts	Nil
Glucose	Nil	Crystals	Nil
Ketones	----	Bacteria	Nil
Blood	Nil	PP Glucose	Nil

Signature of Technician

Signature of Doctor

This Report is not Valid for Medical Legal Purpose



# THAREJA NURSING HOME



DIGITAL X-RAY, OPG, COMPUTERISED ECG & EEG, DIAGNOSTIC  
LABORATORY EQUIPED WITH COMPUTERISED AUTO ANALYZER & CBC

1, Ram Kuteer, Company Bagh Road, ALWAR - 301001 (Raj.) Ph: 0144-2700184, 2331842

PROPOSAL NO.	PKG10000227	Date	06/11/2021
Patient Name	SUNIL KUMAR	Age	30 Yrs.
Ref. By Dr.	M. N. THAREJA	Sex	M

**PART - X-RAYED :** X-RAY CHEST PA VIEW  
**REPORT :** X-RAY CHEST P.A. VIEW  
:- Chest is bilaterally symmetrical.  
:- C.P. Angles are clear.

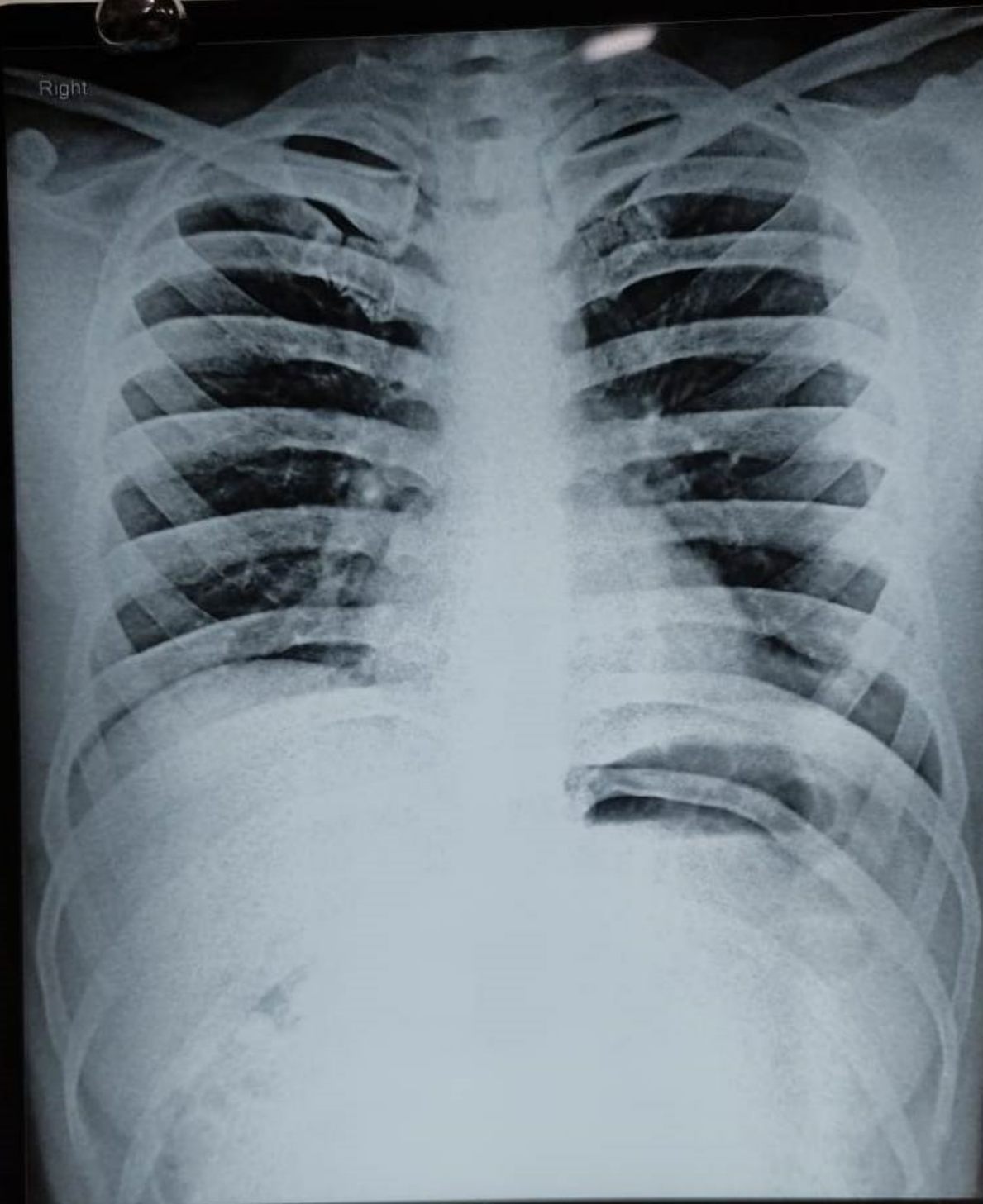
**CONCLUSION: Normal Study**

*Signature of Technician*

*Signature of Doctor*

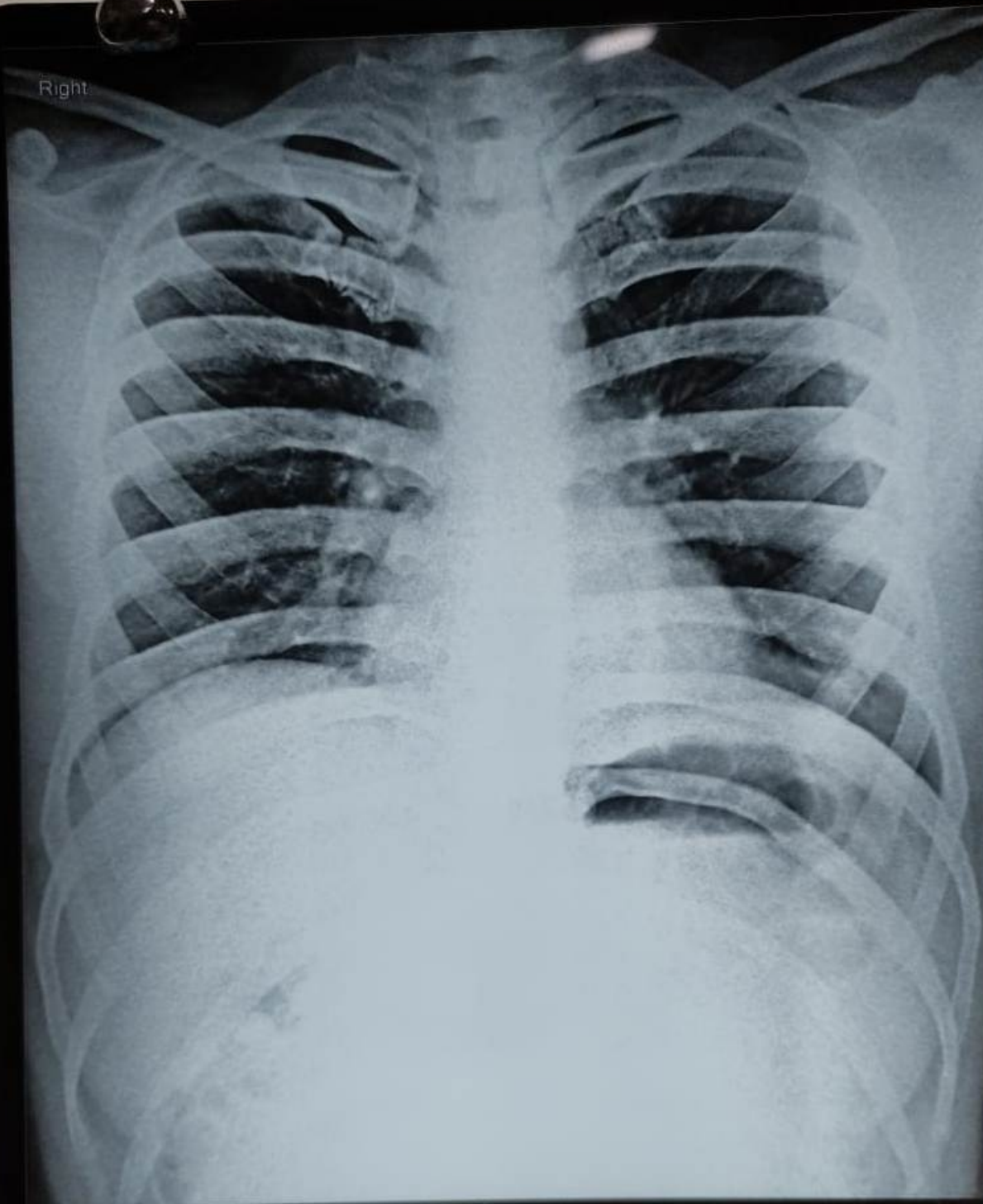
*This Report is not Valid for Medical Legal Purpose*

Right



SUNIL KUMAR 30 Y BY DR M.N. THAREJA 5754.21.1 M CHEST, PA 11/6/2021  
THAREJA NURSING HOME, COMPANY BAGH ROAD, ALWAR

Right



SUNIL KUMAR 30 Y BY DR M.N. THAREJA 5754.21.1 M CHEST, PA 11/6/2021  
THAREJA NURSING HOME, COMPANY BAGH ROAD, ALWAR

Patient Name:

Sunil Kumar

Age: 36 M / F

Weight: kg

Height: cm

HR 65/min

PR 132 ms

QR 132 ms

QT 374 ms

QTc 394 ms

P 39°

QRS 35°

T 21°

P (II) 0.12 mV

S (VI) -1.14 mV

R (V5) 1.44 mV

Sokol 3.55 mV

SINUS RHYTHM

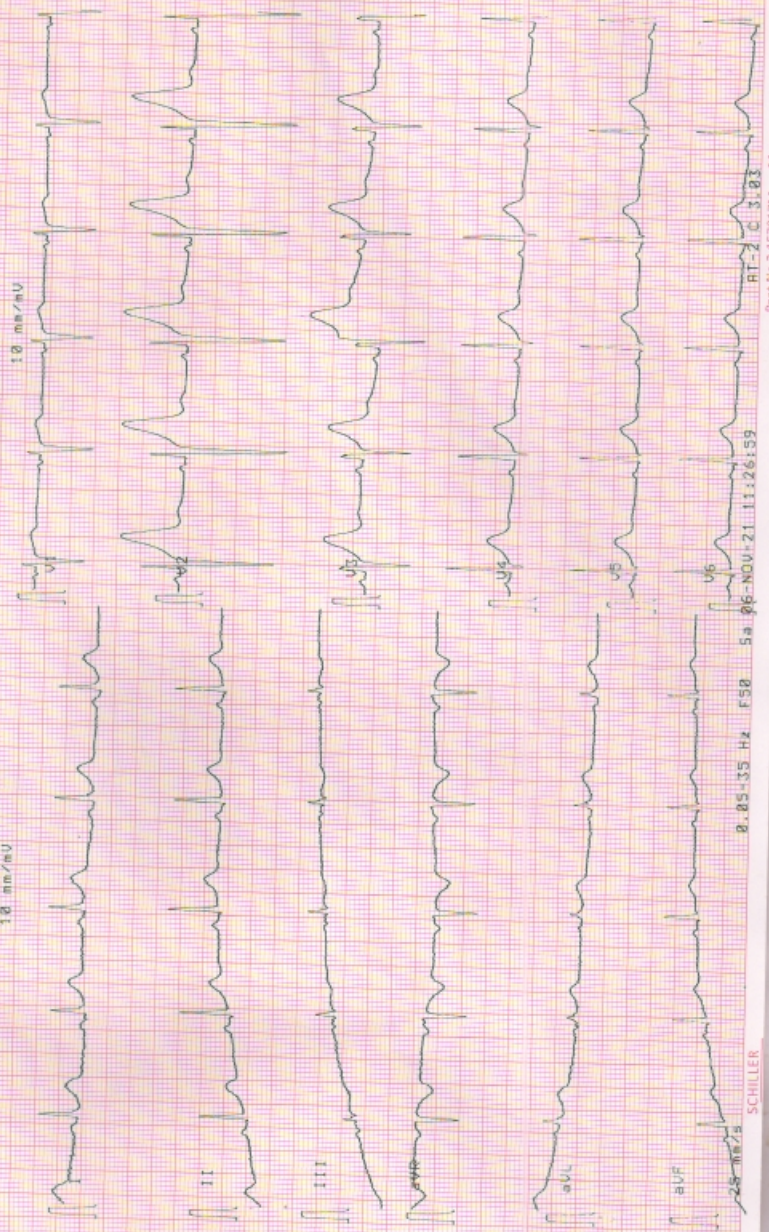
OTHERWISE NORMAL ECG

5.70

UNCONFIRMED REPORT

*Just handw*

10 mm/mV



2.85-3.5 Hz F50 Sa 96-NOV-21 11:26:59

SCHILLER

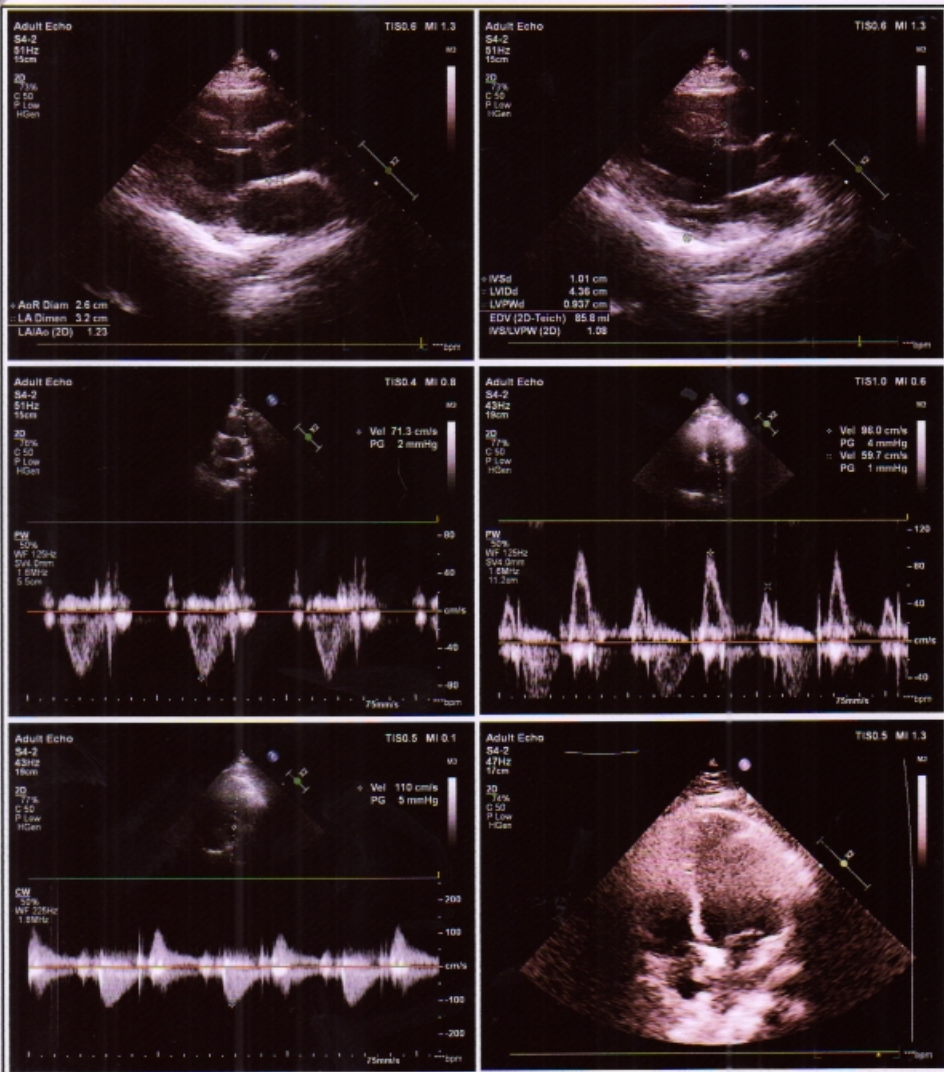
25 mm/s

RT: C 123

Pap: No. 2.15701760

516

Images





# GUPTA ENT AND HEART CENTRE

Dayanand Marg, Nangli Circle, Alwar (Raj.) Ph. 0144-3591336 | M. 7378184427

## Echocardiography Report

Name : Mr. Sunil  
Age / Sex : 31yrs./male

Refd by: Dr. M.N. Thareja  
Date : 6 November 2021

**Clinical Diagnosis :** For Cardiac Evaluation  
**2D Echocardiography Findings**  
Mitral Valve : Normal  
Aortic Valve : Normal  
Tricuspid Valve : Normal  
Pulmonary Valve : Normal  
Left Atrium : 3.2cm: Normal  
Left Ventricle : Normal LV size with normal LV systolic function. No RWMA

LVIDd	4.3cm.	IVSd	1.0cm.	EF	60%	Visual
LVIDs	2.4cm.	PWd	0.9cm.	EF	%	F.S.

Right Atrium : Normal  
Right Ventricle : Normal  
Aorta : 2.6cm: Normal  
Pulmonary Artery : Normal  
Pulmonary Veins : Normal  
Superior Venacava : Normal  
Inferior Venacava : Normal  
Pericardium : Normal  
Intracardiac Masses : No Intracardiac masses seen  
IAS/IVS : Intact

### Doppler Findings:

Valve	Peak Velocity (cm/s)	Peak Gradient (mmHg)	Mean Gradient (mmHg)	Regurgitation Grade	others/comments
Mitral Valve	E-/A-96/59			No MR	
Aortic Valve	110				
Tricuspid Valve				No TR, No PAH.	
Pulmonary Valve	71				

**Diagnosis :** Transthoracic echo done in supine position at resting heart rate of 70bpm, shows **Normal LV size with normal LV systolic function. LVEF~60% (Visual). No RWMA.**  
Other cardiac chambers are normal in Size.  
No MR, No TR, No PAH.  
Normal MIP.  
No pericardial effusion /Vegetation /Clot Intracardiac masses seen.  
Normal left sided arch of aorta, No Coarctation.

Dr. Prachi Gupta  
MBBS, PGDCC  
(Non-invasive cardiologist)





# THAREJA NURSING HOME

1, Ram Kuteer Company Bagh Road, ALWAR - 301001 (Raj.)  
Mob. 9982111801, Ph. 0144-2700184, 2331842, Telefax: 0144-2342339  
E-mail: drmnthareja@yahoo.com



Name Mr. Sunil Kumar Age 31 Yr M OPD/UHID Date 6/11/21  
Address ..... Mobile No. ....

VITALS	B.P.	Pulse	Temp.	Wt.	Ht.	Allergies
--------	------	-------	-------	-----	-----	-----------

### Complaints

Routine eye checkup

### Findings

VA - 6/6 e glasses  
- 6/6

Investigation N6 N6

GL  
Cornea clear B/E

Color vision - WNL  
- WNL

### Treatment

Adv:

Both eyes within normal limit  
e glasses

**DR. M.N. THAREJA**  
7233 (RMC)  
Family Physician

**DR. SAVITA THAREJA**  
7600 (RMC)  
Infertility Specialist

**DR. JAYANT THAREJA**  
A-0824 (RSDS)  
Ex. Sr AIIMS

**DR. SHIVANI THAREJA**  
10807 / 31220 (RMC)  
Ophthalmologist

**DR. PRERNA THAREJA**  
A-3574  
MDS (Endodontics)  
Ex. Sr AIIMS

**DR. H.R. GUPTA**  
1744 (RMC)  
Sr. Surgeon, MS. Gen.

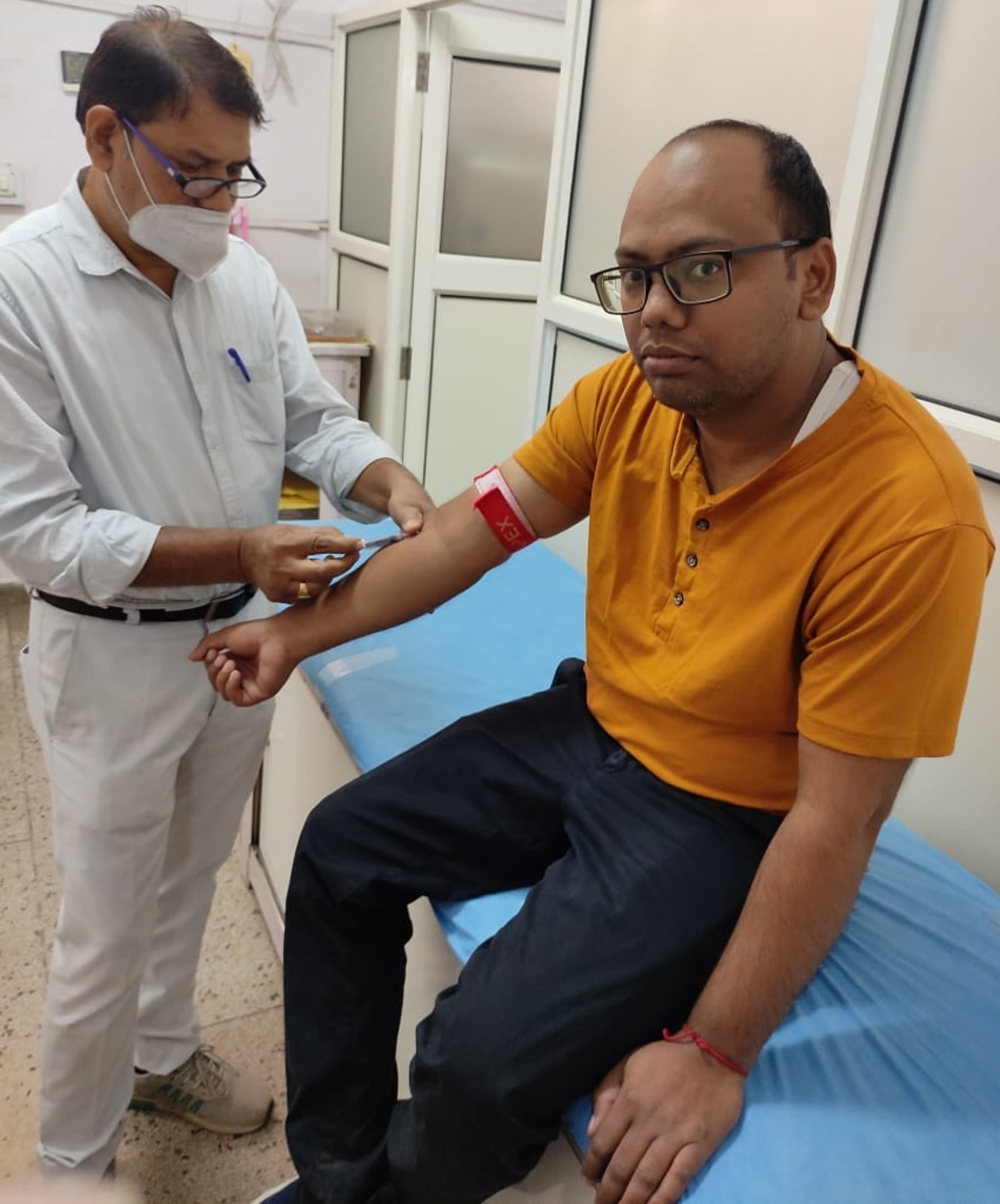**DR. VARUN SAPRA**  
Reg. No. 70990  
DNB, Ortho

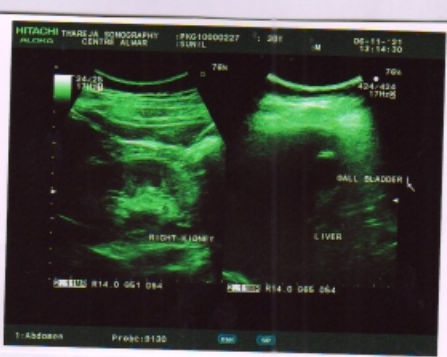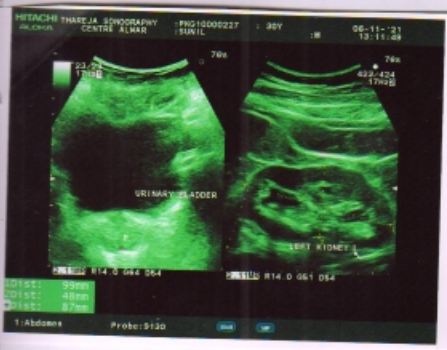Shivani  
Dr. Shivani Thareja  
M.S. (OPHTHAL)  
Fellow (CORNEA)  
L.V. Prasad Eye Institute,  
CORNEA CONSULTANT

**Pain Scale**

0	2	4	8	10
No Pain	Mild Pain	Distressing	Disressing	Intense
				Excruciating

SAMPLE  
LECTION  
ROOM  
नेमरान कम्







# THAREJA SONOGRAPHY CENTRE



1, Ram Kuteer, Company Bagh Road, ALWAR - ☎ (0144) 2700184

This report is not valid for MLC Purpose

Ref. No.

Date 06/11/2021

Name of Patient: MR. SUNIL KUMAR

Age : 30 Yrs. Sex: M

Ref by : DR. M. N. THAREJA

## Sonography Report – abdomen

LIVER:	Size: RL: 13.6 cm	L. L.: 5.2 Cm.
	Margins: Regular	I.H.B.R: ND
	Parenchyma : Echo	
C. B. D.	Size: 3.2 mm	LUMEN: Clear
P.V.	Size: mm	LUMEN: Clear
GALL BLADDER :	Size : 4.0X 1.8 cm	
Wall thickness	N	Lumen : Clear
PANCREAS:	N	
SPLEEN:	8.8 cc	
KIDNEYS:	Right: 9.6 X 4.0 cm	Left: 9.9 X 4.7 cm

PELVICALYCAL SYSTEM: |  
CORTICO – MEDU. DIFF: | N

RETROPERITONEUM : |  
LYMPH – NODES : | Not Seen

PLEURAL EFFUSION : |  
ASCITES

URINARY BLADDER:  
Prevoiding Volume 210 cc  
Wall Thickness N


Residual Urine C.C.  
Lumen: Clear

PROSTATE: N  
Size: N  
Parenchyma: Echotexture

Capsule: Intact

SEMINAL – VASICLES: Normal

**Conclusion:- Normal Study**

  
Dr. Savita Thareja  
Reg. No. 7600  
Rajasthan Medical Council

Enclosed: Photo - 3

PLEASE NOTE: INTESTINAL PATHOLOGY CAN NOT BE RULE OUT

This is only an opinion, not a diagnosis, which should be clinically co-related. No procedure/surgery should be undertaken simply on the basis of this opinion because Ultrasound accuracy is only 96%.

\* Subject to Alwar jurisdiction. \* Not valid for medico-legal purpose.



# THAREJA NURSING HOME



DIGITAL X-RAY, OPG, COMPUTERISED ECG & EEG, DIAGNOSTIC  
LABORATORY EQUIPED WITH COMPUTERISED AUTO ANALYZER & CBC

1, Ram Kuteer, Company Bagh Road, ALWAR - 301001 (Raj.) Ph: 0144-2700184, 2331842

Name : **SUNIL KUMAR** age **30** Sex : **MALE**  
Ref. By : **DR M.N. THAREJA** Lab No. : Date : **November 6, 2021**

## HORMONES & MARKERS

<u>Test</u>	<u>Value</u>	<u>Units</u>	<u>Biological Ref. Values</u>
T3 (Total Triiodothyronine)	1.13	ng/dL	0.60-1.81 ng/dL Adults
T4 (Total Thyroxine)	5.79	µg/dL	3.2-12.60 µg/dL : Adults
TSH (Thyroid Stimulating Hormone)	2.27	µIU/mL	Adults : 0.35-5.50 µIU/mL

### Interpretation of TSH :-

#### Children

0 Days : 1.0-39.0 uIU/mL  
5 days : 1.7-9.1 uIU/mL  
1 year : 0.4-8.6 uIU/mL  
2 years : 0.4-7.6 uIU/mL  
3 years : 0.3-6.7 uIU/mL  
4-19 years : 0.4-6.2 uIU/mL

### Interpretation of TSH :-

#### Children

3.20 - 34.6 µIU/mL 1- 2 Days  
0.70 - 15.4 µIU/mL 3 - 4 Days  
0.70 - 9.10 µIU/mL 15 Days - 5 Months  
0.70 - 6.40 µIU/mL 5 Months - 20 Years

#### Adults

20-54 years : 0.35-5.50 uIU/mL  
55-87 years : 0.5-8.9 uIU/mL

#### Pregnancy

1st Trimester : 0.30 - 4.50 µIU/mL  
2nd Trimester : 0.50 - 4.60 µIU/mL  
3rd Trimester : 0.80 - 5.20 µIU/mL

#### Pregnancy

0.30 - 4.50 µIU/mL 1st Trimester  
0.50 - 4.60 µIU/mL 2nd Trimester  
0.80 - 5.20 µIU/mL 3rd Trimester

Method : **Fluorescence Immunoassay Technology**

Sample Type : **Fresh Blood Serum**

### Remarks :

Primary malfunction of the Thyroid gland may result in excessive (hyper) or Low (hypo) release of T3 or T4. In addition, as TSH directly affect thyroid function, malfunction of the pituitary or the hypothalamus influences the thyroid gland activity.

Disease in any portion of the thyroid-pituitary-hypothalamus system may influence the level of T3 and T4 in the blood, in Primary Hypothyroidism,

TSH levels are significantly elevated, while in secondary and tertiary hypothyroidism, TSH levels may be low. In addition, in Euthyroid sick syndrome, multiple alterations in serum thyroid function test findings have been recognized.

Signature of Technician

Signature of Doctor

This Report is not Valid for Medical Legal Purpose