

Facilities:

All Clinical Biomedical & Hematology Investigations including Bone Marrow Examination
 VPT, Podiascan & Complete Foot Care (First Time in Purvanchal)
 All Hormonal Investigation by Chemiluminescent Method
 Visceral Fat by (AB-140) Ambulatory BP Monitoring
 CGMS & Insulin Pump Available
 PFT, 2D-ECHO (Color Doppler), Holter, TMT, Cardiac-3 available
 VIA, VILI, Colposcopy available
 Special Endocrinological Investigation Protocols.

ISO 9001:2008 Certified
 Mobile: 9389994334, 9554572190, 9453837595



Panacea Pathology

Clinical Reference Lab

Persistence, Preparedness and Precision
 EQAS (CMC Vellore Attached) & IQAS System
 पूर्वांचल की सर्वोत्तम गुणवत्ता वाली पैथोलॉजी

PATIENT NAME : VIVEK KUMAR	AGE/GENDER : 37 YRS/MALE
REFD BY DR. : ARCO FEMI HEALTHCARE LTD.	RECEIVED DATE : 12-11-2022 (11:15 AM)
SAMPLE : BLOOD & URINE	REPORT DATE : 12-11-2022 (07:15 PM)

PATHOLOGY REPORT

COMPLETE BLOOD COUNT (CBC)

TEST	LAB TEST VALUES	NORMAL RANGE
HEMOGRAM		
HEMOGLOBIN (FLOW CYTOMETRY)	14.2	13 – 16 gm/dl
TOTAL LEUCOCYTE COUNT (TLC)	8,300	4000 – 11000
RBC COUNT	4.85	3.5 – 5.5
PCV (HCT)	38.2	37 – 47
MCV	87.3	80 – 95
MCH	28.1	28 – 34
MCHC	32.2	30 – 36
PLATELET COUNT	1,54,000	1,50,000 – 4,00,000
E.S.R. (WINTROBE FIRST HOURS)	8.0	20 mm/1 st hr
DIFFERENTIAL LEUCOCYTE		
NEUTROPHILS	60	40 – 75%
LYMPHOCYTES	30	20 – 45%
EOSINOPHILS	05	1 – 6%
MONOCYTES	05	2 – 8%
BASOPHILS	00	< 2 %

RENAL & KIDNEY PROFILE, SERUM

TEST	LAB TEST VALUES	NORMAL RANGE
RENAL FUNCTION TESTS		
BLOOD UREA NITROGEN (BUN)	11.2	10 – 50 mg/dl
SERUM CREATININE	0.62	0.60 – 1.60 mg/dl
URIC ACID	4.16	3.60 – 7.70 mg/dl
ALKALINE PHOSPHATASE (ALP)	110.0	142 – 353 mg/dl
TOTAL PROTIENS	7.25	0 – 39 mg/dl
ALBUMIN	4.00	3.8 – 5.4 mg/dl
SERUM GLOBULIN	3.25	2.1 – 3.5 mg/dl
CALCIUM	9.8	8.80 – 10.20
PHOSPHORUS	3.92	2.50 – 5.00
SERUM SODIUM NA+	139.8	135.00 – 155.00 mEq/Ltr
SERUM POTASIUM K+	4.28	3.60 – 5.50 mEq/Ltr
ICALCIUM	1.25	1.10 – 1.35 mmol/L
SERUM CHLORIDE CL+	103.3	98.00 – 110.00 mEq/Ltr

PAGE 1

Lab Technician

PANACEA HOSPITAL
 UNIT OF AAROHA HEALTH CARE PVT. LTD.)
 REG. NO. AL-1500
 B.36/44, B-4, KABIR NAGAR
 DURGAKUND, VARANASI

Timing : 8.00 a.m. to 9.00 p.m. (Sunday 8.00 a.m. to 3.00 p.m.)

This Report is not valid for medico legal purpose

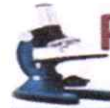Note: These tests have technical limitations. Clinico-pathological interpretation is necessary. In case of any disparity test may be repeated immediately.

Address : 36/44 FK Kabir Nagar, Durgakund, Varanasi – 221005

Email: dramishra@gmail.com, drpallaviojha@gmail.com Website: panaceahospital.org

Clinical Biomedical & Hematology Investigations
 Bone Marrow Examination
 T, Podiascan & Complete Foot Care (First Time in Purvanchal)
 All Hormonal Investigation by Chemiluminescent Method
 Visceral Fat by (AB-140) Ambulatory BP Monitoring
 CGMS & Insulin Pump Available
 PFT, 2D-ECHO (Color Doppler), Holter, TMT, Cardiac-3 available
 VIA, VILI, Colposcopy available
 Special Endocrinological Investigation Protocols.

ISO 9001:2008 Certified
 Mobile: 9389994334, 9554572190, 9453837595



Panacea Pathology

Clinical Reference Lab

Persistence, Preparedness and Precision
 EQAS (CMC Vellore Attached) & IQAS System
 पूर्वांचल की सर्वोत्तम गुणवत्ता वाली पैथोलॉजी

PATIENT NAME : VIVEK KUMAR

AGE/GENDER : 37 YRS/MALE

REFD BY DR. : ARCO FEMI HEALTHCARE LTD.

RECEIVED DATE : 12-11-2022 (11:15 AM)

SAMPLE : BLOOD & URINE

REPORT DATE : 12-11-2022 (07:15 PM)

PATHOLOGY REPORT

LIPID PROFILE, SERUM

TEST	LAB TEST VALUES	NORMAL RANGE
BLOOD CHEMISTRY		
TOTAL CHOLESTEROL (SERUM)	148.0	Desirable:- < 200 mg/dl Borderline:- 200 – 239 mg/dl High:- > 240 mg/dl
TRIGLYCERIDES (SERUM)	132.0	35 – 170 mg/dl
HDL CHOLESTEROL (SERUM)	38.0	35.30 – 79.50 mg/dl
LDL CHOLESTEROL (SERUM)	89.4	< 130 mg/dl
VLDL	28.40	< 40 mg/dl
NON HDL	72.0	0.00 – 100.00 mg/dl
CHOLESTROL/HDL RATIO	4.10	< 3.0 Low Risk Ratio 3.0 – 5.0 Avg Risk > 5.0 High Risk
LDL/HDL RATIO	2.34	< 3 Ratio

ESR

TEST	LAB TEST VALUES
BLOOD GROUP ABO & RH FACTOR	
BLOOD GROUP	"B"
RH FACTOR	POSITIVE

GLYCOSYLATED HEMOGLOBIN (HBA1C)

TEST	LAB TEST VALUES	NORMAL RANGE
HBA1C	5.2	Normal : <5.97 % Good Control : 5.97 – 6.81% Fair Control : 6.81 – 7.65% Poor Control : >7.65%

THYROID PROFILE (T3, T4, TSH)

TEST	LAB TEST VALUES	NORMAL RANGE
THYROID FUNCTION TEST		
T3	1.21	0.60 – 1.81 ng/ml
T4	6.25	4.50 – 10.90 ug/dl
TSH	3.15	0.39 – 6.10 uIU/mL

PAGE 2

Lab Technician

PANACEA HOSPITAL
 A UNIT OF AAROHA HEALTH CARE PVT. LTD.
 REG. NO.: AL 1500
 B.36/44, B-4, KABIR NAGAR
 DURGAKUND, VARANASI
 M.D., Pathology

Timing : 8.00 a.m. to 9.00 p.m. (Sunday 8.00 a.m. to 3.00 p.m.)

This Report is not valid for medico legal purpose

Note: These tests have technical limitations. Clinico-pathological interpretation is necessary. In case of any disparity test may be repeated immediately.

Address : 36/44 FK Kabir Nagar, Durgakund, Varanasi – 221005

Email: dramishra@gmail.com, drpallaviojha@gmail.com Website: panaceahospital.org

Medical Biomedical & Hematology Investigations
 Imaging Bone Marrow Examination
 Podiatry, Podiascan & Complete Foot Care (First Time in Purvanchal)
 Hormonal Investigation by Chemiluminescent Method
 Visceral Fat by (AB-140) Ambulatory BP Monitoring
 CGMS & Insulin Pump Available
 PFT, 2D-ECHO (Color Doppler), Holter, TMT, Cardiac-3 available
 VIA, VILI, Colposcopy available
 Special Endocrinological Investigation Protocols.



Panacea Pathology

Clinical Reference Lab

Persistence, Preparedness and Precision
 EQAS (CMC Vellore Attached) & IQAS System
 पूर्वांचल की सर्वोत्तम गुणवत्ता वाली पैथोलॉजी

PATIENT NAME : VIVEK KUMAR

AGE/GENDER : 37 YRS/MALE

REFD BY DR. : ARCO FEMI HEALTHCARE LTD.

RECEIVED DATE : 12-11-2022 (11:15 AM)

SAMPLE : BLOOD & URINE

REPORT DATE : 12-11-2022 (07:15 PM)

PATHOLOGY REPORT

LIVER PROFILE TEST, SERUM

TEST	LAB TEST VALUES	NORMAL RANGE
BIO CHEMISTRY		
TOTAL BILIRUBIN	0.68	0.0 – 1.1 mg/dl
DIRECT BILIRUBIN	0.21	0.0 – 0.2 mg/dl
INDIRECT BILIRUBIN	0.48	< 0.90 mg/dl
SGOT (AST)	26.6	0 – 52 mg/dl
SGPT (ALT)	30.2	0 – 39 mg/dl
GGT (GYT)	23.0	< 55 U/L
AG RATIO	1.96	-

URINE ROUTINE EXAMINATION

TEST	LAB TEST VALUES	NORMAL RANGE
PHYSICAL EXAMINATION		
QUANTITY	30	ML
COLOUR	STRAW	PALE YELLOW
APPEARANCE	CLEAR	CLEAR
SPECIFIC GRAVITY	1.015	1.01 – 1.03
PH	6.0	4.7 – 7.5
CHEMICAL EXAMINATION		
GLUCOSE	Not Detected	Not Detected
PROTEIN	NIL	Not Detected
MICROSCOPIC EXAMINATION		
PUS CELLS	1-2	0-5
RBC	Not Detected	Not Detected
EPITHELIAL CELLS	1-2	0-5
CASTS	Not Detected	Not Detected
CRYSTALS	Not Detected	Not Detected
BACTERIA	Not Detected	Not Detected

PAGE 3

Lab Technician

PANACEA HOSPITAL
 UNIT OF AAROA HEALTH CARE PVT. LTD.,
 REG. NO.: AL 1500
 B.36/44, B-4, KABIR NAGAR
 DURGAKUND, VARANASI
 M.D., Pathology

Timing : 8.00 a.m. to 9.00 p.m. (Sunday 8.00 a.m. to 3.00 p.m.)

This Report is not valid for medico legal purpose

Note: These tests have technical limitations. Clinico-pathological interpretation is necessary. In case of any disparity test may be repeated immediately.

Address : 36/44 FK Kabir Nagar, Durgakund, Varanasi – 221005

Email: dramishra@gmail.com, drpallaviojha@gmail.com Website: panaceahospital.org

es:
Medical Biomedical & Hematology Investigations
Including Bone Marrow Examination
T, Podiascan & Complete Foot Care (First Time in Purvanchal)
All Hormonal Investigation by Chemiluminescent Method
Visceral Fat by (AB-140) Ambulatory BP Monitoring
CGMS & Insulin Pump Available
PFT, 2D-ECHO (Color Doppler), Holter, TMT, Cardiac-3 available
VIA, VILI, Colposcopy available
Special Endocrinological Investigation Protocols.

ISO 9001:2008 Certified
Mobile: 9389994334, 9554572190, 9453837595



Panacea Pathology Clinical Reference Lab

Persistence, Preparedness and Precision
EQAS (CMC Vellore Attached) & IQAS System
पूर्वाचल की सर्वोत्तम गुणवत्ता वाली पैथोलॉजी

PATIENT NAME : VIVEK KUMAR	AGE/GENDER : 37 YRS/MALE
REFD BY DR. : ARCO FEMI HEALTHCARE LTD.	RECEIVED DATE : 12-11-2022 (11:15 AM)
SAMPLE : BLOOD & URINE	REPORT DATE : 12-11-2022 (07:15 PM)

FASTING/RANDOM BLOOD SUGER

TEST	LAB TEST VALUES	NORMAL RANGE
FBS/RBS		
FASTING BLOOD SUGER	118.0	110-125 mg/dl
RANDOM BLOOD SUGER	157.0	125-140 mg/dl

----- End of Report -----

P. Jha
PANACEA HOSPITAL
UNIT OF AAROHA HEALTH CARE PVT. LTD.
REG. NO.: AL-1500
B.36/44, B-4, KABIR NAGAR
DURGAKUND, VARANASI

Lab Technician

M.D., Pathology

Timing : 8.00 a.m. to 9.00 p.m. (Sunday 8.00 a.m. to 3.00 p.m.)

This Report is not valid for medico legal purpose

Note: These tests have technical limitations. Clinico-pathological interpretation is necessary. In case of any disparity test may be repeated immediately.

Address : 36/44 FK Kabir Nagar, Durgakund, Varanasi – 221005

Email: dramishra@gmail.com, drpallaviojha@gmail.com Website: panaceahospital.org



भारतीय विशिष्ट पहचान प्राधिकरण
UNIQUE IDENTIFICATION AUTHORITY OF INDIA

पता:

S/O: श्री उग्रा नारायण
प्रसाद, एच न 25/5 डी.,
विजय नगर कॉलोनी
चतुर्भुजपुर, छिंदे, मुगलसराय,
मुगलसराय, चंदौली,
उत्तर प्रदेश - 232101

Address:

S/O: Sri Ugra Narayan Prasad, H
NO 25/5 D., vijay nagar colony
chaturbhujpur, chire, mughalsarai,
Mugalsarai, Chandauli,
Uttar Pradesh - 232101

4606 7155 3209

Aadhaar-Aam Admi ka Adhikar



GPS Map Camera



Google

Varanasi, Uttar Pradesh, India

B36/44BA-4, Durgakund, Bhelupur,


Varanasi, Uttar Pradesh 221001, India

Lat 25.28915°

Long 82.993315°

12/11/22 11:07 AM GMT +05:30



 GPS Map Camera



Varanasi, Uttar Pradesh, India

B36/44BA-4, Durgakund, Bhelupur,

Varanasi, Uttar Pradesh 221001, India

Lat 25.28915°

Long 82.993315°

12/11/22 11:07 AM GMT +05:30

A=11B. (85-100)

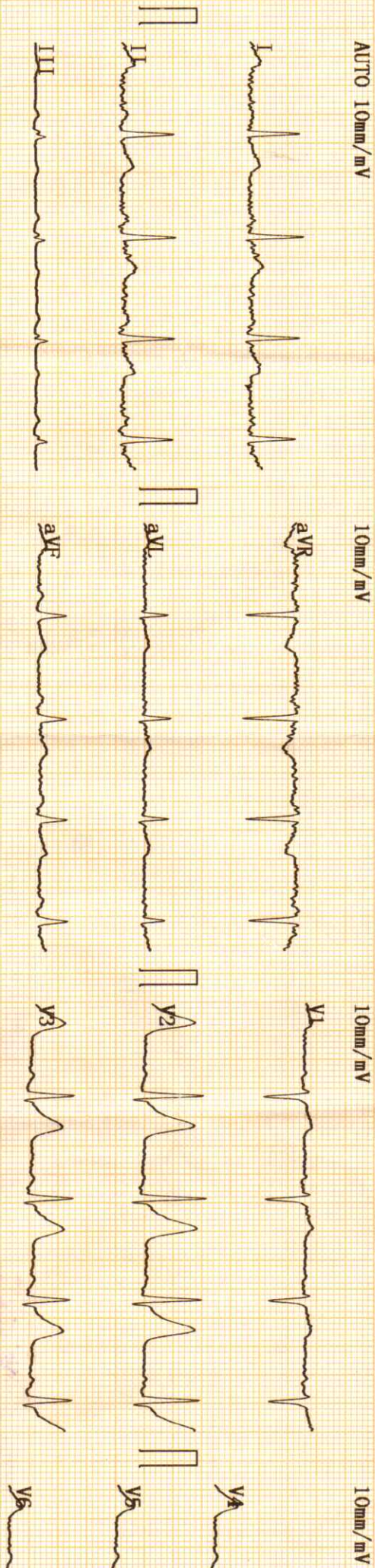
ADW
above.

R.

-
- Discheb diet 1400 kcal/d
 - Exer 60min/d.
 - eg. Diabetes (10) or
 - es. Znter (80) SUNDAY.
-

M

25mm/s AC50Hz+EMG35Hz+DFT



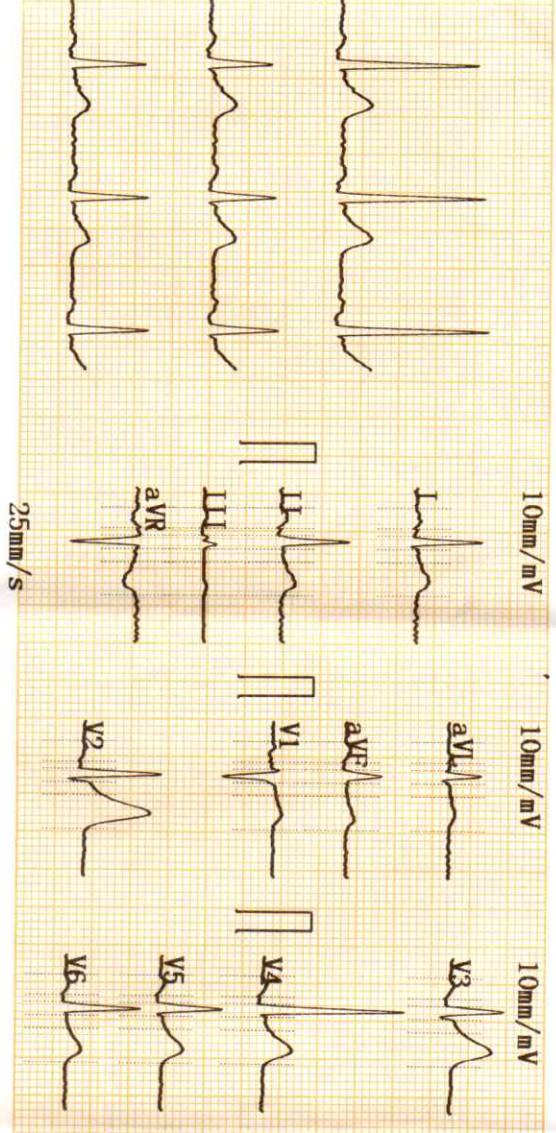
AUTO 10mm/mV

10mm/mV

10mm/mV

10mm/mV

CARDIART



2022-11-12 11:37

ID : _____
 Name : Vivek Kumar
 Sex : M
 Height : _____
 SYS : _____
 DIA : _____
 HR [bpm] : 84
 PR Interval [ms] : 155
 P Duration [ms] : 114
 QRS Duration [ms] : 73
 T Duration [ms] : 181
 QT/QTc [ms] : 325/384
 P/QRS/T Axis [deg] : 58.0/42.0/41.8
 R(Y5)/S(V1) [mV] : 0.86/0.65
 R(V5)+S(V1) [mV] : 1.50

<< Conclusions >>

Normal Sinus Rhythm;
 Cardiac electric axis normal;

kg **Report need physician confirm**

DR. PALLAVI MISHRA
 (BS, MD GENERAL MEDICINE)
 MCI Reg. No. 52033

Physician



PANACEA HOSPITAL

A shelter for many hearts A Home for many lives

(An ISO 9001:2008 Certified Organisation)

Lab Attached with CMC Vellore Under EQAS Scheme

Name	MR.VIVEK KUMAR	Sex /Age	37/M	Date	12/11/2022
Ref. by	SELF	BSA - m ²		Echo window	fair

Echo - Cardiography Stress Echo- Pre Exercise

MITRAL VALVE Doppler	AML - normal morphology MV Flow - E - 1.0 A-0.6 E/A=1.73	PML - normal morphology MVA - 3.0 cm ² Mitral Regurgitation -No
TRICUSPID VALVE Doppler	Normal TV Flow -No	Tricuspid Regurgitation -No
PULMONARY VALVE Doppler	Normal PV Flow -No	Pulmonary Regurgitation - No
AORTIC VALVE Doppler	Trileaflet- No AV Flow - no	Aortic Regurgitation - No
MEASUREMENT	Aorta - 34.3 (20-38) mm IVS ed - 8.0 (6-12) mm LVID ed -38.3 (35 - 55) mm LVPW ed -13.7 (6-12) mm OA - 7 (> 5) mm	LA - 35.4 (24-32) mm IVS es -23.4 (6 - 12) mm LVID es - 25.1 (24 - 40) mm LVPW es -17.7 (6 -12) mm EPSS - 5 (< 9) mm

CONCLUSION

All cardiac chamber dimensions are WNL
No valvular abnormalities
Good LV systolic function present Modified Simpson's method (4C, 2C) (LVEF-64%)
No diastolic dysfunction present (E/A = 1.73) by tissue Doppler (E/e'=6.2)
No pericardial effusion
No RWMA
Intact IAS / IV
No PAH
No intra cardiac mass /thrombus /vegetation

IMPRESSION Normal Echocardiogram

Niraj Mishra
Physician Assistant
(PIIRE)

Dr. Pallavi Mishra
MBBS, MD (MED) Lucknow
Echocardiography Specialist, MIAE
Non-invasive cardiologist
Women Cardiologist
Diabetocardiologist

Address : Kabir Nagar (Near Sanjay Shiksha Niketan), Durgakund, Varanasi

Mobile : 9554572190 / 9453837595 / Recpn. 9389994334

E-mail : dramishra@gmail.com, drpallaviojha@gmail.com, Website: www.piire.org



Call Now - 1800-123-3070

PANACEA HOSPITAL

A shelter for many hearts A Home for many lives

(An ISO 9001:2008 Certified Organisation)

Lab Attached with CMC Vellore Under EQAS Scheme

NAME: MR.VIVEK KUMAR

AGE/SEX: 37 YRS / MALE

REF BY: DR. ASHUTOSH MISHRA (MD)

DATE: 12/11/2022

ULTRA SOUND WHOLE ABDOMEN REPORT

Liver: Normal in shape and size(11.1 cm) and shows smooth and regular margin.
No diffuse/focal lesion seen.

Gall bladder: Partially distended with normal wall thickness and echo-free lumen.

CBD diameter Visualized part normal in course & caliber.

Pancreas: Normal in size, shape & echogenicity.
Margins are smooth & regular.
No diffuse/ focal lesion seen. Pancreatic tail obscured.

Spleen: Normal in size, shape & echogenicity.
Margins are smooth & regular. No diffuse / focal lesion seen.
Splenic vessels at hilum is normal.

Kidney: Right kidney: 9.7 X 4.1cm
Left kidney: 9.1 X 4.7 cm
Both normal in size, shape, echogenicity & position.
Cortical-medullary differentiation is maintained.
Pelvicalyceal system normal.
No calculus/mass lesion seen.
No hydronephrosis/ hydroureter seen.
No suprarenal mass lesion.

Address : Kabir Nagar (Near Sanjay Shiksha Niketan), Durgakund, Varanasi

Mobile : 9554572190 / 9453837595 / Recpn. 9389994334

E-mail : dramishra@gmail.com, drpallaviojha@gmail.com, **Website:** www.piire.org



PANACEA HOSPITAL

A shelter for many hearts A Home for many lives

(An ISO 9001:2008 Certified Organisation)

Lab Attached with CMC Vellore Under EQAS Scheme

Urinary bladder: Normally distended, wall thickness is normal.

No echogenic foci lumen or diverticula seen.

Both VUJ appears normal.

No E.R. calculus / mass lesion seen.

Prostate: Normal in size, shape, & echogenicity.

No calcification or focal cystic lesion seen.

Capsular margins are smooth and regular.

Seminal vesicles appear normal in size, shape & echogenicity.

No diffuse /focal lesion seen.

Others: No free fluid in peritoneal cavity.

No free fluid in bilateral pleural cavity.

IMPRESSION:

- **NO SIGNIFICANT SONOLOGICAL ABNORMALITY DETECTED.**

Please correlate clinically and further investigations.


DR. PALLAVI MISHRA

MBBS MD(MED) Lucknow

Echocardiography specialist, MIAE

Non invasive cardiologist

Women cardiologist


Radiologist


Dr. Tusharika Rai

MBBS MS

NIRAJ MISHRA

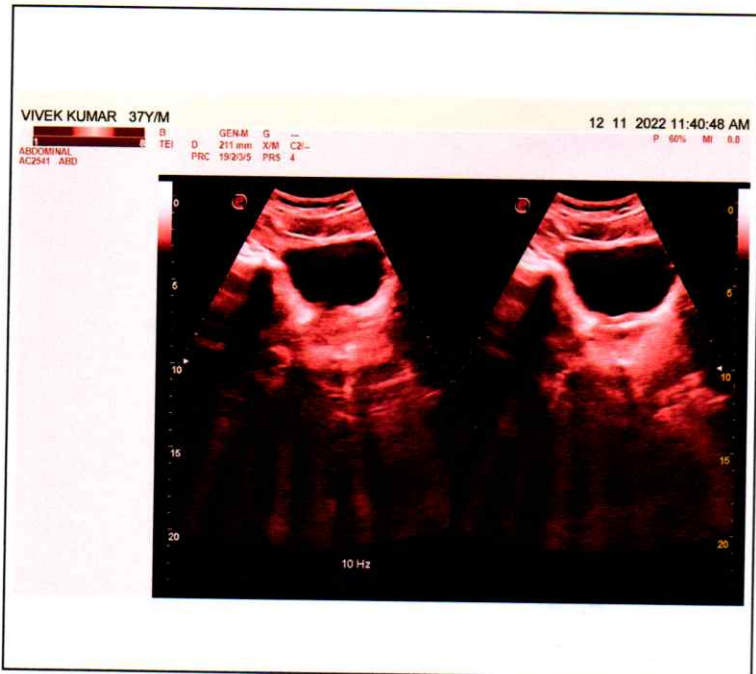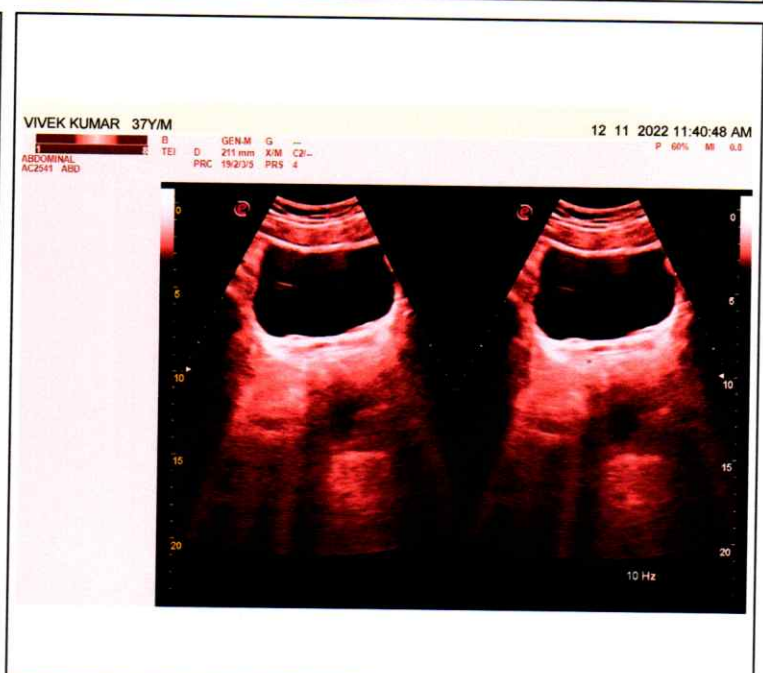
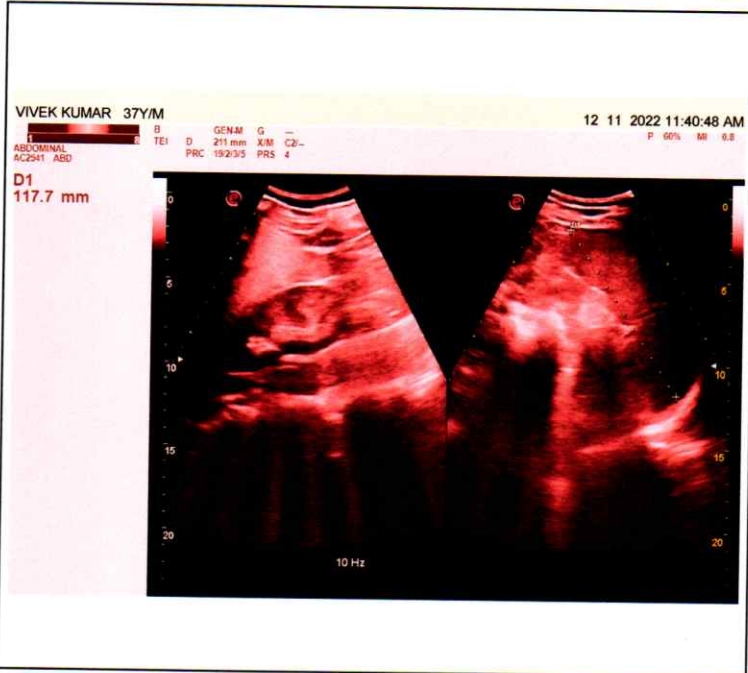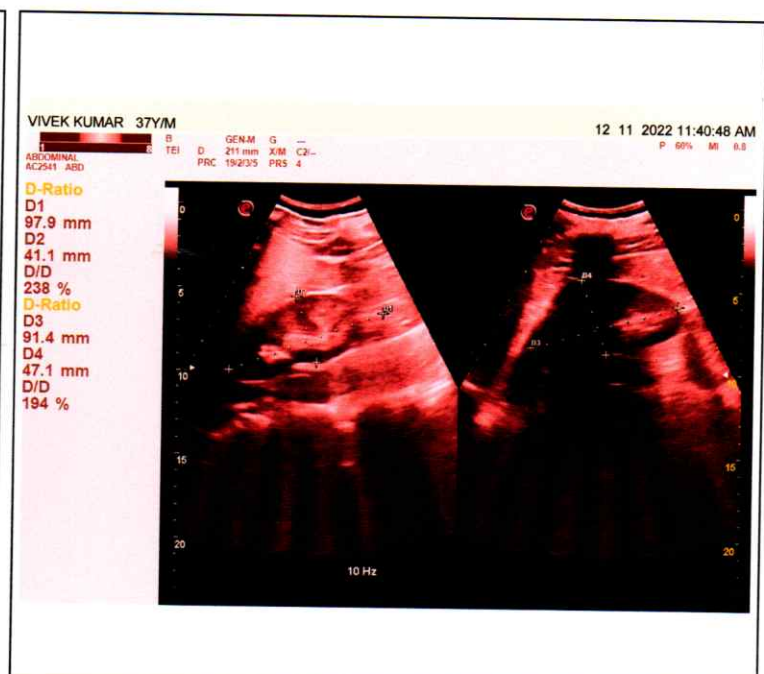
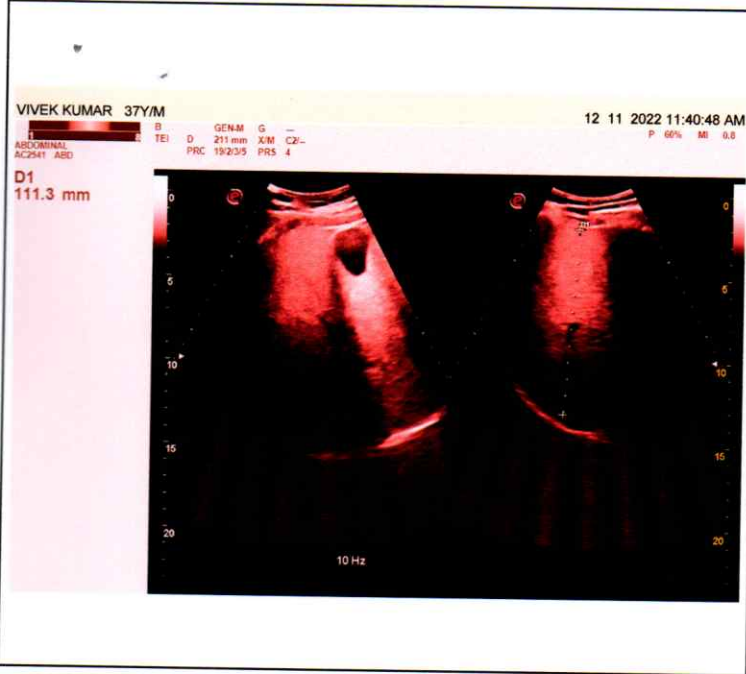(Physician Assistant)

(PIIRE)

Address : Kabir Nagar (Near Sanjay Shiksha Niketan), Durgakund, Varanasi

Mobile : 9554572190 / 9453837595 / Recpn. 9389994334

E-mail : dramishra@gmail.com, drpallaviojha@gmail.com, Website: www.piire.org





PANACEA HOSPITAL

A shelter for many hearts A Home for many lives

(An ISO 9001:2008 Certified Organisation)

Lab Attached with CMC Vellore Under EQAS Scheme

AME: MR.VIVEK KUMAR
EF BY: SELF

AGE/SEX: 37 YRS / MALE
DATE: 12/11/2022

X-RAY CHEST PA

BOTH LUNG FIELDS AND PLEURAE:

Both lungs show normal bronchovascular pattern.

Right & left hila are normal

No focal mass or calcification is seen

There is no evidence of any fluid in the both the pleural cavities.

Both domes of diaphragms are normal in position.

MEDIASTINUM:

Trachea is central in position.

Cardiac silhouette is of normal size and configuration.

No evidence of pericardial effusion.

No significant lymphadenopathy is seen.

Visualized skeleton is normal.

NO SIGNIFICANT RADIOGRAPHIC ABNORMALITY.

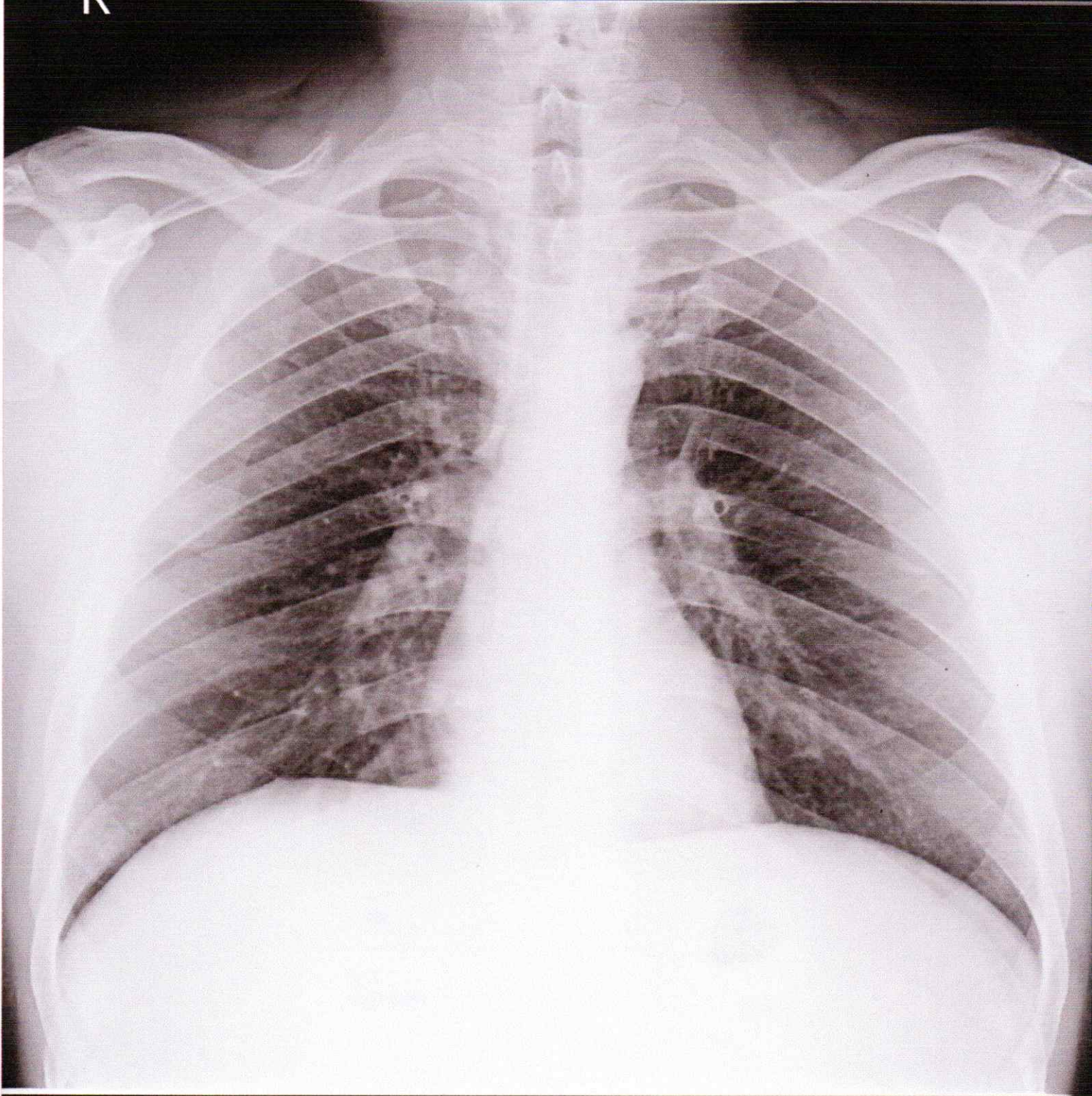

Radiologist

Address : Kabir Nagar (Near Sanjay Shiksha Niketan), Durgakund, Varanasi

Mobile : 9554572190 / 9453837595 / Recpn. 9389994334

E-mail : dramishra@gmail.com, drpallaviojha@gmail.com, Website: www.piire.org

R



vivek kumar 37y/m 5623 O CHEST P.A. 12-Nov-22 11:00 AM

PANACEA HOSPITAL, KABIR NAGAR, DURGAKUND, VARANASI