



BANK OF BARODA MEDICAL EXAMINATION REPORT

Client name :- Debari Missa
 Ref. No. :- PKG 10000237
 Date of birth :- 10.09.1981, Sex :- Male / Female
 Identification mark on the body :- Nothing as such found,
 Photo ID Xerox :- Adhar card. 745664377646,
 Date & place of medical examination :- 12.11.2022, Asansol,

Request for medical exam. of **BANK OF BARODA** through Medi Assist Health Care India (Pvt.) Ltd.

- A) 1. Height :- 159 cm. 2. Weight :- 68 kgs.
 3. Chest Inspiration :- 90 cm. 4. Chest Expiration :- 86 cm.
 5. Abdomen Girth :- 104 cm.
 6. Blood Pressure :- I) 131/78 mm. of Hg. II) mm. of Hg.
 7. Pulse Rate :- 78 / minute. Character of pulse :- Regular.
- B) 1. Are you now in good health? Yes
 2. Are you currently taking any medicine? NO
 3.) Are you married? Yes
 4. Have you ever had a positive test for HIV / AIDS / Malignancy? No
 5. Have you ever suffering from sexually transmitted disease or Hepatitis B or C?
 NO
 6. Have you any congenital disorders? NO
 7. Have you any respiratory disorders? NO
 8. Have you any musculo skeletal disorders? NO
 9. Have you CVS disorders? NO
 10. Have you GI system disorders? NO
 11. Have you urinary system disorders? NO
 12. Have you reproductive system disorders? NO

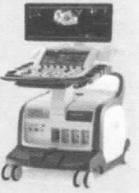



ANUBIKSHAN

Diagnostic Centre

Near Asansol District Hospital(Main Gate)
S.B. Gorai Road, Asansol-713301
Email ID : anubikshan.dc@gmail.com
Ph. : 0341-3590332, M. : 9732362727, 7872772680



13. Have you Diabetes / Hypertension / Endocrine disorders? NO
14. Have you ever done any surgical operation? NO
15. Have you any ear problem? NO
16. Have you any eye problem? VA etc, Near vision - M6, CV - Normal *RM 12/11/22*
17. Have you nervous system disorders? NO
18. Have you any abnormal growth? NO
19. Have you any blood disorders? NO
20. What is general appearance of the client? Healthy
21. Does the appearance correspond with the age? Yes
22. Is there any personal peculiarities? NO
23. Tobacco (Stick / gms)- Panmasala/Cigar / Cigarette / Bidi / Gutkha Yes No
Alcohol(ml)- Beer / Wine / Hard Liquor :- Qty./ Day For No. of Yrs

24.Family History	Age if living	Age at death	Present state of health or cause of death
Father	70y		Good health
Mother	69y		" "
Brother (s)	46y		" "
Sister (s)	36y		" "

25. ANY REMARK BY THE MEDICAL EXAMINAR: - She is fit

Debojini Mishra
Signature of the Client

DR. S.K. SHAW
Name of the Doctor

Date: - 12.11.22



Dr. Sanjeev Kevin Shaw
Signature & Seal of the Doctor
Dr. Sanjeev Kevin Shaw
M.B.B.S., MD (Med.)
Reg. No. 16138

भारत सरकार
Government of India

देबोसरी मिश्रा
DEBOSRI MISRA
जन्म तिथि / DOB: 10/09/1981
महिला / FEMALE

7456 6437 7645

मेरा आधार, मेरी पहचान

Issue Date: 05/02/2014

1947

help@uidai.gov.in

www.uidai.gov.in

7456 6437 7645

Print Date: 09/05/2021

Address: A S-3/17A, KALYANPUR HOUSING, POST R K MISSION, Assam (m Corp.), Bardhaman, West Bengal, 713305

भारतीय विशिष्ट पहचान प्राधिकरण
Unique Identification Authority of India

वर्ग 19 एम. 3/17A, कल्याणपुर शहरीकरण, पोस्ट आरके मिशन, असम (म. कॉर्प.), बर्द्धमान, पश्चिम बंगाल, 713305

ANUSHYAM DIAGNOSTIC CENTRE
ASANSOL

Debosri Misra

Dr. Sanjeev Kevin Shah
M.B.B.S., MD (Med.)
Reg. No. 16138

Dr. Rajib Banerjee

B.Sc., B.H.M.S., DOS (Kol)
Consultant Homoeopathic Physician
and optometric Eye Specialist

ADDRESS :

1 No. Mohishila Colony
Bottala Bazar
Asansol - 3
Mob. : 9832197360

Rx

Debarshi Mishra

Rt. Eye		Lt. Eye	
Sph	Cyl	Sph	Cyl
0	0	0	0
Near Add. →	0	Near Add. →	0

VA ^{0/6} _{0/6}
Near Vision - NB
CV - Normal.

BBM
12/4/22



Chamber

Balananda Homoeo Clinic
Khejurtala More
Mohishila - 2, Asansol

Morning : 8.00 a.m. to 9.00 a.m.
Evening : 6.00 p.m. to 9.30 p.m.
Saturday Evening Closed
& Sunday Morning Closed

Test Report

DEBOSRI MISHRA

Reference: Dr.BANK OF BARODA

VID: 220224000018846

PID NO: P2242200021862

Age: 41.0 Year(s) Sex: Female



Sample Collected At:
Anubikshan Diagnostic Centre
Near Asansol District Hospital Main Gate,
Asansol : 713301

Processing Location:-MHL ASANSOL
LAB West Apar Garden
G.T.Road,Asansol-713304

Registered On:

12/11/2022 04:10 PM

Collected On:

12/11/2022 4:10PM

Reported On:

12/11/2022 05:02 PM

Investigation	Observed Value	Unit	Biological Reference Interval
Thyroid panel-1 (T3/T4/TSH) (Serum,ECLIA)			
T3 (Total)	98.61	ng/dL	84.63-201.8
T4 (Total)	7.82	µg/dL	5.13-14.06
TSH(Ultrasonensitive)	1.41	µIU/mL	0.54-5.3 First Trimester : 0.1-2.5 Second Trimester : 0.2-3.0 Third trimester : 0.3-3.0

INTERPRETATION

TSH	T3 / FT3	T4 / FT4	Suggested Interpretation for the Thyroid Function Tests Pattern
Within Range	Decreased	Within Range	• Isolated Low T3-often seen in elderly & associated Non-Thyroidal illness. In elderly the drop in T3 level can be upto 25%.
Raised	Within Range	Within Range	•Isolated High TSHespecially in the range of 4.7 to 15 mIU/ml is commonly associated with Physiological & Biological TSH Variability. •Subclinical Autoimmune Hypothyroidism •Intermittent T4 therapy for hypothyroidism •Recovery phase after Non-Thyroidal illness"
Raised	Decreased	Decreased	•Chronic Autoimmune Thyroiditis •Post thyroidectomy,Post radioiodine •Hypothyroid phase of transient thyroiditis"
Raised or within Range	Raised	Raised or within Range	•Interfering antibodies to thyroid hormones (anti-TPO antibodies) •Intermittent T4 therapy or T4 overdose •Drug interference- Amiodarone, Heparin,Beta blockers,steroids, anti-epileptics"
Decreased	Raised or within Range	Raised or within Range	•Isolated Low TSH -especially in the range of 0.1 to 0.4 often seen in elderly & associated with Non-Thyroidal illness •Subclinical Hyperthyroidism •Thyroxine ingestion"
Decreased	Decreased	Decreased	•Central Hypothyroidism •Non-Thyroidal illness •Recent treatment for Hyperthyroidism (TSH remains suppressed)"
Decreased	Raised	Raised	•Primary Hyperthyroidism (Graves' disease),Multinodular goitre, Toxic nodule •Transient thyroiditis:Postpartum, Silent (lymphocytic), Postviral (granulomatous,subacute, DeQuervain's),Gestational thyrotoxicosis with hyperemesis gravidarum"
Decreased or within Range	Raised	Within Range	•T3 toxicosis •Non-Thyroidal illness"

- References: 1. Interpretation of thyroid function tests. Dayan et al. THE LANCET • Vol 357 • February 24, 2001
2. Laboratory Evaluation of Thyroid Function, Indian Thyroid Guidelines, JAPI, January 2011,vol. 59

-- End of Report --

Results relate only to the sample as received. Refer to conditions of reporting overleaf

† This test was outsourced to Metropolis Healthcare Ltd. Mumbai

Dr. Satabdi.Mitra
M.D (Pathology)

Page 1 of 1



ANUBIKSHAN

Diagnostic Centre

Near Asansol District Hospital(Main Gate)
S.B. Gorai Road, Asansol-713301
Email ID : anubikshan.dc@gmail.com
website: www.anubikshan.com

PATIENT ID:2022K9026 NAME: DEBOSRI MISRA AGE:41 YR FEMALE
ADVISED BY:Dr. .M.O., BANK OF BARODA.,
DATE OF RECEIPT : 12/11/2022 DELIVERY DATE : 12/11/2022 TIME : 07:00 PM

HEAMATOLOGY TEST

TEST	RESULT	NORMAL RANGE
* Haemoglobin :-	12.2 gm/dl	12 - 16 gm/dl
* Total Leucocyte Count :-	7,400 /cu mm	4,000-11,000/cu mm
* Differential Leucocyte Count ::		
* -----		
Neutrophil	65 %	40-75%
Lymphocyte	32 %	20-45%
Monocyte	01 %	2-10%
Eosinophil	02 %	1-6%
Basophil	00 %	0-1%
* Erythrocyte Sedimentation	14 mm / 1st hour	Less than 15 mm (M) Less than 20 mm (F)
* P. C. V.	43 %	45.0-50.0% (M) 37.0-47.0% (F)
* M. C. V.	87.8 fl.	77-93 fl
* M. C. H.	24.9 pg.	27.0-32.0 pg
* M.C.H.C.	28.4 gm/dl.	31.0-35.0 gm/dl
* Platelet Count	1,82,000 /cu mm	1.5 - 4.0Lakh/cu mm
* R. B. C.	4.9 million/cu mm	6.0-8.0million/cu mm(M) 3.8-5.8million/cu mm(F)

All Reference ranges are age and sex matched. Reference limit mentioned herein are in accordance with the literature provided along with the kit. Which may change in chemistry or the kit.

DR. APARNA MONDAL.
M.B.B.S., M.D (Pathology)
(Regd. No. 57881)

DR. SWARUP GHOSH
M.B.B.S., M.D (Pathology)
(Regd. No. 52140)



ANUBIKSHAN

Diagnostic Centre

Near Asansol District Hospital(Main Gate)
S.B. Gorai Road, Asansol-713301
Email ID : anubikshan.dc@gmail.com
website: www.anubikshan.com

PATIENT ID:2022K9026 NAME: DEBOSRI MISRA AGE:41 YR FEMALE
ADVISED BY:Dr. .M.O., BANK OF BARODA.,
DATE OF RECEIPT : 12/11/2022 DELIVERY DATE : 12/11/2022 TIME : 07:00 PM

BIO CHEMISTRY REPORT

TEST	RESULT	NORMAL RANGE
Plasma Glucose (Fasting)	103.4 mg/dl	70 - 115 mg/dl
Plasma Glucose (P.P)	144.5 mg/dl	80 - 150 mg/dl.
Uric-Acid	3.7 mg/dl	2.6 mg/dl - 6.0 mg/dl
Creatinine	0.88 mg/dl	0.7 - 1.4 mg/dl
Cholesterol	195.0 mg/dl	00 - 200 mg/dl
Triglyceride	90.0 mg/dl	0 - 200 mg/dl
HDL Cholesterol	35.0 mg/dl	40 - 90.0 mg/dl
LDL Cholesterol	142.0 mg/dl	00 - 130 mg/dl
V.L.D.L.	18.0 mg/dl	23 - 45 mg/dl
CHOLESTEROL/HDL RATIO	5.6 : 1	upto - 5.0
LDL/HDL RATIO	4.1 : 1	upto - 3.0
Serum Bilirubin(Total)	0.79 mg/dl	0.1 - 1.2 mg/dl
Serum Bilirubin (Direct)	0.36 mg/dl	0.0 - 0.4 mg/dl
Serum Bilirubin(Indirect)	0.43 mg/dl	UPTO - 0.8 mg/dl
S.G.P.T	27.4 U/L	00 - - 35.0 U/L

All biochemistry done by fully automated system Diasys respons 910.

All Reference ranges are age and sex matched. Reference limit mentioned herein are in accordance with the literature provided along with the kit. Which may change in chemistry or the kit.

DR. APARNA MONDAL.
M.B.B.S., M.D (Pathology)
(Regd. No. 57881)

DR. SWARUP GHOSH
M.B.B.S., M.D (Pathology)
(Regd. No. 52140)



ANUBIKSHAN

Diagnostic Centre

Near Asansol District Hospital(Main Gate)
S.B. Gorai Road, Asansol-713301
Email ID : anubikshan.dc@gmail.com
website: www.anubikshan.com

PATIENT ID: 2022K9026 NAME: DEBOSRI MISRA AGE: 41 YR FEMALE
ADVISED BY: Dr. .M.O., BANK OF BARODA.,
DATE OF RECEIPT : 12/11/2022 DELIVERY DATE : 12/11/2022 TIME : 07:00 PM


BIO CHEMISTRY REPORT

TEST	RESULT	NORMAL RANGE
S.G.O.T	20.5 U/L	00 - 31.0 U/L
Alkaline Phosphatase	80.2 U/L	35 - 105 U/L
Total Protein	7.3 gm/dl	6.6 - 8.8 gm/dl
Albumin	4.0 gm/dl	3.5 - 5.2 gm/dl
Globulin	3.3 gm/dl	2.3 - 3.5 gm/dl
A : G	1.2:1	upto - 2.5:1
G.G.T	24 U/L	00 - 38 U/L

BUN/CREATNINE RATIO:- 18:1

All biochemistry done by fully automated system Diasys respons 910.

All Reference ranges are age and sex matched. Reference limit mentioned herein are in accordance with the literature provided along with the kit. Which may change in chemistry or the kit.


DR. APARNA MONDAL.
M.B.B.S., M.D (Pathology)
(Regd. No. 57881)

DR. SWARUP GHOSH
M.B.B.S., M.D (Pathology)
(Regd. No. 52140)



ANUBIKSHAN

Diagnostic Centre

Near Asansol District Hospital(Main Gate)
S.B. Gorai Road, Asansol-713301
Email ID : anubikshan.dc@gmail.com
website: www.anubikshan.com

PATIENT ID: 2022K9026 NAME: DEBOSRI MISRA AGE: 41 YR FEMALE
ADVISED BY: Dr. .M.O., BANK OF BARODA.,
DATE OF RECEIPT : 12/11/2022 DELIVERY DATE : 12/11/2022 TIME : 07:00 PM

URINE ROUTINE EXAMINATION

PHYSICAL EXAMINATION

Colour : STRAW
S.P.Gravity : 1.010
Appearance : CLEAR
Sediment : NIL

CHEMICAL EXAMINATION

pH : 6.0
Protein : NIL
Sugar : NIL
Blood : NIL

MICROSCOPICAL EXAMINATION

R.B.C : NIL
Pus Cells : 1-2/HPF
Epithelial Cells : 3-4/HPF
Casts : NOT FOUND
Crystals : NOT FOUND
Bacteria : NOT FOUND
Others : NOT FOUND

All Reference ranges are age and sex matched. Reference limit mentioned herein are in accordance with the literature provided along with the kit. Which may change in chemistry or the kit.

DR. APARNA MONDAL.
M.B.B.S., M.D (Pathology)
(Regd. No. 57881)

DR. SWARUP GHOSH
M.B.B.S., M.D (Pathology)
(Regd. No. 52140)



Pathology Department

REPORT ON EXAMINATION OF

GLYCOSYLATED HEMOGLOBIN

PATIENT'S NAME: - DEBOSRI MISHRA AGE: - 41 YEAR SEX:- FEMALE


REF. BY DR.: - M.O. BANK OF BARODA. DATE: - 12-11-2022

HbA1C

<u>TEST</u>	<u>RESULT</u>	<u>NORMAL RANGE</u>
HbA1C	4.2 %	NON-DIABETIC - (<6%)
		GOOD CONTROL-(6.0%-7%)
		FAIR CONTROL- (7.1%-8%)
		POOR CONTROL- (>8%)

Alert: - Poor control may develop long term complications such as Retinopathy, Nephropathy, Neuropathy and Cardiopathy etc.

Comment: - MBG is a value calculated from HbA1c and indicator of average more or less glucose Level over past three months.


DR. APARNA MONDAL.
M.B.B.S., M.D (Pathology)
(Regd. No. 57881)

DR. SWARUP GHOSH
M.B.B.S., M.D (Pathology)
(Regd. No. 52140)



ELECTRO CARDIO GRAM FORMAT

PATIENT NAME:- DEBOSRI MISHRA	
AGE:- 41 YRS	GENDER:- FEMALE
REF BY DR:- M.O.BANK OF PARODA	DATE:- 12.11.2022

❖ **RATE** :- 98
❖ **AXIS** :- Normal
❖ **P-WAVE** :- Normal
❖ **P-R** :- Normal
❖ **QRS** :- Normal
❖ **ST-T** :- Normal
❖ **T-WAVE** :- Normal

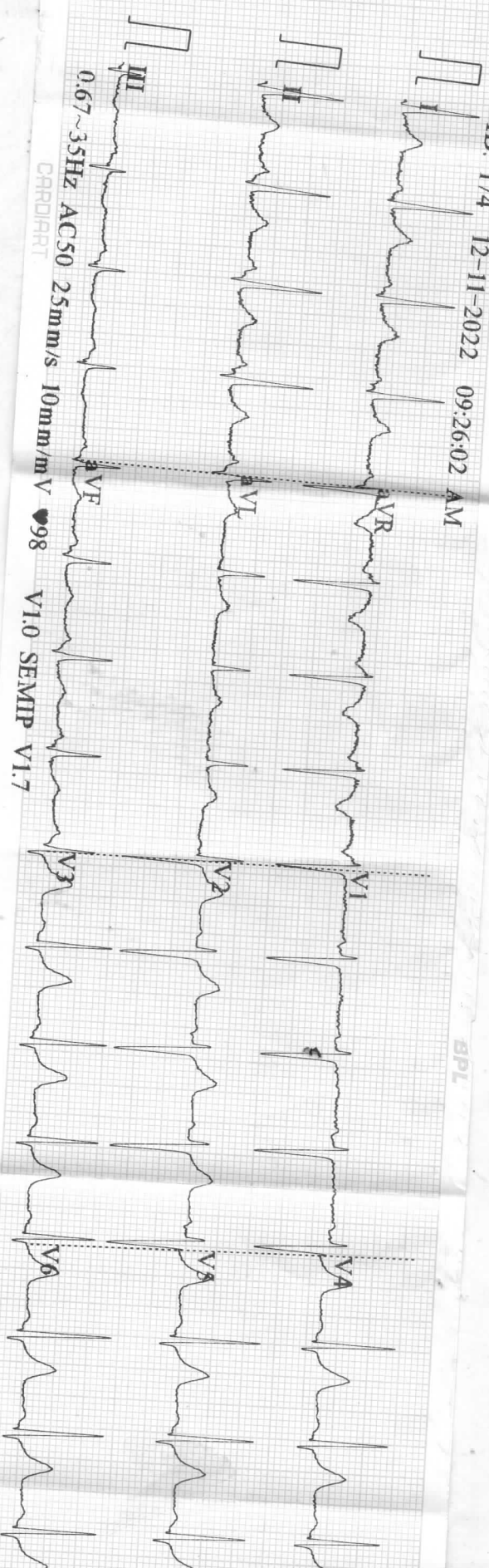
➤ **IMPRESSION** :- Normal sinus rhythm


Dr. Sunil Gupta

48372
WB

Dr. SUNIL GUPTA
M B B S MD (Medicine)
Reg No WBMC 48372

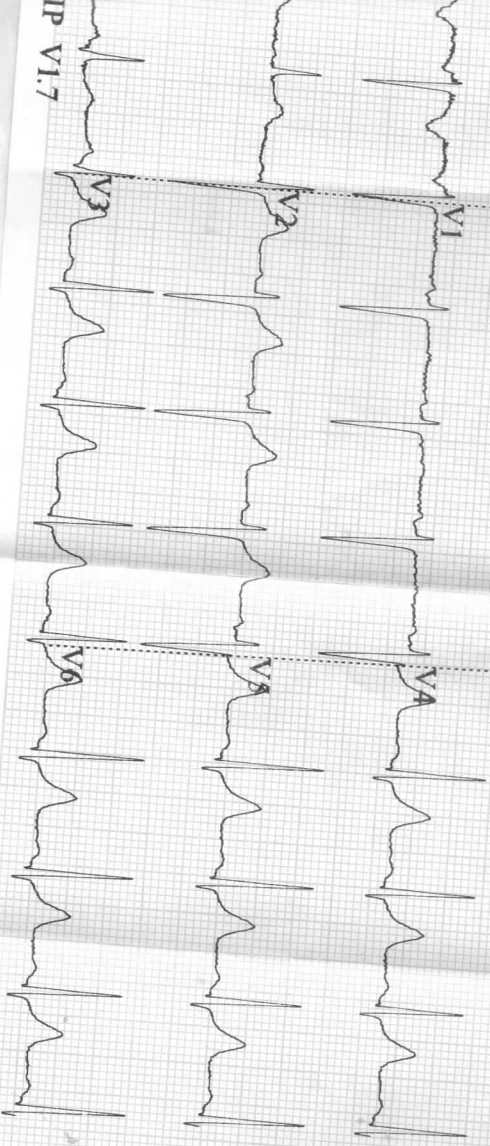
ID: 174 12-11-2022 09:26:02 AM



0.67~35Hz AC50 25mm/s 10mm/mV 98

CR001R1 V1.0 SEMIP V1.7

BPL



[Handwritten signature]

ID: 174
 Female
 41 Years
 cm
 kg
 mmHg

HR	97	bpm
P	102	ms
PR	131	ms
QRS	77	ms
QT	334	ms
QTc	42	ms
P/ORS/T	57/31/21	°
RV5/SV1	1.297/1.198	mV

Diagnosis Information:
 Sinus Rhythm
 Slight ST Depression (V2)

Deborah Miskin
Bank of Baroda
Delays' Dept.
 Report Confirmed by:



ANUBIKSHAN

Diagnostic Centre

Near Asansol District Hospital(Main Gate)
S.B. Gorai Road, Asansol-713301
Email ID : anubikshan.dc@gmail.com
Ph. : 0341-3590332, M. : 9732362727, 7872772680

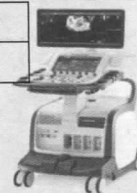PATIENT'S NAME: - DEBOSRI MISHRA

AGE:- 45 YEAR

SEX:- FEMALE

REF. BY DR.:- BANK OF BARODA.

DATE: - 18.11.2022



U.S.G OF WHOLE ABDOMEN

LIVER

Normal shape and size. Homogeneous echo texture of the liver is seen.
No focal parenchymal lesion is seen. (Measure:- 140.88 mm.)

PORTA VEIN

Portal vein at porta hepatis measures: - 6.36 mm. in diameter.
The appearance of porta is normal.

GALL BLADDER

Normal shape, size and position of the Gall Bladder is seen.
No calculus or any intraluminal mass is seen.

COMMON BILE DUCT

Common bile duct is not dilated (1.33 mm.)
No calculus or any intraluminal echogenicity.

PANCREAS

Normal echo-texture of the pancreas is seen. No space occupying lesion is seen.
Its relation with the anatomical landmark is normal.

SPLEEN

Normal dimension of the spleen is seen. It shows normal echo-texture.
No space occupying lesion is seen in the spleen. (Measure: - 87.22 mm.)

KIDNEYS

Both the kidneys are normal in shape, size, margin and axis.
Cortico medullary differentiation is normal.
No calculi or any hydronephrotic changes noted.
(Rt. Kidney Measure: - 104.66 mm. in length. & Lt. Kidney Measure:- 110.68 mm. in length.)

URINARY BLADDER

Normal shape and size of the urinary bladder is seen.
No intraluminal echo is noted.

UTERUS

A/V, Bulky. (Measure: - 106.95 mm x 32.74 mm x 49.01 mm.)

OVARIES

Normal shape and size of the ovaries are seen.
No space occupying lesion is seen in the ovaries. Normal echo texture is seen.
(Right ovary Measure: - 33.33 mm. x 34.42 mm.)
(Left ovary Measure: - 46.19 mm. x 42.57 mm.)

- **IMPRESSION :-**
- **NORMAL STUDY**

ADVICE
Clinical co-relation.

Handwritten signature and date: 18/11

DR. DIPANKAR DASGUPTA.
(M.B.B.S., D.M.R.D)
(Regd.No:- WB-34374)

PATIENT'S NAME:- DEBOSRI MISHRA

AGE:- 41 YEAR SEX:- FEMALE

REF BY DR: - BANK OF BARODA

DATE:- 18.11.2022

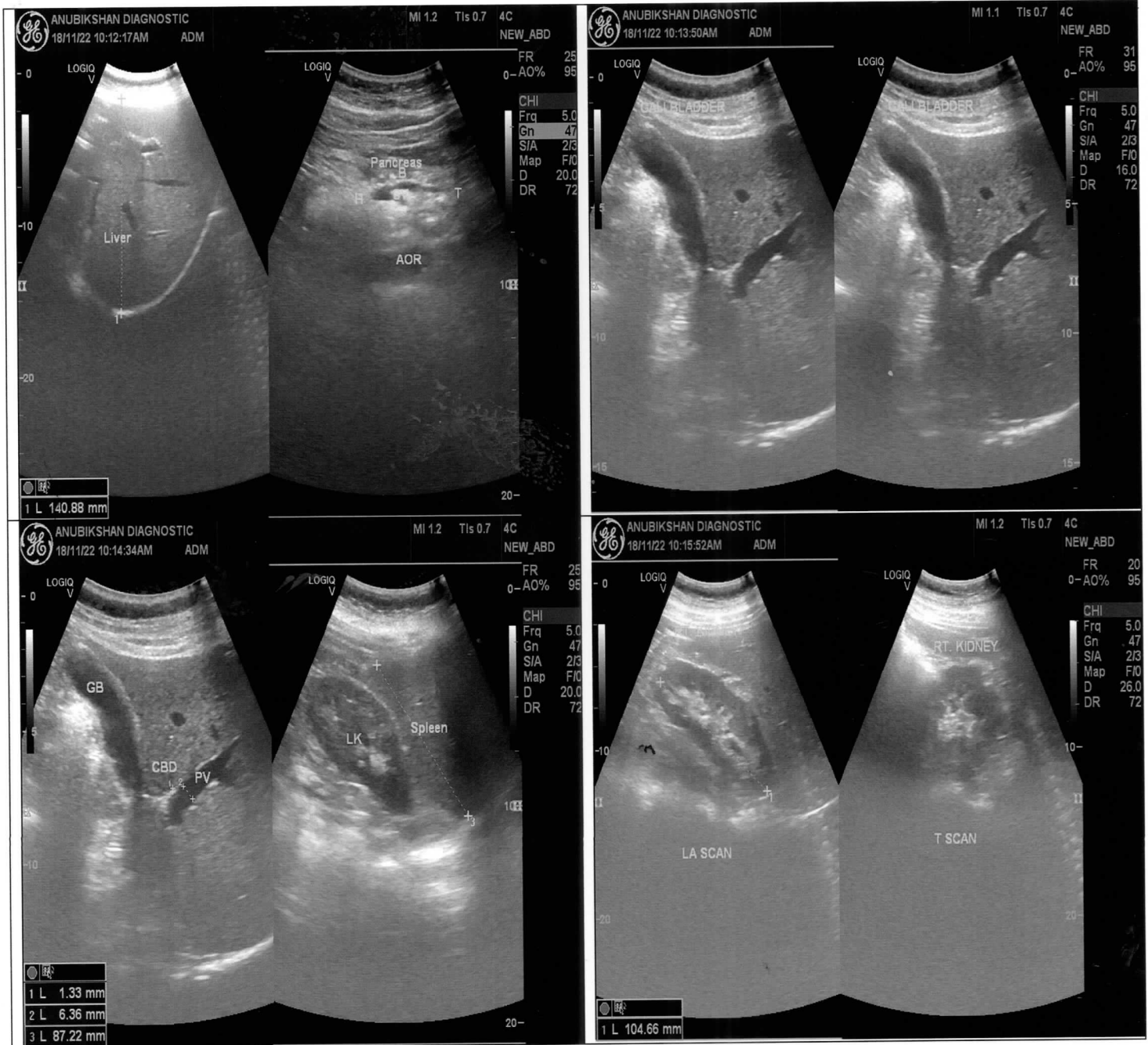
U.S.G. OF WHOLE ABDOMEN

ANUBIKSHAN DIAGNOSTIC CENTRE

NEAR ASANSOL DISTRICT HOSPITAL (MAIN GATE)
S.B.GORAI ROAD (EAST), PIN - 713301

LANDLINE: - 0341-3590332 // MOB - 7872772680

E- mail ID: - anubikshan.dc@gmail.com (1)



PATIENT'S NAME:- DEBOSRI MISHRA

AGE:- 41 YEAR SEX:- FEMALE

REF BY DR: - BANK OF BARODA

DATE:- 18.11.2022

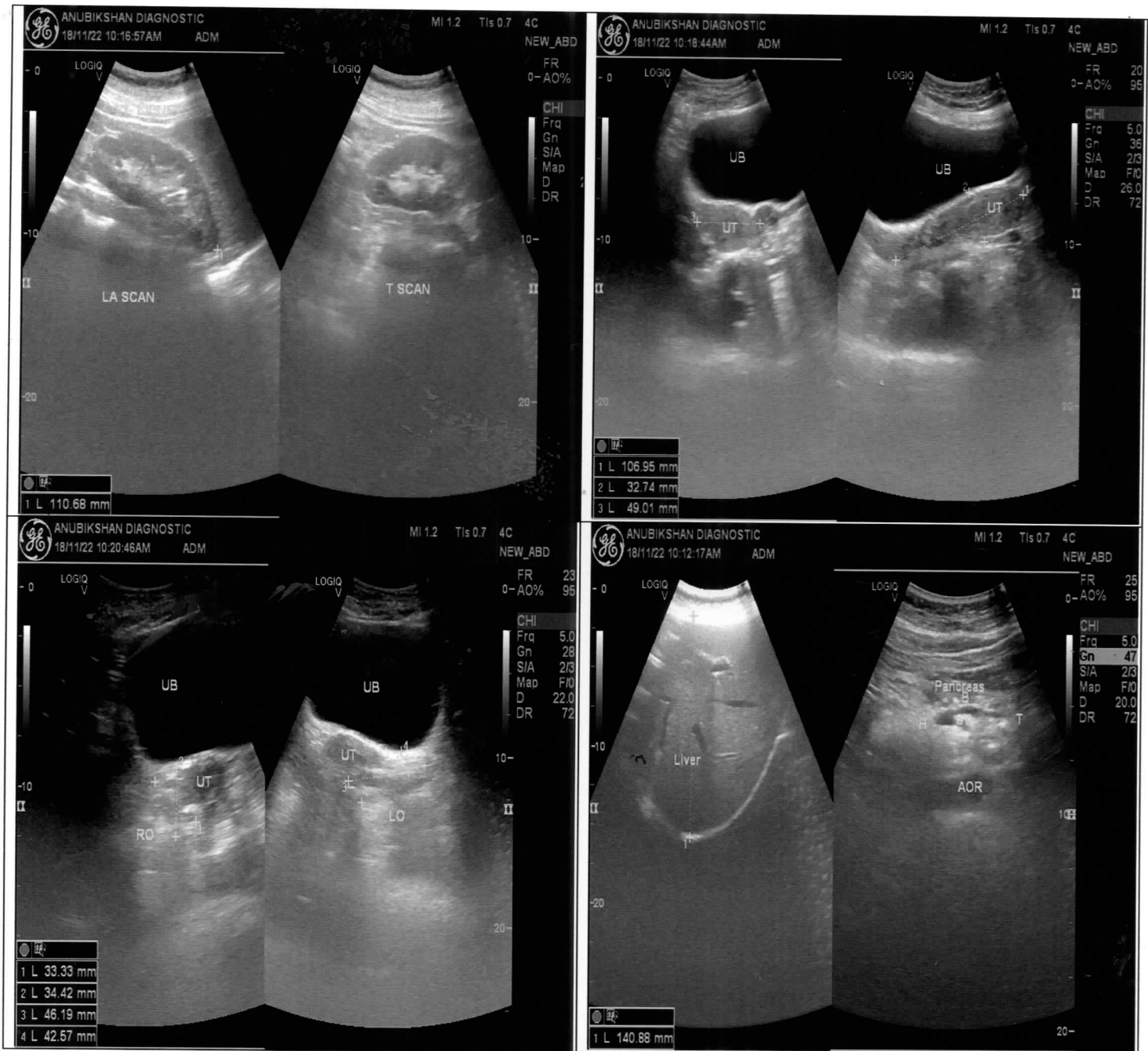
U.S.G. OF WHOLE ABDOMEN

ANUBIKSHAN DIAGNOSTIC CENTRE

NEAR ASANSOL DISTRICT HOSPITAL (MAIN GATE)
S.B.GORAI ROAD (EAST), PIN - 713301

LANDLINE: - 0341-3590332 // MOB - 7872772680

E- mail ID: - anubikshan.dc@gmail.com (2)





PATIENT'S NAME:- DEBOSRI MISRA	AGE:- 45 YEARS	SEX:- FEMALE
REFERRED BY DR:- M.O. BANK OF BARODA.	DATE:- 17.11.2022	

Transthoracic Echo 2-D/M-Mode, Echo Report

2-D/ M-Mode Measurements :(mm.)

	Observed Values(mm)	Normal Values(mm)
Aortic root diameter	26.60	20 – 36 mm
Left Atrium Size	30.40	19 – 40 mm

	End Diastolic(mm)	End Systolic(mm)	Normal Values(mm)
Interventricular Septum	11.40	19.76	ED=6-10
Left Ventricle Size	47.12	28.88	ED=37-53; ES=22-40
Posterior Wall Thickness	11.40	16.72	ED=5-10

LV Ejection Fraction (%)	69.03 %	55 – 80%
--------------------------	---------	----------

❖ FINDINGS :-

1. No LV Regional Wall Motion Abnormality, Global LVEF is 69.03%.
2. Normal Cardiac chambers dimension.
3. All valves normal.
4. Normal L.V. Compliance.
5. No intracardiac clot/veg.
6. No pericardial effusion.
7. Normal RV systolic function.

❖ IMPRESSION:-

❖ NORMAL 2D ECHOCARDIOGRAPHY.

DR. KAUSHIK SUR.
(M.B.B.S., M.D., D.M)
(Sr. Consultant Interventional Cardiologist
(Regd. No: - WB-62545)

PATIENT'S NAME: - DEBOSRI MISRA

AGE:- 45 YEAR SEX:- FEMALE

REF BY DR: - M.O. BANK OF BARODA.

DATE:- 17.11.2022

2D ECHO DONE BY :-

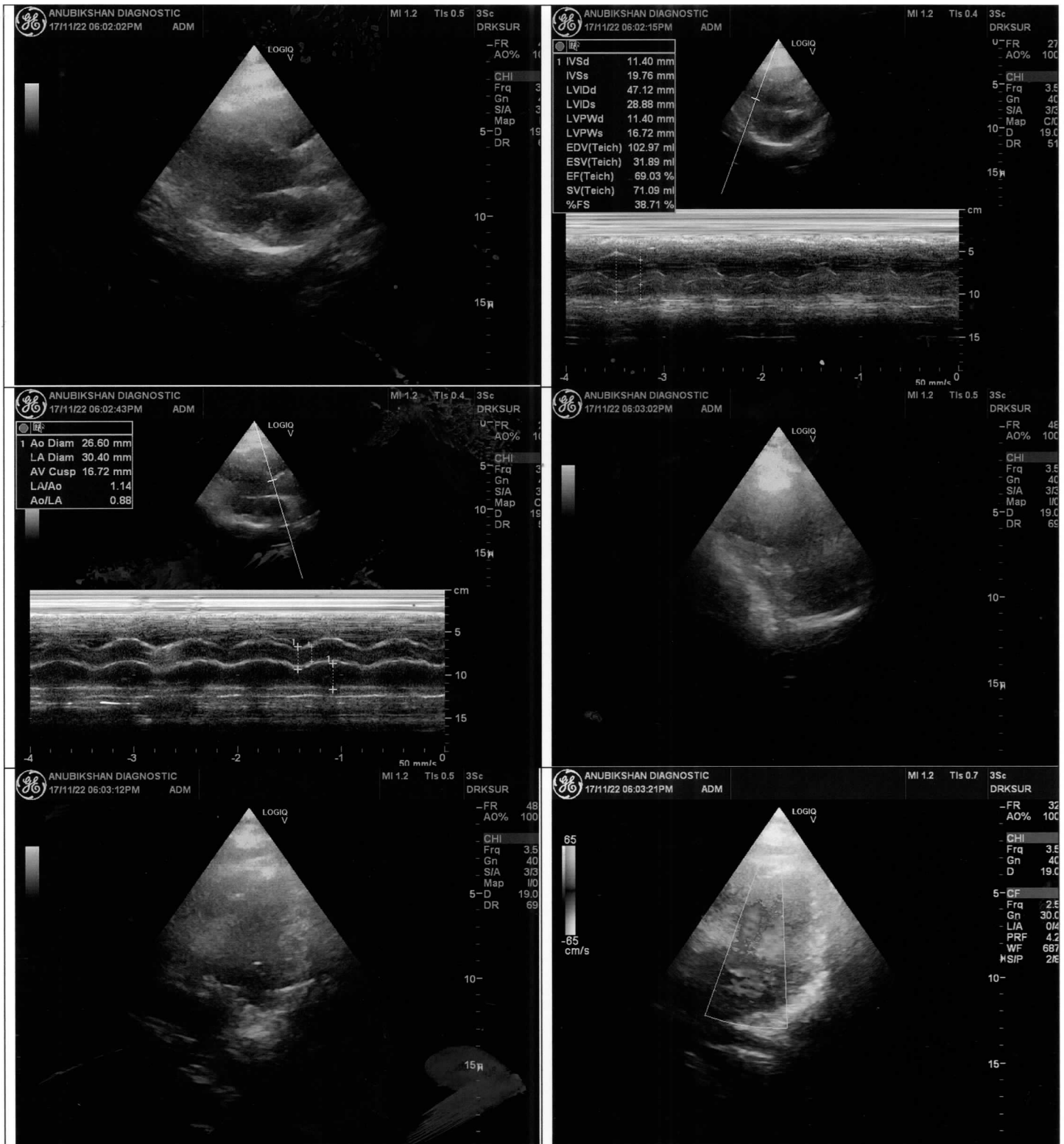
DR. KAUSHIK SUR (MD, DM) (CARDIOLOGIST)

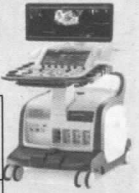ANUBIKSHAN DIAGNOSTIC CENTRE

NEAR ASANSOL DISTRICT HOSPITAL (MAIN GATE)
S.B.GORAI ROAD (EAST), PIN - 713301

LANDLINE: - 0341-3590332 // MOB - 7872772680

E-mail add: - anubikshan.dc@gmail.com





PATIENT'S NAME: - DEBOSRI MISHRA

AGE: - 41 YEAR

GENDER: - FEMALE

REFERRED BY DR: - M.O. BANK OF BARODA.

DATE: - 12.11.2022

REPORT

CHEST X – RAY P A VIEW

Soft tissue around chest and bony cage --- normal.

No active lung lesion in either field.

Cardiac configuration normal.

Pleural recesses are clear.

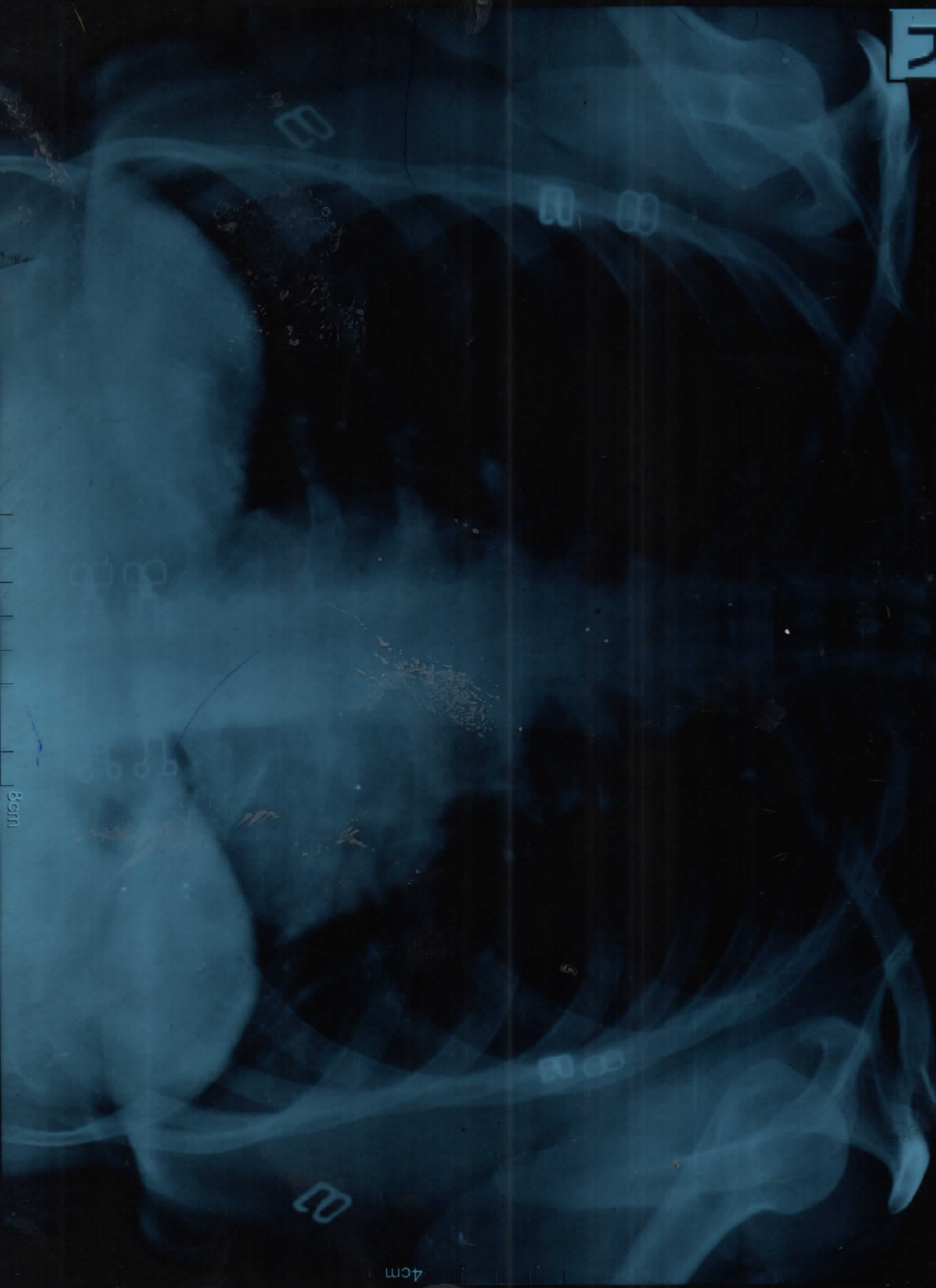
I M P R E S T I O N

✓ **NORMAL SKIAGRAM OF CHEST.**

[Handwritten signature]
12/11

DR. DIPANKAR DASGUPTA.
(M.B.B.S., D.M.R.D)
(Regd.No:- WB-34374)

R



DEBOSRI MISHRA 41Y Female
NEW ASANSOL X RAY CLINIC. MOB-9434236862

4cm

8cm

Self
12/11/2022

