



PANACEA HOSPITAL

B 36/44 F.K KABIR NAGAR, DURGAKUND
TOLLFREE NO-18001233070. Whatsapp No - 8795832852
www.piire.org
panaceaquery@gmail.com|panceahospitalit@gmail.com



OP Slip

Print Date : 23-Mar-2024 09:58AM



UHID No :- UD-23240007039 OP No :- OP-23240021605 OP Date :- 23 Mar 2024 9:56AM
 Patient Name :- Mr ASHISH RANJAN Age/Sex :- 35 Y/Male Mobile No :- 7800940557
 Father :- PARMESHWAR PRASAD GUPTA Department :- OPHTHALMOLOGY
 Pay Type :- Cr Consultant :- Dr Santosh Verma (MBBS,MS)
 Token No :- NOR. - 6 Paid/Bal :- 0.00 /30.00
 Patient Type :- Normal
 Address :- SONU MEDICAL AGENCY, MARUFGUNJ ROAD WARD NO- 20 SAHARSA 852201,BIHAR

BP :- 100/70
 height :- 153
 Weight (kg) :- 76
 BMI :-
 wc - 102
 NC - 38
 CH - 101
 SpO2 - 98
 PR - 82
 PEFr - 300

Rx
 6/9 - 6/6' ✕
 6/9 - 6/6' ✕

NG
 NG

B/E ant. segment, WNL
 B/E central fundus?, WNL

B/E
 UBSTANT VCTR TRD

NOBL. R/P 10 deg infero super view

Adv
 - RFT
 - OCT(M)BE
 - Fundus BE

Printed By : Ms. Renuka
 Created By : Ms. Renuka

Dr. SANTOSH VERMA
 MBBS, MS (Ophthalmologist)
 MCI Reg. No. 09-34327



PANACEA HOSPITAL

B 36/44 F.K KABIR NAGAR, DURGAKUND
TOLLFREE NO-18001233070. Whatsapp No - 8795832852
www.piire.org
panaceaquery@gmail.com|panceahospitalit@gmail.com



OP Slip

Print Date : 23-Mar-2024 09:56AM



UHID No :- UD-23240007039	OP No :- OP-23240021605	OP Date :- 23 Mar 2024 9:56AM
Patient Name :- Mr ASHISH RANJAN	Age/Sex :- 35 Y/Male	Mobile No :- 7800940557
Father :- PARMESHWAR PRASAD GUPTA	Department :- GENERAL MEDICINE	
Pay Type :- Cr	Consultant :- Dr Pallavi Mishra (MBBS,MD,MBBS)	
Token No :- NOR. - 6	Paid/Bal :- 0.00 /30.00	
Patient Type :- Normal		
Address :- SONU MEDICAL AGENCY, MARUFGUNJ ROAD WARD NO- 20 SAHARSA 852201,BIHAR		

BP :- 100/70
 height :- 163
 Weight (kg) :- 76
 BMI :-
 we - 102
 Nc - 38
 CH - 101
 SpO2 - 98 -
 PR - 82
 PEFr - 300

Rx

Rx

Diet 1000kcal P/dy
 Exercise 60 min P/dy
 Tab Beudophus 200

R/A 21 day

Pallavi
 DR. Pallavi Misra
 MBBS, MD(GENERAL MEDICINE)
 MCI Reg. No.52033

Printed By : Mr AZAD

Created By : Ms. Renuka

Facilities:

All clinical Biomedical & Hematology Investigations including Bone Marrow Examination
VPT, Podiascan & Complete Foot Care (First Time in Purvanchal)
All Hormonal Investigation by Chemiluminescent Method
Visceral Fat by (AB-140) Ambulatory BP Monitoring
CGMS & Insulin Pump Available
PFT, 2D-ECHO (Color Doppler), Holter, TMT, Cardiac-3 available
VIA, VILI, Colposcopy available
Special Endocrinological Investigation Protocols.

ISO 9001:2008 Certified

Mobile: 9389994334, 9554572190, 9453837595

**Panacea Pathology****Clinical Reference Lab**

Persistence, Preparedness and Precision
EQAS (CMC Vellore Attached) & IQAS System
पूर्वांचल की सर्वोत्तम गुणवत्ता वाली पैथोलॉजी

UHID No :- UD-23240007039 **Booking No/Date** :- 57 / 23-Mar-2024 02:28 PM
Patient Name :- Mr ASHISH RANJAN **Age/Sex** :- 35 Y/M
Father :- PARMESHWAR PRASAD GUPTA **OP No** :- OP-23240021605
Address :- SONU MEDICAL AGENCY, MARUFGUNJ ROAD WARD NO- 20 SAHARSA 852201, BIHAR **Mobile No** :- 7800940557
Consultant :- Dr Pallavi Mishra (MBBS,MD)

Investigations Observations Biological Ref. Interval Unit

HAEMATOLOGY**CBC**

HAEMOGLOBIN <i>DefaultMethod / test Machine</i>	14.5	13.00 - 16.00	gm/dl
TLC <i>Methology / Carm</i>	5,800	4000.00 - 11000.00	Cells/cumm.
DLC DIFFERENTIAL LEUCOCYTE COUNT			
NEUTROPHILS	55	40.00 - 75.00	%
LYMPHOCYTES	35	20.00 - 45.00	%
EOSINOPHILS	04	1.00 - 6.00	%
MONOCYTES	06	2.00 - 10.00	%
BASOPHILS	00	<1-2	%
PLATELET COUNT	1.03	1.50 - 4.10	lacs /cumm
PCV	45.7	33.00 - 42.00	%
RBC <i>Methology / Carm</i>	4.81	4.50 - 5.50	million/cumm
MCV(MEAN CELL VOLUME)	94.9	83.00 - 101.00	fl
MCH(MEAN CELL HAEMOGLOBIN)	30.1	27.00 - 32.00	pg
MCHC	31.7	31.50 - 35.00	gm%
RDW-CV	13.1	11.00 - 16.00	%
RDW-SD	50.6	37.00 - 57.00	fl

Consulting Pathologist
DR. UMESH KUMAR
MBBS, MD (PATHOLOGIST)
M.O. Pathology
Reg. No. 41413

Lab Technician

Timing : 24/7 hrs

This Report is not valid for medico legal purpose

Note: These tests have technical limitations. Clinico-pathological interpretation is necessary. In case of any disparity test may be repeated immediately.

Address : 36/44 FK Kabir Nagar, Durgakund, Varanasi – 221005

Email: dramishra@gmail.com, drpallaviojha@gmail.com Website: panaceahospital.org

Facilities:

All clinical Biomedical & Hematology Investigations including Bone Marrow Examination
 VPT, Podiascan & Complete Foot Care (First Time in Purvanchal)
 All Hormonal Investigation by Chemiluminescent Method
 Visceral Fat by (AB-140) Ambulatory BP Monitoring
 CGMS & Insulin Pump Available
 PFT, 2D-ECHO (Color Doppler), Holter, TMT, Cardiac-3 available
 VIA, VILI, Colposcopy available
 Special Endocrinological Investigation Protocols.

ISO 9001:2008 Certified
 Mobile: 9389994334, 9554572190, 9453837595



Panacea Pathology

Clinical Reference Lab

Persistence, Preparedness and Precision
 EQAS (CMC Vellore Attached) & IQAS System
 पूर्वांचल की सर्वोत्तम गुणवत्ता वाली पैथोलॉजी

UHID No :- UD-23240007039 **Booking No/Date** :- 57 / 23-Mar-2024 02:28 PM
Patient Name :- Mr ASHISH RANJAN **Age/Sex** :- 35 Y/M
Father :- PARMESHWAR PRASAD GUPTA **OP No** :- OP-23240021605
Address :- SONU MEDICAL AGENCY, MARUFGUNJ ROAD WARD NO- 20 SAHARSA 852201, BIHAR **Mobile No** :- 7800940557
Consultant :- Dr Pallavi Mishra (MBBS,MD)

URINE EXAMINATION

URINE ROUTINE EXAMINATION

PHYSICAL EXAMINATION

QUANTITY	25		ml
COLOR <i>Methology</i>	STRAW	CLEAR YELLOW	
APPEARANCE <i>DefaultMethod</i>	CLEAR	CLEAR	

CHEMICAL EXAMINATION

SPECIFIC GRAVITY	1.010	1.01 - 1.03	
PH	6.5	4.60 - 8.00	
GLUCOSE	NIL	60.00 - 100.00	mg/dl
PROTEIN-	NIL		

MICROSCOPIC EXAMINATION

PUS CELLS	NIL	2.00 - 3.00	/HPF
RBCS (RED BLOOD CELLS)	NIL	4.50 - 5.50	/HPF
EPITHELIAL CELLS	1-2		/HPF
CASTS	ABSENT	ABSENT	
CRYSTALS	ABSENT	ABSENT	

Consulting Pathologist
DR. UMESH KUMAR
 MBBS, MD (PATHOLOGIST)
 MCD, Reg. No. 41413

Lab Technician

Timing : 24/7 hrs

This Report is not valid for medico legal purpose

Note: These tests have technical limitations. Clinico-pathological interpretation is necessary. In case of any disparity test may be repeated immediately.

Address : 36/44 FK Kabir Nagar, Durgakund, Varanasi – 221005

Email: dramishra@gmail.com, drpallaviojha@gmail.com Website: panaceahospital.org

Facilities:

All clinical Biomedical & Hematology Investigations including Bone Marrow Examination
VPT, Podiascan & Complete Foot Care (First Time in Purvanchal)
All Hormonal Investigation by Chemiluminescent Method
Visceral Fat by (AB-140) Ambulatory BP Monitoring
CGMS & Insulin Pump Available
PFT, 2D-ECHO (Color Doppler), Holter, TMT, Cardiac-3 available
VIA, VILI, Colposcopy available
Special Endocrinological Investigation Protocols.

ISO 9001:2008 Certified

Mobile: 9389994334, 9554572190, 9453837595

**Panacea Pathology****Clinical Reference Lab**

Persistence, Preparedness and Precision
EQAS (CMC Vellore Attached) & IQAS System
पूर्वांचल की सर्वोत्तम गुणवत्ता वाली पैथोलॉजी

UHID No :- UD-23240007039 **Booking No/Date** :- 57 / 23-Mar-2024 02:28 PM
Patient Name :- Mr ASHISH RANJAN **Age/Sex** :- 35 Y/M
Father :- PARMESHWAR PRASAD GUPTA **OP No** :- OP-23240021605
Address :- SONU MEDICAL AGENCY, MARUFGUNJ ROAD WARD NO- 20 SAHARSA 852201 , BIHAR **Mobile No** :- 7800940557
Consultant :- Dr Pallavi Mishra (MBBS,MD)

Investigations	Observations	Biological Ref. Interval	Unit
----------------	--------------	--------------------------	------

HAEMATOLOGY

ESR	12.0	0.00 - 15.00	mm at 1 hr
BLOOD GROUP ABO & RH FACTOR			
BLOOD GROUP	"B"		
RH FACTOR	POSITIVE		
HBA1C -(BY GOLD STANDARD METHOD :HPLC)	6.0	Normal: 4.0 - 5.4 Prediabetic : 5.5 -6.3 Diabetes mellitus := 6.4	%

BIOCHEMISTRY**BLOOD SUGAR FASTING**

GLUCOSE	105.0	60.00 - 100.00	mg/dl
PRE-DIABETICS(IMPAIRED FASTING TOLER)	-	100.00 - 125.00	mg/dl
DIABETICS	-	upto 126	mg/dl
TARGET IN DM	-	80.00 - 130.00	mg/dl

BIOCHEMISTRY

YGGT	16.0	10.00 - 50.00	U/L
URIC ACID			
URIC ACID	4.10	3.60 - 7.70	mg/dl
BUN	12.0	7.00 - 21.00	mg/dl
S.CREATININE	1.05	0.60 - 1.40	mg/dl

Lab Technician

Umesh Kumar
Consulting Pathologist
DR. UMESH KUMAR
MBBS, MD (PATHOLOGIST)
M.D., Pathology 13

Timing : 24/7 hrs

This Report is not valid for medico legal purpose

Note: These tests have technical limitations. Clinico-pathological interpretation is necessary. In case of any disparity test may be repeated immediately.

Address : 36/44 FK Kabir Nagar, Durgakund, Varanasi – 221005

Email: dramishra@gmail.com, drpallaviojha@gmail.com Website: panaceahospital.org

Facilities:

All clinical Biomedical & Hematology Investigations including Bone Marrow Examination
 VPT, Podiascan & Complete Foot Care (First Time in Purvanchal)
 All Hormonal Investigation by Chemiluminescent Method
 Visceral Fat by (AB-140) Ambulatory BP Monitoring
 CGMS & Insulin Pump Available
 PFT, 2D-ECHO (Color Doppler), Holter, TMT, Cardiac-3 available
 VIA, VILI, Colposcopy available
 Special Endocrinological Investigation Protocols.

ISO 9001:2008 Certified

Mobile: 9389994334, 9554572190, 9453837595

**Panacea Pathology****Clinical Reference Lab**

Persistence, Preparedness and Precision
 EQAS (CMC Vellore Attached) & IQAS System
 पूर्वांचल की सर्वोत्तम गुणवत्ता वाली पैथोलॉजी

UHID No :- UD-23240007039 **Booking No/Date** :- 57 / 23-Mar-2024 02:28 PM
Patient Name :- Mr ASHISH RANJAN **Age/Sex** :- 35 Y/M
Father :- PARMESHWAR PRASAD GUPTA **OP No** :- OP-23240021605
Address :- SONU MEDICAL AGENCY, MARUFGUNJ ROAD WARD NO- 20 SAHARSA 852201 , BIHAR **Mobile No** :- 7800940557
Consultant :- Dr Pallavi Mishra (MBBS,MD)

Investigations	Observations	Biological Ref. Interval	Unit
LIPID PROFILE			
TOTAL CHOLESTROL	146.0	Desirable : - < 200 mg/dL Borderline: - 200 - 239 mg/dL High : - > 240mg/dL	mg/dl
TRIGLYCERIDES	139.0	35.00 - 160.00	mg/dl
HDL CHOLESTROL	41.0	35.30 - 79.50	mg/dl
LDL CHOLESTROL	77.2	<130	mg/dl
VLDL	27.80	<40	mg/dl
CHOLESTROL/ HDL RATIO	3.56	<3.0 LOW RISK, 3.0-5.0 AVG RISK, >5.0 HIGH RISK	ratio
LDL/HDL RATIO	1.88	<3	ratio
LFT (LIVER FUNCTION TESTS)			
TOTAL BILIRUBIN	0.62	0.00 - 1.20	mg/dl
DIRECT BILIRUBIN	0.22	0.00 - 0.30	
INDIRECT BILIRUBIN	0.40	0.20 - 0.70	mg/dl
SGOT	21.0	2.00 - 31.00	U/L
SGPT	22.0	10.00 - 45.00	U/L
ALKALINE PHOSPHATASE	74.0	25.00 - 140.00	U/L
TOTAL PROTIENS	6.92	6.60 - 8.70	g/dl

Lab Technician

Consulting Pathologist
 DR. UMESH KUMAR
 M.D., M.C. (PATHOLOGIST)
 M.D., Pathology

Timing : 24/7 hrs

This Report is not valid for medico legal purpose

Note: These tests have technical limitations. Clinico-pathological interpretation is necessary. In case of any disparity test may be repeated immediately.

Address : 36/44 FK Kabir Nagar, Durgakund, Varanasi - 221005

Email: dramishra@gmail.com, drpallaviojha@gmail.com Website: panaceahospital.org

Facilities:

All clinical Biomedical & Hematology Investigations including Bone Marrow Examination
 VPT, Podiascan & Complete Foot Care (First Time in Purvanchal)
 All Hormonal Investigation by Chemiluminescent Method
 Visceral Fat by (AB-140) Ambulatory BP Monitoring
 CGMS & Insulin Pump Available
 PFT, 2D-ECHO (Color Doppler), Holter, TMT, Cardiac-3 available
 VIA, VILI, Colposcopy available
 Special Endocrinological Investigation Protocols.

ISO 9001:2008 Certified

Mobile: 9389994334, 9554572190, 9453837595

**Panacea Pathology****Clinical Reference Lab**

Persistence, Preparedness and Precision
 EQAS (CMC Vellore Attached) & IQAS System
 पूर्वांचल की सर्वोत्तम गुणवत्ता वाली पैथोलॉजी

UHID No :- UD-23240007039 **Booking No/Date** :- 57 / 23-Mar-2024 02:28 PM
Patient Name :- Mr ASHISH RANJAN **Age/Sex** :- 35 Y/M
Father :- PARMESHWAR PRASAD GUPTA **OP No** :- OP-23240021605
Address :- SONU MEDICAL AGENCY, MARUFGUNJ ROAD WARD NO- 20 SAHARSA 852201 , BIHAR **Mobile No** :- 7800940557
Consultant :- Dr Pallavi Mishra (MBBS,MD)

Investigations	Observations	Biological Ref. Interval	Unit
ALBUMIN	3.80	3.50 - 5.20	gm%
GLOBULIN	3.12	1.50 - 3.60	gms/dl
A/G RATIO	1.21	2:1	RATIO

IMMUNOLOGY**THYROID PROFILE (T3,T4,TSH)**

T3	0.91	0.60 - 1.81	ng/ml
T4	6.5	4.50 - 10.90	ug/dl
TSH	1.01	0.39 - 6.10	uIU/mL

PARASITOLOGY**STOOL ROUTINE****GROSS EXAMINATION**

COLOR <i>Methology</i>	YELLOW	CLEAR YELLOW
CONSISTANCY	NORMAL	
BLOOD	ABSENT	
MUCUS	ABSENT	

MICROSCOPIC EXAMINATION

OVA OR EGGS OF HELMINTHS	ABSENT
--------------------------	--------

Lab Technician

Consulting Pathologist
 DR. UMESH KUMAR
 MBBS, MD (PATHOLOGIST)
 MCI Reg. No. 41413

Timing : 24/7 hrs

This Report is not valid for medico legal purpose

Note: These tests have technical limitations. Clinico-pathological interpretation is necessary. In case of any disparity test may be repeated immediately.

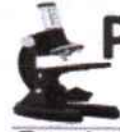Address : 36/44 FK Kabir Nagar, Durgakund, Varanasi – 221005

Email: dramishra@gmail.com, drpallaviojha@gmail.com Website: panaceahospital.org

Facilities:

All clinical Biomedical & Hematology Investigations including Bone Marrow Examination
 VPT, Podiascan & Complete Foot Care (First Time in Purvanchal)
 All Hormonal Investigation by Chemiluminescent Method
 Visceral Fat by (AB-140) Ambulatory BP Monitoring
 CGMS & Insulin Pump Available
 PFT, 2D-ECHO (Color Doppler), Holter, TMT, Cardiac-3 available
 VIA, VILI, Colposcopy available
 Special Endocrinological Investigation Protocols.

ISO 9001:2008 Certified
 Mobile: 9389994334, 9554572190, 9453837595



Panacea Pathology

Clinical Reference Lab

Persistence, Preparedness and Precision
 EQAS (CMC Vellore Attached) & IQAS System
 पूर्वांचल की सर्वोत्तम गुणवत्ता वाली पैथोलॉजी

UHID No :- UD-23240007039 **Booking No/Date** :- 57 / 23-Mar-2024 02:28 PM
Patient Name :- Mr ASHISH RANJAN **Age/Sex** :- 35 Y/M
Father :- PARMESHWAR PRASAD GUPTA **OP No** :- OP-23240021605
Address :- SONU MEDICAL AGENCY, MARUFGUNJ ROAD WARD NO- 20 SAHARSA 852201 , BIHAR **Mobile No** :- 7800940557
Consultant :- Dr Pallavi Mishra (MBBS,MD)

Investigations	Observations	Biological Ref. Interval	Unit
CYST OF PROTOZOA	ABSENT		
VEG. FORMS OF PROTOZOA	ABSENT		
PUS CELLS	04-05	2.00 - 3.00	/HPF
RBC <i>Methology / Carm</i>	NIL	4.50 - 5.50	million/cumm

* END OF REPORT *

Lab Technician


Timing : 24/7 hrs

This Report is not valid for medico legal purpose

Note: These tests have technical limitations. Clinico-pathological interpretation is necessary. In case of any disparity test may be repeated immediately.

Address : 36/44 FK Kabir Nagar, Durgakund, Varanasi – 221005

Email: dramishra@gmail.com, drpallaviojha@gmail.com **Website:** panaceahospital.org


 Consulting Pathologist
 DR. UMESH KUMAR
 MBBS, MD (PATHOLOGIST)
 M.D. Pathology
 Reg. No. 41413



Call Now - 1800-123-3070

PANACEA HOSPITAL



A shelter for many hearts A Home for many lives
(An ISO 9001:2008 Certified Organisation)
Lab Attached with CMC Under EQAS Scheme

Dept. of Radiodiagnosis - 32 Slice CT Scan, 3D/4D USG, 2D ECHO, Colour Doppler, Intervention Procedures, Digital X-Ray

PATIENT'S NAME : ASHISH RANJAN	AGE/SEX : M
REF. BY : Dr. ASHUTOSH MISHRA(MD)	DATE : 23/03/2024

X-RAY CHEST (PA VIEW)

- Bilateral lung fields appear normal.
- Trachea and mediastinum appear normal in position.
- Both hila appear normal in size and are symmetrical.
- Transverse cardiac diameter is within normal limits.
- Great vessels appear normal
- Both CP angles appear clear. Normal position and contour diaphragms noted.
- Bony rib cage and soft tissue shadows appear normal.

IMPRESSION

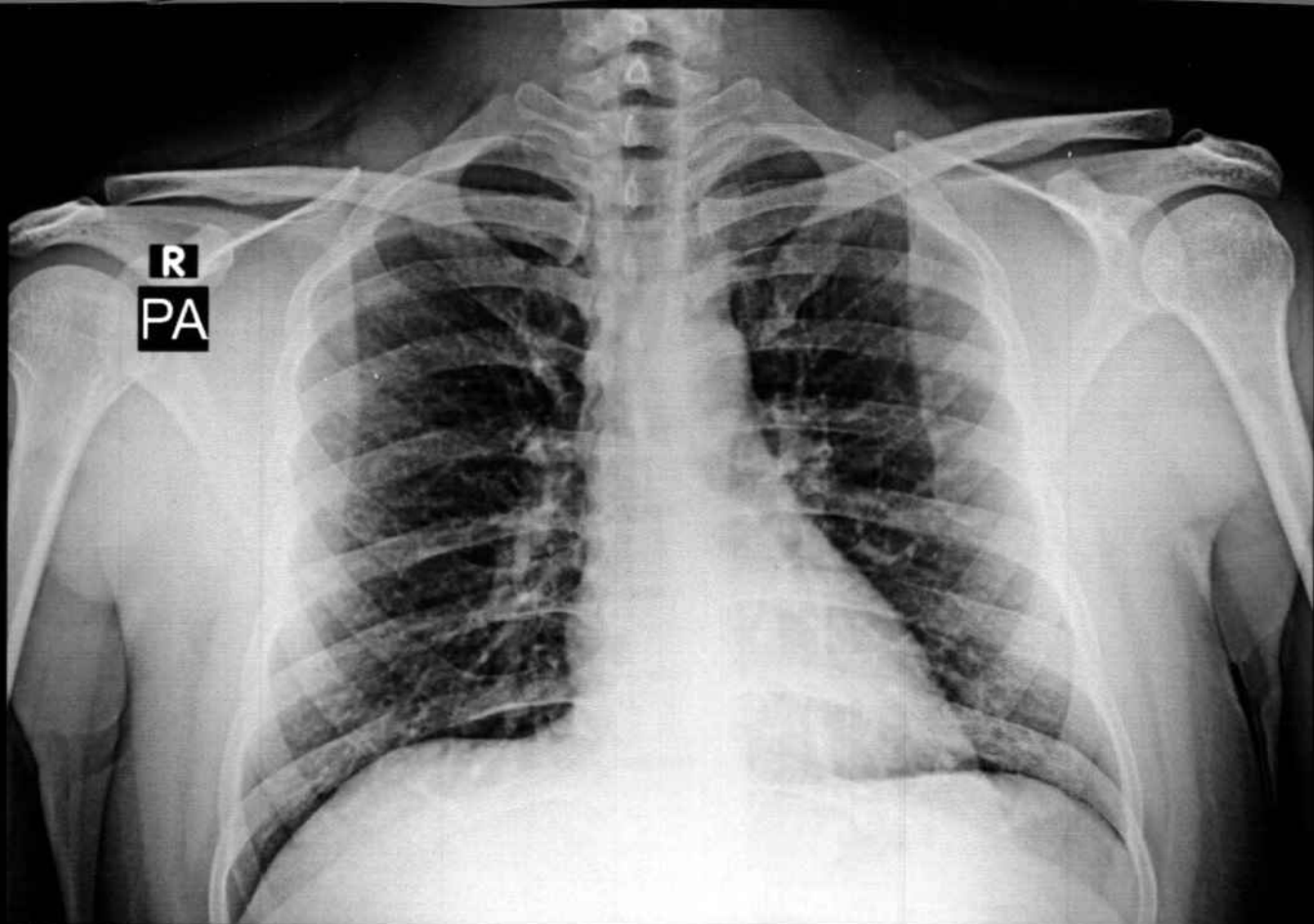
- **No obvious abnormality noted in the chest radiograph.**

Thanks for reference.

Radiologist
Dr. Rahul Kumar Tiwari
MBBS, MD (Radio Diagonosis)
Reg. No. 57557

Disclaimer: This report is not valid for Madicolegal or Judicial Purpose. Radiological diagnosis is solely interpretation of images produced by tissue & may not be always conclusive.

Address : B36/44 B4 Kabir Nagar (Near Sanjay Shiksha Niketan), Durgakund, Varanasi
Mobile : 9554572190 / 9453837595 / Recpn, 9389994334
Email : dramishra@gmail.com, drpallaviojha@gmail.com, Website : www.piire.org



ASHISH RANJAN 35Y/M 7039 M CHEST P.A. 23-Mar-24 10:41 AM

PANACEA HOSPITAL, KABIR NAGAR, DURGAKUND, VARANASI



Call Now - 1800-123-3070

PANACEA HOSPITAL



A shelter for many hearts A Home for many lives
(An ISO 9001:2008 Certified Organisation)
Lab Attached with CMC Under EQAS Scheme

Dept. of Radiodiagnosis - 32 Slice CT Scan, 3D/4D USG, 2D ECHO, Colour Doppler, Intervention Procedures, Digital X-Ray

NAME: ASHISH RANJAN
REF.DR. DR.ASHUTOSH MISHRA(MD)

AGE/SEX: 35 YRS/MALE
DATE: 23/03/2024

ULTRA SOUND WHOLE ABDOMEN REPORT

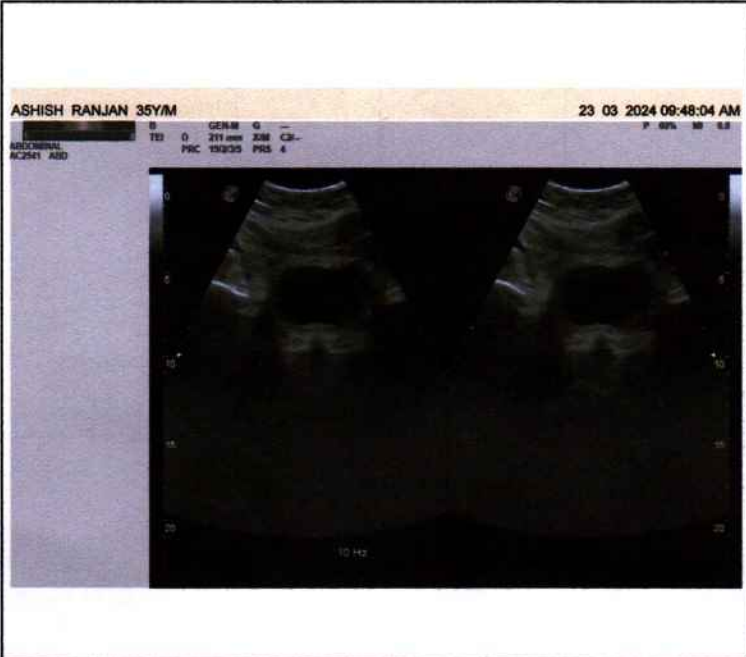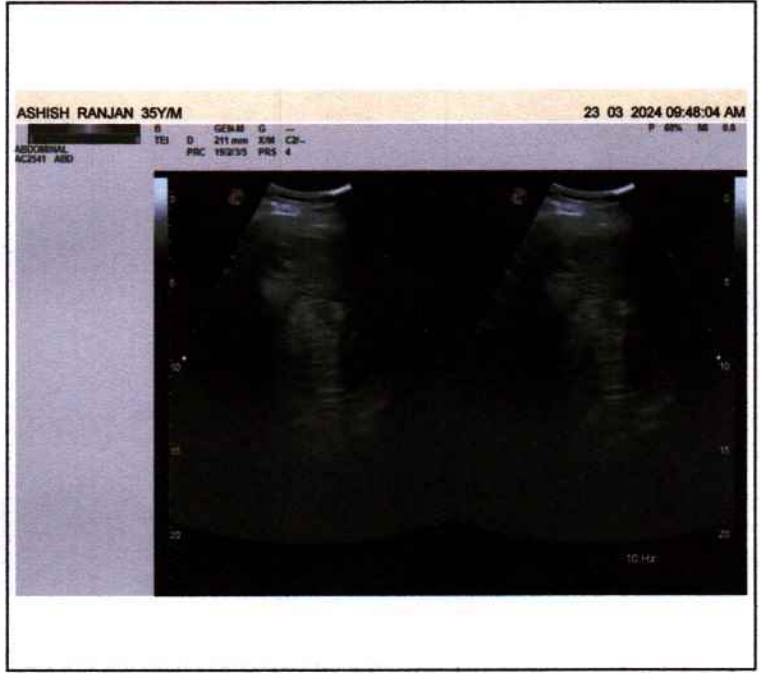
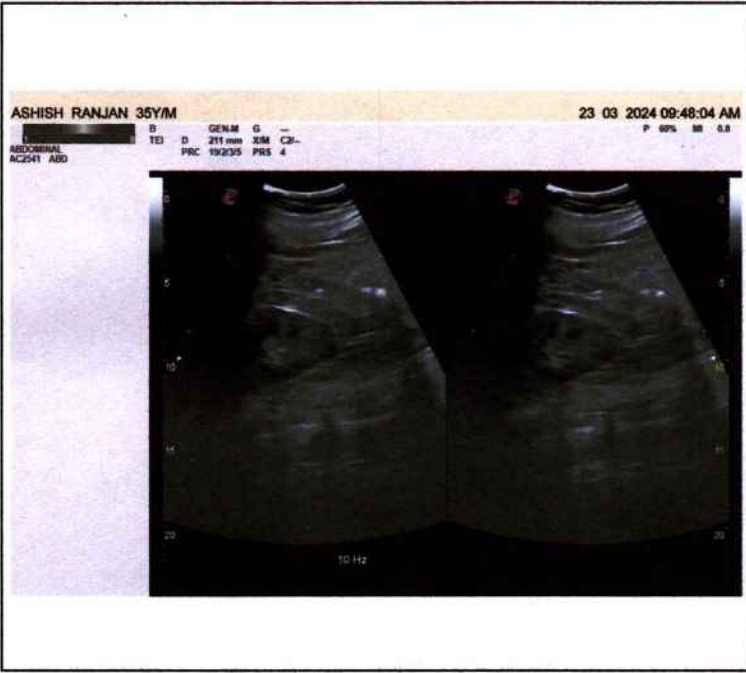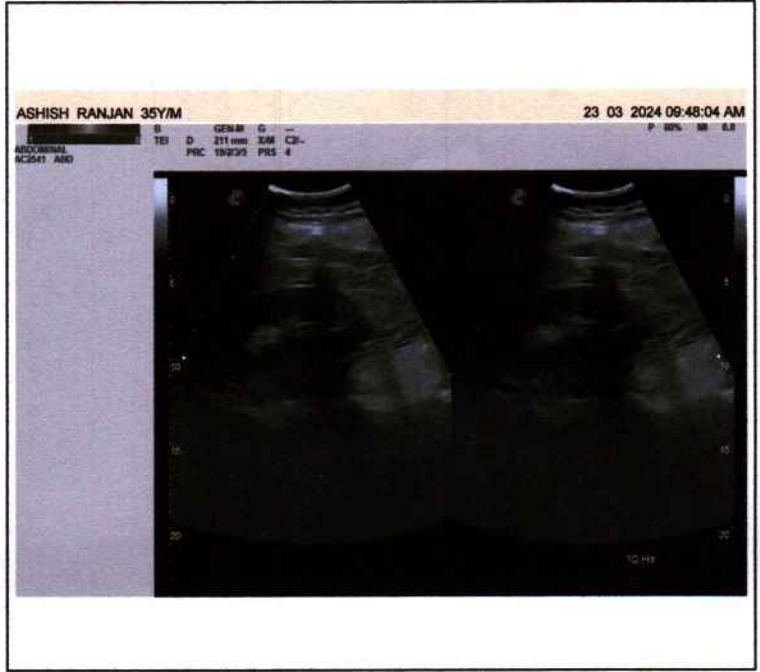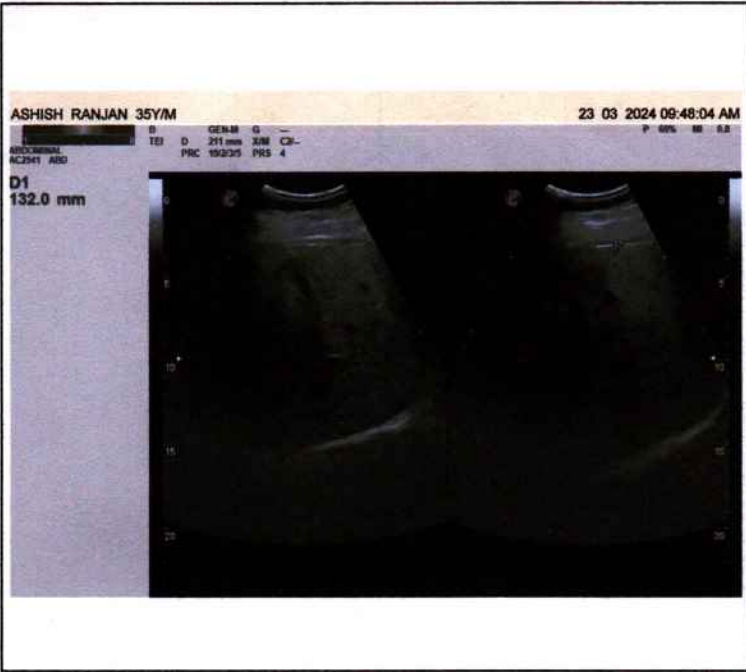- Liver:** Normal in size, shape & echogenicity. Intra & extra hepatic biliary Radicals & Vascular structures are normal. Margins are smooth and regular.
- Gall bladder:** Normally distended with echo free lumen.
- Portal vein:** Normal in course and caliber.
- CBD diameter:** Visualized part normal in course & caliber.
- Pancreas:** Normal in size, shape & echogenicity. Margins are smooth & regular. No diffuse/ focal lesion seen. Pancreatic duct not visualized.
- Spleen:** Normal in size, shape & echogenicity. Margins are smooth & regular.
No diffuse / focal lesion seen. Splenic vessels at hilum is normal.
- Kidney:** Both normal in size, shape echogenicity & position. Cortical-medullary differentiation is maintained. Pelvicalyceal system normal. No evidence of any calculus/mass lesion seen
No hydronephrosis/ hydroureter seen. No suprarenal mass lesion.
- Urinary bladder:** Normally distended with normal wall thickness. No echogenic foci lumen or diverticula seen.
Both VUJ appears normal. No evidence of calculus / mass lesion seen.
- Prostate:** Normal in size, shape & echogenicity.
- Others:** No free fluid in peritoneal cavity.
No free fluid in bilateral pleural cavity.
No evidence of significantly enlarged retroperitoneal/ mesenteric lymph nodes noted.
- IMPRESSION:** **NO OBVIOUS SONOLOGICAL ABNORMALITY SEEN.**

Please correlate clinically and further investigations.


Sonologist
Dr. Ravi Kumar Tiwari
MBBS, MD (Radio Diagonosis)
Reg. No. 57557

Disclaimer: This report is not valid for Madicolegal or Judicial Purpose. Radiological diagnosis is solely interpretation of images produced by tissue & may not be always conclusive.

Address : B36/44 B4 Kabir Nagar (Near Sanjay Shiksha Niketan), Durgakund, Varanasi
Mobile : 9554572190 / 9453837595 / Recpn, 9389994334
Email : dramishra@gmail.com, drpallaviojha@gmail.com, Website : www.piire.org





Call Now - 1800-123-3070

PANACEA HOSPITAL



A shelter for many hearts A Home for many lives
(An ISO 9001:2008 Certified Organisation)
Lab Attached with CMC Under EQAS Scheme

Dept. of Radiodiagnosis - 32 Slice CT Scan, 3D/4D USG, 2D ECHO, Colour Doppler, Intervention Procedures, Digital X-Ray


NAME: MR. ASHISH RANJAN**AGE/SEX: 35Y/YRS/MALE****REF BY: DR. ASHUTOSH MISHRA (MD)****DATE: 23/03/2024****Echo - Cardiography**

MITRAL VALVE Doppler	AML - Normal morphology MV Flow - E - 0.7 A-0.4 E/A=1.56	PML - Normal morphology MVA - 3.0 cm ² Mitral Regurgitation - No
TRICUSPID VALVE Doppler	Normal TV Flow - No	Tricuspid Regurgitation - No
PULMONARY VALVE Doppler	Normal PV Flow - No	Pulmonary Regurgitation - No
AORTIC VALVE Doppler	Trileaflet-No AV Flow - no	Aortic Regurgitation - No
MEASUREMENT	Aorta - 27.4 (20-38) mm IVS ed - 9.1 (6-12) mm LVID ed - 51.4 (35-55) mm LVPW ed - 11.4 (6-12) mm OA - 1.2 (> 5) mm	LA - 36.6 (24-32) mm IVS es - 15.4 (6-12) mm LVID es - 34.3 (24-40) mm LVPW es - 17.1 (6-12) mm EPSS - 4 (< 9) mm

CONCLUSION All cardiac chamber dimensions are WNL
No valvular abnormalities
Good LV systolic function present Modified Simpson's method (4C, 2C) (LVEF-62%)
No diastolic dysfunction present (E/A = 1.56)
No RWMA
No pericardial effusion
Intact IAS / IV
No PAH
No intra cardiac mass /thrombus /vegetation

IMPRESSION Normal Echocardiogram


Niraj Mishra
Physician Assistant
(PIIRE)


Dr. Pallavi Mishra
MBBS, MD (GENERAL MEDICINE)
Echocardiography Specialist, MCh
Non-invasive cardiologist
Women Cardiologist
MCI Reg. No. 52033
Diabetocardiologist

Disclaimer: This report is not valid for Medicolegal or Judicial Purpose. Radiological diagnosis is solely interpretation of images produced by tissue & may not be always conclusive.

Address : B36/44 B4 Kabir Nagar (Near Sanjay Shiksha Niketan), Durgakund, Varanasi

Mobile : 9554572190 / 9453837595 / Recpn, 9389994334

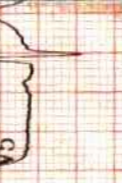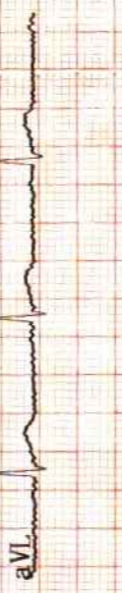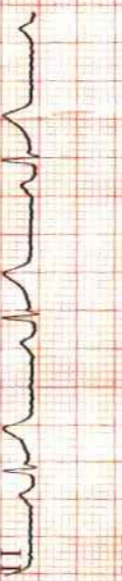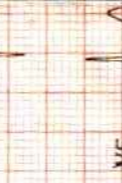

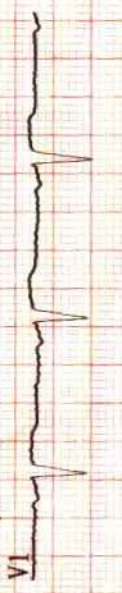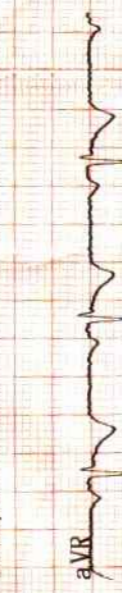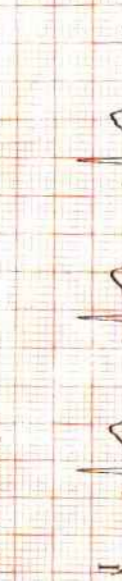Email : dramishra@gmail.com, drpallaviojha@gmail.com, Website : www.piire.org

AUTO 10mm/mV

10mm/mV

10mm/mV

10mm/mV



25mm/s AC50Hz+EMG35Hz+DFT

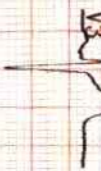
10mm/mV

10mm/mV

10mm/mV

2024-03-23 12:53


<< Conclusions >>



25mm/s

ID :
 Name : **Ashish Raygor**
 Sex : **M** Age : **35**
 Height : **153** Weight : **76** kg **Report need physician confirm**
 SYS :
 DIA :
 HR [bpm] : 73
 PR Interval [ms] : 164
 P Duration [ms] : 120
 QRS Duration [ms] : 69
 T Duration [ms] : 166
 QT/QTc [ms] : 329/361
 P/QRS/T Axis [deg] : 69.7/19.0/46.6
 R(V5)/S(V1) [mV] : 0.94/0.68
 R(V5)+S(V1) [mV] : 1.61

Normal Sinus Rhythm;
 Longitudinal Left axis deviation;


Dr. Pallavi Misra
 MD (GENERAL MEDICINE)
 MIBBS, MCI Reg. No.52033

Physician