



To,

The Coordinator,
Mediwheel (Arcofemi Healthcare Limited)
Helpline number: 011- 41195959

Dear Sir / Madam,

Sub: Annual Health Checkup for the employees of Bank of Baroda

This is to inform you that the following spouse of our employee wishes to avail the facility of Cashless Annual Health Checkup provided by you in terms of our agreement.

PARTICULARS OF HEALTH CHECK UP BENEFICIARY	
NAME	NIMAGNA PATRA
DATE OF BIRTH	17-06-1971
PROPOSED DATE OF HEALTH CHECKUP FOR EMPLOYEE SPOUSE	24-07-2021
BOOKING REFERENCE NO.	21S73190100001308S
SPOUSE DETAILS	
EMPLOYEE NAME	MR. PATRA AMULYA KUMAR
EMPLOYEE EC NO.	73190
EMPLOYEE DESIGNATION	HEAD CASHIER "E" _II
EMPLOYEE PLACE OF WORK	BERHAMPUR,BRAJANAGAR
EMPLOYEE BIRTHDATE	15-04-1970

This letter of approval / recommendation is valid if submitted along with copy of the Bank of Baroda employee id card. This approval is valid from **20-07-2021** till **31-03-2022**. The list of medical tests to be conducted is provided in the annexure to this letter. Please note that the said health checkup is a **cashless facility** as per our tie up arrangement. We request you to attend to the health checkup requirement of our employee's spouse and accord your top priority and best resources in this regard. The EC Number and the booking reference number as given in the above table shall be mentioned in the invoice, invariably.

We solicit your co-operation in this regard.

Yours faithfully,

Sd/-

**Chief General Manager
HRM Department
Bank of Baroda**

(Note: This is a computer generated letter. No Signature required. For any clarification, please contact Mediwheel (Arcofemi Healthcare Limited))



बैंक ऑफ बड़ोदा
Bank of Baroda



नाम
Name **AMULYA KUMAR PATRA**

कर्मचारी कूट क्र.
E.C. No **73190**



अधीनस्थ अधिकारी-उप क्षेत्राधिकार
Issuing Authority - D.G.M.
Odisha Region

होल्डर का हस्ताक्षर
Signature of Holder



New
NEELACHALA HOSPITAL

A Promise for Life...

(AN ISO 9001 : 2008 CERTIFIED HOSPITAL)

NAME	NIMAGNA PATRA	Age/Sex	50Yrs/F
Ref. By.	New Neelachala Hospital	EC No.	73190
Sample.Dt.	24-07-2021	Reporting Dt	26-07-2021

HAEMOGRAM REPORT

<u>INVESTIGATION</u>	<u>RESULT</u>	<u>UNIT</u>	<u>NORMAL VALUE</u>
Hb%	12.7	gm%	(11.0 - 15.0 gm%)
TWBC	7800	Cumm	(4500-11000/ Cumm)
TRBC	4.1	Mill	(4.0- 5.5 Mill/ Cumm)
TPC	2.0	Lacs / Cumm	(1.5 - 4.0 Lacs / Cumm)
PCV	40	%	(35- 50%)
MCV	81	fl	(76 - 96 fl)
MCH	29.2	pg	(28 - 32 pg)
MCHC	32.6	%	(28 - 43%)
RDW (CV)	14.1	%	(13 - 16%)
MPV	8.6	fl	(8.0 - 10.5 fl)
PDW	8.8	fl	(8.2 - 10.0 fl)

DIFFERENTIAL COUNT

<u>INVESTIGATION</u>	<u>RESULT</u>	<u>UNIT</u>	<u>NORMAL VALUE</u>
Neutrophil	64	%	40 - 70
Eosinophil	03	%	01 - 06
Basophil	00	%	00 - 01
Lymphocyte	27	%	15 - 40
Monocyte	06	%	02 - 10

<u>INVESTIGATION</u>	<u>RESULT</u>	<u>UNIT</u>	<u>NORMAL VALUE</u>
ESR	15	/mm in 1 st hour	05 - 20


Swayam Prava Pradhan
MD Pathologist
Regd. No.9431

N. B. : THIS REPORT IS NOT MEANT FOR MEDICO LEGAL PURPOSE

KAMAPALI - GOILUNDI LINK ROAD, NEAR NANDIGHOSH APARTMENT, BERHAMPUR - 760 004 (ODISHA)
CELL : 9438251721, 9337859729



New
NEELACHALA HOSPITAL

A Promise for Life...

(AN ISO 9001 : 2008 CERTIFIED HOSPITAL)

NAME	NIMAGNA PATRA	Age/Sex	50Yrs/F
Ref. By.	New Neelachala Hospital	EC No.	73190
Sample.Dt.	24-07-2021	Reporting Dt	26-07-2021

URINE ANALYSIS REPORT

PHYSICAL EXAMINATION

VOLUME	:	10 ML.
SPECIFIC GRAVITY	:	1.015
COLOUR	:	PALE YELLOW.
APPEARANCE	:	CLEAR.
TURBIDITY	:	ABSENT.
SEDIMENT	:	ABSENT.
REACTION	:	ACIDIC.

CHEMICAL EXAMINATION

ALBUMIN	:	ABSENT.
SUGAR	:	NIL.
PHOSPHATE	:	ABSENT.
ACETONE	:	ABSENT.
BILE SALT	:	ABSENT.
BILE PIGMENT	:	NEGATIVE.
UROBILINOGEN	:	ABSENT.
CHYLE	:	ABSENT.
HAEMATURIA	:	ABSENT.

MICROSCOPIC EXAMINATION

EPITHELIAL CELL	:	1 - 5/ H.P.F
PUS CELL	:	2 - 4 / H.P.F
R.B.C	:	NIL.
CAST	:	NIL.
CRYSTAL	:	NIL.
YEAST	:	ABSENT.
OTHERS	:	ABSENT

Swayam Prava Pradhan
Signature
MD Pathologist
Regd. No.9431

N. B. : THIS REPORT IS NOT MEANT FOR MEDICO LEGAL PURPOSE

KAMAPALI - GOILUNDI LINK ROAD, NEAR NANDIGHOSH APARTMENT, BERHAMPUR - 760 004 (ODISHA)
CELL : 9438251721, 9337859729



New
NEELACHALA HOSPITAL


A Promise for Life...

(AN ISO 9001 : 2008 CERTIFIED HOSPITAL)

NAME	NIMAGNA PATRA	Age/Sex	50Yrs/F
Ref. By.	New Neelachala Hospital	EC No.	73190
Sample.Dt.	24-07-2021	Reporting Dt	26-07-2021

STOOL ANALYSIS REPORT

COLOUR :- Yellow
CONSISTENCY :- Pesty
REACTION :- Acidic
MUCUS :- Absent
BLOOD :- Absent
PARASITS :- Adequate
R.B.C. :- Not Seen
VEG.CELLS :- Present
STARCH :- Not Seen
MICROPHAGES :- Not Seen
FAT GLOBULES :- Not Seen
BACTERIAL FLORA :- Reduced.
YEAST/MOULDS :- Not Seen
SUGAR :- Not Seen
OVA/LARVA OF HELMINTUS:- Not Seen
CYST.VEG FORMS PROTOZOA:- Not Seen
OCCULT BLOOD :- Not Seen
PROTOZOA (Cysts/Trohozoites) :- Not Seen
HELMINTHES (Ova/Larva) :- Not Seen


Signature
MD Pathologist
Regd. No.9431

N. B. : THIS REPORT IS NOT MEANT FOR MEDICO LEGAL PURPOSE

KAMAPALI - GOILUNDI LINK ROAD, NEAR NANDIGHOSH APARTMENT, BERHAMPUR - 760 004 (ODISHA)
CELL : 9438251721, 9337859729



New
NEELACHALA HOSPITAL

A Promise for Life...

(AN ISO 9001 : 2008 CERTIFIED HOSPITAL)


NAME	NIMAGNA PATRA	Age/Sex	50Yrs/F
Ref. By.	New Neelachala Hospital	EC No.	73190
Sample.Dt.	24-07-2021	Reporting Dt	26-07-2021

BIOCHEMICAL TEST

<u>TEST</u>	<u>OBSERVED VALUE</u>	<u>UNIT</u>	<u>NORMAL VALUE</u>
Fasting Blood Sugar	82.6	mg/dl	70 - 110
Fasting Urine Sugar	0.3	mmol/L	0 - 0.8
2H PPBS	86	mg/dl	> 140
PP Urine Sugar	05	mg/dl	0 - 15
Serum Uric Acid	5.3	mg/dl	3.4 - 7.0
Serum Creatinine	0.9	mg/dl	0.0 - 1.2
Blood Urea Nitrogen	14.3	mg/dl	07 - 20
BUN Ratio	15.9		

LIPID PROFILE

<u>TEST</u>	<u>OBSERVED VALUE</u>	<u>UNIT</u>	<u>NORMAL VALUE</u>
Cholesterol	149	mg/dl	130 - 220
Triglycerides	106	mg/dl	50 - 160
HDL Cholesterol	46.2	mg/dl	35 - 70
LDL Cholesterol	81.6	mg/dl	60 - 130
VLDL	28	mg/dl	25 - 50
Cholesterol/HDL Ratio	3.22	mg/dl	< 4.5
LDL/HDL Ratio	1.76		


Swayan Prava Pradhan
MD Pathologist
Regd. No.9431

N. B. : THIS REPORT IS NOT MEANT FOR MEDICO LEGAL PURPOSE

KAMAPALI - GOILUNDI LINK ROAD, NEAR NANDIGHOSH APARTMENT, BERHAMPUR - 760 004 (ODISHA)
CELL : 9438251721, 9337859729



New
NEELACHALA HOSPITAL

A Promise for Life...

(AN ISO 9001 : 2008 CERTIFIED HOSPITAL)

NAME	NIMAGNA PATRA	Age/Sex	50Yrs/F
Ref. By.	New Neelachala Hospital	EC No.	73190
Sample.Dt.	24-07-2021	Reporting Dt	26-07-2021

LIVER FUNCTION TEST (L.F.T)

<u>TEST</u>	<u>OBSERVED VALUE</u>	<u>UNIT</u>	<u>NORMAL VALUE</u>
Total Protein	6.3	g/dl	5.5 - 8.0
Albumin	4.2	g/dl	3.5 - 5.0
Globulin	2.09	g/dl	2.0 - 3.0
A/G Ratio	2.0		
S.G.O.T	21	IU/L	5 - 40
S.G.P.T	25	IU/L	5 - 50
G.G.T.P	22	mg/dl	15 - 40
Serum Bilirubin (Total)	0.7	mg/dl	0.3 - 1.0
(Direct)	0.2	mg/dl	0.0 - 0.3
(Indirect)	0.5	mg/dl	0.2 - 0.8
Alkaline Phosphate	119	IU/ML	60 - 170

Thyroid Test

<u>TEST</u>	<u>OBSERVED VALUE</u>	<u>UNIT</u>	<u>NORMAL VALUE</u>
T3	1.10	ng/mL	0.6 - 1.81
T4	8.75	ug/dl	4.61 - 14.94
TSH	3.92	IU/ml	0.35 - 5.5

<u>TEST</u>	<u>OBSERVED VALUE</u>	<u>UNIT</u>	<u>NORMAL VALUE</u>
HBA1C	5.4	%	below 6.0%-Normal Value 6.0%-7.0%-Good control 7.0%-8.0%-Fair Control 8.0%-10%-Unsatisfactory Control Above 10%-Poor Control

Swayam Prava Pradhan
Signature
MD Pathologist
Regd. No.9431

N. B. : THIS REPORT IS NOT MEANT FOR MEDICO LEGAL PURPOSE

KAMAPALI - GOILUNDI LINK ROAD, NEAR NANDIGHOSH APARTMENT, BERHAMPUR - 760 004 (ODISHA)
CELL : 9438251721, 9337859729

Resting ECG Report

Patient Name Mrs. Nimagna Patra 50/F

July 24, 2021

Time: 12:01:21

Page No. []

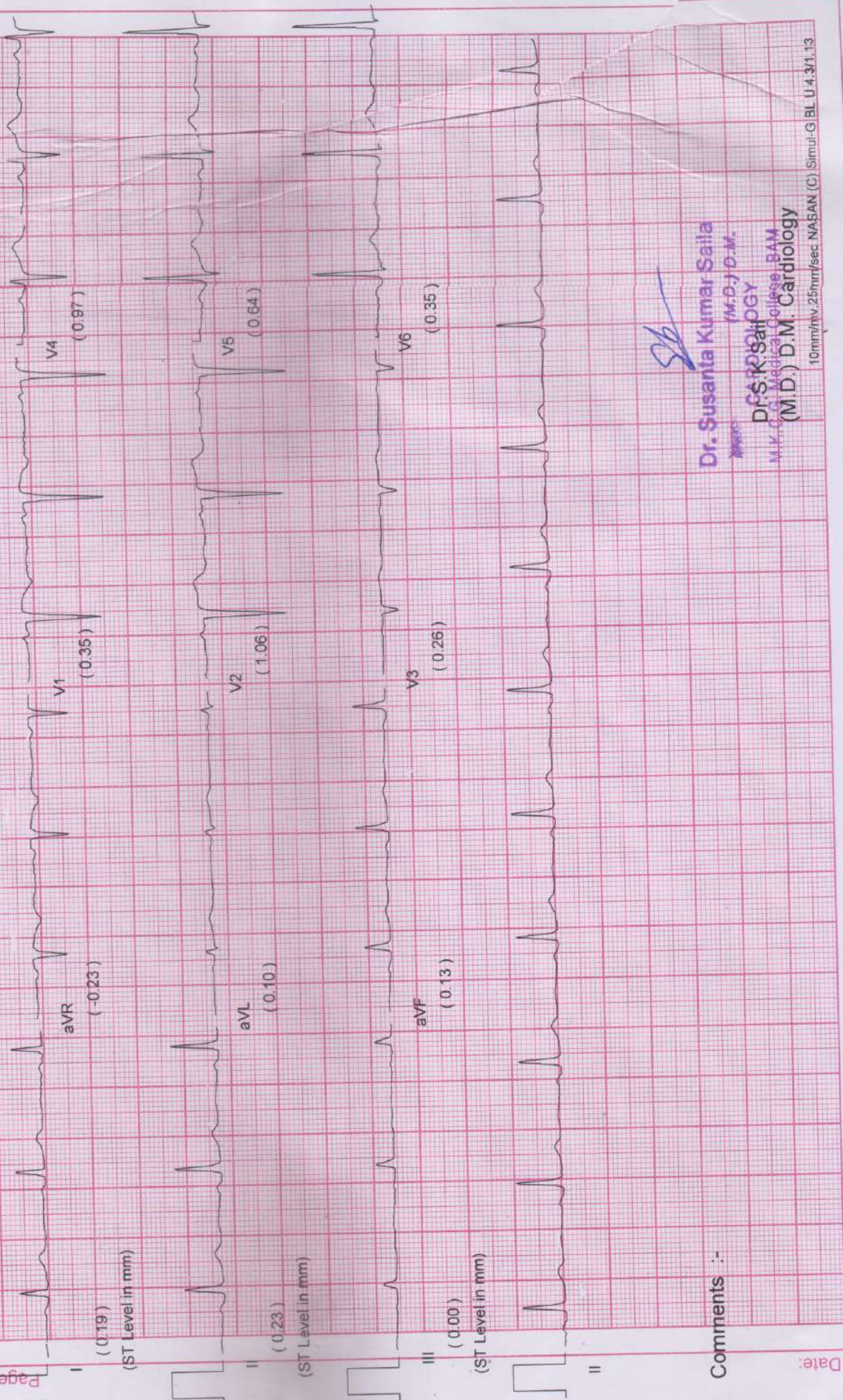
QT/QTc: 0.328 / 0.337 Sec
P-QRS-T Axis (38)-(43)-(22) deg

PR Interval: 0.13 sec
RR Interval: 0.94 sec
QRS Duration: 0.108 Sec

BP 0 / 0 mmHg

63 b.m

HR



Sb

Dr. Susanta Kumar Saita
(M.D.) D.M.

Dr. S. K. Saita
(M.D.) D.M.

M.K. G. Medical College, BAM
(M.D.) D.M. Cardiology

10mm/mv, 25mm/sec NASAN (C) Simul-G BL U.4.3/1.13

Comments :-

Date:



BHABANI DIAGNOSTIC CENTRE

Goilundi-Kamapalli Road,
Infront of Nandighos Apartment, Brahmapur
Mob. : 9078214639, 7008833151

PATIENT NAME : Mrs... NIMAGNA PATRA AGE :50Yrs SEX: F
REFERRED BY :NEELANCHAL HOSPITAL DATE: 24-Jul-21....

ULTRASOUND EXAMINATION OF WHOLE ABDOMEN

LIVER:

Normal in size & measures 12.0cm
Normal parenchymal echotexture. No focal lesion or IHBR Dilatation is seen.
P.V—normal.

GALL BLADDER:

Normal in shape and size with anechoic lumen.
Wall thickness is normal. CBD-normal.

PANCREAS:

Normal in size & outline. Parenchymal echo is normal. Pancreatic duct is not dilated.

KIDNEYS:

Rt. Kidney: Normal in shape and size-9.9.x3.7 cm.
Parenchymal echogenicity is normal. Cortical thickness is normal.
Cortico medullary differentiation is well maintained.
Collecting system appears normal.
No evidence of calculus or any pathological abnormalities is seen.

Lt. Kidney: Normal in shape and size-9.4x4.0cm..
Parenchymal echogenicity is normal. Cortical thickness is normal.
Cortico medullary differentiation is well maintained.
Collecting system appears normal.
No evidence of calculus or any pathological abnormalities is seen.

SPLEEN:

Normal in size & measures 7.9 cm
Parenchymal echogenicity appears normal.

URINARY BLADDER:

Normal in outline. Wall thickness is normal. .

UTERUS:


Atrophied in size(Postmenopausal status) .

OVARIES:

Both ovaries could not be visualized .
No fluid is seen in peritoneal cavity.

IMPRESSION

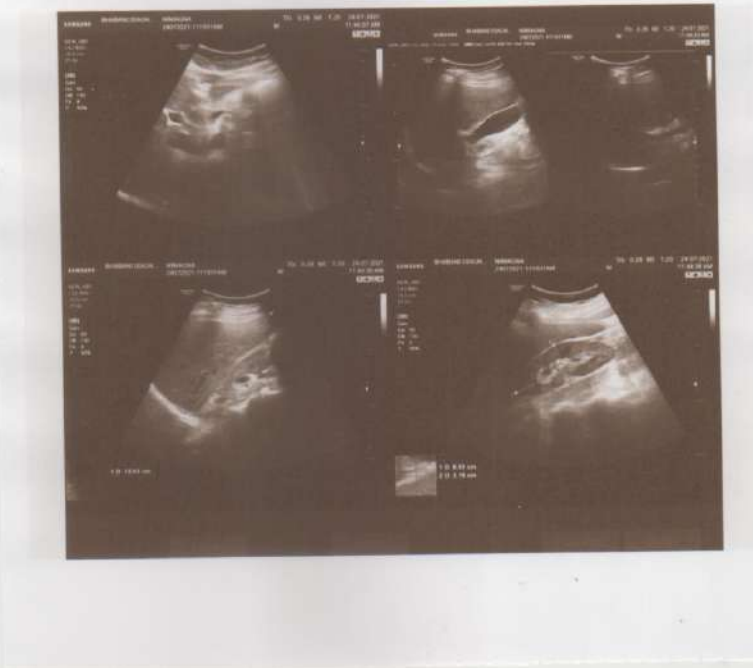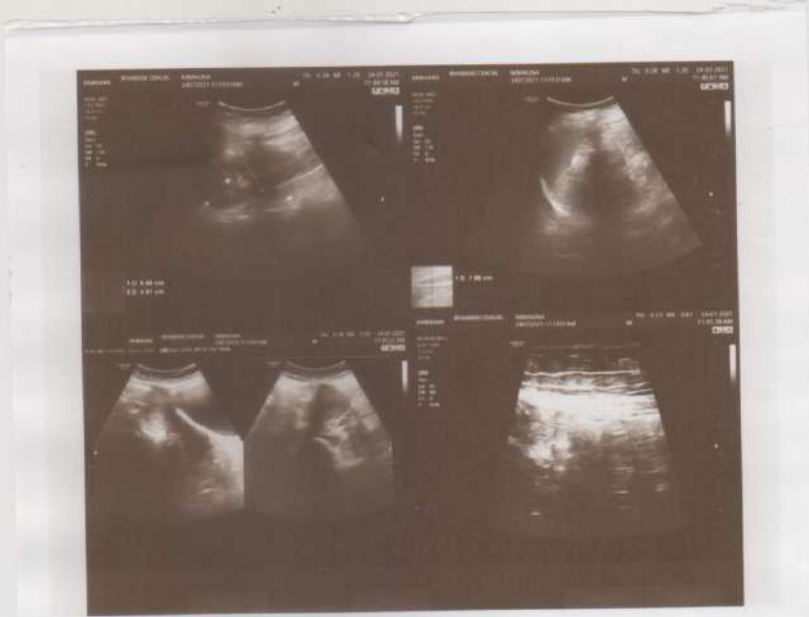
- NO SIGNIFICANT ABNORMALITY IS NOTED IN ABDOMEN & PELVIS.


DR. B. A. SUBUDHI, M.D
RADIOLOGIST

Clinical correlation of this report is a must.

NB. : This report is not valid for medico legal purpose

ULTRA SOUND, DIGITAL X-RAY, VIDEO ENDOSCOPY, ECG, ALL PATHOLOGICAL INVESTIGATION DONE HERE



**BHABANI DIAGNOSTIC CENTRE**

Goilundi-Kamapalli Road,
Infront of Nandighos Apartment, Brahmapur
Mob. : 9078214639, 7008833151

PATIENTS NAME: NIMAGNA PATRA**AGE:50 YRS SEX:M****REFERRED BY : NEELANCHAL HOSPITAL****DATE:24-Jul-2021****X-RAY CHEST PA / VIEW**

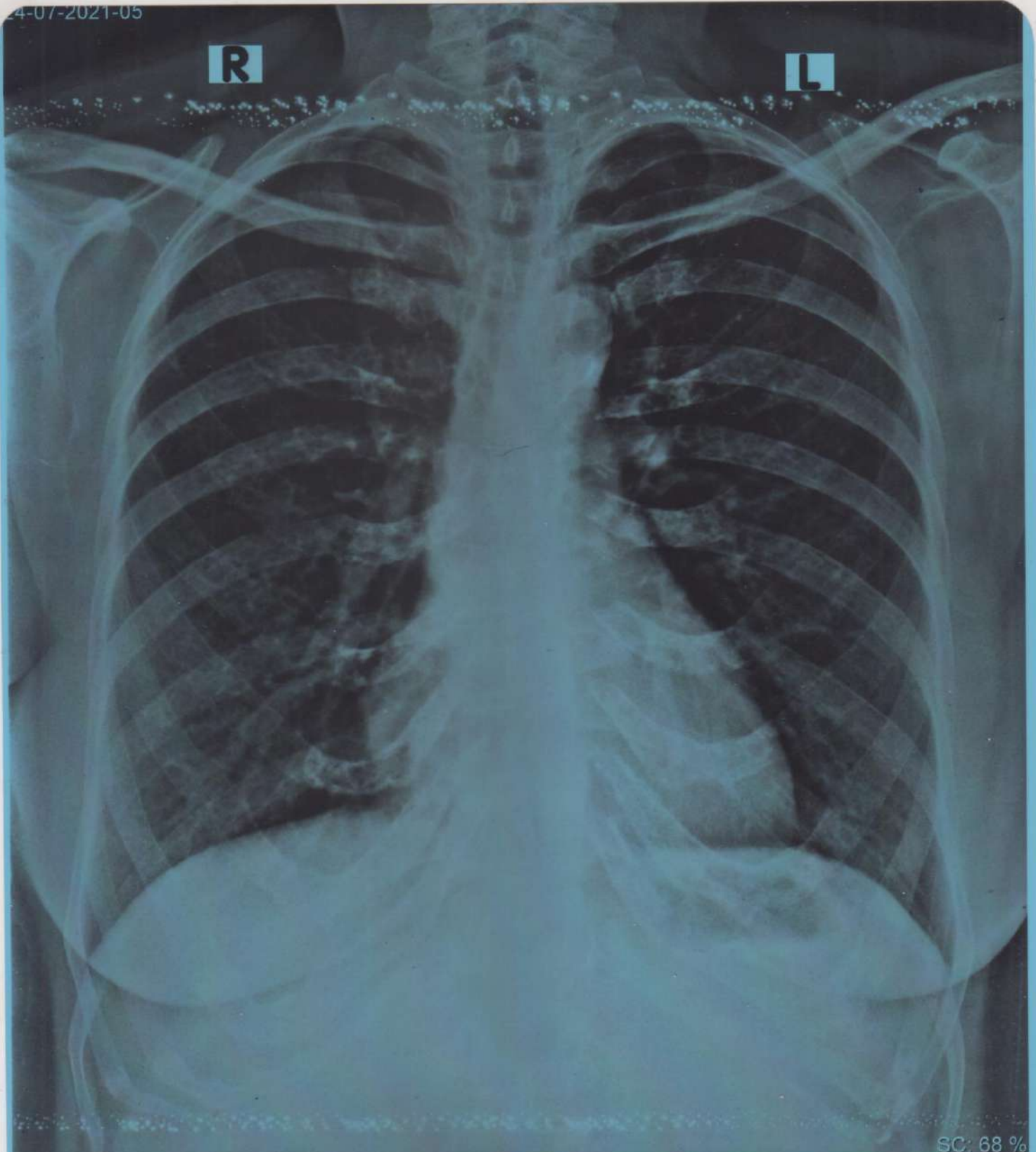
- Tracheas is centre.
- Mediastium is central and normal.
- Both lung fields are clear.
- Pulmonary vasculatures are normal.
- Both hila are normal.
- Both cp angels are normal.
- Cardiac shape size are normal .
- Both domes of diaphragm are normal is position.
- Thoracic cage and soft tissue are normal.

IMPRESSION :NORMAL STUDY.**PROF: S.N.SAHU****CONSULTANT RADIOLOGIST**

24-07-2021-05

R

L



SC: 68 %

24-07-2021-05 NIMAGNA PATRA, (F) AGE-50 YRS (NEELANCHAL HOSPITAL)

2021.JUL.24 X-RAY-CHEST-PA VIEW

BHABANI DIAGNOSTIC CENTER, BERHAMPUR