



To,

The Coordinator,
Mediwheel (Arcofemi Healthcare Limited)
Helpline number: 011- 41195959

Dear Sir / Madam,

Sub: Annual Health Checkup for the employees of Bank of Baroda

This is to inform you that the following spouse of our employee wishes to avail the facility of Cashless Annual Health Checkup provided by you in terms of our agreement.

PARTICULARS OF HEALTH CHECK UP BENEFICIARY	
NAME	TAMALIKA GHOSH
DATE OF BIRTH	29-09-1989
PROPOSED DATE OF HEALTH CHECKUP FOR EMPLOYEE SPOUSE	08-11-2021
BOOKING REFERENCE NO.	21D128044100006150S
SPOUSE DETAILS	
EMPLOYEE NAME	MR. BASU SAYANTAN
EMPLOYEE EC NO.	128044
EMPLOYEE DESIGNATION	CORPORATE & INSTITUTIONAL RELATIONSHIP
EMPLOYEE PLACE OF WORK	MUMBAI,BKC, BARODA CORPORATE C
EMPLOYEE BIRTHDATE	26-04-1984

This letter of approval / recommendation is valid if submitted along with copy of the Bank of Baroda employee id card. This approval is valid from **01-11-2021** till **31-03-2022**.The list of medical tests to be conducted is provided in the annexure to this letter. Please note that the said health checkup is a **cashless facility** as per our tie up arrangement. We request you to attend to the health checkup requirement of our employee's spouse and accord your top priority and best resources in this regard. The EC Number and the booking reference number as given in the above table shall be mentioned in the invoice, invariably.

We solicit your co-operation in this regard.

Yours faithfully,

Sd/-

**Chief General Manager
HRM Department
Bank of Baroda**

(Note: This is a computer generated letter. No Signature required. For any clarification, please contact Mediwheel (Arcofemi Healthcare Limited))

ভারত সরকার
Government of India

তামালিকা ঘোষ
Tamalika Ghosh
পিতা : স্বপন কুমার ঘোষ
Father : Swapan Kr. Ghosh

জন্মতারিখ/DOB: 29/09/1989
মহিলা / Female


8185 4204 1928

আধার - সাধারণ মানুষের অধিকার



Tamalika Ghosh.

Pa. Ho. Treat. Diagnostic Center
& Poly Clinic
75 Dum Dum Road, Kol-700074
Phone No. - (033) 2550 0541



Patho Treat

TEST REPORT

DIAGNOSTIC CENTRE & POLYCLINIC

Regd. Off : 75, Dum Dum Road, Kolkata - 700 074
Phone No.: 82403 48836, (Infront of Motijheel College of Commerce)

Tamalika Ghosh 32 / Female.

Ht - 160 cm, wt - 82 kg.

Bp - 115/70, pulse - 74/min

all reports are normal. There was no
abnormalities found. She is
Physically fit & healthy.

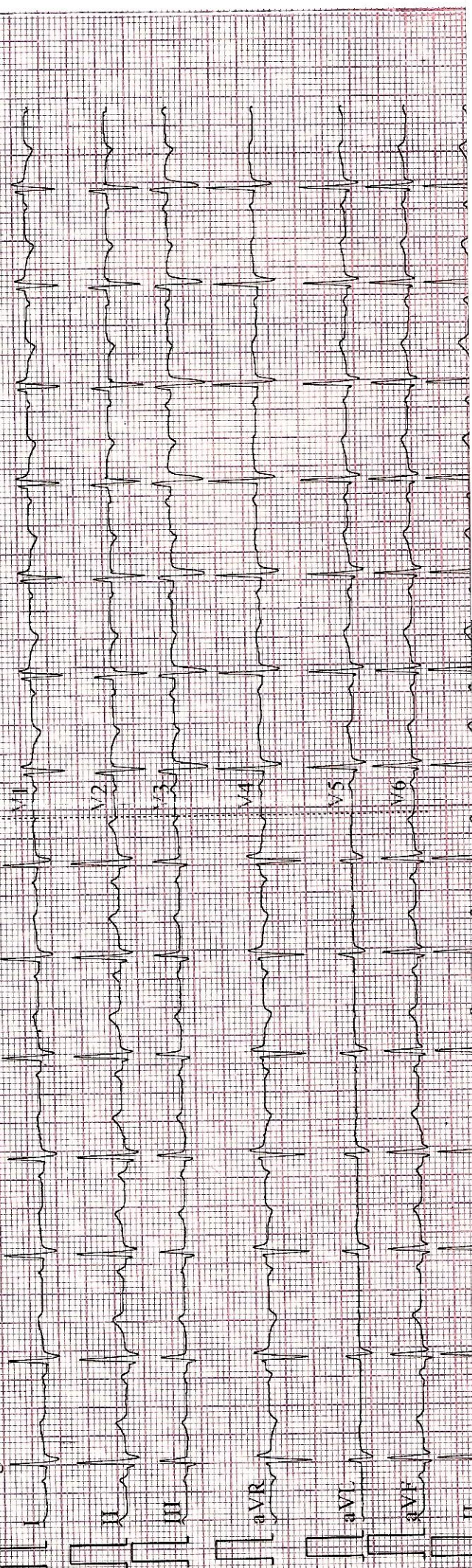
Dr. Debajit Banerjee
M.B.B.S., MD (Medicine)
Reg. No. - 42951

11-11-2021 12:07:53

BPL

ID: 799

tamatika ghosh Female 32 Year



ID: 799

tamatika ghosh
Female 32 Year

0.67 2.5Hz 25mm/s 10mm/mV 2*5s#1r ♡87 1.32

11-11-2021 12:07:53

BPL

HR 86 bpm
 P 96 ms
 PR 143 ms
 QRS 93 ms
 QT/QTc 374/450 ms
 P/QRS/T 59/67/53 °
 RV5/SVI 0.790/0.574 mV

Diagnosis Information:

Sinus Rhythm

Poor R Wave Progression(V3)

Inverted T Wave(V2)

Dr. Debajyoti Banerjee
 MBBS (Honors), MD (Internal Med),
 DM (Cardiology), DNB (Cardiology),
 FACC (USA), FICP (India),
 FICM (India), FICN (India),
 FICU (India), FICG (India),
 FICV (India), FICP (India),
 FICM (India), FICN (India),
 FICU (India), FICG (India),
 FICV (India)



Patho Treat

DIAGNOSTIC CENTRE & POLYCLINIC

TEST REPORT

Regd. Off : 75, Dum Dum Road, Kolkata - 700 074
Phone No.: 82403 48836, (Infront of Motijheel College of Commerce)

ID NO: B/11/03
PT.NAME= MRS TAMALIKA GHOSH
SEX: F AGE: 32 YRS

DATE OF RECEIPT: 11.11.2021

DATE OF REPORT: 11.11.2021

Reference By: BANK OF BARODA

DIGITAL X-RAY CHEST PA VIEW

- Prominent broncho vascular marking is seen in bilateral lung fields.
- Domes of diaphragms are smooth and regular.
- Costophrenic angles are clear.
- Cardiac shadow is normal.
- Mediastinum is central.
- Both hila are normal in position and density.
- Bony thorax shows no abnormality.

IMPRESSION

Prominent broncho vascular marking is seen in bilateral lung fields & ground glass haziness noted by lateral lung fields

DR VIMLESH JI VIMAL
M.B.B.S.,MD,
DMRD (Radiologist)



Patho Treat

DIAGNOSTIC CENTRE & POLYCLINIC

TEST REPORT

Regd. Off : 75, Dum Dum Road, Kolkata - 700 074
Phone No.: 82403 48836, (Infront of Motijheel College of Commerce)

ID NO: B/11/03
PT.NAME= MRS TAMALIKA GHOSH
SEX: F AGE: 32 YRS

DATE OF RECEIPT: 11.11.2021

DATE OF REPORT: 11.11.2021

Reference By: BANK OF BARODA

TEST	RESULT & UNIT	NORMAL RANGE
HAEMOGLOBIN (Cyanmethmaglobin Method)	11.8 gm %	Male :- (13 - 18) Female :- (11.5 - 16.5)
Total R.B.C	4.05 Million / cmm	3.5 - 6.5 Million / cmm
Total W.B.C	6300 / cmm	(4000 - 11000) / cmm
Platelets Count	2.10 lac / cmm	(1.5 - 4.0) lac / cmm

Differential Count W.B.C


TEST	RESULT & UNIT	NORMAL RANGE
Neutrophils	63%	(40 - 80) %
Lymphocytes	32%	(20 - 40) %
Eosinophils	03 %	(2 - 10) %
Monocytes	02 %	(1 - 6) %
Basophils	00 %	(0 - 2) %

Haemogram

TEST	RESULT & UNIT	NORMAL RANGE
PCV	41.5%	(38 - 54) %
MCV	83Um3	(77 - 93) Um3
MCH	27.5 g %	(26 - 32) g %
MCHC	29.5 %	(27 - 35) %

Morphology of RBC : Normocytic, Normochromic.
ESR(Westergern Method): 1st Hour-16/mm (MALE : 0 -14 FEMALE : 0-20)

DR. SUMANA MAJUMDAR
M.B.B.S., MD
(PATHOLOGIST)



Patho Treat

DIAGNOSTIC CENTRE & POLYCLINIC

TEST REPORT

Regd. Off : 75, Dum Dum Road, Kolkata - 700 074
Phone No.: 82403 48836, (Infront of Motijheel College of Commerce)

ID NO: B/11/03
PT.NAME= MRS TAMALIKA GHOSH
SEX: F AGE: 32 YRS


DATE OF RECEIPT: 11.11.2021

DATE OF REPORT: 11.11.2021

Reference By: BANK OF BARODA

REPORT ON THE BIO – CHEMICAL EXAMINATION

<u>TEST</u>	<u>RESULT</u>	<u>UNIT</u>	<u>NORMAL VALUE</u>
BILIRUBIN TOTAL	0.59	mg /dL	(Upto 1.00)
Bilirubin Conjugated	0.15	mg /dL	(Upto 0.25)
Bilirubin Unconjugated	.044	mg /dL	(Upto 0.75)
SGOT/AST	24.00	U/L	(Male : 10 -35 Female : 10 – 31)
SGPT/ALT	28.00	U/L	(9.00 - 43.00)
TOTAL PROTEIN	7.22	g/dL	(6.00 - 8.50)
ALBUMIN	4.45	gm/dL	(3.5 – 5.2)
GLOBULIN :	2.77	gm/dL	(2.3 – 3.6)
A G Ratio :	1.6:1		
GAMA GT (G . G . T)	30.5	IU/L	(7.00 - 52.00)
ALKALINE PHOSPHATSE	94.0	IU/L	<i>Upto 5Yrs. F: 48-406, M: 75-389 5-10 Yrs.F: 96-332, M: 93-362 11- 15 Yrs. F: 52-162, M:74-390 16- 19 Yrs.F: 47-119, M:52-171 Adult – F: 35-141, M: 40-129</i>
AST/ALT RATIO	1.6:1		


DR. SUMANA MAJUMDAR
M.B.B.S.,MD (PATHOLOGIST)



Patho Treat

DIAGNOSTIC CENTRE & POLYCLINIC

TEST REPORT

Regd. Off : 75, Dum Dum Road, Kolkata - 700 074
Phone No.: 82403 48836, (Infront of Motijheel College of Commerce)

ID NO: B/11/03
PT.NAME= MRS TAMALIKA GHOSH
SEX: F AGE: 32 YRS


DATE OF RECEIPT: 11.11.2021


DATE OF REPORT: 11.11.2021

Reference By: BANK OF BARODA

HEMATOLOGY

<u>TEST</u>		<u>RESULT</u>
"ABO" GROUPING	:	" A "
Rh (D) FACTOR	:	POSITIVE


DR. SUMANA MAJUMDAR
M.B.B.S., MD
(PATHOLOGIST)



Patho Treat

DIAGNOSTIC CENTRE & POLYCLINIC

TEST REPORT

Regd. Off : 75, Dum Dum Road, Kolkata - 700 074
Phone No.: 82403 48836, (Infront of Motijheel College of Commerce)


ID NO: B/11/03
PT.NAME= MRS TAMALIKA GHOSH
SEX: F AGE: 32 YRS

DATE OF RECEIPT: 11.11.2021

DATE OF REPORT: 11.11.2021

Reference By: BANK OF BARODA

<u>INVESTIGATION</u>	<u>RESULT / UNIT</u>	<u>REFERENCE VALUE</u>
TOTAL TRI-iodothyronin (T3)	220ng/dl	(60 – 181)
TOTAL THYROXINE (T4)	11.6ng/dl	(4.5 – 10.9)
THYROID STIMULATING HORMONE	7.2 nl/ml	(0.35 – 5.5)


DR. SUJANA MAJUMDAR
M.B.B.S.,MD
(PATHOLOGIST)



Patho Treat

DIAGNOSTIC CENTRE & POLYCLINIC

TEST REPORT

Regd. Off : 75, Dum Dum Road, Kolkata - 700 074
Phone No.: 82403 48836, (Infront of Motijheel College of Commerce)

ID NO: B/11/03
PT.NAME= MRS TAMALIKA GHOSH
SEX: F AGE: 32 YRS

DATE OF RECEIPT: 11.11.2021

DATE OF REPORT: 11.11.2021

Reference By: BANK OF BARODA

REPORT ON EXAMINATION OF BLOOD

INVESTIGATION


RESULT & UNIT


GLYCOSYLATED HB%
(HBA1C)

6.14%

REFERENCE RANGE :-

Below 6.0 % ----- Normal Value
6.0 % - 7.0 % ----- Good Control
7.0 % - 8.0 % ----- Fair Control
8.0 % - 10.0 % ----- Unsatisfactory Control
Above 10.0 % ----- Poor Control


DR.SUMANA MAJUMDAR
M.B.B.S.,MD
(PATHOLOGIST)



Patho Treat

DIAGNOSTIC CENTRE & POLYCLINIC

TEST REPORT

Regd. Off : 75, Dum Dum Road, Kolkata - 700 074
Phone No.: 82403 48836, (Infront of Motijheel College of Commerce)

ID NO: B/11/03
PT.NAME= MRS TAMALIKA GHOSH
SEX: F AGE: 32 YRS

DATE OF RECEIPT: 11.11.2021


DATE OF REPORT: 11.11.2021


Reference By: BANK OF BARODA

<u>TEST</u>	<u>RESULT</u>	<u>VALUE RANGE</u>
COTININE TEST	NEGATIVE	(<200 ng / ml)

METHOD : - Qualitative Immunochromatographic Assay

SAMPLE : - URINE


DR.SUNANA MAJUMDAR
M.B.B.S.,MD
(PATHOLOGIST)



Patho Treat

DIAGNOSTIC CENTRE & POLYCLINIC

TEST REPORT

Regd. Off : 75, Dum Dum Road, Kolkata - 700 074
Phone No.: 82403 48836, (Infront of Motijheel College of Commerce)

ID NO: B/11/03
PT.NAME= MRS TAMALIKA GHOSH
SEX: F AGE: 32 YRS

DATE OF RECEIPT: 11.11.2021


DATE OF REPORT: 11.11.2021

Reference By: BANK OF BARODA

REPORT ON THE BIO – CHEMICAL EXAMINATION

<u>TEST</u>	<u>RESULT</u>	<u>UNIT</u>	<u>NORMAL VALUE</u>
TRIGLYCERIDES	135.00	mg / dL	(65.00 – 170.00)
HDL - CHOLESTEROL	58.00	mg / dL	(30 . 00 – 55 . 00)
LDL - CHOLESTEROL (By Enzymatic Method at 370C)	136.00	mg / dL	(Upto 150.00)
VLDL	27.0	mg / dL	(16 . 00 - 40 . 00)
CHOLESTEROL - TOTAL	221.00	mg / dL	(150 . 00 – 250 . 00)
LDL/HDL	2.3:1		
CHOLESTEROL TOTAL/HDL	3.8:1		

DR. SUMANA MAJUMDAR
M.B.B.S., MD(PATHOLOGIST)



Patho Treat

TEST REPORT

DIAGNOSTIC CENTRE & POLYCLINIC

Regd. Off : 75, Dum Dum Road, Kolkata - 700 074
Phone No.: 82403 48836, (Infront of Motijheel College of Commerce)

ID NO: B/11/03
PT.NAME= MRS TAMALIKA GHOSH
SEX: F AGE: 32 YRS


DATE OF RECEIPT: 11.11.2021


DATE OF REPORT: 11.11.2021

Reference By: BANK OF BARODA

REPORT ON THE BIO – CHEMICAL EXAMINATION

<u>TEST</u>	<u>RESULT</u>	<u>UNIT</u>	<u>NORMAL VALUE</u>
SUGAR (F)	107	mg / dl	(70 – 110)
SUGAR (PP)	252	mg / dl	(110 – 140)
CREATININE	0.82	mg /dL	(0.70 - 1.20)
URIC – ACID	5.2	mg/dL	(Male -3.4 – 7.0 Female - 2.4 – 5.7)
BUN	10.2	mg/dL	(5 – 23)
BUN/CREATININE	12.4/1		


DR. SUMANA MAJUMDAR
M.B.B.S.,MD
(PATHOLOGIST)



Patho Treat

DIAGNOSTIC CENTRE & POLYCLINIC

TEST REPORT

Regd. Off : 75, Dum Dum Road, Kolkata - 700 074
Phone No.: 82403 48836, (Infront of Motijheel College of Commerce)

ID NO: B/11/03
PT.NAME= MRS TAMALIKA GHOSH
SEX: F AGE: 32 YRS

DATE OF RECEIPT: 11.11.2021

DATE OF REPORT: 11.11.2021

Reference By: BANK OF BARODA

PHYSICAL EXAMINATION

Quantity 45 ml
Colour pale yellow
Appearance clear
Sediment Nil
Sp. Gravity 1.015

CHEMICAL EXAMINATION

Reaction Acidic
Albumin Nil
Proteins Nil
Sugar Nil
Acetone Negative
Bile Salt Negative
Bile Pigment Negative
Phosphates Nil
Chyle -----
Occult Blood Negative
Urobilinogen -----
Bence-Jones -----

MICROSCOPIC EXAMINATION

Unorganised Examination
Crystals Not Found
Organised Constituents
Not Found
CASTS
Cellular(Pus Cell) Not Found
Hyaline Not Found
Granular Not Found
Fatty Not Found
Others Not Found
CELLS
Epithelial Cells (3 - 4 / HPF)
Pus Cells (0 - 1 /HPF)
R.B.C. Not Found
Others Nil
Bacteria Not Found


DR.SUMANA MAJUMDAR
M.B.B.S.,MD
(PATHOLOGIST)



Patho Treat

DIAGNOSTIC CENTRE & POLYCLINIC

TEST REPORT

Regd. Off : 75, Dum Dum Road, Kolkata - 700 074

Phone No.: (033) 2560 3641 / 3642, (033) 6526 0026, (Infront of Motijheel College of Commerce)

Associate Code :	D1	Received On :	11/11/2021
Patient's Name :	MRS TAMALIKA GHOSH	Reported On :	12/11/2021
ID Number :	10923/K-804	Age/Sex :	32Y/FEMALE
Referred By :	SELF	Sample Source :	

ClinicPro/debjan

Page 1 of 1

ULTRASONOGRAPHY OF WHOLE ABDOMEN

LIVER

It is grossly enlarged(23.1 cm) in size. Parenchymal echotexture is raised . No focal parenchymal lesion is seen. Intrahepatic biliary radicles not dilated.

PORTA

PV : Normal in diameter with echofree lumen. PV measures 0.9 cm.

CD : Normal in caliber. No calculus is seen up to traceable part. CD measures 0.3 cm.

GALL BLADDER

It is contracted.

PANCREAS

Normal in size, shape & outline. No focal S.O.L. or calcification noted. Main pancreatic duct – not dilated.

SPLEEN

Spleen is normal in size (11.6 cm). Parenchymal echotexture is normal. Splenic vein at its hilum is not dilated.

KIDNEY

Both kidneys are normal in size , shape and outline. Cortical echogenicity appears normal on both sides. Central echocomplexes are normal. Corticomedullary differentiation is maintained. No-evidence of stone, hydronephrosis or any mass lesion seen on either side.

DR. S. PAL
M.B.B.S.(KOL),
APUSC-CBET(WBUHS)
CONSULTANT SONOLOGIST

DR. V. J. VIMAL
MD,DMRD
CONSULTANT RADIOLOGIST

Checked by.....



Patho Treat

DIAGNOSTIC CENTRE & POLYCLINIC

TEST REPORT

Regd. Off : 75, Dum Dum Road, Kolkata - 700 074

Phone No.: (033) 2560 3641 / 3642, (033) 6526 0026, (Infront of Motijheel College of Commerce)

URETERS

Not visualized hence not dilated.

URINARY BLADDER

Sub optimally distended. .

UTERUS

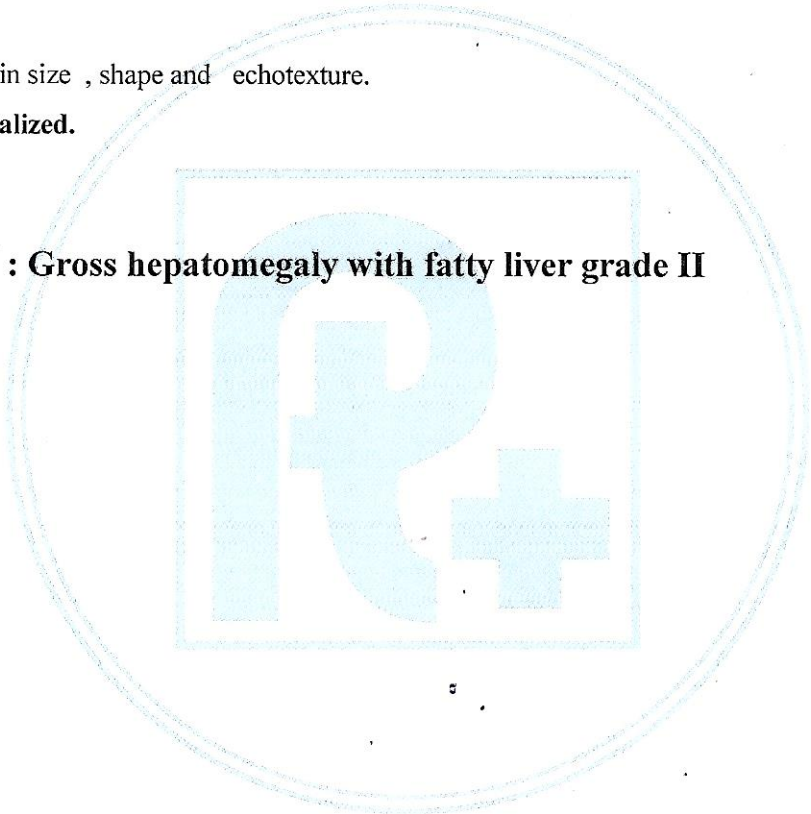
Normal in size & echotexture.

OVARIES

Right ovary normal in size , shape and echotexture.

Left ovary not visualized.

IMPRESSION : Gross hepatomegaly with fatty liver grade II



DR. S. PAL
M.B.B.S.(KOL),
APUSC-CBET(WBUHS)
CONSULTANT SONOLOGIST


DR. V. J. VIMAL
MD,DMRD
CONSULTANT RADIOLOGIST

Checked by.....