

Solad Roshan P.
38 / M

2D ECHO

27.12.21

PHY2.

History and Complaints:
NIL.

EXAMINATION FINDINGS:			
Height (cms): 174		Weight (kg): 76	BMI
Temp (0c): Afebrile		Skin: Normal	NAD
Blood Pressure (mm/hg): 130/80		Nails: Healthy	
Pulse: 84		Lymph Node: Not Palpable	

Systems

Cardiovascular: S1,S2 Normal No Murmurs

Respiratory: Air Entry Bilaterally Equal

Genitourinary: Normal

GI System: Soft non tender No Organomegaly

CNS: Normal

IMPRESSION:

FII
Grade 1 diastolic dye on 2D ECHO.
↑ in non HDL, LDL.

ADVICE:

Diet + Exercise.

CHIEF COMPLAINTS:	
1)	Hypertension:
2)	IHD:
3)	Arrhythmia:
4)	Diabetes Mellitus :
5)	Tuberculosis :
6)	Asthama:
7)	Pulmonary Disease :

NIL.

Patient Name:

HR 92/min

Saloo Koshan Purnestham.

Age: 38 yrs

174 cm / 76 kg

130 / 80 mmHg

H/O N/C

Fig.

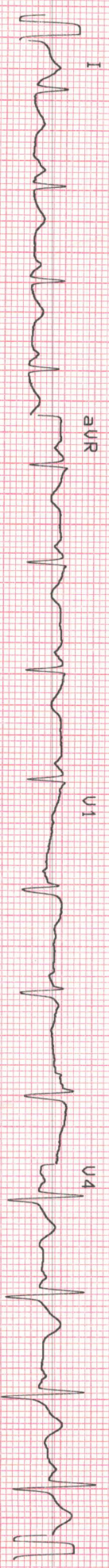Sinus Rhythm, Normal Axis.
Late 2 wave progression

Krutika Ingle

Dr. KRUTIKA INGLE

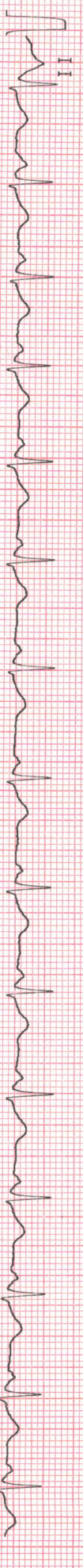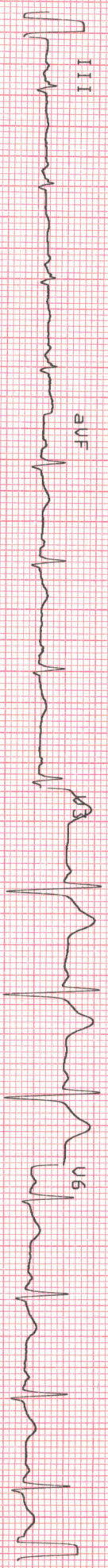
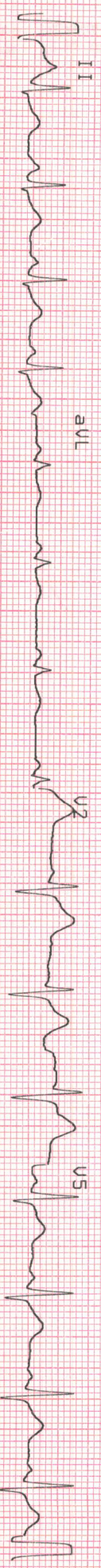MBBS, D.D.M., PG in Diabetology (USA)
MNC Regd - 2012 103018

Bank of Baroda



10 mm/mV

10 mm/mV



25 mm/s

0.05-25 Hz

F50

Mo 27-DEC-21 12:27:49

AT-2

3.03

SUBURBAN DIAGNOSTIC (I) PVT. LTD.
 "Fortuna" Ground Floor, Near Shivaji
 Garden Chowk, Next to Radha Krishna
 Hotel, Pimple Saudagar, Pune-411 027.

Preventive Health Check-up | Pathology | Digital X-Ray | Sonography | Colour Doppler | Mammography | BMD (DXA Scan) | OPG | Stress Test/TMT | 2D Echo | Spirometry | Eye Examination | Dental Examination | Diet Consultation | Audiometry | OT Sterility | Water Sterility | Clinical Pathology

Date:- 27-12-21

CID:

Name:- Roshan Solao P

Sex / Age: / 38/M

EYE CHECK UP

Chief complaints:

Systemic Diseases:

Past history:

Unaided Vision:

Aided Vision:

Refraction:

Yours
Yours
- nil -
Yours

(Right Eye)


(Left Eye)

	Sph	Cyl	Axis	Vn	Sph	Cyl	Axis	Vn
Distance	_____				_____			
Near	_____				_____			

Colour Vision: Normal / ~~Abnormal~~

Remark:

nil



Dr. KRUTIKA INGLE

MBBS, D.DM, PG in Diabetology (USA)
MMC Regd - 2012 103018



बैंक ऑफ बरोडा
Bank of Baroda



नाम : Roshan P Solao

नाम क्र. : 105560



ISSUING AUTHORITY
C.M. (Co-ord./Security)
M & G Zone

SUBURBAN DIAGNOSTIC (I) PVT. LTD
"Fortuna" Ground Floor, Near Shivhar
Garden Chowk, Next to Radha Krishna
Hotel, Pimple Saudagar, Pune-411027.

for health checkup
R.P.S.



CID : 2136101559
Name : Mr SOLAO ROSHAN
PURUSHOTTAM
Age / Sex : 38 Years/Male
Ref. Dr :
Reg.Location : Pimple Saudagar, Pune Main Centre
Reg. Date : 27-Dec-2021 / 11:21
Reported : 28-Dec-2021 / 08:43

USG WHOLE ABDOMEN

LIVER:

The liver is normal in size, shape and smooth margins. It shows normal parenchymal echo pattern. The intra hepatic biliary and portal radical appear normal. No evidence of any intra hepatic cystic or solid lesion seen. The main portal vein and CBD appears normal.

GALL BLADDER:

The gall bladder is physiologically distended and appears normal. No evidence of gall stones or mass lesions seen

PANCREAS:

The pancreas is well visualised and appears normal. No evidence of solid or cystic mass lesion.

KIDNEYS:

Both the kidneys are normal in size shape and echotexture.

No evidence of any calculus, hydronephrosis or mass lesion seen.

Right kidney measures- 10.6 x 4.8 cm. Left kidney measures- 10.8 x 5.4 cm.

SPLEEN:

The spleen is normal in size and echotexture. No evidence of focal lesion is noted. There is no evidence of any lymphadenopathy or ascites.

URINARY BLADDER:

The urinary bladder is well distended and reveal no intraluminal abnormality.

PROSTATE:

Prostate is normal in size, shape and echopattern. No focal lesion seen.

IMPRESSION:

No significant abnormality is seen.

-----End of Report-----

DR. RUJUTA SAWANT
MBBS DMRE
Regd. No. 2011/11/3329
Consultant Radiologist

[Click here to view images http://202.143.96.162/Suburban/Viewer?ViewerType=3&AccessionNo=2021122709281283](http://202.143.96.162/Suburban/Viewer?ViewerType=3&AccessionNo=2021122709281283)

2D ECHO / COLOUR DOPPLER

NAME : Mr .SOLAO ROSHAN PURUSHOTTAM

Age : 38 YRS./MALE

REF BY: Arcofemi Healthcare Limited

DATE :27/12/2021

M - Mode values

Doppler Values


AORTIC ROOT (mm)	24	PULMONARY VEL (m/sec)	1.0
LEFT ATRIUM (mm)	32	PG (mmHg)	4
RV (mm)	28	AORTIC VEL (m/sec)	1.0
IVS - D (mm)	11	PG (mmHg)	5
LVID - D (mm)	42	MITRAL E VEL (m/sec)	0.4
LVID - S (mm)	22	A VEL (m/ sec)	0.6
LVPW - D (mm)	11	TRICUSPID VEL. (m/sec)	2.0
EJECTION FRACTION (%)	60	PG (mmHg)	17

OBSERVATION:

All four cardiac valves are structurally normal.
All four cardiac chambers normal in dimensions.
Normal left ventricle size with Good ventricle systolic function .(LVEF-65%)
No Regional wall motion abnormalities.
Left atrium, Right atrium & Right ventricle are normal in size.
No pulmonary artery hypertension. RVSP = 27 mmHg.
Interatrial septum & Interventricular septum are intact.
No clot/vegetation /pericardial effusion.
Doppler study revealed mild mitral regurgitation , mild tricuspid regurgitation.
IVC 1.5 cm, more than 50% pulsatile.
Left sided aortic arch, No coarctation of aorta.
Grade 1 diastolic dysfunction.

CONCLUSION:

**Normal left ventricle size with Good ventricle systolic function .(LVEF-65%)
No pulmonary artery hypertension. RVSP = 27 mmHg.
Grade 1 diastolic dysfunction.**


**DR SONAM SHAH
MD DM CARDIOLOGY
INTERVENTIONAL CARDIOLOGIST**

**Dr. Sonam Shah
MBBS MD DM Cardiology
Interventional Cardiologist
MMC 2010 / 06 / 2218**

Authenticity Check



Use a QR Code Scanner
Application To Scan the Code

CID : 2136101559
Name : Mr SOLAO ROSHAN
PURUSHOTTAM
Age / Sex : 38 Years/Male
Ref. Dr :
Reg.Location : Pimple Saudagar, Pune Main Centre

Reg. Date : 27-Dec-2021 / 12:15
Reported : 28-Dec-2021 / 09:11

R
E
P
O
R
T

X-RAY CHEST PA VIEW

There is no evidence of any parenchymal lesion in either lung.
Both lung fields are clear.
Cardio-aortic silhouette has a normal appearance.
Diaphragmatic domes have normal contours and positions.
There is no evidence of any pleural effusion.
Bony thorax and soft-tissues are normal.

CONCLUSION:

NORMAL CHEST X-RAY.

-----End of Report-----

DR. RUJUTA SAWANT
MBBS DMRE
Regd. No. 2011/11/3329
Consultant Radiologist

[Click here to view images http://202.143.96.162/Suburban/Viewer?ViewerType=3&AccessionNo=2021122709281286](http://202.143.96.162/Suburban/Viewer?ViewerType=3&AccessionNo=2021122709281286)