



प्रतिपूर्व विना विचारणी करी नकार बंदी आहे. परंतु
जर कोणी विना विचार कळविल्याची प्रमाणे केले तर त्याला
१०,०००/- पर्यंत दंड देण्यात येईल.

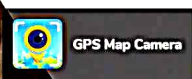
विना विचार करणा-या डॉक्टरांना
अपवि ५ वर्षांचा कारावासा त्या
सोबतच दंड होऊ शकतो.

५०००० पर्यंत प्रत्येक विधान
निकटित प्रमाणे १९९४ संवत्सर्ग
मुदत पर्यंत आहे कोणतेही व्यक्ती
आढळल्यास त्या व्यक्तीस ५ वर्षांचा
दंड देण्यात येईल.

कारावासासाठी - पोलिसांच्या ४ वकिला ह्या अंत
आपणांचा पत्ता - ११००३३००
कारावासा (वेळापत्र) : www.maharashtra.gov.in

"मुंबई मुंबई वास्तव्यास,
असत असत कायमितीकरण"

या संदर्भातचे अधिकृत तपसपत्ती क्षेत्र



Mumbai, Maharashtra, India

Shop No. - 3, Akhil Bhartiya Bhavan, Belasis Road, Tardeo, Mumbai - 400034, Marzban Parsi Colony, Dalal Estate, Mumbai Central, Mumbai, Maharashtra 400008, India

Lat 18.968768°

Long 72.81999°

11/09/21 09:07 AM

entral
SMART
Google

Medline


आयकर विभाग
INCOME TAX DEPARTMENT

भारत सरकार
GOVT. OF INDIA



स्थायी लेखा संख्या कार्ड
Permanent Account Number Card

IGLPK4890P



नाम / Name

SULEKHA KUMARI

पिता का नाम / Father's Name

KISHOR SAHU

जन्म की तारीख /
Date of Birth

20/01/1996

हस्ताक्षर / Signature

Sulekha

[Signature]
DR. HARI CHHABLANI
M.B.B.S F.C.C.P.(RESP.MEDICINE) F.S.M.M., PGDMLS
FELLOW INTENSIVE CARE
MMC REG. NO. - 91702

"DR. PLUS HEALTHCARE CENTRE"
NATHANI HEIGHTS', B-WING,
42, MUMBAI CENTRAL (EAST)

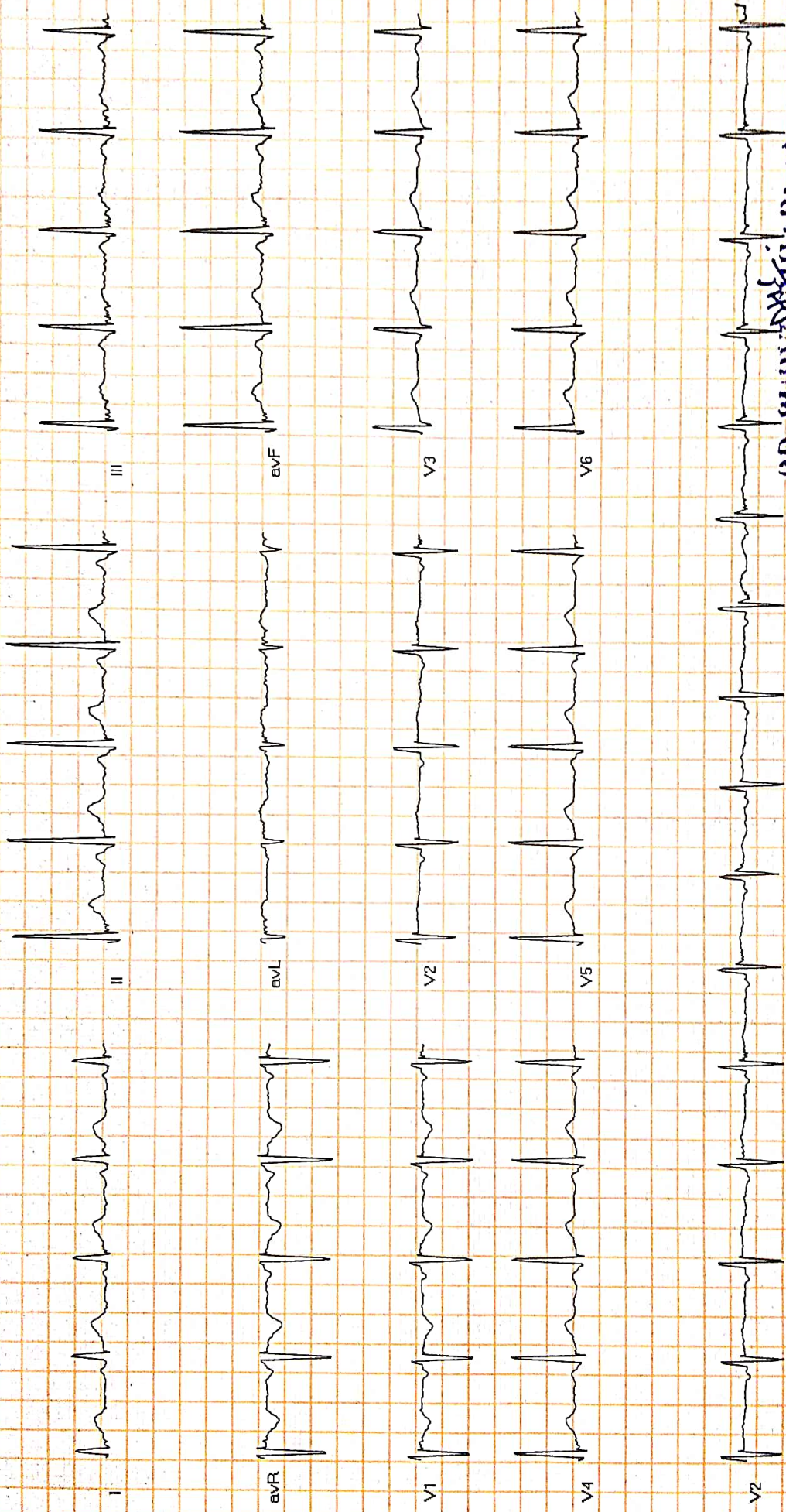
Sulekha

DR PLUS HEALTHCARE CENTRE- MUMBAI CENTRAL

ECG

1060 / SULEKHA KUMARI / 26 Yrs / F.

Heart Rate : 93 bpm / Tested On : 11-Sep-21 10:27:39 / HF 0.05 Hz - LF 100 Hz / Notch 50 Hz / Sn 1.00 Cm/mV / Sw 25 mm/s
/ Refd By : DR. HARICHHABLANI



WNL

DR. PURVAKHABLANI

MBBS DNB (Medicine)

Consultant Physician And Intensivis

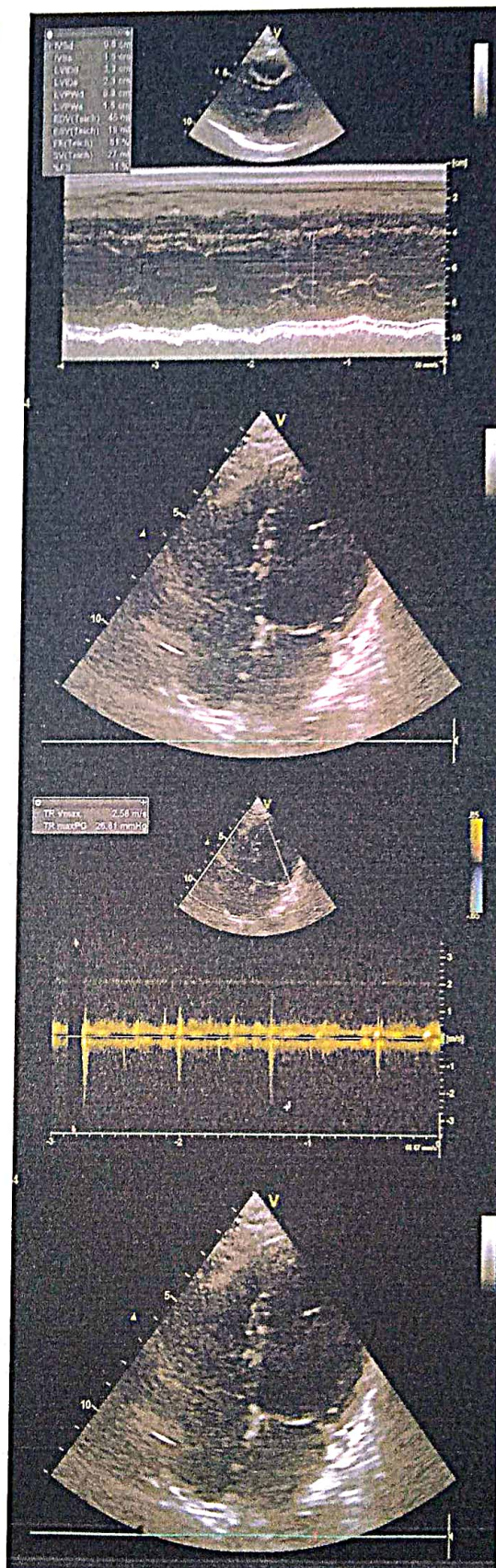
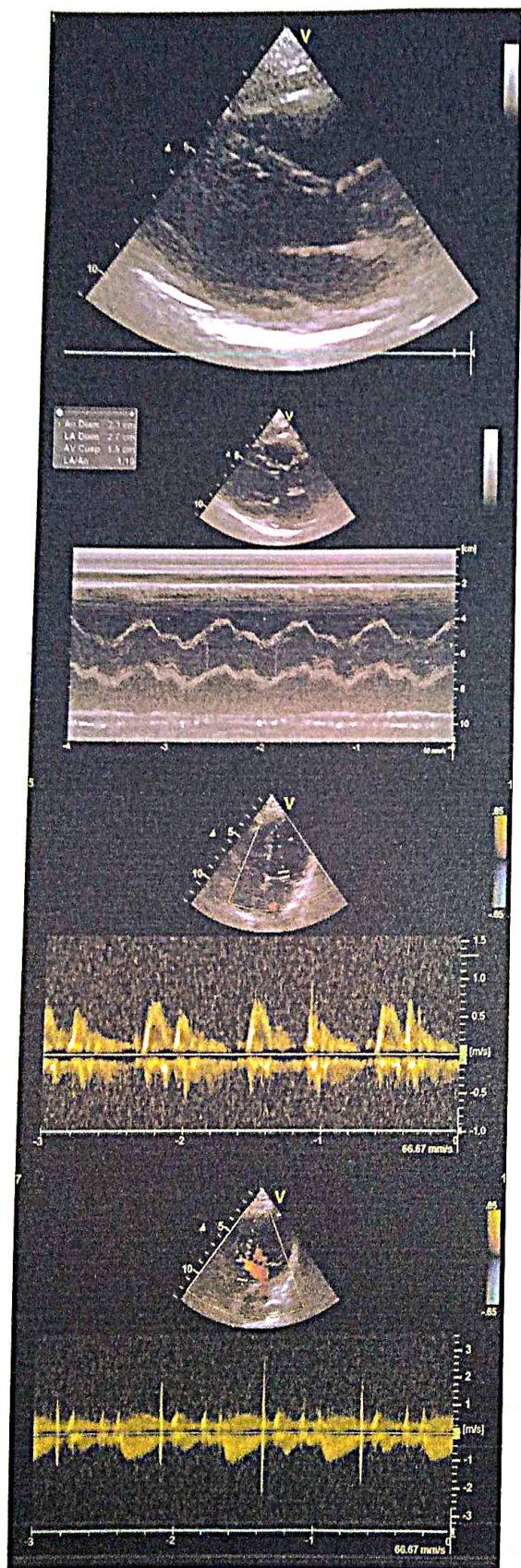
Reported By: DR. PURVAKHABLANI

Name SULEKHA KUMARI

Sex Female

Age 25

Date 11/09/2021





NAME : SULEKHA KUMARI

25/F

DATE:11/09/2021

REF BY : DR. PURVI CHHABLANI

2D-ECHO. AND COLOR DOPPLER REPORT

- NORMAL CARDIAC VALVES WITH TRIVIAL TR.
- NORMAL CARDIAC CHAMBERS
- NO E/O REGIONAL WALL MOTION ABNORMALITY. WITH NORMAL LVEF OF 64 %.
- NO E/O PULMONARY HYPERTENSION. PASP 31 mmHg by TR jet.
- NO E/O LEFT VENTRICULAR HYPERTROPHY.
- NO E/O DIASTOLIC DYSFUNCTION.
- NO E/O PERICARDIAL EFFUSION.
- NO E/O INTRACARDIAC CLOT OR VEGETATIONS.
- INTACT IAS/IVS
- CONVENTIONL DOPPLER :

E TO A RATIO IS MORE THAN ONE IN LV INFLOW.

THERE IS NO GRADIENT ACROSS AV,LVOT OR RVOT
PASP FROM TR JET IS .31 mm OF Hg.

- COLOUR DOPPLER:

TRIVIAL TR

EF Slope	112	mm/sec		
Opening Amplitude	18			
Posterior leaflet				
E.P.S.S	02	mm		
Mitral valve prolapse				
Vegetations				
TRICUSPID VALVE	OBSERVED	NORMAL VALUES		
PULMONARY VALVE	OBSERVED	NORMAL VALUES		
EF Slope				
'A' Wave				
Midsystolic notch				
Flutter				
Other Findings				
AORTIC VALVE	OBSERVED	NORMAL VALUES		
Cuspal opening	17	mm		
Closure line	Central			
Eccentricity index	1			
Other Findings				
DIMENSIONS	OBSERVED	NORMAL VALUES		
1. Lvd (Diastolic)	33	26-52		
2. Lvd (Systolic)	23	24-42mm		
3. RVD (Diastolic)	17	7-23mm		
4. IVST (Diastolic)	08	6-11mm		
5. IVST (Systolic)	15			
6. LVPWT (Diastolic)	09	6-11mm		
7. LVPWT (Systolic)	15			
8. Aortic root	23	22-37mm		
9. left Atrium	33	19-40mm		
	STRUCTURE	REGURGRADING	VELOCITY m/sec	STENOSIS GRADIENT mm/Hg
			Max mean	Peak mean
MITRAL VALVE	NORMAL	0/3	/	/
TRICUSPID VALVE	NORMAL	TRIVIAL	/	/
PULMONARY VALVE	NORMAL	0/4	/	/
AORTIC VALVE	NORMAL	0/4	/	/

DR. P. H. CHHABLANI
M.B.B.S, DNB. (MEDICINE)
CONSULTANT PHYSICIAN AND CARDIOLOGIST.

DR. PURVI CHHABLANI
MBBS DNB. (Medicine)
Consultant Physician And Intensive
Reg No 77696



Dr-Plus Healthcare Centre

NATHANI HEIGHTS, B-Wing, Shop No. 42, Ground Floor, Opp. Mumbai Central Station (East), Mumbai - 400 008.

Patient's Name : SULEKHA KUMARI

Report Date : 11/09/2021

Referred By Dr. : DR. HARI CHHABLANI

Age : 25 Years

Sex : FEMALE

X- RAY CHEST PA

BOTH THE LUNG FIELDS ARE CLEAR .

THE HILAR SHADOWS APPEAR NORMAL.

THE COSTO -PHRENIC ANGLES ARE CLEAR.

THE CARDIAC SHADOWS APPEAR NORMAL.

THE TRACHIA IS CENTRAL IN POSITION.

THE BONY CAGE APPEARS NORMAL.


Rad|ologist

DR. A. J. MAZUMDAR

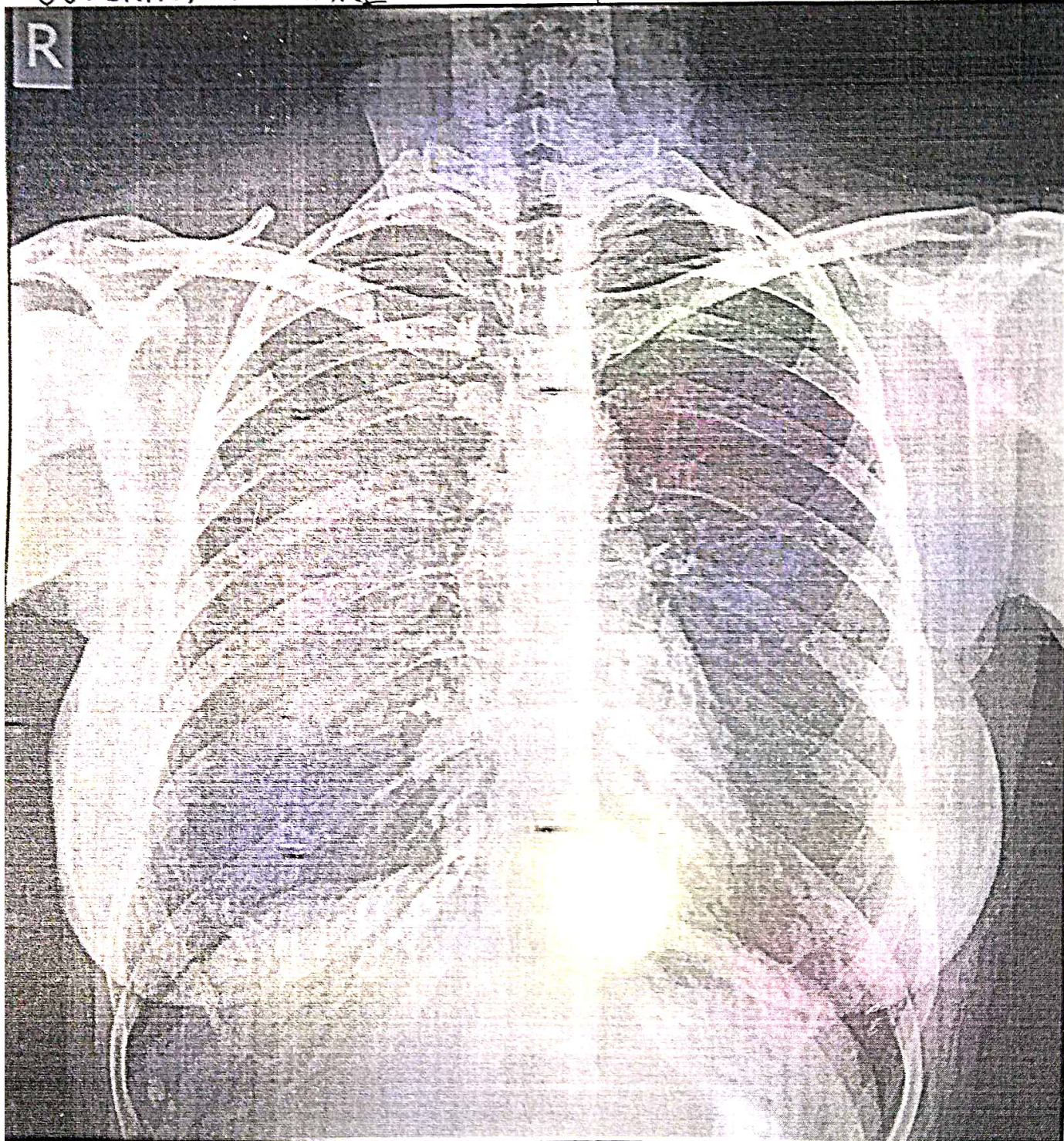
MD. DMRE, MDRD

**"DR. PLUS HEALTHCARE CENTRE"
NATHANI HEIGHTS', B-WING,
42, MUMBAI CENTRAL (EAST)**

SULEKHA KUMARI

25/F

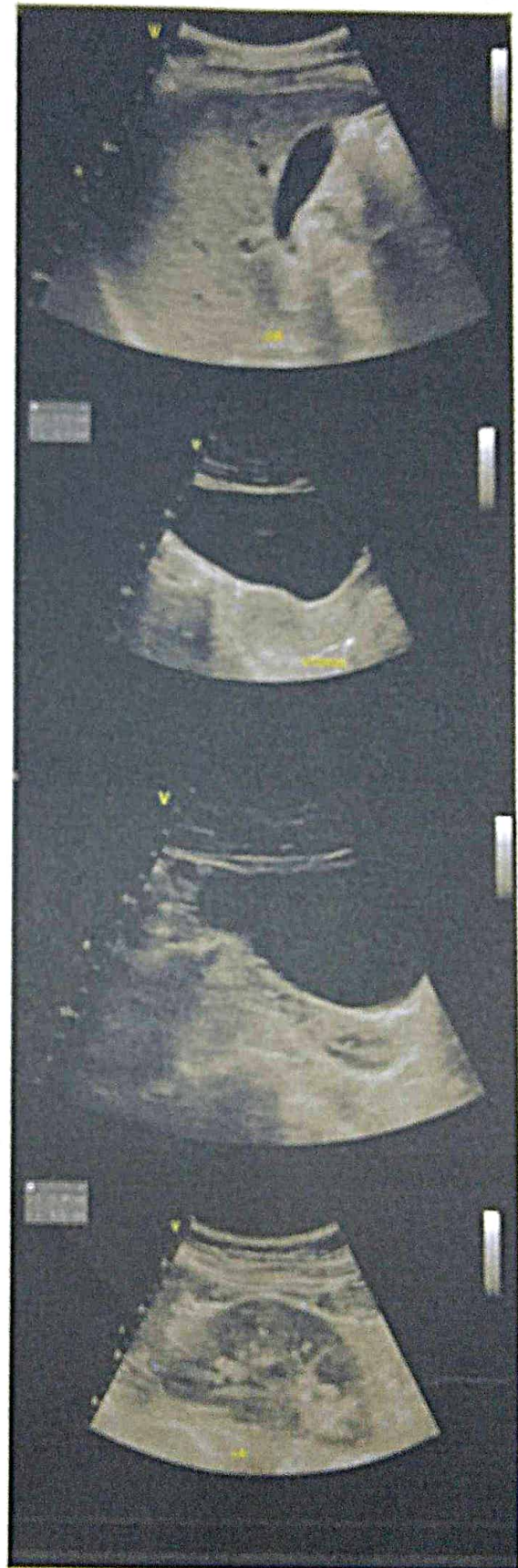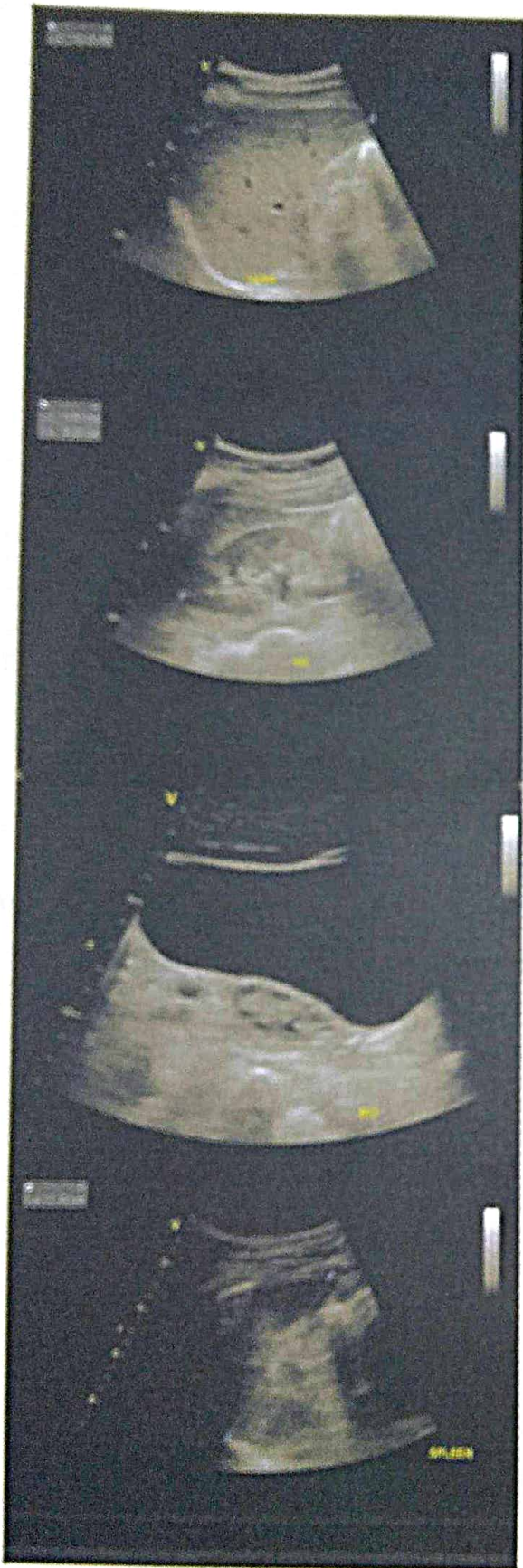11/09/2021



Name SULEKHA KUMARI

Sex Female

Age 25





Dr-Plus Healthcare Centre

NATHANI HEIGHTS, B-Wing, Shop No. 42, Ground Floor, Opp. Mumbai Central Station (East), Mumbai - 400 008.

Patient Name	: SULEKHA KUMARI	Sex:	Female
Doctor's Name	: SELF	Age:	25 Years
Date	: 11-09-2021		

ULTRASONOGRAPHY OF THE ABDOMEN AND THE PELVIS TVS:

The relevant sonographic findings include the following:

HEPATOBIILIARY APPARATUS

Mild fatty liver. No obvious focal parenchymal lesion is seen. Intrahepatic biliary radicals are not dilated. The portal vein and the common bile duct are normal.

GALL BLADDER

The gall bladder is adequately distended. The wall thickness is normal. No echogenic contents are noted in its lumen. There is no pericholecystic collection noted.

PANCREAS

The pancreas shows normal echogenicity and size. No focal or diffuse lesions are noted. No evidence of calcification is noted.

SPLEEN

The spleen appears normal in size (9.6 cm) and echogenicity. No focal or diffuse lesions are noted. No evidence of calcification is noted.

KIDNEYS

Right kidney measures : 9.9 x 4.0 cm , Left kidney measures : 10.1 x 4.7 cm. Both the kidneys appear normal in size, shape and echogenicity. Both the pelvi-calyceal system is normal and both corticomedullary differentiations are well maintained. There is no obvious focal or diffuse lesion noted. No evidence of any calculus seen in either kidney.

UTERUS

Uterus measures = 5.7 x 3.2 x 2.3 cms. The uterus is anteverted and anteflexed and normal in size. There are no focal or diffuse lesions noted. The endometrium appears thin (5-6 mms).

OVARIES

Both the ovaries are enlarged with polycystic pattern. Right ovary volume 17 ccs. Left ovary volume 16 ccs. No obvious adnexal mass is seen. Posterior pelvic-cul-de-sac is normal.

No other obvious pelvic mass is seen. No probe-tenderness is noted.

IMPRESSION: PCOD noted.


Dr. Parag Jhaveri
MBBS (BOM), DMRE(BOM)
Radio-Sonologist

**'DR. PLUS HEALTHCARE CENTRE'
NATHANI HEIGHTS', B-WING.
42 MUMBAI CENTRAL (EAST)**



Dr-Plus Healthcare Centre

NATHANI HEIGHTS, B-Wing, Shop No. 42, Ground Floor, Opp. Mumbai Central Station (East), Mumbai - 400 008.

Full Name

SULEKHA KUMARI

25/F

DATE:11/09/202

	Type of Test	Actual Reading	Normal Range
1	Fasting Blood Sugar	78.6	70-100 mg%
2	PPBS	120	110 TO 140 mg%
3	Total Cholesterol	185	120-200 mg%
4	VERY LOW DENSINTY LEVEL(VLDL)	20	10-30 mg/dl
5	High Density Lipid (HDL)	50	40-60 mg%
6	Low Density Lipid (LDL)	115	Upto 150
7	S. Triglycerides	125.1	50-150 mg%
8	CHOL/HDL	3.7	Upto 5
9	HDL/LDL	0.4	
10	S. Creatinine	0.90	0.5-1.2 mg%
11	Blood Urea Nitrogen (BUN)	14.5	7-21 mg%
12	BUN/CREAT RATIO	16.1	
13	S. Proteins	6.7	6.0-7.9 mg%
14	(a) Albumin	3.5	3.5-5.5 mg%
15	(b) Globulin	3.2	2.0-3.5 mg%
16	A/G RATIO	1.09	
17	S. Bilirubin	0.90	0.3-1.3mg%
18	(a) Direct	0.70	0.0-0.8 mg%
19	(b) Indirect	0.20	0.0-0.5 mg%
20	SGOT (AST)	21.13	05-34 IU
21	SGPT (ALT)	28.05	05-40 IU
22	GGTP (GGT)	35.25	05-50 IU
23	SGOT/SGPT	0.7	
24	HBA1C	5.62	UPTO 6.5
25	S. Alkaline Phosphatase	91.2	30-115 IU
26	T3	132.5	80-180ng/dl
27	T4	8.85	4.6-12 ug/dl
28	TSH	3.0	0.4-4.0 mIU/L
29	SERUM URIC ACID	5.21	2.5-7.2mg/dl
30	URINE SUGAR PP	ABSENT	
31	URINE SUGAR FASTING	ABSENT	
32	BLOOD GROUP	"B" POSITIVE	

DR. RAKESH PATKAR
M.D., D.N.B. (Pathology)
Reg. No. 2013/05/1660



Dr-Plus Healthcare Centre

NATHANI HEIGHTS, B-Wing, Shop No. 42, Ground Floor, Opp. Mumbai Central Station (East), Mumbai - 400 008.

Full Name of life to be assured:

SULEKHA KUMARI

25/F

DATE:11/09/2021

HAEMOGRAM

		Normal Range	
1.	Red Blood Cell Count	3.6	[M : 4.5 - 5.6 / F : 3.5 - 5.5/cu.mm]
2.	Hb%	11.5	[M: 14-18 / F: 11-16%]
3.	Hematocrit	36	[M : 40-53 / F : 30-47 %]
4.	Indices:		
(a)	MCV(Mean Corpuscular Volume)	83	[79-101 cu.mi.]
(b)	MCH(Mean Corpuscular Hb)	31	[27-32 pg]
(c)	MCHC(Mean Corpuscular Hb Concentration)	34	[32-38%]
5.	Morphology		
	Macrocytes :	--	Microcytes: -- Hypochromia: --
	Piokilocytosis:	--	Anisocytosis: --
6.	Target cells:	--	
	Spherocytes:	--	Elliptocytes: --
7.	TOTALW.B.C.Count	6,500	{4000-11000/cu.mm}
Differential Count			
a)	Neutrophils :	60	[45 - 70%]
b)	Lymphocytes :	30	[20 - 45%]
c)	Eosinophils:	05	[01 - 06%]
d)	Monocytes:	05	[00 - 08%]
e)	Basophils :	00	[00 - 01%]
8.	Platelets : 2.630	1.5-4.5 Lacks/cu.mm	
9.	Erythrocyte Sedimentation Rate:09	20 mm at end of 1 hour	
		Method : Westergrens	

ROUTINE URINE EXAMINATION (RUA)

1. Physical Examination:

(i)	Colour:	PALE YELLOW	(ii)	Sediment:	CLEAR
(iii)	Transparency:	ABSENT	(iv)	Reaction:	ACIDIC
(v)	Specific gravity	1.015			

2. Chemical Examination:

(i)	Protein :	ABSENT	(ii)	Sugar:	ABSENT
(iii)	Bile salt:	ABSENT	(iv)	Bile pigment:	ABSENT

3. Microscopic Examination:

(i)	Red Blood Cells:	+	(ii)	Epithelial Cells:	ABSENT
(iii)	Crystals:	ABSENT	(iv)	Pus Cells:	02 TO 03/HPF
(v)	Casts:	ABSENT	(vi)	Deposits:	ABSENT
(vii)	Bacteria's :	ABSENT			

DR. RAKESH PATKAR
M.D., D.N.B. (Pathology)
Reg. No. 2013/05/1660



Dr. Hari Chhablani

Cardiometabolic Physician & Intensivist
M.B.B.S., F.C.C.P. (RESP. MED.), PGDHMM,
PGDMLS, FELLOW INTENSIVE CARE MED.

ATTACHED TO: Wockhardt Hospital • Saifee Hospital • Apollo Spectra Hospital

NATHANI HEIGHTS, B-Wing, Shop No. 42, Ground Floor, Opp. Mumbai Central Station (East),
Mumbai - 400 008. • Cell : 98206 46163 • E : drharichhablani@gmail.com

PHYSICIAN REPORT

11/09/2021

NAME : SULEKHA KUMARI

AGE/SEX: 25/F

PRESENTING COMPLAINS: K/C/O PCOS SINCE 3 YEARS ON TREATMENT , HAIR FALL , CHRONIC
CONSTIPATION .

PAST HISTORY: NIL

TREATMENT HISTORY : HOMEOPATHY TREATMENT FOR PCOS .

FAMILY HISTORY: NOT SIGNIFICANT

ADDICTION: NIL

P: 92/MIN

BP: 118/76

RS: CLEAR

CVS: S1,S2 REGULAR

PA: SOFT

CNS: CLINICALLY NAD

ECG: WNL

CXR: WNL

LABS: ATTACHED

EYE EXAMINATION B/E : NEAR VISION - BL N6 DISTANT VISION - 6/6 COLOUR VISION - NORMAL

IMPRESSION : REFER TO GYNECOLOGIST AND DERMATOLOGIST .

SYP. DUPHALAC 10 TO 15 ML- HS

DR. HARI CHHABLANI

DR. HARI CHHABLANI
M.B.B.S.;F.C.C.P.(RESP MEDICINE) PGDHMM, PGDMLS
FELLOW INTENSIVE CARE
MMC REG. NO. - 91702