



DR. GYNEAECOLOGIST CONSULTATION  
CONSULTANT GYNAECOLOGIST



KURNOOL

Organization Name : ARCOFEMI HEALTHCARE PVT LTD

ReF. Letter No. :

Name : Miss. RANI NAGIRI LEELA

Age : 34 Year(s) / Female

UMR No : KUU186384

Ref. Doctor :

Address : KURNOOL  
KURNOOL, Andhra Pradesh

Visit Type : NORMAL

Phone No : 9704932277 , 9491313347

Consult.No : KUOC340678

Date : 13-Mar-2024 10:08 am

Chief Complaints & H/O Present illness :

No gynec complaints.

Past History

	Yes
HTN	
DM	
IHD	
Others	

Personal History

	Yes
Smoking	
Alcohol	

Adv.

1) urine cl.

Investigations :

Provisional Diagnosis :

KUU186384

KUOC340678



A UNIT OF SAHRUDAYA HEALTHCARE (KURNOOL) PVT. LTD.

Sy. No. 419/B2, Opp. Old Edga, Near RTC Bus Stand, Kurnool | Ph : 040-6833 4455



Dr. PHYSICIAN CONSULTATION  
CONSULTANT GENERAL PHYSICIAN



**MEDICOVER**  
HOSPITALS

KURNOOL

Organization Name : ARCOFEMI HEALTHCARE PVT LTD

Ref. Letter No. :

Name : Miss. RANI NAGIRI LEELA

Age : 34 Year(s) / Female

UMR No : KUU186384

Ref. Doctor :

Address : KURNOOL  
KURNOOL, Andhra Pradesh

Visit Type : NORMAL

Phone No : 9704932277 , 9491313347

Consult.No : KUOC340677

Date : 13-Mar-2024 10:08 am

Chief Complaints & H/O Present illness :

Past History

	Yes
HTN	
DM	
IHD	
Others	

no iscm

Personal History

	Yes
Smoking	
Alcohol	

Investigations :

Uric acid  
2-4

Adv

1. Tab Febutar 40mg

1-0-0

Provisional Diagnosis :

Smyy

KUU186384

KUOC340677



A UNIT OF SAHRUDAYA HEALTHCARE (KURNOOL) PVT. LTD.

Sy. No. 419/B2, Opp. Old Edga, Near RTC Bus Stand, Kurnool | Ph : 040-6833 4455



**Dr. DENTAL CONSULTATION**  
**CONSULTANT DENTAL**



Organization Name : ARCOFEMI HEALTHCARE PVT LTD

ReF. Letter No. :

Name : Miss. RANI NAGIRI LEELA

Age : 34 Year(s) / Female

UMR No : KUU186384

Ref. Doctor :

Address : KURNOOL  
 KURNOOL, Andhra Pradesh

Visit Type : NORMAL

Phone No : 9704932277 , 9491313347

Consult.No : KUOC340676

Date : 13-Mar-2024 10:08 am

**Chief Complaints & H/O Present illness :**

**Past History**

	Yes
HTN	
DM	
IHD	
Others	

**Personal History**

	Yes
Smoking	
Alcohol	

**Investigations :**

**Provisional Diagnosis :**

KUU186384



KUOC340676



A UNIT OF SAHRUDAYA HEALTHCARE (KURNOOL) PVT. LTD.

Sy. No. 419/B2, Opp. Old Edga, Near RTC Bus Stand, Kurnool | Ph : 040-6833 4455



**MEDICOVER**  
HOSPITALS

**DEPARTMENT OF HAEMATOLOGY**

**KURNOOL**

<b>Patient Name</b> : Miss. RANI NAGIRI LEELA	<b>Age /Sex</b> : 34 Y(s)/Female
<b>Bill Date</b> : 13-Mar-2024 10:08 AM	<b>UMR No</b> : KUU186384
<b>Received Date</b> : 13-Mar-2024 10:47 AM	<b>Bill No</b> : KUB316872
<b>Report Date</b> : 13-Mar-2024 01:11 PM	<b>Result No</b> : RES488864
<b>Ref By</b> : DR.ANY CONSULTATION	<b>Org.Name</b> : ARCOFEMI HEALTHCARE PVT LTD
	<b>Specimen</b> : Blood

**COMPLETE BLOOD COUNT**

<u>Parameters</u>	<u>Result</u>	<u>Biological Reference Intervals</u>	<u>Method</u>
WBC	5,800	4000 - 11000 cells/cumm	Automated Cell Counter
* RED BLOOD CELLS	* 3.70 mill/cumm.	3.9 - 5.0 milli/cumm	Automated Cell Counter Electrical Impedance
HAEMOGLOBIN	12.5 g/dl	11.5 - 16.0 g/dl	Automated Cell Counter cyanmethemoglobin
PCV (PACKED CELL VOLUME)	* 34.9 %	37 - 52 %	Automated Cell Counter Calculated
MCV (MEAN CORPUSCULAR VOLUME)	95 fl	80.0 - 100.0 fl	Automated Cell Counter Calculated
MCH (Mean Corpuscular Hemoglobin)	33.8 pg	27.0 - 34.0 pg	Automated cell counter calculated
MCHC (Mean Corpuscular Hemoglobin Concentration)	35.7 g/dL	32.0 - 36.0 g/dL	Automated cell counter calculated
PLATELET COUNT	3.88 Lakhs/cumm.	1.4 - 4.0 Lakhs/cumm.	Automated Cell Counter Electrical Impedance
* RDW-SD	* 12.5 fl	37.0 - 54.0 fl	FULLY AUTOMATED HAEMATOLOGY ANALYSER
PDW	11.8 fl	9.0 - 17.0 fl	FULLY AUTOMATED HAEMATOLOGY ANALYSER
MPV	* 7.7 fl	9.0 - 13.0 fl	FULLY AUTOMATED HAEMATOLOGY ANALYSER
PCT	0.298 %	0.17 - 0.35 %	FULLY AUTOMATED HAEMATOLOGY ANALYSER
NEUTROPHILS	* 47.4 %	50.0 - 70.0 %	Microscopy
LYMPHOCYTES	* 43.1 %	20.0 - 40.0 %	Microscopy
MONOCYTES	8.2 %	1.0 - 10.0 %	Microscopy
EOSINOPHILS	1.0 %	1.0 - 6.0 %	Microscopy
BASOPHILS	0.3 %	0.0 - 1.0 %	Microscopy

\*\*\* End Of Report \*\*\*

Verified By:

DR.K VASUNDHARA, MBBS, MD  
CONSULTANT PATHOLOGIST

A UNIT OF SAHRUDAYA HEALTHCARE (KURNOOL) PVT. LTD.

Sy. No. 419/B2, Opp. Old Edga, Near RTC Bus Stand, Kurnool | Ph : 040-6833 4455





## Department Of Laboratory



<b>Patient Name</b> : Miss. RANI NAGIRI LEELA	<b>Age /Sex</b> : 34 Y(s)/Female
<b>Bill Date</b> : 13-Mar-2024 10:08 AM	<b>UMR No.</b> : KUU186384
<b>Report Date</b> : 13-Mar-2024 10:47 AM	<b>Bill No.</b> : KUB316872
<b>Received Date</b> : 13-Mar-2024 01:01 PM	<b>Result No</b> : RES488861
<b>Ref By</b> : DR.ANY CONSULTATION	<b>Org.Name</b> : ARCOFEMI HEALTHCARE PVT LTD
	<b>Specimen</b> : URINE

<u>Parameters</u>	<u>Result</u>	<u>Biological Reference</u>	<u>Method</u>
<b>COMPLETE URINE TEST</b>			
COLOUR	PALE YELLOW	Pale yellow	
PH	6.0	5.0 - 7.5	
SP. GRAVITY	* 1.030	1.010 - 1.025	
BILE SALTS	NEGATIVE	Negative	
BILE PIGMENTS	NEGATIVE	Negative	
KETONE BODIES	NEGATIVE	Negative	
BLOOD	TRACE	Absent	
SUGAR	NIL	Negative	
ALBUMIN	NIL	Negative	
<b>MICROSCOPIC EXAMINATION</b>			
PUS CELLS	* 2-3	1 - 2	
RBC	* 4-6	0.0 - 1.0	
EPITHELIAL CELLS	* 1-2	0 - 4	
CASTS	NIL	Absent	
CRYSTALS	NIL	Absent	

### BLOOD GROUPING RH TYPING

**BLOOD GROUP** " B "

**Rh TYPING** POSITIVE

### COMMENTS

- 1.RECONFIRM THE BLOOD GROUP & RH TYPING ALONG WITH CROSS MATCHING BEFORE BLOOD TRANSFUSSION.
- 2.RECENT BLOOD TRANSFUSSION IF ANY,INTERFERES WITH INTERPRETATION OF BLOOD GROUPING.
- 3.SUB GROUPS & BOMBAY BLOOD GROUP NEEDS TO BE FURTHER VERIFIED.



<u>Parameters</u>	<u>Result</u>	<u>Biological Reference</u>	<u>Method</u>
<b>Erythrocyte Sedimentation Rate (ESR)</b>	08 mm/Hour	0 - 20 mm/Hour	westergren's
<b>BLOOD UREA NITROGEN (BUN)</b>	9.9 mg/dL	7.0 - 21.0 mg/dL	Urease kinetic
<b>GLYCOSYLATED HAEMOGLOBIN (HbA1c)</b>	5.5 %	NORMAL : 4.0 - 6.0 % increased risk of diabetes : > 6.0 - 6.40 % indicate diabetes : > 6.5 - 7.0 %	Immunturbidimetric
<b>URINE SPOT PROTEIN CRETININE RATIO</b>			
URINE PROTEINS	1.4 mg/dL	0.0 - 11.9 mg/dL	
URINE CREATININE	102.5 mg/dL	30 - 125 mg/dL	
PROTEIN/CREATININE RATIO	0.013	< 0.2	
<b>LIPID PROFILE</b>			
TOTAL CHOLESTEROL	178 mg/dl	0 - 200 mg/dl	Cholesterol esterase
SERUM TRYGLYCERIDES	56 mg/dL	Border line : 200 - 240 mg/dL Desirable : < 200 mg/dL High : > 400 mg/dL	Lipoprotein Lipase
HDL CHOLESTEROL	51 mg/dL	Desirable : >= 40 mg/dL	Direct measure-PEG
LDL CHOLESTEROL	116 mg/dL	Border line : 100 - 130 mg/dL Desirable : < 100 mg/dL High : > 130 mg/dL	Calculated
VLDL	11 mg/dL	0 - 40 mg/dL	Calculated
<b>FBS (FASTING BLOOD GLUCOSE)</b>			
<b>FASTING PLASMA /SERUM GLUCOSE (FBS)</b>	88 mg/dL	70 - 110 mg/dL	Hexokinase
<b>CREATININE</b>	0.6 mg/dl	0.6 - 1.5 mg/dl	Kinetic jaffe reaction
<b>T3 T4 TSH</b>			
<b>TRI-IODO THYRONINE (T3)</b>	166.2 ng/dL	55 - 205 ng/dL	Enzyme Linked Fluorescence Assay
<b>THYROXINE (T4)</b>	10.0 µg/dL	3.5 - 12.50 µg/dL	Enzyme Linked Fluorescence Assay
<b>THYROID STIMULATING HORMONE (TSH)</b>	2.46 µIU/mL	0.25 - 5.5 µIU/mL	Enzyme Linked Fluorescence Assay
<b>LIVER FUNCTION TESTS (LFT)</b>			
<b>TOTAL BILIRUBIN</b>	0.5 mg/dL	0.2 - 1.1 mg/dL	Diazotization
<b>DIRECT (CONJUGATED) BILIRUBIN</b>	0.1 mg/dL	0.0 - 0.25 mg/dL	Diazotization
<b>SGOT (AST)</b>	33 U/L	9 - 48 U/L	Uv kinetic with P5P
<b>SGPT (ALT)</b>	18 U/L	0.0 - 50.0 U/L	Uv kinetic with P5P
<b>ALKALINE PHOSPHATASE (ALP)</b>	69 U/L	37 - 110 U/L	p-NPP AMP Buffer
<b>TOTAL SERUM PROTEINS</b>	* 5.7 g/dL	6.4 - 8.2 g/dL	Biuret reaction
<b>SERUM ALBUMIN</b>	4.3 g/dL	3.5 - 5.2 g/dL	BCG Dye Method
<b>URIC ACID</b>	* 7.6 mg/dL ↑	2.6 - 6.0 mg/dL	URICASE
<b>TOTAL SERUM PROTEINS</b>	* 5.7 g/dL	6.4 - 8.2 g/dL	Biuret reaction
<b>POST PRANDIAL PLASMA / SERUM GLUCOSE (PPBS)</b>			
<b>POST PRANDIAL PLASMA / SERUM GLUCOSE (PLBS)</b>	101 mg/dL	UPTO - 140 mg/dL	HEXOKINASE



Parameters

Result

Biological Reference

Method

\*\*\* End Of Report \*\*\*

Verified By:

DR DEVAJIID SREEATHA

A handwritten signature in black ink, appearing to read 'Devajiid Sreeatha', is written over the printed name.

ST



# MEDICOVER HOSPITALS-KURNOOL

51/1-E2, 1-E3, 1-E4  
Opp Old Eidga, Near RTC Bus Stand,



## MEDICOVER HOSPITALS

### DEPARTMENT OF RADIOLOGY

KURNOOL

<b>Patient Name</b>	: Miss. RANI NAGIRI LEELA	<b>Age / Sex</b>	: 34 Y(s)/Female
<b>Bill Date</b>	: 13-Mar-2024 10:08 AM	<b>UMR No.</b>	: KUU186384
<b>Received Date</b>	: 13-Mar-2024 10:08 AM	<b>Bill No.</b>	: KUB316872
<b>Report Date</b>	: 13-Mar-2024 02:14 PM	<b>Result No</b>	: RES488926 / 0
<b>Ref By</b>	: DR.ANY CONSULTATION	<b>Org.Name</b>	: ARCOFEMI HEALTHCARE PVT LTD

### X-RAY CHEST PA VIEW

#### FINDINGS

Cardiac shadow within normal limits.

Aorta normal.

Mediastinum normal.

Lung fields are clear.

Hilar and bronchovascular markings are normal bilaterally.

Both domes of diaphragm are regular.

Both costophrenic angles normal.

Bony thoracic cage and soft tissues of the chest wall normal.

#### IMPRESSION

**No significant abnormality detected.**

#### **SUGGESTED CLINICAL CORRELATION.**

\*\*\* End Of Report \*\*\*

  
DR.D SREENIVASULU, MBBS,MD  
CONSULTANT RADIOLOGIST

Verified By :

Approved By :

Dispatched By :

A UNIT OF SAHRUDAYA HEALTHCARE (KURNOOL) PVT. LTD.

Sy. No. 419/B2, Opp. Old Edga, Near RTC Bus Stand, Kurnool | Ph : 040-6833 4455





# PRASANTHI HOSPITAL

SUPERSPECIALITY  
HEART & EYE CARE

Best in care

Patient Name : Rani Nagiri Leela Age : 34 Gender : M  F

Address : Atmakur

Date : 13/03/24

BP : 121/73

PR : 102/BPM

VISUAL ACUITY  
RE -6/6  
LE -6/6


CHIEF COMPLAINTS came for eye checkup.

SYSTEMIC ILLNESS no

CURRENT MEDICATION no

ALLERGIES

ANTERIOR SEGMENT



DIAGNOSIS

TREATMENT

normal smd

sdv

**Dr. D. SATHYA KUMARI**  
MS, FCRS, FICO (UK)  
Consultant Ophthalmologist  
Phaco Cornea Refractive Surgeon  
Reg. No: 61001  
PRASANTHI HOSPITAL, KURNOOL-2.

BE

Resque 6/10  
3rd



**Dr. OPHTHAMOLOGY CONSULTATION**  
**CONSULTANT OPHTHALMOLOGIST**



**KURNOOL**

Organization Name : ARCOFEMI HEALTHCARE PVT LTD

ReF. Letter No. :

Name : Miss. RANI NAGIRI LEELA

Age : 34 Year(s) / Female

UMR No : KUU186384

Ref. Doctor :

Address : KURNOOL  
KURNOOL, Andhra Pradesh

Visit Type : NORMAL

Phone No : 9704932277 , 9491313347

Consult.No : KUOC340679

Date : 13-Mar-2024 10:08 am

**Chief Complaints & H/O Present illness :**

*Vn - 6/6  
- 6/6*

*W - 21/21  
- 21/21*

*lids (n)*

*OS  
OD  
lids (n)  
SNO  
replaced*

**Past History**

	Yes
HTN	
DM	
IHD	
Others	

**Personal History**

	Yes
Smoking	
Alcohol	

**Investigations :**

*normal study.*

**Revisonal Diagnosis :**

**Dr.D. SANTHA KUMARI**  
MS,FCRS, FICO (UK)  
Consultant Ophthalmologist  
Phaco Cornea Refractive Surgeon  
Reg. No: 61001  
PRASANTHI HOSPITAL, KURNOOL-2.

KUU186384

KUOC340679



A UNIT OF SAHRUDAYA HEALTHCARE (KURNOOL) PVT. LTD.

Sy. No. 419/B2, Opp. Old Edga, Near RTC Bus Stand, Kurnool | Ph : 040-6833 4455



# MEDICOVER HOSPITALS-KURNOOL

51/1-E2, 1-E3, 1-E4  
Opp Old Eidga, Near RTC Bus Stand,



## DEPARTMENT OF CARDIOLOGY

KURNOOL

<b>Name</b>	: Miss. RANI NAGIRI LEELA	<b>Age /Sex</b>	: 34 Y(s)/Female
<b>Bill Date</b>	: 13-Mar-2024 10:08 AM	<b>UMR No</b>	: KUU186384
<b>Received</b>	: 13-Mar-2024 10:08 AM	<b>Bill No</b>	: KUB316872
<b>Report Date</b>	: 13-Mar-2024 12:50 PM	<b>Result No</b>	: RES488852
<b>Ref By</b>	: DR.ANY CONSULTATION	<b>Org.Name</b>	: ARCOFEMI HEALTHCARE PVT LTD

### 2D ECHOCARDIOGRAPHY/COLOR DOPPLER

**MITRAL VALVE** : NORMAL  
**AORTIC VALVE** : NORMAL  
**TRICUSPID VALVE** : NORMAL  
**PULMONARY VALVE** : NORMAL  
**LEFT ATRIUM** : 2.6 CMS  
**AORTA** : 2.5 CMS  
**LEFT VENTRICLE** : EDD :4.5 CMS      ESD :3.0 CMS      EF : 62 %  
**RIGHT VENTRICLE** : NORMAL  
**RIGHT ATRIUM** : NORMAL  
**PULMONARY ARTERY** : NORMAL  
**IAS** : ANERYSM BULGING INTO RA  
**IVS** : INTACT  
**PERICARDIUM** : NORMAL  
**DOPPLER** : AJV=1.3m/sec. PJV=1.0m/sec.1+MR.1+TR.  
**CONCLUSION** : NO RWMA

NORMAL LV SYSTOLIC FUNCTION  
TRIVIAL MR, NO AR, TRIVIAL TR, NO PAH  
NO PE/NO LA, LV CLOTS

\*\*\* End Of Report \*\*\*

DR.CARDIOLOGY CONSULTATION  
CONSULTANT CARDIOLOGIST



34 Years

LEEIA  
Female

13-Mar-24 11:54:00 AM

MEDICOVER HOSPITAL'S, KURNOOL

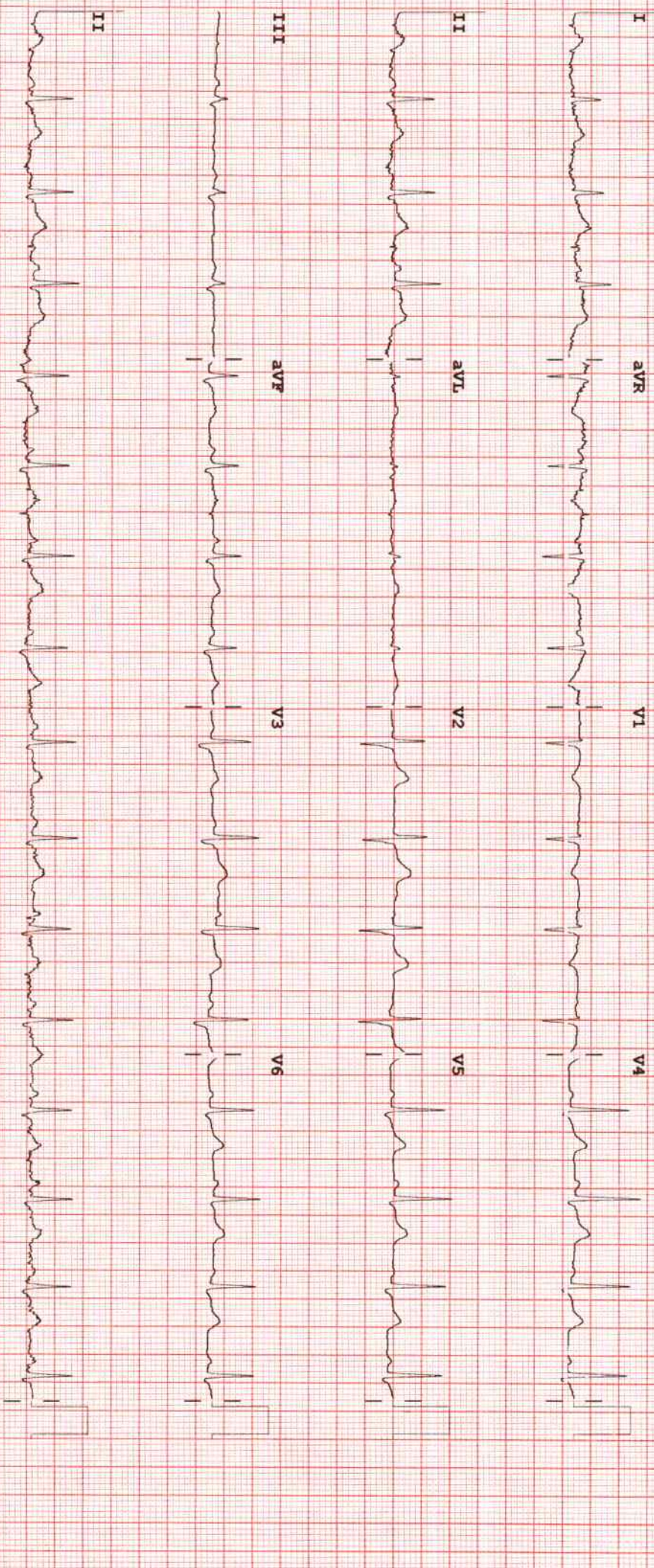
Rate 92 Sinus rhythm.....Normal P axis, V-rate 50- 99  
 PR 125 Baseline wander in lead(s) I, II, aVR, aVF, V1, V2, V3, V4, V5, V6  
 QRSD 90  
 QT 376  
 QTc 466

--AXIS--  
 P 71  
 QRS 44  
 T 31

- NORMAL ECG -

12 Lead; Standard Placement

Unconfirmed Diagnosis



Device: Speed: 25 mm/sec Limb: 10 mm/mV Chest: 10.0 mm/mV

PHILIPS

F 50~ 0.50-100 Hz W PH100B CL P2

REORDER M3709A

011





**MEDICOVER HOSPITALS-KURNOOL**

51/1-E2, 1-E3, 1-E4  
Opp Old Eidga, Near RTC Bus Stand,



**DEPARTMENT OF RADIOLOGY**

<b>Patient Name</b> : Miss. RANI NAGIRI LEELA	<b>Age /Sex</b> : 34 Y(s)/Female
<b>Bill Date</b> : 13-Mar-2024 10:08 AM	<b>UMR No.</b> : KUU186384
<b>Received Date</b> : 13-Mar-2024 10:08 AM	<b>Bill No.</b> : KUB316872
<b>Report Date</b> : 13-Mar-2024 01:56 PM	<b>Result No</b> : RES488911 / 0
<b>Ref By</b> : DR.ANY CONSULTATION	<b>Org.Name</b> : ARCOFEMI HEALTHCARE PVT LTD

**U/S ABDOMEN - PELVIS**

**FINDINGS**

**LIVER** : Normal in size and normal echotexture. No focal lesions seen. No Intra hepatic biliary ductal dilatation.

**CBD & PV** : Normal.

**GALL BLADDER** : Well distended. No gallstones. Gall Bladder wall thickness is normal

**PANCREAS** : Visualized head of pancreas appears normal in size with echotexture. No focal lesions. Pancreatic duct normal. No Pancreatic Calcifications.

**SPLEEN** : Normal in size with normal echotexture. No focal lesions.

**KIDNEYS** : Right kidney normal in size (10.3 x 4.4cm) and position. Cortico medullary differentiation is well made out. No e/o calculus / Hydronephrosis.

Left kidney normal in size (9.6 x 5.5cm) and position. Cortico medullary differentiation is well made out. No e/o calculus / Hydronephrosis.

**URINARY BLADDER** : Well Distended.No vesical calculus. Bladder wall thickness is normal.

**Uterus** : Normal in size (6.6 x 3.4 x 5.2cm) and normal echotexture  
No focal lesions. Endometrial thickness is 12mm.

**Ovaries** : Both ovaries are normal in size with normal echotexture.

Right ovary : 4.5 x 2.4cm with 2cm follicle. Left ovary : 3.9 x 2.2cm

**IVC, Aortic and Para aortic areas** normal.

No free fluid in the abdomen.

**IMPRESSION**

**No significant abnormality detected.**

**ADVICED: Clinical correlation and kindly discuss if necessary not for medico legal purpose**

\*\*\* End Of Report \*\*\*

DR.C.A.SANTOSH VARMA  
CONSULTANT RADIOLOGIST

Verified By :

Approved By :

Dispatched By :