

mrs. Barkha Verma

F-Male Years = 33

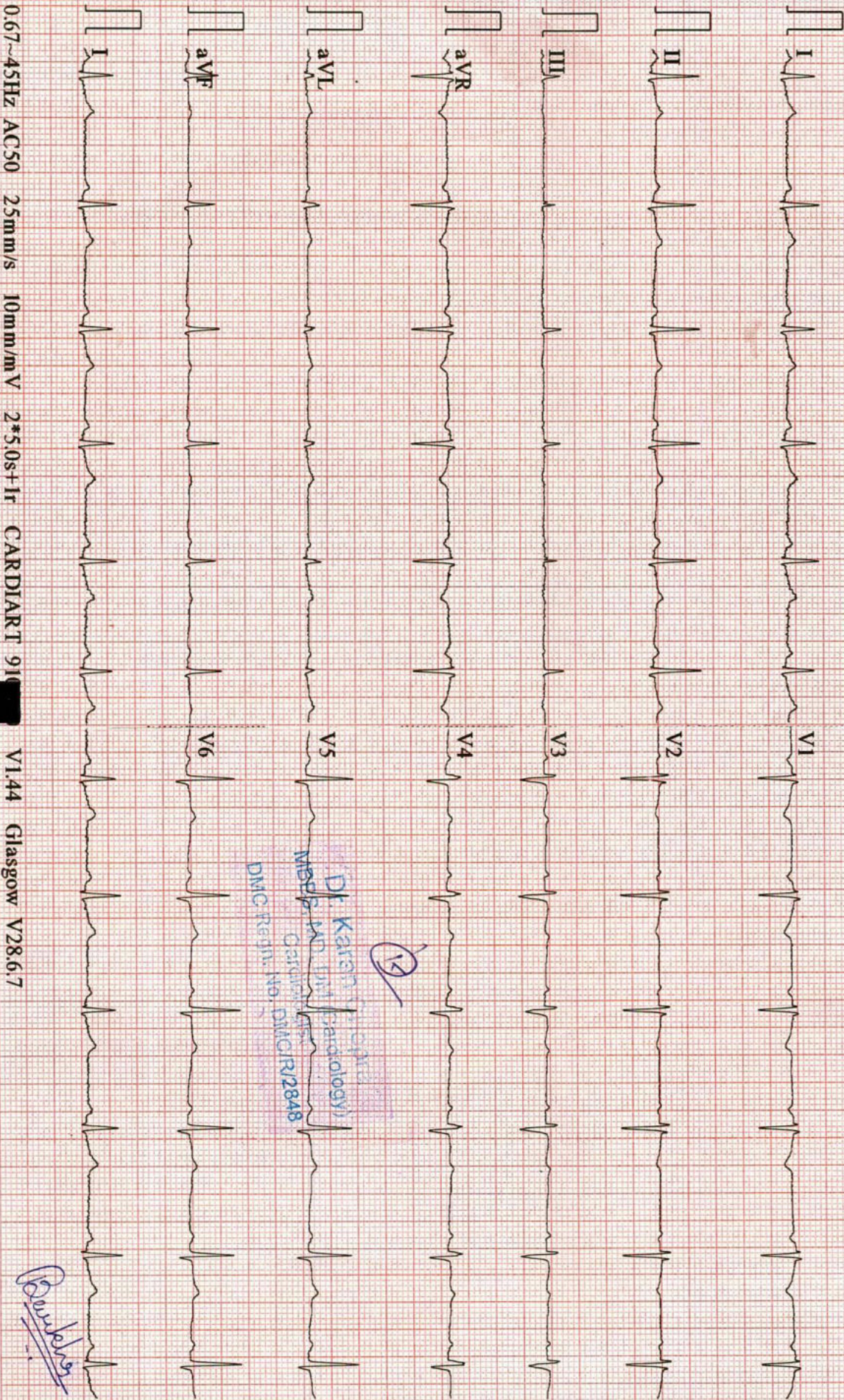
Req. No. :

HR	: 69	bpm
P	: 100	ms
PR	: 152	ms
QRS	: 80	ms
QT/QTcBz	: 388/416	ms
P/QRS/T	: 23/51/21	°
RV5/SV1	: 0.825/0.626	mV

Diagnosis Information:

Sinus rhythm
 rS'(V1) - probable normal variant
 Poor R wave progression
 Septal T wave abnormality is nonspecific
 Borderline ECG

Report Confirmed by:



12

Dr. Karan (Cardiology)
 MBBS, MD (Internal Medicine)
 Cardiology Registrar
 DMC Regn. No. DMC/CR/2848

Bamber

THE DIAGNOSTIC & IMAGING CENTRE

Plot No. 147, 2nd Floor, Main Road, Sec. 7,
Dwarka, New Delhi-110078 Ph. 011-49078567

BARKHA VERMA

TREADMILL TEST REPORT

ID : 3505
DATE : 08-11-2022
AGE/SEX : 33 / F
HT/WT : 0 / 0
REF. BY :

PROTOCOL : Bruce
HISTORY :
INDICATION : Checkup/Physical fitness,
MEDICATION :

PHASE	TOTAL TIME	STAGE TIME	SPEED Km/Hr	GRADE %	H.R. bpm	B.P. mmHg	RPP x100	ST LEVEL (MM)			METS
								II	V1	V5	
SUPINE					65	120 / 80	78	0.6	0.5	1	
STANDING					65	120 / 80	78	1.2	0.2	1.4	
HYPERVENT					71	120 / 80	85	0.7	0.2	0.9	
Stage 1	2:55	0:12	2.7	10	98	130 / 80	127	0.9	0.5	2.2	4.07
Stage 2	5:55	2:55	4	12	114	140 / 80	159	0.6	0.4	1	7.04
Stage 3	8:55	2:55	5.4	14	135	150 / 80	202	0.3	0.3	0.5	9.92
Stage 4	11:55	2:55	6.7	16	144	160 / 80	230	-0.2	0.2	-0.5	13.89
Stage 5	14:55	2:55	8	18	157	170 / 80	266	-0.2	0.5	-0.5	19.83
Stage 6	15:24	0:24	8.8	20	163	170 / 80	277	-0.4	0.8	-0.4	20.00
EK EXERCISE	15:34	0:34	8.8	20	166	170 / 80	282	-0.5	0.2	-0.4	20.00
RECOVERY	16:56	0:55			104	160 / 80	166	0.4	0.7	0.4	
RECOVERY	17:56	1:55			91	150 / 80	136	0	0.3	0.1	
RECOVERY	18:56	2:55			86	140 / 80	120	0.2	0.3	0	
RECOVERY	19:40	3:39			79	120 / 80	94	0.3	0.3	0.3	

RESULTS

EXERCISE DURATION : 15:34
MAX HEART RATE : 166 bpm
MAX BLOOD PRESSURE : 170 / 80 mm Hg
REASON OF TERMINATION : Achieved THR,
BP RESPONSE : Normal,
ARRHYTHMIA : None,
H.R. RESPONSE : Normal Chronotropic Response,
IMPRESSIONS :
Negative for Provocable myocardial ischemia,

MAX WORK LOAD : 20.00 METS

Barkha

DR. KARAN GUPTA
MEBS, MPT (Cardiology)
DMC Regn. No. DMC/R/2848

Technician :

THE DIAGNOSTIC & IMAGING CENTRE

BARKHA VERMA
 I.D. 3505
 Age 33/F
 Date 08-11-2022

RATE 65bpm
 B.P. 120/80

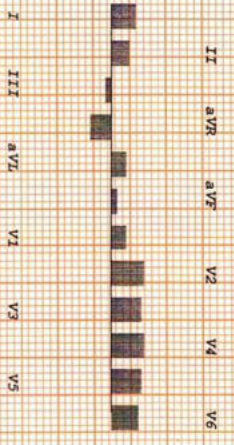
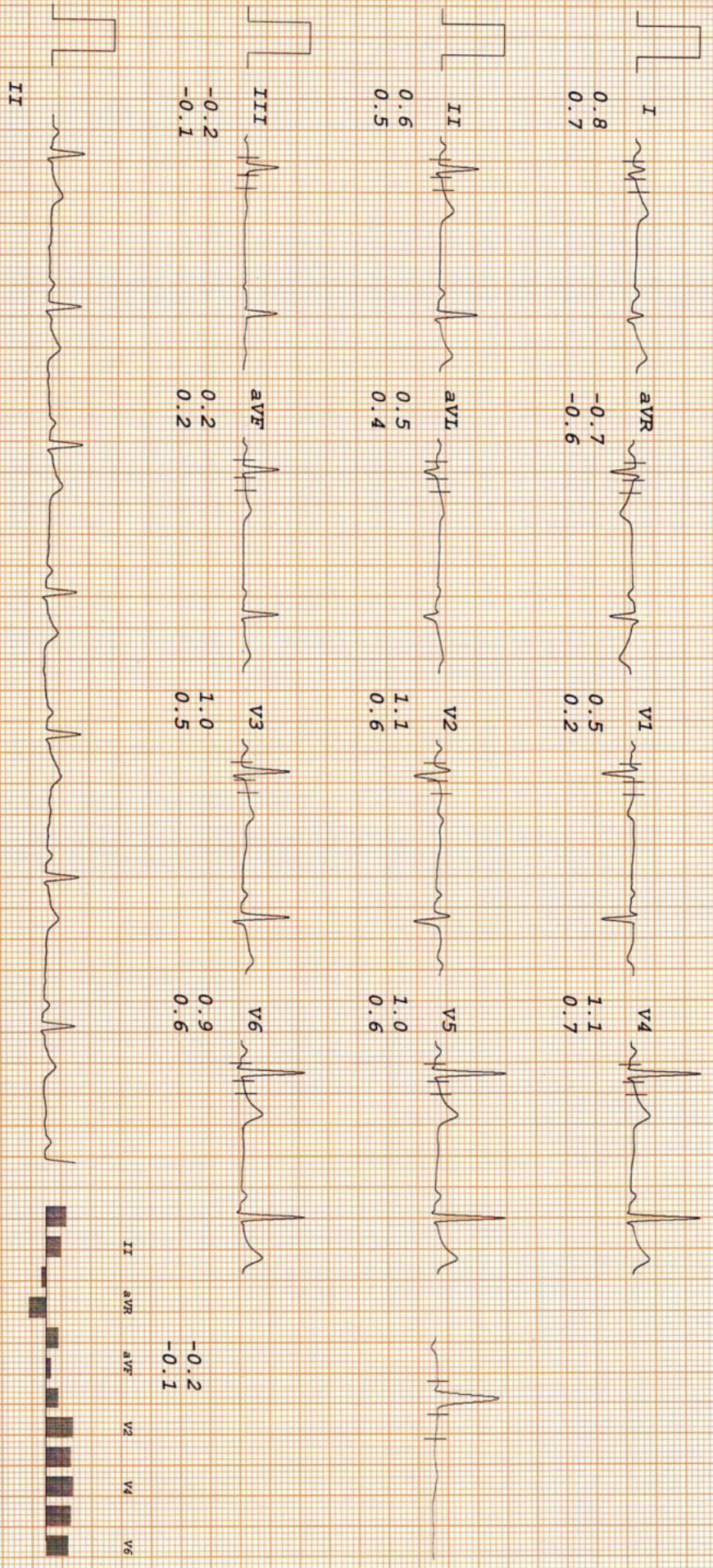
PRETEST
 SUPINE

ST @ 10mm/mV
 80ms Post J

LINKED MEDIAN

Mag. X 2

III



Barkha

THE DIAGNOSTIC & IMAGING CENTRE

BARKHA VERMA
 I.D. 3505
 Age 33/F
 Date 08-11-2022

RATE 71bpm
 B.P. 120/80

PRETEST
 HYPERVENT

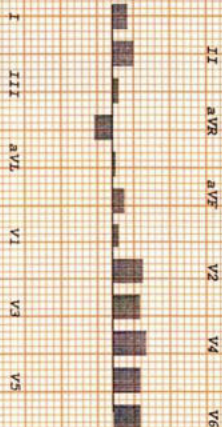
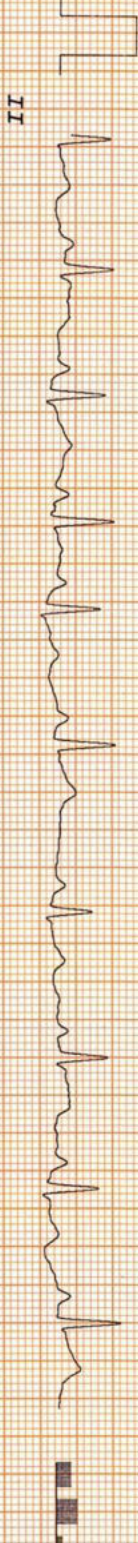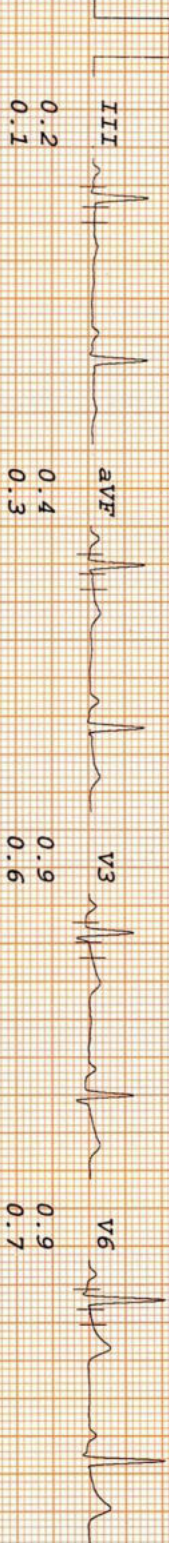
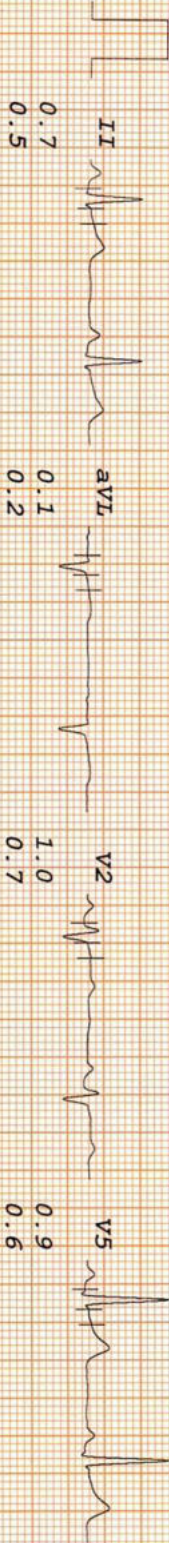
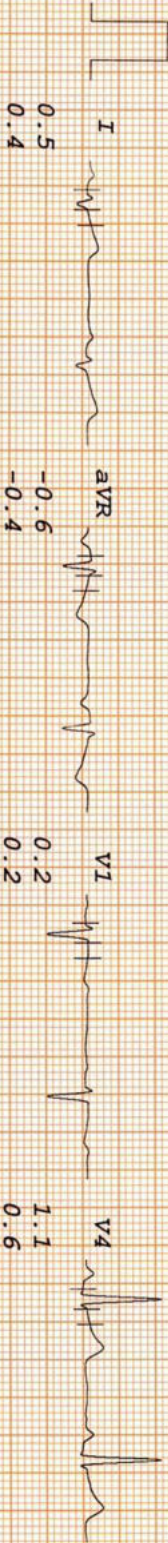
ST @ 10mm/mV
 80ms PostJ

PHASE TIME 0:12

LINKED MEDIAN

Mag. X 2

III



THE DIAGNOSTIC & IMAGING CENTRE

BARKHA VERMA
 I.D. 3505
 Age 33/F
 Date 08-11-2022

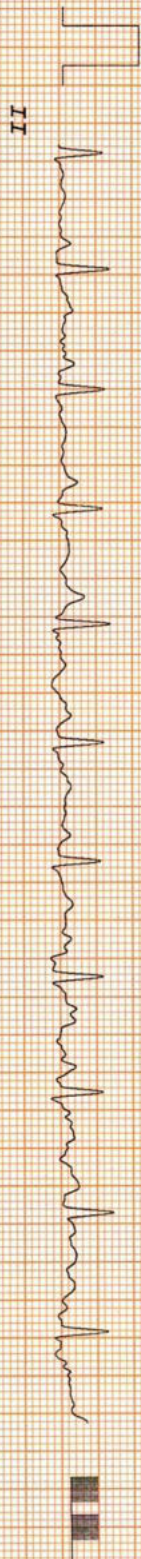
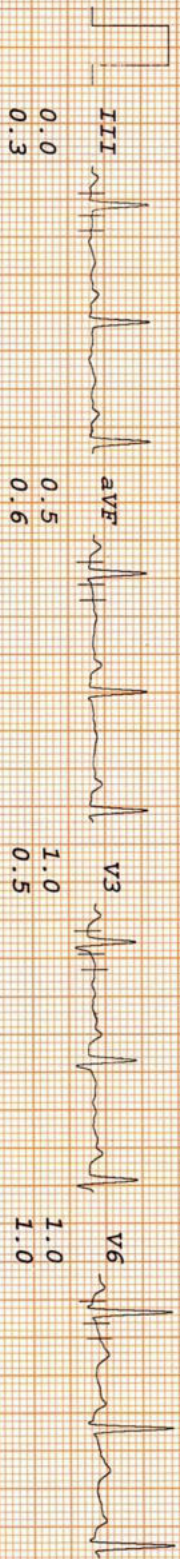
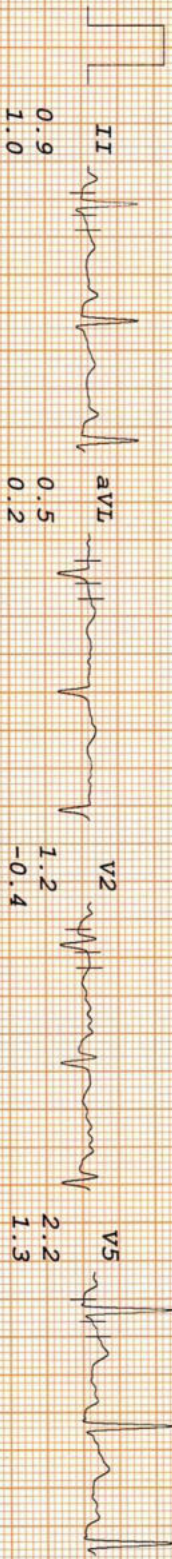
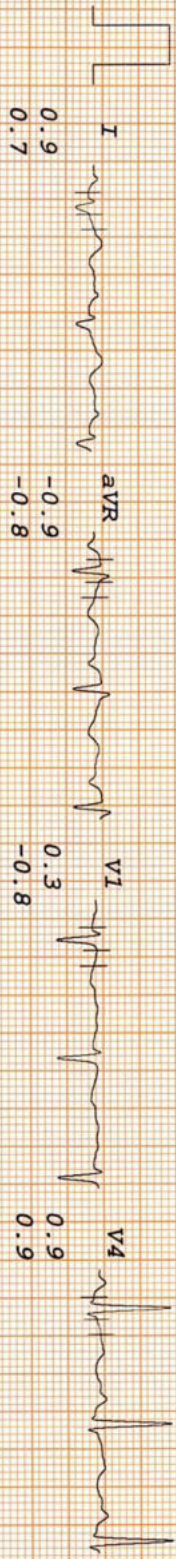
Rate 98bpm
 B.P. 130/80

Bruce
 Stage 1
 TOTAL TIME 2:55
 PHASE TIME 2:55


ST @ 10mm/mv
 80ms PostJ
 Speed 2.7 km/hr
 SLOPE 10 %

LINKED MEDIAN

Mag. X 2



III



I III aVR aVF V1 V2 V3 V4 V5 V6

THE DIAGNOSTIC & IMAGING CENTRE

BARKHA VERMA
 I.D. 3505
 Age 33/F
 Date 08-11-2022

Rate 114bpm
 B.P. 140/80

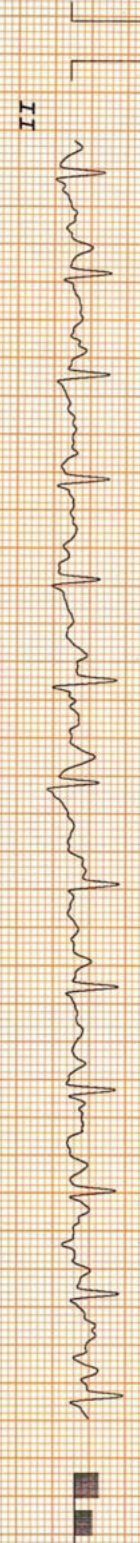
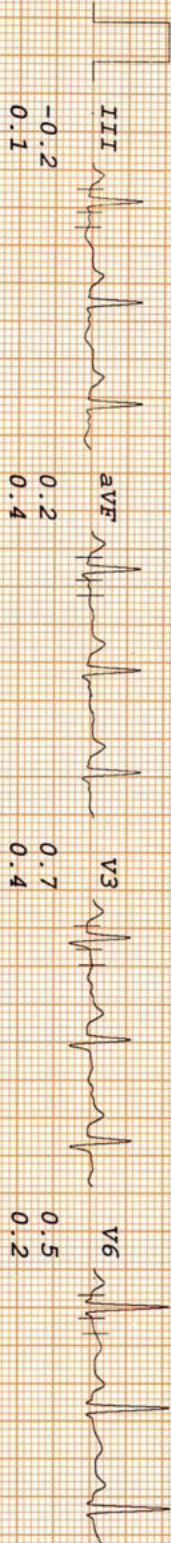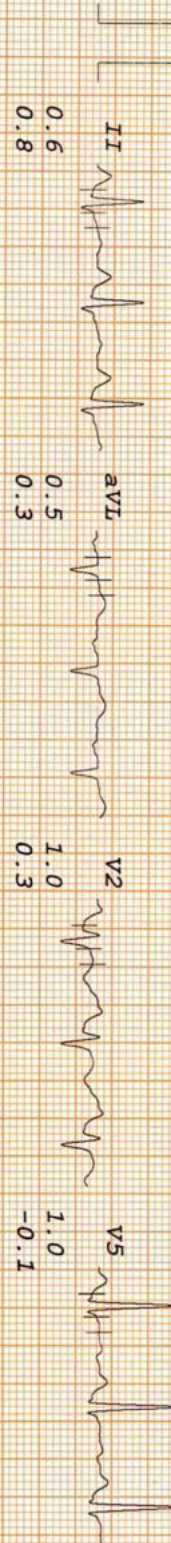
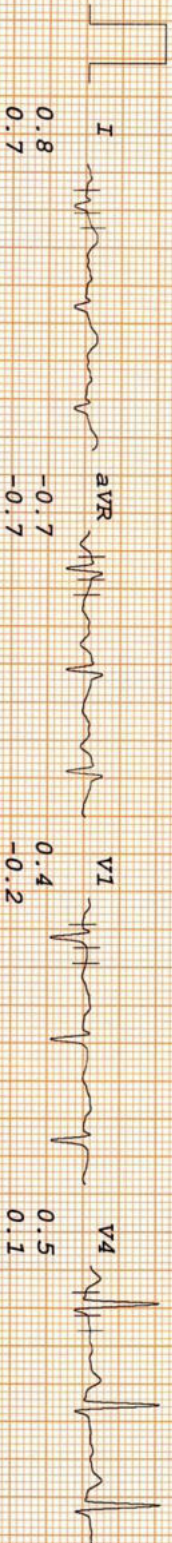
Bruce
 Stage 2
 TOTAL TIME 5:55
 PHASE TIME 2:55

ST @ 10mm/mV
 80ms PostJ
 Speed 4 km/hr
 SLOPE 12 %

LINKED MEDIAN

Mag. X 2

III



-0.2
0.1

II aVR aVF V2 V4 V6

I III aVL V1 V3 V5

THE DIAGNOSTIC & IMAGING CENTRE

BARSHA VERMA

I. D. 3505

Age 33/F

Date 08-11-2022

RATE 144bpm

B.P. 160/80

Bruce

Stage 4

TOTAL TIME 11:55

PHASE TIME 2:55

ST @ 10mm/mV

80ms PostJ

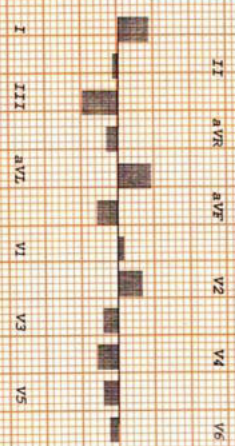
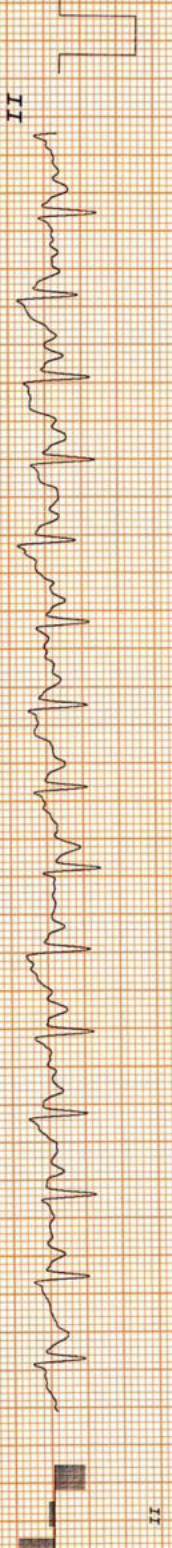
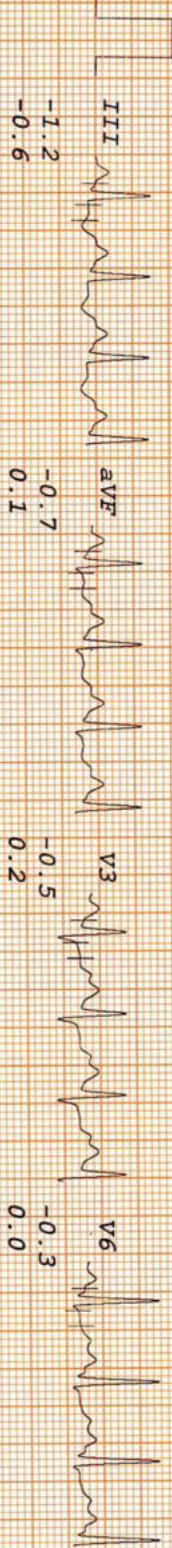
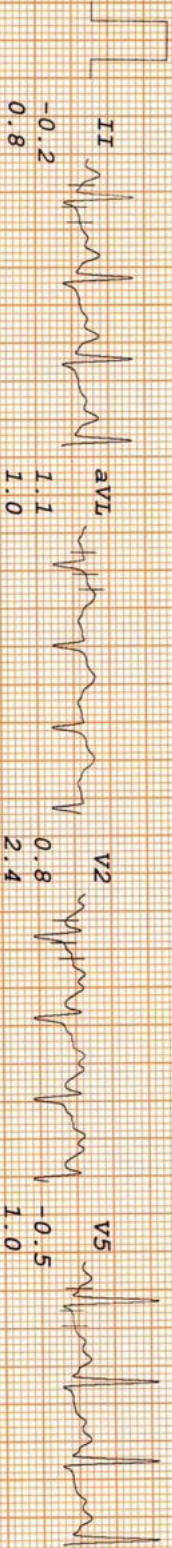
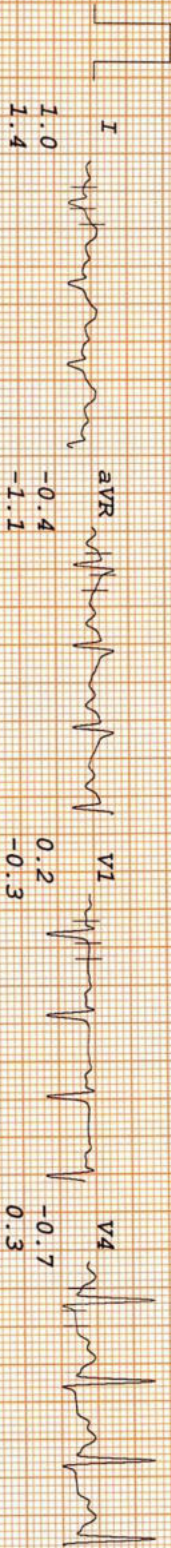
Speed 6.7 km/hr

SLOPE 16 %

LINKED MEDIAN

Mag. X 2

III



THE DIAGNOSTIC & IMAGING CENTRE

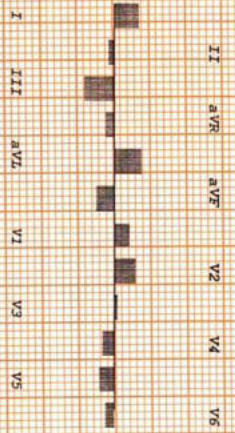
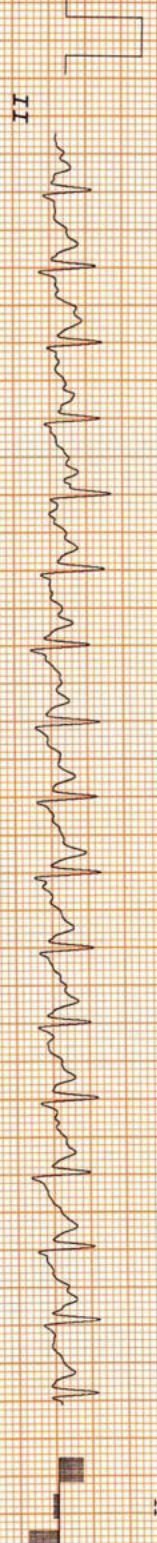
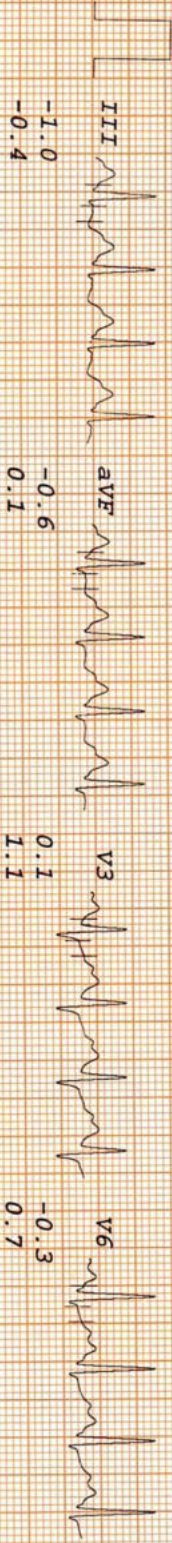
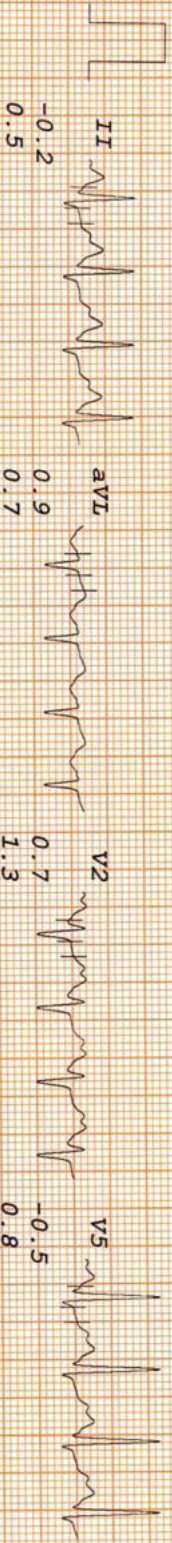
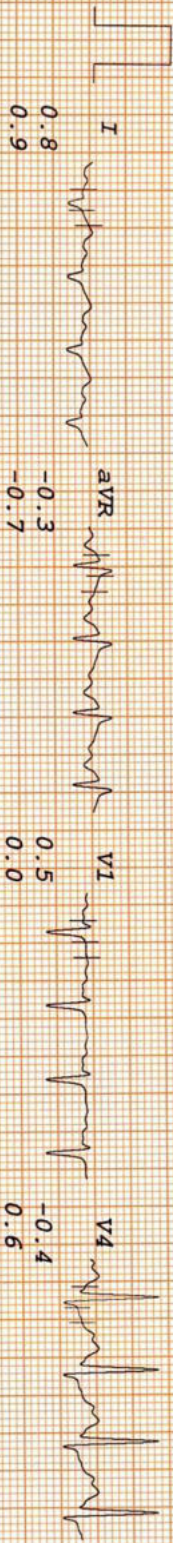
BARKHA VERMA
 I. D. 3505
 Age 33/F
 Date 08-11-2022

Rate 157bpm
 B.P. 170/80
 Bruce
 Stage 5
 TOTAL TIME 14:55
 PHASE TIME 2:55

ST @ 10mm/mV
 80ms PostJ
 Speed 8 km/hr
 SLOPE 18 %

LINKED MEDIAN

Mag. X 2



THE DIAGNOSTIC & IMAGING CENTRE

BARKHA VERMA

I.D. 3505

Age 33/F
Date 08-11-2022

RATE 163bpm

B.P. 170/80

TOTAL TIME 15:24
PHASE TIME 0:24

Bruce
Stage 6

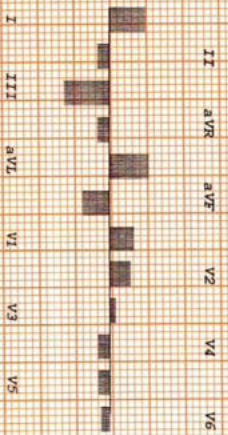
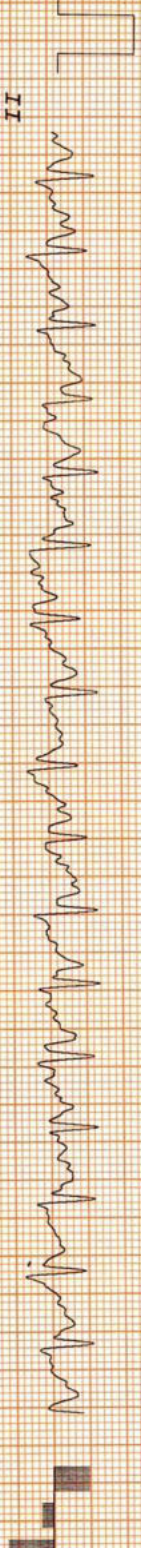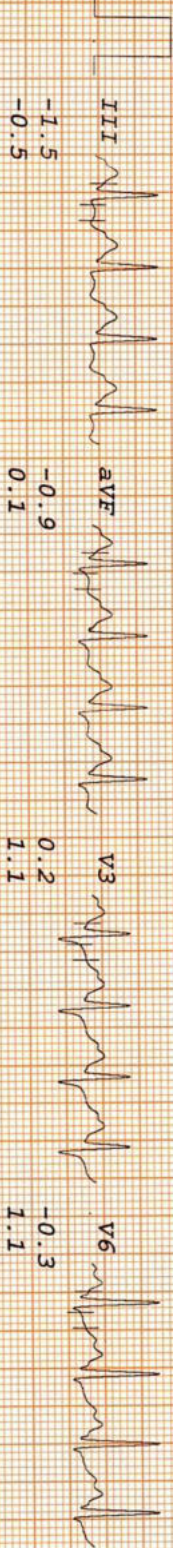
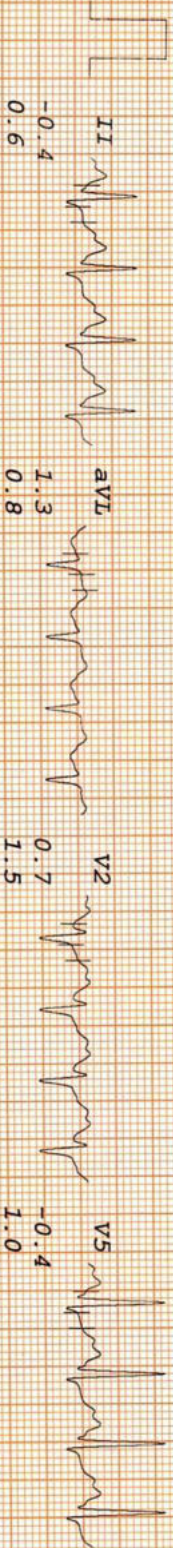
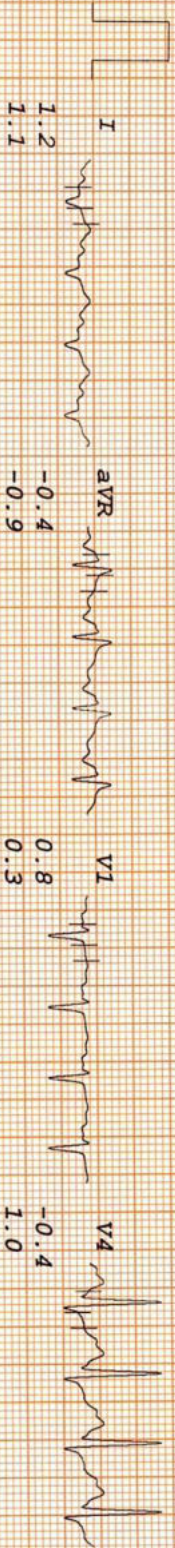ST @ 10mm/mV
80ms PostJ

Speed 8.8 km/hr
SLOPE 20 g

LINKED MEDIAN

Mag. X 2

III



THE DIAGNOSTIC & IMAGING CENTRE

BARKHA VERMA
 I.D. 3505
 Age 33/F
 Date 08-11-2022

RATE 104bpm
 B.P. 160/80

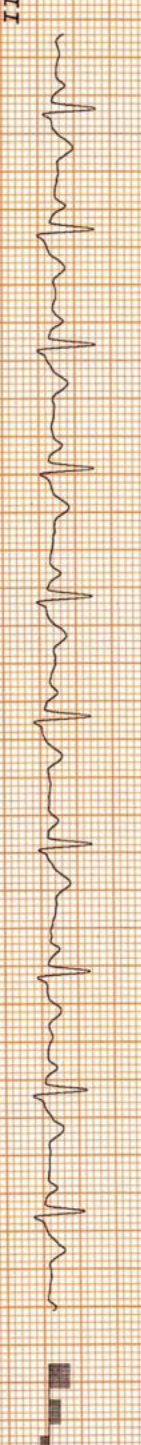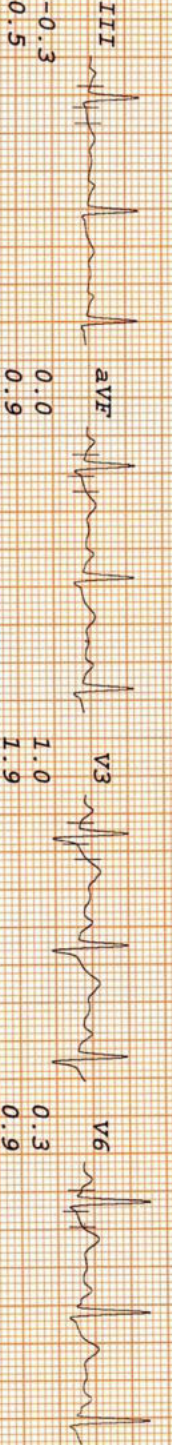
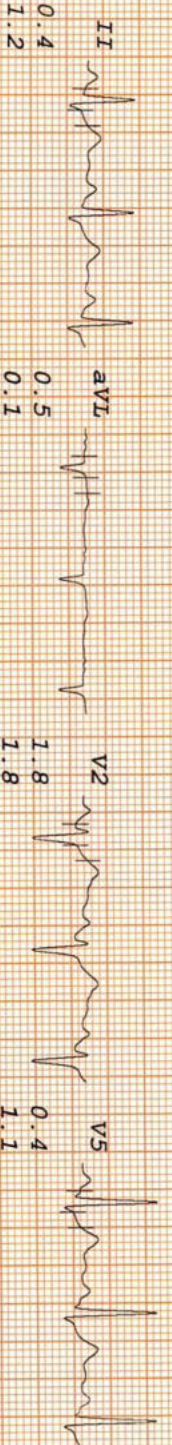
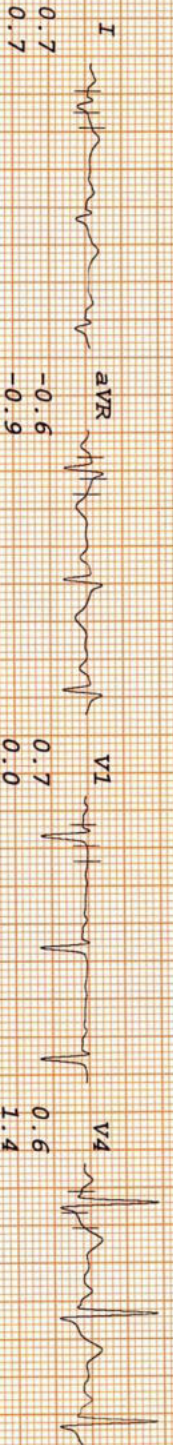
Bruce
 RECOVERY
 TOTAL TIME 16:56
 PHASE TIME 0:55

ST @ 10mm/mV
 80ms PostJ

LINKED MEDIAN

Mag. X 2

III



-0.3
0.5

II aVR aVF V2 V4 V6

I III aVL V1 V3 V5

THE DIAGNOSTIC & IMAGING CENTRE

BARKHA VERMA
I.D. 3505
Age 33/F
Date 08-11-2022

RATE 91bpm
B.P. 150/80

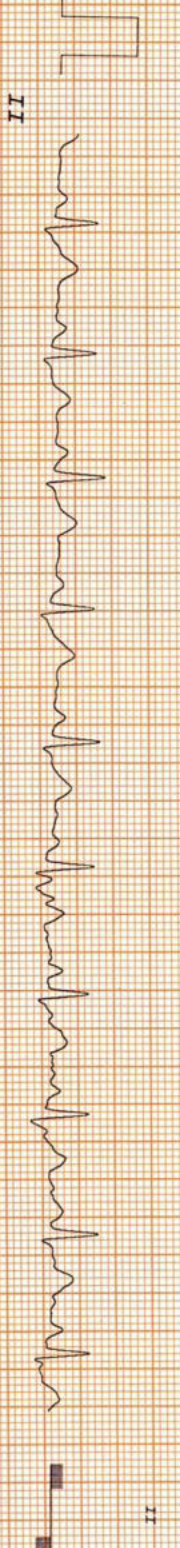
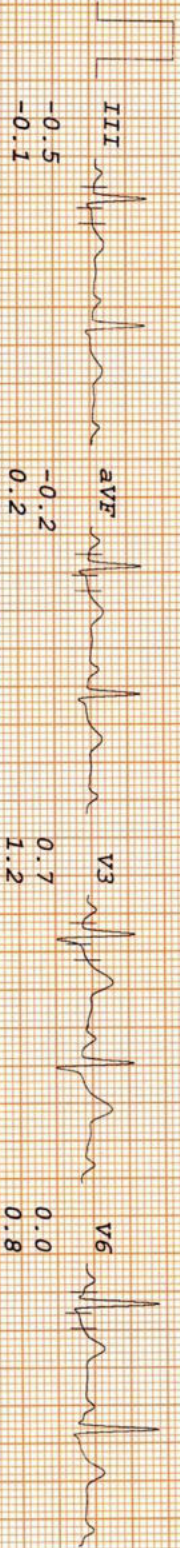
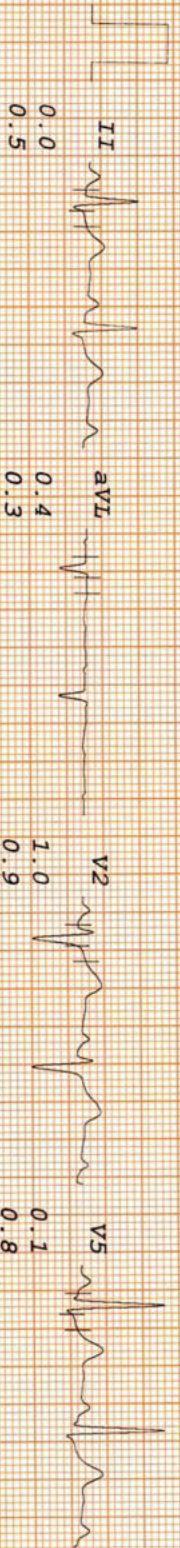
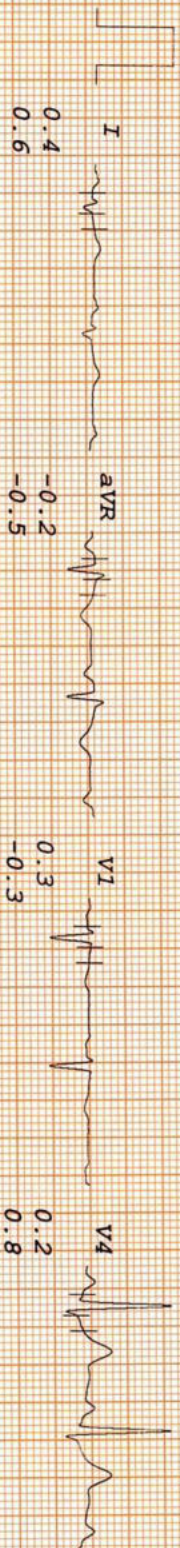
Bruce
RECOVERY
TOTAL TIME 17:56
PHASE TIME 1:55

ST @ 10mm/mV
80ms PostJ

LINKED MEDIAN

Mag. X 2

III



I III aVR aVF V1 V2 V3 V4 V5

THE DIAGNOSTIC & IMAGING CENTRE

BARKHA VERMA
I.D. 3505
Age 33/F
Date 08-11-2022

RATE 86bpm
B.P. 140/80

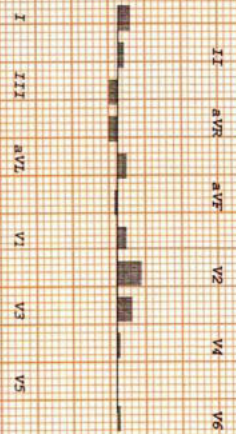
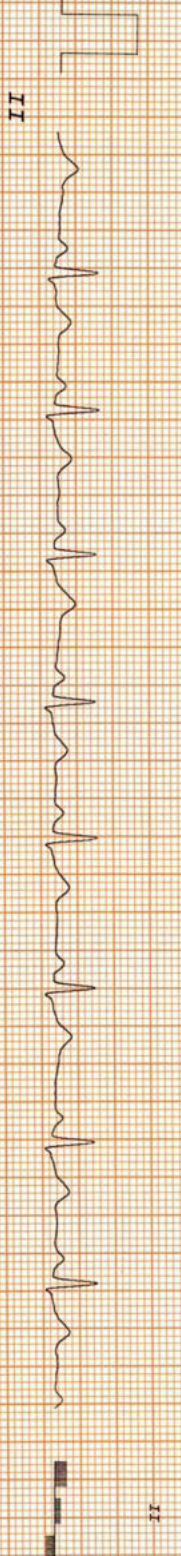
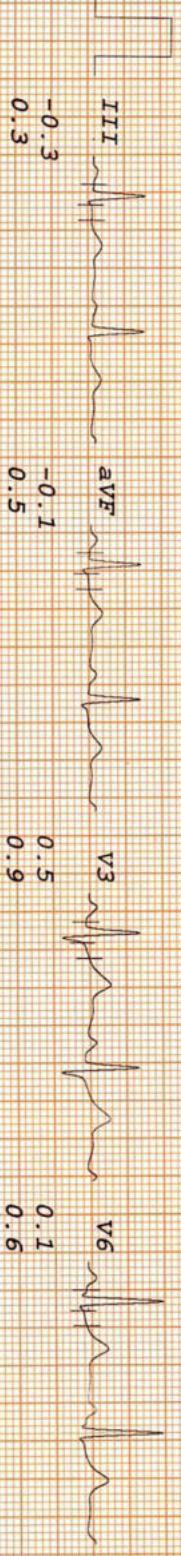
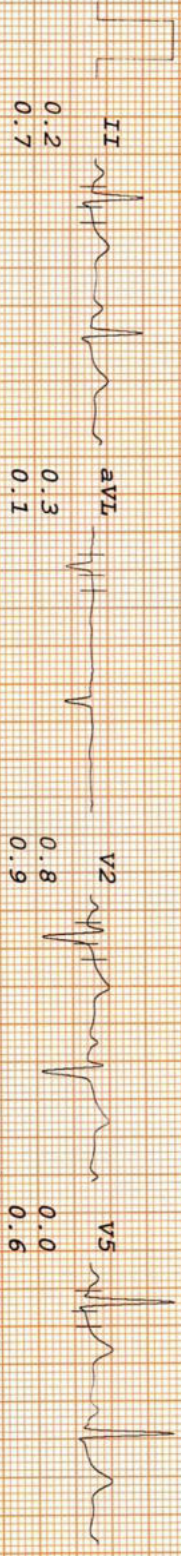
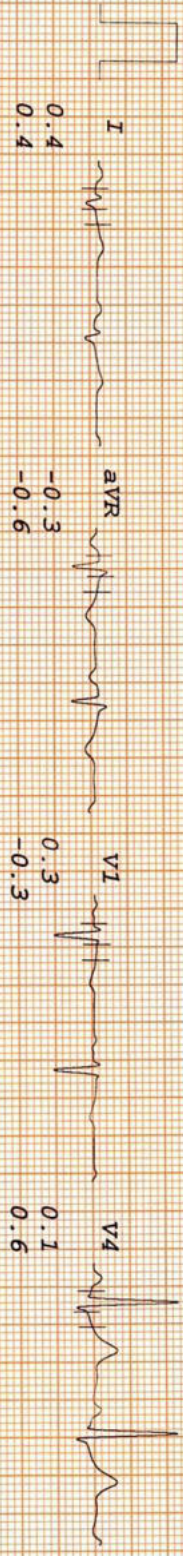
Recovery
TOTAL TIME 18:56
PHASE TIME 2:55

ST @ 10mm/mV
80ms PostJ

LINKED MEDIAN

Mag. X 2

III



THE DIAGNOSTIC & IMAGING CENTRE

BARKHA VERMA

I.D. 3505

Age 33/F

Date 08-11-2022

RATE 166bpm

B.P. 170/80

Bruce

PK-EXERCISE

TOTAL TIME 15:34

PHASE TIME 0:34

ST @ 10mm/mV

80ms PostJ

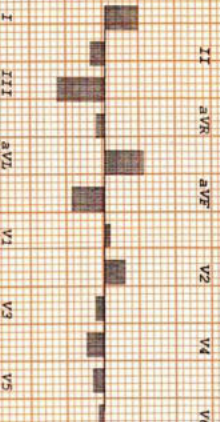

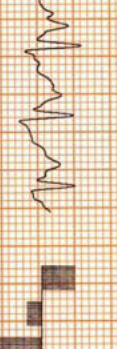
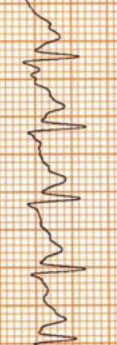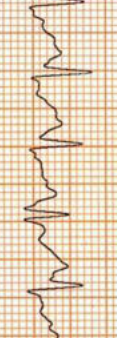
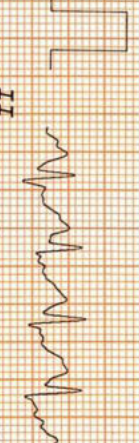
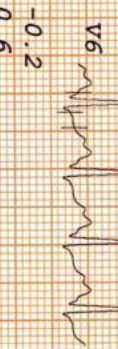
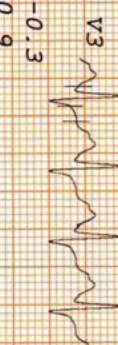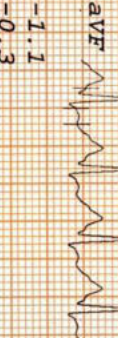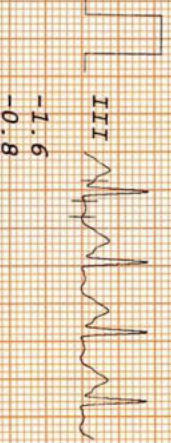
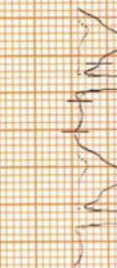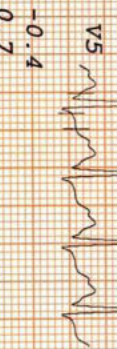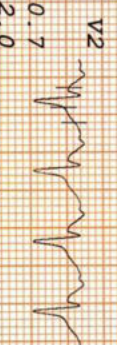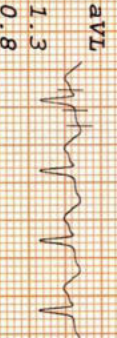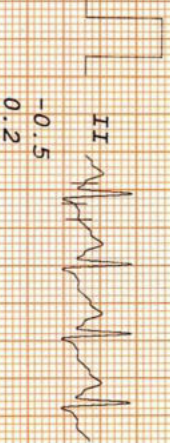
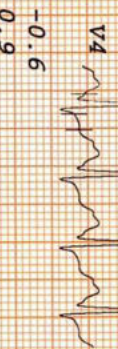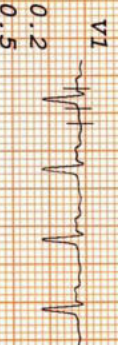
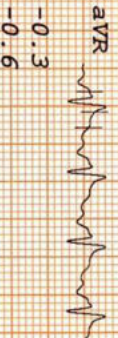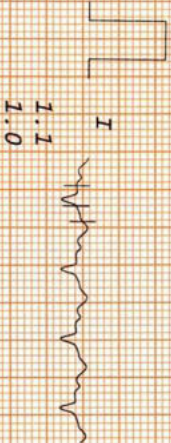
Speed 8.8 Km/hr

SLOPE 20 %

LINKED MEDIAN

Mag. X 2

III



THE DIAGNOSTIC & IMAGING CENTRE

BARKHA VERMA
 I.D. 3505
 Age 33/F
 Date 08-11-2022

RATE 79bpm
 B.P. 120/80

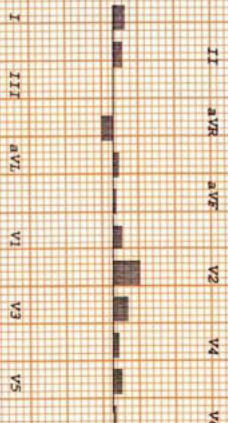
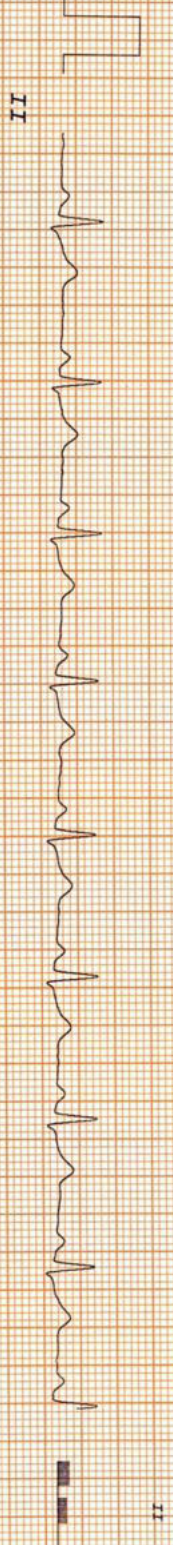
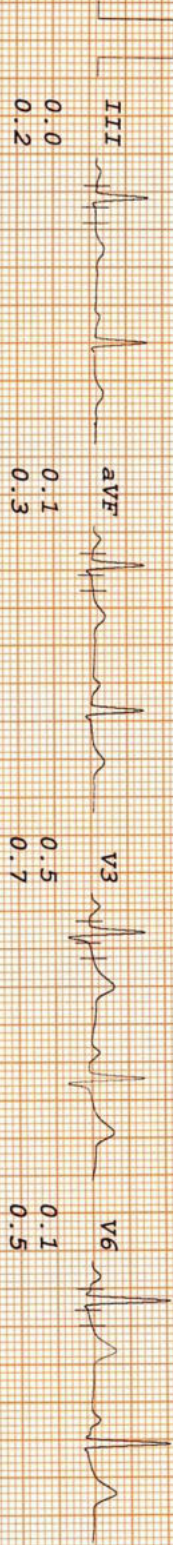
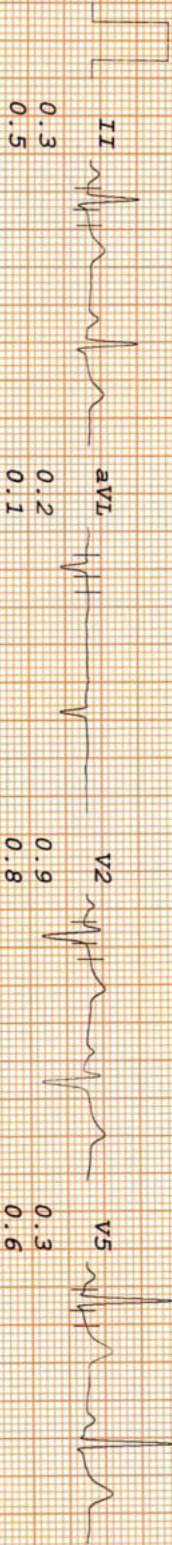
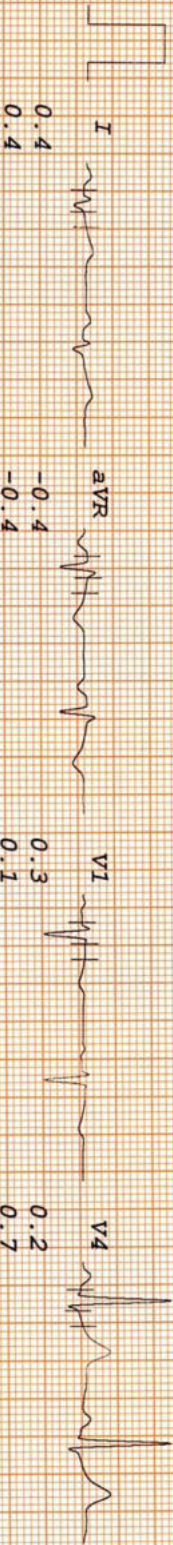Bruce
 RECOVERY
 TOTAL TIME 19:40
 PHASE TIME 3:39

ST @ 10mm/mV
 80ms PostJ

LINKED MEDIAN

Mag. X 2

III



THE DIAGNOSTIC & IMAGING CENTRE

BARSHA VERMA
I. D. 3505

Age 33/F
Date 08-11-2022

Rate 135bpm
B.P. 150/80

Stage 3

TOTAL TIME 8:55
PHASE TIME 2:55

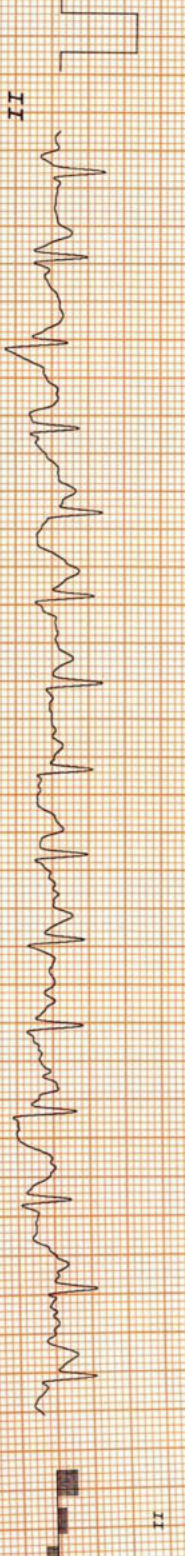
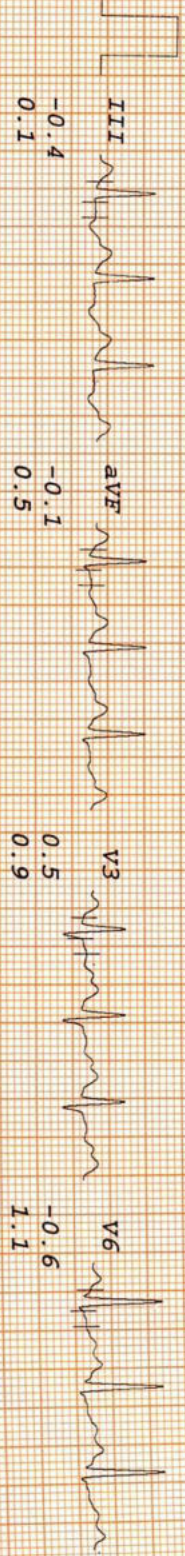
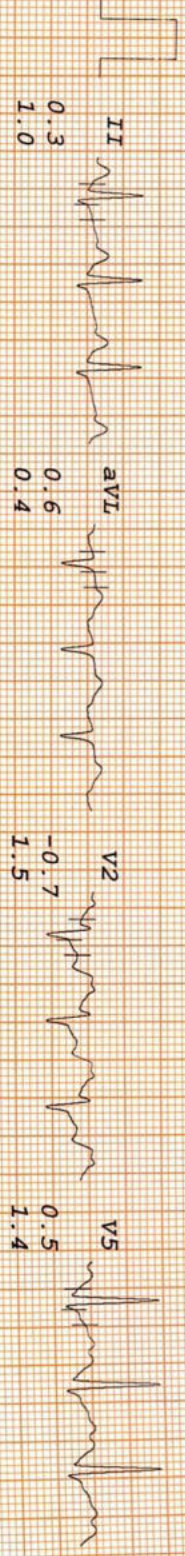
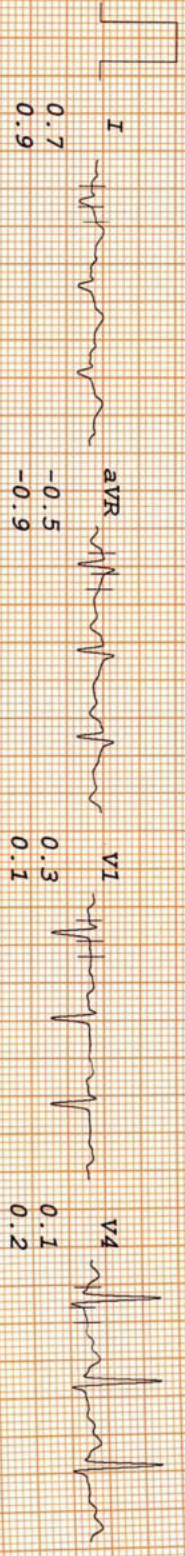
ST @ 10mm/mv
80ms PostJ

Speed 5.4 km/hr
SLOPE 14 %

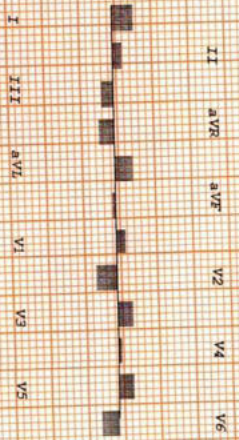
Mag. X 2

LINKED MEDIAN

V2



-0.7
1.5





LETTER OF APPROVAL / RECOMMENDATION

To,

The Coordinator,
Mediwheel (Arcofemi Healthcare Limited)
Helpline number: 011- 41195959

Dear Sir / Madam,

Sub: Annual Health Checkup for the employees of Bank of Baroda

This is to inform you that the following employee wishes to avail the facility of Cashless Annual Health Checkup provided by you in terms of our agreement.

PARTICULARS	EMPLOYEE DETAILS
NAME	MS. VERMA BARKHA
EC NO.	109324
DESIGNATION	IT
PLACE OF WORK	NEW DELHI,ZO NEW DELHI
BIRTHDATE	02-08-1988
PROPOSED DATE OF HEALTH CHECKUP	10-09-2022
BOOKING REFERENCE NO.	22S109324100024602E

This letter of approval / recommendation is valid if submitted along with copy of the Bank of Baroda employee id card. This approval is valid from **31-08-2022** till **31-03-2023** The list of medical tests to be conducted is provided in the annexure to this letter. Please note that the said health checkup is a **cashless facility** as per our tie up arrangement. We request you to attend to the health checkup requirement of our employee and accord your top priority and best resources in this regard. The EC Number and the booking reference number as given in the above table shall be mentioned in the invoice, invariably.

We solicit your co-operation in this regard.

Yours faithfully,


Sd/-

Chief General Manager
HRM Department
Bank of Baroda

(Note: This is a computer generated letter. No Signature required. For any clarification, please contact Mediwheel (Arcofemi Healthcare Limited))

SUGGESTIVE LIST OF MEDICAL TESTS


FOR MALE	FOR FEMALE
CBC	CBC
ESR	ESR
Blood Group & RH Factor	Blood Group & RH Factor
Blood and Urine Sugar Fasting	Blood and Urine Sugar Fasting
Blood and Urine Sugar PP	Blood and Urine Sugar PP
Stool Routine	Stool Routine
Lipid Profile	Lipid Profile
Total Cholesterol	Total Cholesterol
HDL	HDL
LDL	LDL
VLDL	VLDL
Triglycerides	Triglycerides
HDL / LDL ratio	HDL / LDL ratio
Liver Profile	Liver Profile
AST	AST
ALT	ALT
GGT	GGT
Bilirubin (total, direct, indirect)	Bilirubin (total, direct, indirect)
ALP	ALP
Proteins (T, Albumin, Globulin)	Proteins (T, Albumin, Globulin)
Kidney Profile	Kidney Profile
Serum creatinine	Serum creatinine
Blood Urea Nitrogen	Blood Urea Nitrogen
Uric Acid	Uric Acid
HBA1C	HBA1C
Routine urine analysis	Routine urine analysis
USG Whole Abdomen	USG Whole Abdomen
General Tests	General Tests
X Ray Chest	X Ray Chest
ECG	ECG
2D/3D ECHO / TMT	2D/3D ECHO / TMT
Stress Test	Thyroid Profile (T3, T4, TSH)
PSA Male (above 40 years)	Mammography (above 40 years) and Pap Smear (above 30 years).
Thyroid Profile (T3, T4, TSH)	Dental Check-up consultation
Dental Check-up consultation	Physician Consultation
Physician Consultation	Eye Check-up consultation
Eye Check-up consultation	Skin/ENT consultation
Skin/ENT consultation	Gynaec Consultation



भारतीय रिजिस्ट्रार पदचान प्राधिकरण
Unique Identification Authority of India


पता:
 आनमथा: अरुण कुमार वर्मा, 96 /
 213, पुराना गणेशगंज, थाना -
 अमीनबाद, लुकरनऊ, लुकरनऊ,
 उत्तर प्रदेश - 226018

Address:
 D/O: Arun Kumar Verma, 96 /
 213, Purana Ganesganj, Thana
 - Aminabad, Lucknow, Lucknow,
 Uttar Pradesh - 226018

5779 1287 4601

1947 

help@uidai.gov.in 

www.uidai.gov.in 

Barkha


भारत सरकार
Government of India



वरका वर्मा
 Barkha Verma
 जन्म तिथि/ DOB: 02/08/1988
 महिला / FEMALE

5779 1287 4601

मेरा आधार, मेरी पहचान



Radiology No.	: 5075/OPDPB22DL	Date	: 08-Nov-2022
Patient Name	: Mrs. BARKHA VERMA	Age/Sex	: 33Y
Guardian Name	:	UHID No.	: 4621/UHID22DL
Consultant	: Dr. INSURANCE	Mobile No.	: 9453839073

ULTRASOUND OF WHOLE ABDOMEN

**Convex and TVS Probes were used.
Complaining of pain in abdomen**

The liver is normal in size, contour and echotexture. Intrahepatic bile ducts and CBD are not dilated. Hepatic portal veins and the IVC appear normal in caliber.

Gall bladder is adequately distended with normal intraluminal fluid contents. No evidence of calculus / wall thickness noted.

Pancreas is of normal size and contour with normal echotexture.

Kidneys are of normal size, shape and echo pattern. No calculus, mass or hydronephrotic changes seen in either kidney. Corticomedullary differentiation is normal bilaterally. Bilateral PCS are normal. Bilateral ureters are not dilated.

Right Kidney measures 10.11x4.02cm

Left kidney measures 10.18x4.45cm

Spleen is of normal size and shape. Echotexture is normal. No focal lesion is seen. No evidence of retro-peritoneal lymphadenopathy/ ascites/ pleural effusion noted.



Dr. Harshita Surange
MBBS, DMRD (RADIODIAGNOSIS)
DIPLOMA IN MSK, UCAM (Spain)
Reg. No. MCI/16522, DMC/18402



BOOK APPOINTMENT





Radiology No.	: 5075/OPDPB22DL	Date	: 08-Nov-2022
Patient Name	: Mrs. BARKHA VERMA	Age/Sex	: 33Y
Guardian Name	:	UHID No.	: 4621/UHID22DL
Consultant	: Dr. INSURANCE	Mobile No.	: 9453839073

Uterus is anteverted and is normal in size. **Two 18x10 and 18x13mm fibroids are seen in anterior wall having the subserosal component.** Rest of the myometrium shows normal echo-pattern.

No other mass or lesion is noted. **A Bartholin cyst of 17x14mm is seen on anterior vaginal wall.**

Endometrial is normal measuring 13mm and is in mid line.

Both ovaries are visualized and are normal with subcentemetric follicles.

Right ovary measures 23x11x27mm(3.99cc)

Left ovary measures 32x15x34mm(9.29cc)

POD fluid is significant

Urinary bladder does not show any calculus or mass lesion.

Please correlate clinically

Dr. Harshita Surange
MBBS, DMRD (RADIO DIAGNOSIS)
DIPLOMA IN MSK, UCAM (Spain)
Reg. No. MCI/16522, DMC/18402



BOOK APPOINTMENT



Radiology No.	: 5075/OPDPB22DL	Date	: 08-Nov-2022
Patient Name	: Mrs. BARKHA VERMA	Age/Sex	: 33Y
Guardian Name	:	UHID No.	: 4621/UHID22DL
Consultant	: Dr. INSURANCE	Mobile No.	: 9453839073

X-RAY CHEST

Indication: Routine checkup.

Image quality:-

No evidence of rotation.

PA view. Normal penetration.

Airway:- Trachea central.

Carina & bronchi are normal.

No hilar abnormality.

Lung fields:- Clear.

Cardiac:- Cardiac borders are visible.

Normal heart size.

Diaphragm:- Costophrenic angles on right & left are normal.

Cardiophrenic angles on right & left are normal.

Diaphragm portion are normal.

Bony cage:- No evidence of bony lesion/fracture seen.

No evidence of cervical ribs seen.

Impression: No significant abnormality detected.



Dr. Harshita Surange
MBBS, DMRD (RADIODIAGNOSIS)
DIPLOMA IN MSK, UCAM (Spain)
Reg.No. MCI/16522, DMC/18402



BOOK APPOINTMENT

