

भारत सरकार  
 GOVERNMENT OF INDIA  
  
 కోకకు ముని చంద్రశేఖర్  
 Kokku Muni Chandrasekhar  
 పుట్టిన తేదీ/ DOB: 15/05/1976  
 పురుషుడు / MALE  
 3880 6782 2223  
 నా ఆధార్ - నా గుర్తింపు

भारतीय विधिक पहचान प्राधिकरण  
 UNIQUE IDENTIFICATION AUTHORITY OF INDIA  
 పేరు/నామం: S/O కోకకు ముని శ్రీకృష్ణ, డి  
 NO-1-1-127, కౌలమిల్ల - లాకాండ్  
 నిలయం, మునిపాలెం వాటర్  
 కృష్ణ మునిచంద్ర, సూరపేట,  
 సూరపేట, నెల్లూరు,  
 ఆంధ్ర ప్రదేశ్ - 524121  
 Address: S/O Kokku Muni Krishnak, D  
 NO-1-1-127, Kollamilla - Lakshmi  
 Nilayam, Opposite Municipal  
 Water Tank, Sullurpete,  
 Sullurpete, Nellore,  
 Andhra Pradesh - 524121  
 3880 6782 2223  
 MERA AADHAAR. MERI PEHACHAN

(K.M.)  
 (K.M.)  
 [For Medical checker  
 25/2/22]





**LAB REPORT**

Patient Name : Mr. K.M.CHANDRASEKHAR  
 Age / Gender : 45-Years / Male  
 UHID ID : MH20220035116  
 Doctor Name : Dr. ARUN PRAKASH  
 OP Report No. : INVA2104595  
 Bill No. : INV2108058  
 Sample Date : 25/02/2022 - 11:20 AM  
 Report Date : 25/02/2022 - 01:49 PM

Test Name	Result	Units	Reference Interval
<b>HAEMATOLOGY</b>			
<b>Complete Blood Cell Count(CBC)</b>			
HAEMOGLOBIN	15.1	gms/dl	male :13.0 - 17.0 female :12.0 - 15.0
PACKED CELL VOLUME	45.4	%	male : 40 - 50 female : 36 - 46
RBC COUNT	<u>5.19</u>	millions cells/cu.mm	female: 3.8 - 4.8 male : 4.5 - 5.5
TOTAL WBC	4,500	Cells/Cumm	4,000 - 11,000
<b>Differential Count</b>			
NEUTROPHILS	63	%	40 - 65
LYMPHOCYTES	32	%	30-50
EOSINOPHILS	05	%	01-06
MONOCYTES	<u>00</u>	%	1-10
BASOPHILS	00	%	0-2
ESR 60 MTS	06	mm	5 - 20
PLATELET COUNT	2.93	Lakhs/cumm	1.5 - 4.5
MCV	87.6	fL	76 - 96
MCH	29.0	pg	27 - 32
MCHC	33.2	gms/dl	30 - 36

*INTERPRETATION: Test done on automated three part cell counter, all abnormal results are reviewed and confirmed microscopically.*

**BLOOD GROUPING & RH TYPING** " O " POSITIVE





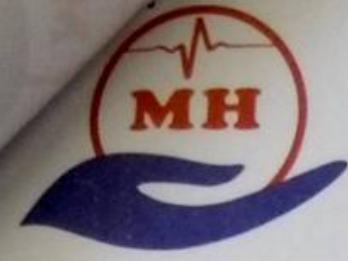**LAB REPORT**

Patient Name : Mr. K.M.CHANDRASEKHAR  
Age / Gender : 45-Years / Male  
UHID ID : MH20220035116  
Doctor Name : Dr. ARUN PRAKASH

OP Report No. : INVA2104595  
Bill No. : INV2108058  
Sample Date : 25/02/2022 - 11:20 AM  
Report Date : 25/02/2022 - 01:49 PM

Test Name	Result	Units	Reference Interval
<b>BIO CHEMISTRY</b>			
BLOOD SUGAR FASTING	83	mgs/dl	70-110
BLOOD SUGAR POST PRANDIAL	100	mgs/dl	80- 160
SERUM CREATININE	1.0	mg/dl	0.7-1.4
SERUM URIC ACID	5.1	mg/dl	male 3.1-7.0 , female 2.5-5.6
<b>LIPID PROFILE</b>			
TOTALCHOLESTEROL	210	mg/dl	< 200
TRIGLYCERIDE	189	mg/dl	< 150
HDL	52	mg/dl	35 - 80
VLDL	<u>38</u>	mg/dl	2 to 30
LDL	120	mg/dl	<130
CHOLESTEROL/ HDL RATIO	4.0	mg/dl	





# MURUGAN HOSPITALS

HEALING HANDS



## LAB REPORT

Patient Name : Mr. K.M.CHANDRASEKHAR  
 Age / Gender : 45-Years / Male  
 UHID ID : MH20220035116  
 Doctor Name : Dr. ARUN PRAKASH

OP Report No. : INVA2104595  
 Bill No. : INV2108058  
 Sample Date : 25/02/2022 - 11:20 AM  
 Report Date : 25/02/2022 - 01:49 PM

Test Name	Result	Units	Reference Interval
<b>LIVER FUNCTION TEST</b>			
BILLIRUBIN(TOTAL)	0.3	mg/dl	0.0 -1.0
BILLIRUBIN(DIRECT)	0.1	mg/dl	0.1- 0.30
BILLIRUBIN(INDIRECT)	0.2	mg/dl	0.2-0.8
SGOT	24	IU/L	0-38
SGPT	31	IU/L	0.0-40
ALKALINE PHOSPHATASE	77	IU/L	40-140
			4-6Years 93-309
			13-15Years 74-390
TOTAL PROTEIN	7.6	gm/dl	6.6-8.7
ALBUMIN	4.5	gm/dl	3.5 - 5.5
GLOBULIN	3.1	gm/dl	2.0-3.5
AG RATIO	1.4		
<b>GAMMA G T</b>	27	U/L	male<49
			female<32
<b>BLOOD UREA NITROGEN</b>	8.4	mg/dl	7-21
<b>HBA1C</b>	5.6	%	normal: <6.0
			good control: 6.1-7.0
			fair control: 7.1- 8.0
			poor control:8.1 -10.0
			unsatisfactory: >10.0

Healing Hearts and Lives

264/125, Kilpauk Garden Road, Kilpauk, Chennai - 600 010.  
 Phone : +91 44 4644 8989 / 75500 53335 | Email : muruganhosp@gmail.com  
 Website : www.muruganhospitals.in





**LAB REPORT**

Patient Name : Mr. K.M.CHANDRASEKHAR  
Age / Gender : 45-Years / Male  
UHID ID : MH20220035116  
Doctor Name : Dr. ARUN PRAKASH

OP Report No. : INVA2104595  
Bill No. : INV2108058  
Sample Date : 25/02/2022 - 11:20 AM  
Report Date : 25/02/2022 - 01:49 PM

Test Name	Result	Units	Reference Interval
<b>CLINICAL PATHOLOGY</b>			
URINE SUGAR (F)	NIL		
URINE SUGAR (PP)	NIL		
<b>URINE ROUTINE</b>			
COLOUR	STRAW YELLOW		
APPEARANCE	CLEAR		
REACTION	ACIDIC		
ALBUMIN	NIL		
<b>DEPOSITES</b>			
PUS CELLS	2 - 3	/ HPF	
EPI CELLS	1 - 2	/ HPF	
RBC COUNT	NIL	/ HPF	
CAST	NIL		
CRYSTALS	NIL		
OTHERS	NIL		
MALATHI			
Verified by	*** End of Report ***		Authorized Signature





**MURUGAN HOSPITALS**  
HEALING HANDS

Date : 25/02/2022

NAME OF PATIENT : MR.K.M.CHANDRASEKHAR

AGE : 45 / MALE

Nil visual complaints

O/E

V/A

OD : 6/6 N6

OS : 6/6 N6

Within normal limits in both eyes.

**IMPRESSION :**

- Nil ophthalmic problem



Medical Officer

264/125, Kilpauk Garden Road, Kilpauk, Chennai - 600 010.

☎ : +91 44 4644 8989 / 75500 53335 email : muruganhosp@gmail.com

Website : www.muruganhospitals.in



Mr. K. M. CHANDRASEKHAR  
OP21017973- MH20220035116  
45 Yrs 9 Months / Male  
25.02.2022 09.00  
Dr. ARUN PRAKASH



**MURUGAN HOSPITALS**  
HEALING HANDS



25/2/22

Mr. K. M. Chandrasekhar

H/L/M

O/E:

B/L ears: B/L tympanic membrane visualized.  
no ear wax / no pus discharge  
no perforation visualized.

B Oral cavity: All root canal done  
No other decay in teeth visualized.



264/125, Kilpauk Garden Road, Kilpauk, Chennai - 600 010.

☎ : +91 44 4644 8989 / 75500 53335 email : muruganhosp@gmail.com

Website : www.muruganhospitals.in



ID : 2202250003  
Name: CHANDRASEKHAR  
Sex : Male  
Divisions:

DataTime: 2022-02-25 09:39  
Age : 45  
BP : 100/70 mmHg  
Bed No. :

Hospital: MURUGAN HOSPITALS  
Height : 181 cm  
Weight : 64 kg  
Hospital No.:

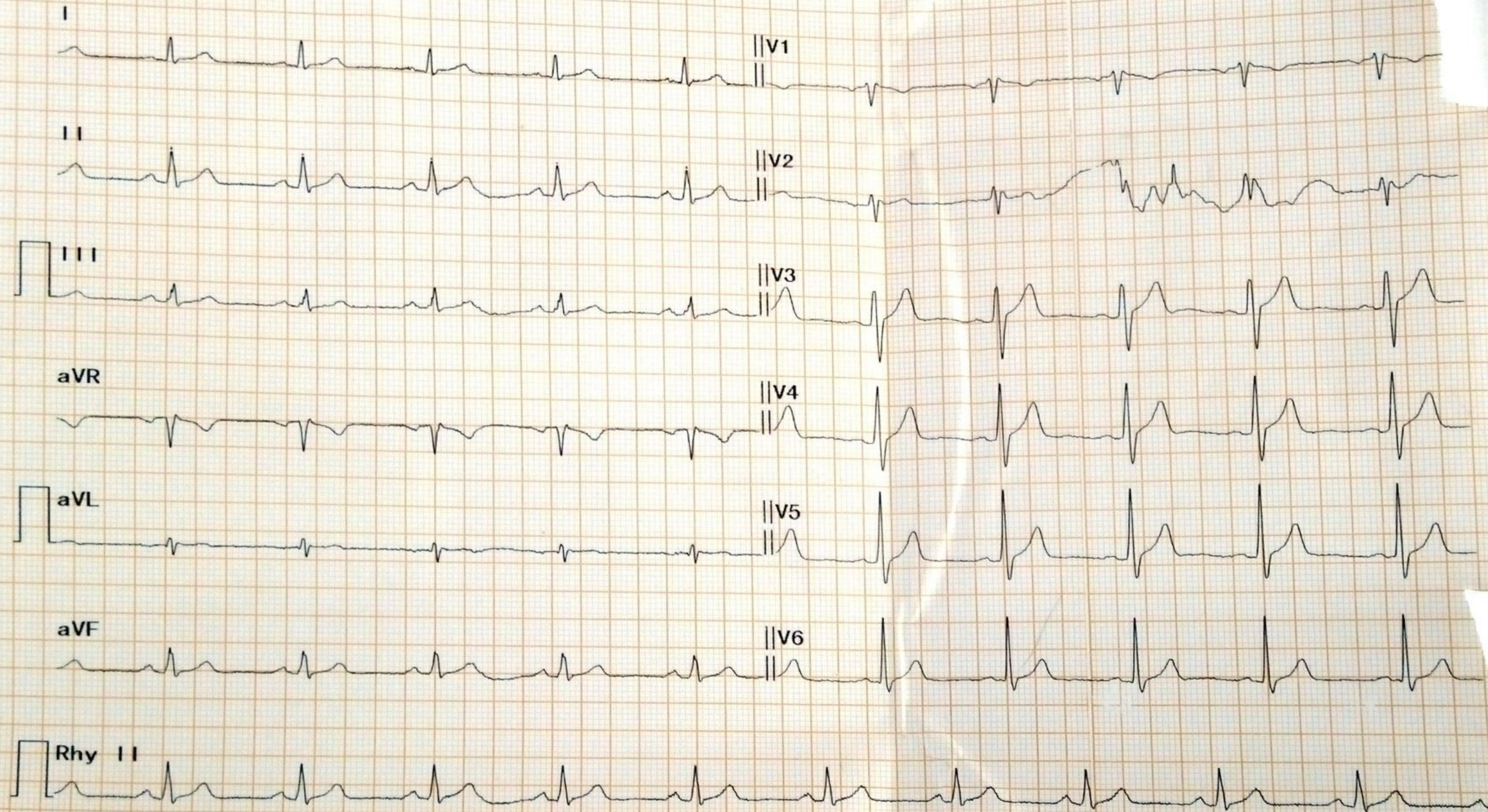HR 66 bpm  
P Dur/PR int 108/167ms  
QRS Dur 105ms  
QT/QTc int 345/363 ms  
P/QRS/T axis 74/58/54 °

RV5/SV1 amp 1.363/0.382mV  
RV5+SV1 amp 1.745mV  
RV6/SV2 amp 1.218/0.324mV

Minnesota Code  
4-2-0(V2)

Diagnosis Info  
800: Sinus Rhythm

\*\*\*Normal ECG\*\*\*



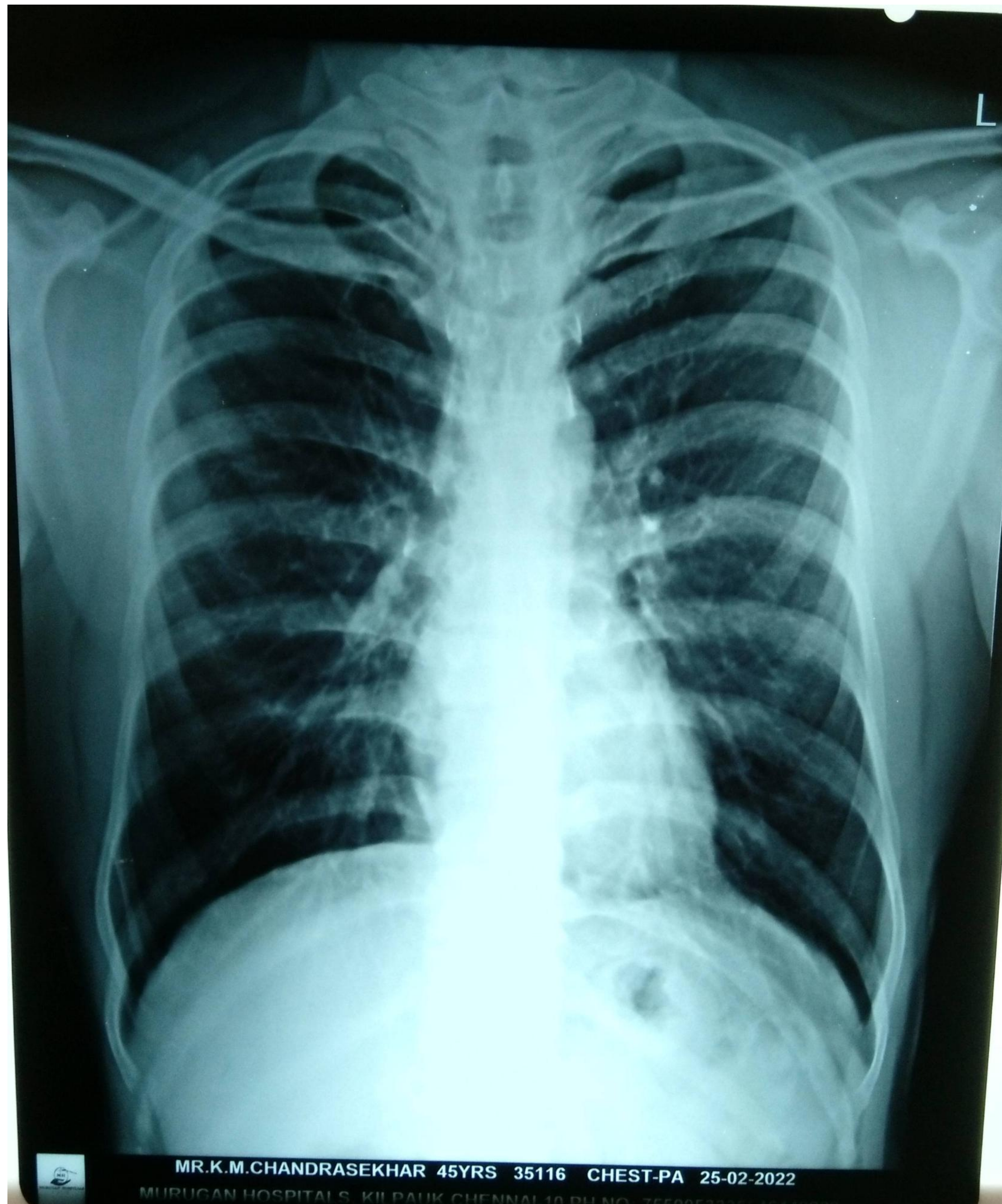Diagnosis for reference, ask your doctor to confirm

AUTO PRINT 6X2+1R 66bpm 10 mm/mV 0.50Hz-45Hz AG 60Hz 25 mm/sec

Confirmed By:

Dr. SIDHARTH  
Consultant Card  
Reg. No. 62





*Scanned by TapScanner*





**MURUGAN HOSPITALS**  
HEALING HANDS



**SCAN REPORT**

NAME : Mr .K.M.CHANDRA SEK HAR  
AGE / SEX: 45 YEARS /MALE  
CONSULTANT: DR. ARUN PRAKASH

UHID NO : MH20220035116  
DATE : 25- 02- 2022  
OP/IP :OUT PATIENT

**CHEST XRAY PA VIEW**

- Trachea is in midline.
- Hila appear Normal.
- Mediastinal shadow appears normal.
- Costophrenic&Cardiophrenic angles appear free.
- Cardiothoracic ratio is within normal limits.
- Lungs fields appear clear
- Bony thorax and soft tissue appear normal

**IMPRESSION:**

- No significant abnormality noted.



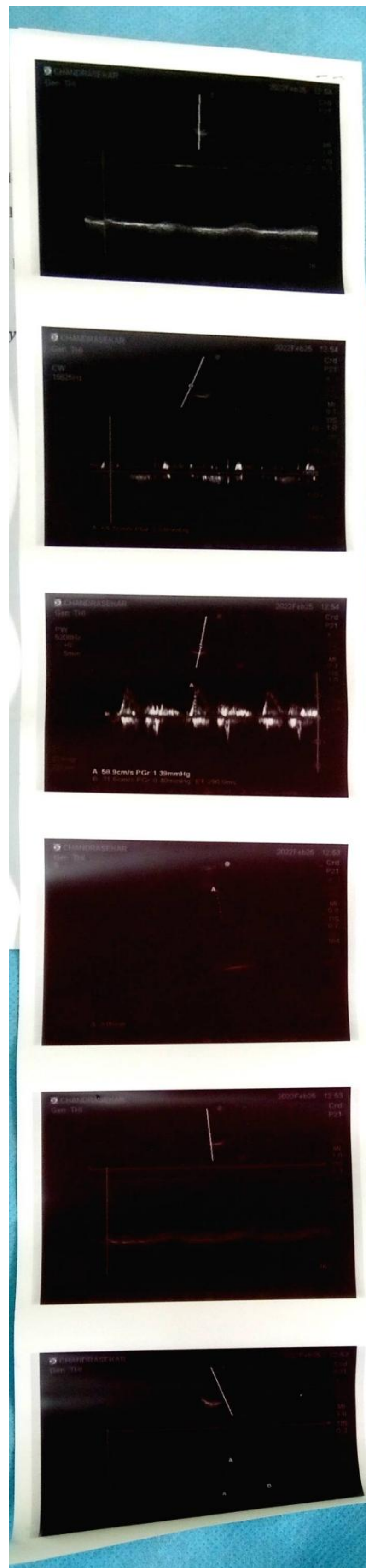
CONSULTANT RADIOLOGIST

Healing Hearts and Lives

264/125, Kilpauk Garden Road, Kilpauk, Chennai - 600 010. Phone : +91 44 4644 8989 / 75500 53335

Email : muruganhosp@gmail.com | Website : www.muruganhospitals.in









**SCAN REPORT**

NAME : MR. K.M.CHANDRASEKHAR UHID NO : MH20220035116  
AGE / SEX : 45/MALE IP / NO : OUTPATIENT  
CONSULTANT: DR. ARUN PRAKASH DATE : 25.02.2022

**ULTRA SOUND SCAN OF ABDOMEN**

**LIVER:** Normal in size and measures 12.3 cm and normal in echotexture. No focal lesions are seen. No dilatation of intra-hepatic biliary radicals present. Hepatic veins and IVC appear normal. Portal vein is normal in caliber. Common bile duct is normal in caliber.

**GALL BLADDER:** Normal in size and wall thickness. No evidence of any calculus or mass present. No evidence of pericholecystic collections.

**PANCREAS:** Normal in size and echotexture. No focal lesions are seen. No evidence of calculi or calcifications. No evidence of pancreatic duct dilation.

**PARA AORTIC AREAS:** Aorta and IVC appear normal. No evidence of para aortic lymphadenopathy.

**SPLEEN:** Normal in size and measures 8.6 cm. Normal in echotexture. No evidence of focal lesions.

**RIGHT KIDNEY:** Measures 8.7 X 3.8 cm and is normal in size and echotexture. Cortico medullary differentiation is well maintained. There is no calculus hydronephrosis or mass.

**LEFT KIDNEY:** Measures 9.9 X 3.9 cm and is normal in size and echotexture. Cortico medullary differentiation is well maintained. There is no calculus hydronephrosis or mass.

Healing Hearts and Lives

264/125, Kilpauk Garden Road, Kilpauk, Chennai - 600 010. Phone : +91 44 4644 8989 / 75500 53335  
Email : muruganhosp@gmail.com | Website : www.muruganhospitals.in



**URINARY BLADDER:** Partially distended.

**PROSTATE:** Grossly appears normal in size and echotexture. Seminal vesicles appear normal.

No ascites present. No retroperitoneal lymphadenopathy present.

**IMPRESSION:**

✓ *No significant abnormality detected in the visualized organs.*



**Dr. SARAVANAN, MDRD.**  
**Consultant Radiologist.**





**ECHO CARDIOGRAM REPORT**

NAME: MR.K.M.CHANDRASEKHAR

UHID NO: MH20220035116

AGE&SEX : 45 /MALE

IP/OP: OUTPATIENT

CONSULTANT: DR. ARUN PRAKASH

DATE : 25-02-2022

**2D PLAX (mm)**

RV - 31 mm  
AO - 39 mm  
LA - 26 mm

**COLOR DOPPLER**

Normal

**M-Mode (mm)**


IVS - 07 mm  
PW - 08 mm  
LVD - 36 mm  
LVS - 22 mm  
EF - 70 %  
FS - 39 %

**DOPPLER (m/sec)**

MITRAL E - 0.6m/s  
MITRAL A - 0.3 m/s  
PULMONARY - 1.1 m/s  
AORTIC - 0.8 m/s  
TRICUSPID - 0.4 m/s

**IMPRESSION:**

No RWMA  
Normal biventricular function  
No pulmonary hypertension  
No pericardial effusion  
No clot/ Vegetation.

  
Dr. SIDHARTHAN ,MD.,DM.,  
Consultant Cardiologist

Healing Hearts and Lives

264/125, Kilpauk Garden Road, Kilpauk, Chennai - 600 010.

Phone : +91 44 4644 8989 / 75500 53335 | Email : muruganhosp@gmail.com

Website : www.muruganhospitals.in



