

Mr Alok Kumar Sharma

24/2/23



**Park Hospital**  
GROUP SUPER SPECIALITY HOSPITAL




Cert. No. MC - 4830



Cert. No. H-2018-0369

For medical exam



Oral - NAD

Nose - Septum median  
Bk nasal cavity - NAD

Ado

P1A  
  
 24/2/23

(This is only professional opinion and not the diagnosis, Please correlate clinically)

Q Block South City 11, Sohna Road, Main Sector-47, Gurgaon, Haryana

Ph.: 0124-4900000 (100 Lines) Fax : 0124-2218733 E-mail : parkmedicenters@gmail.com

**PARK GROUP OF HOSPITALS : West Delhi • South Delhi • Gurgaon • Karnal • Panipat • Hodal • Ambala • Behror**

the **health** care providers

the **health** care providers



Scanned with OKEN Scanner



**Park Hospital**  
GROUP SUPER SPECIALITY HOSPITAL

Advised - Composite restoration w.r.t  $\frac{6}{7}$   
Scaling and polishing



Cert. No. H-2016-0300 Cert. No. MC-4930

(This is only professional opinion and not the diagnosis, please correlate clinically)

Q Block, South City -II, Sohna Road, Sector-47, Gurgaon, Haryana

Ph.: 0124-4900000 (100 Lines), Toll Free No. : 1800-102-6767, Mob.: 62 62 82 82 35, Email: [customercare@parkhospital.in](mailto:customercare@parkhospital.in)

**PARK GROUP OF HOSPITALS** : West Delhi - Gurugram - Faridabad - Sonapat - Panipat - Karnal - Ambala - Patiala - Behror - Jaipur

the **health** care providers

the **health** care providers



Scanned with OKEN Scanner



Mr. Alex Kk Sharma, 35/14.

For general health checkup

do No fresh complaints

No previous comorbidities

O/E

BP - 142/96 mm of Hg.

Chest - B/L vesicular B/S

CRS - S1 S2 (+)

PIA - Soft, L's

ECG! -

RAD.

Adv

1. Review with reports



Cert. No. H-2018-0369 Cert. No. MC-4830

(This is only professional opinion and not the diagnosis, please correlate clinically)

Q Block, South City -II, Sohna Road, Sector-47, Gurgaon, Haryana  
Ph.: 0124-4900000 (100 Lines), Toll Free No. : 1800-102-6767, Mob.: 82 62 82 82 35, Email: customercare@parkhospital.in

**PARK GROUP OF HOSPITALS** : West Delhi - Gurugram - Faridabad - Sonapat - Panipat - Karnal - Ambala - Patiala - Behror - Jaipur

the **health** care providers

the **health** care providers





IP- 672634

Mr. Alok Kumar Sharma  
35y/M

Routine eyes checkup


UV { 6/6 unaided  
      6/6

RET { 18  
      15

NV { 100  
      100

Colour Vision - normal - BE

Fundus Examination - Normal



Cert. No. H-2015-0369 Cert. No. MC-4830

(This is only professional opinion and not the diagnosis, please correlate clinically)

Q Block, South City -II, Sohna Road, Sector-47, Gurgaon, Haryana

Ph.: 0124-4900000 (100 Lines), Toll Free No. : 1800-102-6767, Mob.: 62 62 82 82 35, Email: customercare@parkhospital.in

PARK GROUP OF HOSPITALS : West Delhi - Gurugram - Faridabad - Sonapat - Panipat - Karnal - Ambala - Patiala - Behror - Jaipur





24/2/23

g.B. Dermatology

Vitals :

Chief Complaints :

BP:- 130/80 mmHg  
Height:- 167 cm.  
Weight:- 77.6 kg

H/O Present Illness :

Past History :

Investigation :

Drug Allergies : (if any)

Treatment :

? eczema  
? fungal acne

Adv:-

CALOSOFT  
AF LOTION

+ EXCELA MAX  
LOTION

(YA) ✓ 2 weeks

- ABZORB DUSTING  
POWDER

(YA) ✓ 2 weeks  
Bact Ointment

(YA) ✓ 2 weeks (YA) ✓ 2 weeks

ANASOL NC (Bact) - BANZAC AC  
gel 2.5 gel

(YA) M 2 weeks (YA) 2 weeks

Gurgaon

Q Block South City 11, Sohna Road, Main Sector-47, Gurgaon, Haryana Ph: 24-4900000 Fax: 0124-2216733  
E-mail: parkmedicenters@gmail.com

• West Delhi • South Delhi • Faridabad • Panipat • Karnal

the health care providers

the health care providers



**DEPARTMENT OF PATHOLOGY**

Patient Name : Mr. ALOK KUMAR SHARMA  
MR No : 672624  
Age/Sex : 35 Years 5 Months 15 Days / Male  
Type : OPD  
TPA/Corporate : MEDIWHEEL PVT LTD

Bill Date : 24/02/2023  
Reporting Date : 24/02/2023  
Sample ID : 103778  
Bill/Req. No. : 24047031  
Ref Doctor : Dr.RMO

Test	Result	Bio. Ref. Interval	Units	Method
<b>BLOOD SUGAR 2 HR. PP</b>				
BLOOD SUGAR P.P.	135	80 - 150	mg/dl	

\*\*\*\*\* END OF THE REPORT \*\*\*\*\*



Sample no.

Dr. SONIA KUMARI  
MBBS, MD (PATHOLOGY) Gold medalist

Dr. PRADIP KUMAR  
Consultant (Microbiology)

Dr. NISHA TIWARI  
MBBS, MD (Microbiology)

USER NM ARUN



Cert. No. H-2016-0369 Cert. No. MC-4830

(This is only professional opinion and not the diagnosis, please correlate clinically) Page 1 of 1

Q Block, South City -II, Sohna Road, Sector-47, Gurgaon, Haryana  
Ph.: 0124-4900000 (100 Lines), Toll Free No. : 1800-102-6767, Mob.: 62 62 82 82 35, Email: [customercare@parkhospital.in](mailto:customercare@parkhospital.in)

**PARK GROUP OF HOSPITALS** : West Delhi - Gurugram - Faridabad - Sonapat - Panipat - Karnal - Ambala - Patiala - Behror - Jaipur

the health care providers

the health care providers





## DEPARTMENT OF PATHOLOGY

Patient Name : Mr. ALOK KUMAR SHARMA  
 MR No : 672624  
 Age/Sex : 35 Years 5 Months 15 Days / Male  
 Type : OPD  
 TPA/Corporate : MEDIWHEEL PVT LTD  
 Ref Doctor : Dr.RMO

Bill Date : 24/02/2023 9.57 AM  
 Sample Col Dt/Tm : 24/02/2023 11:26 am  
 Sample Rec Dt/Tm : 24/02/2023 11:26 am  
 Reporting Date : 2023-02-24 00:00:00-01 14:48:  
 Sample ID : 103778  
 Bill/Req. No. : 24047031

Test	Result	Bio. Ref. Interval	Units	Method
<b>BLOOD SUGAR FASTING</b>				
PLASMA GLUCOSE FASTING	95	60 - 110	mg/dl	GOD TRINDERS

\*\*\*\*\* END OF THE REPORT \*\*\*\*\*



Dr. PRADIP KUMAR  
 Consultant (Microbiology)

Dr. SONIA KUMARI  
 MD Pathology (Gold Medalist)

Dr. NISHA TIWARI  
 MBBS, MD (Microbiology)  
 USER NM ARUN



Cert. No. H-2016-0369 Cert. No. MC - 4830

(This is only professional opinion and not the diagnosis, please correlate clinically) Page 1 of 1

Q Block, South City -II, Sohna Road, Sector-47, Gurgaon, Haryana  
 Ph.: 0124-4900000 (100 Lines), Toll Free No. : 1800-102-6767, Mob.: 62 62 82 82 35, Email: [customer@parkhospital.in](mailto:customer@parkhospital.in)

PARK GROUP OF HOSPITALS : West Delhi - Gurugram - Faridabad - Sonapat - Panipat - Karnal - Ambala - Patiala - Behror - Jaipur

the **health** care providers the **health** care providers





**DEPARTMENT OF PATHOLOGY**

<b>Patient Name</b> :	Mr. ALOK KUMAR SHARMA	<b>Bill Date</b> :	24/02/2023
<b>MR No</b> :	672624	<b>Reporting Date</b> :	24/02/2023
<b>Age/Sex</b> :	35 Years 5 Months 15 Days / Male	<b>Sample ID</b> :	103778
<b>Type</b> :	OPD	<b>Bill/Req. No.</b> :	24047031
<b>TPA/Corporate</b> :	MEDIWHEEL PVT LTD	<b>Ref Doctor</b> :	Dr.RMO

Test	Result	Bio. Ref. Interval	Units	Method
------	--------	--------------------	-------	--------

**BLOOD GROUPING AND RH FACTOR**

BLOOD GROUP	* O * RH POSITIVE	MATRIX GEL
-------------	-------------------	------------

\*\*\*\*\* END OF THE REPORT \*\*\*\*\*



Sample no.

**Dr. SONIA KUMARI**  
MBBS, MD (PATHOLOGY) Gold medalist

**Dr. PRADIP KUMAR**  
Consultant (Microbiology)

**Dr. NISHA TIWARI**  
MBBS, MD (Microbiology)

USER NM      ARUN



Cert. No. H-2016-0369    Cert. No. MC - 4830

(This is only professional opinion and not the diagnosis, please correlate clinically)

Page 1 of 1

Q Block, South City -II, Sohna Road, Sector-47, Gurgaon, Haryana  
Ph.: 0124-4900000 (100 Lines), Toll Free No. : 1800-102-6767, Mob.: 62 62 82 82 35, Email: [customercare@parkhospital.in](mailto:customercare@parkhospital.in)

**PARK GROUP OF HOSPITALS** ; West Delhi - Gurugram - Faridabad - Sonapat - Panipat - Karnal - Ambala - Patiala - Behror - Jaipur







## DEPARTMENT OF PATHOLOGY

Patient Name : Mr. ALOK KUMAR SHARMA  
 MR No : 672624  
 Age/Sex : 35 Years 5 Months 15 Days / Male  
 Type : OPD  
 TPA/Corporate : MEDIWHEEL PVT LTD

Bill Date : 24/02/2023  
 Reporting Date : 24/02/2023  
 Sample ID : 103778  
 Bill/Req. No. : 24047031  
 Ref Doctor : Dr.RMO

Test	Result	Bio. Ref. Interval	Units	Method
<b>CBC</b>				
HAEMOGLOBIN	14.5	12 - 16	gm/dL	COLORIMETRY
TOTAL LEUCOCYTE COUNT	5800	4000-11000	/ $\mu$ L	ELECTRICAL
<b>DIFFERENTIAL COUNT</b>				
NEUTROPHILS	55	40.0 - 80.0	%	FLOW CYTOMETRY
LYMPHOCYTES	35	20.0 - 40.0	%	FLOW CYTOMETRY
MONOCYTES	08	2.0 - 10.0	%	FLOW CYTOMETRY
EOSINOPHILS	02	0.0 - 5.0	%	FLOW CYTOMETRY
BASOPHILS	00	0.0 - 2.0	%	FLOW CYTOMETRY
RED BLOOD CELL COUNT	4.9	3.5 - 5.5	millions/ $\mu$ L	ELECTRICAL
PACKED CELL VOLUME	48.0	35.0 - 50.0	%	ELECTRICAL
MEAN CORPUSCULAR VOLUME	96.5	83 - 101	fL	ELECTRICAL
MEAN CORPUSCULAR HAEMOGLOBIN	29.2	27 - 31	Picogrames	CALCULATED
MEAN CORPUSCULAR HB CONC	<b>30.2</b>	L 33 - 37	g/dl	CALCULATED
PLATELET COUNT	293	150 - 450	thou/ $\mu$ L	ELECTRICAL
RDW	13.2	11.6 - 14.5	%	CALCULATED

\*\*\*\*\* END OF THE REPORT \*\*\*\*\*



Sample no.

Dr. SONIA KUMARI  
 MBBS, MD (PATHOLOGY) Gold medalist

Dr. PRADIP KUMAR  
 Consultant (Microbiology)

Dr. NISHA TIWARI  
 MBBS, MD (Microbiology)

USER NM ARUN



Page 1 of 1

(This is only professional opinion and not the diagnosis, please correlate clinically)

Q Block, South City -II, Sohna Road, Sector-47, Gurgaon, Haryana

Ph.: 0124-4900000 (100 Lines), Toll Free No. : 1800-102-6767, Mob.: 62 62 82 82 35, Email: [customercare@parkhospital.in](mailto:customercare@parkhospital.in)

PARK GROUP OF HOSPITALS : West Delhi - Gurugram - Faridabad - Sonipat - Panipat - Karnal - Ambala - Patiala - Behror - Jaipur

the health care providers

the health care providers





**DEPARTMENT OF PATHOLOGY**

<b>Patient Name</b> :	Mr. ALOK KUMAR SHARMA	<b>Bill Date</b> :	24/02/2023
<b>MR No</b> :	672624	<b>Reporting Date</b> :	24/02/2023
<b>Age/Sex</b> :	35 Years 5 Months 15 Days / Male	<b>Sample ID</b> :	103778
<b>Type</b> :	OPD	<b>Bill/Req. No.</b> :	24047031
<b>TPA/Corporate</b> :	MEDIWHEEL PVT LTD	<b>Ref Doctor</b> :	Dr.RMO

Test	Result	Bio. Ref. Interval	Units	Method
<b>ESR (WESTERGREN)</b>				
E.S.R. - II HR,	45		mm II Hr.	Westergren

\*\*\*\*\* END OF THE REPORT \*\*\*\*\*



Sample no.

**Dr. SONIA KUMARI**  
MBBS, MD (PATHOLOGY) Gold medalist

**Dr. PRADIP KUMAR**  
Consultant (Microbiology)

**Dr. NISHA TIWARI**  
MBBS, MD (Microbiology)

USER NM ARUN



Cert No. 11-2016-0369 Cert No. MC - 4830

(This is only professional opinion and not the diagnosis, please correlate clinically)

Q Block, South City -II, Sohna Road, Sector-47, Gurgaon, Haryana  
Ph.: 0124-4900000 (100 Lines), Toll Free No. : 1800-102-6767, Mob.: 62 62 82 82 35, Email: [customercare@parkhospital.in](mailto:customercare@parkhospital.in)

**PARK GROUP OF HOSPITALS** : West Delhi - Gurugram - Faridabad - Sonapat - Panipat - Karnal - Ambala - Patiala - Behror - Jaipur

the **health** care providers

the **health** care providers





**DEPARTMENT OF PATHOLOGY**

Patient Name	: Mr. ALOK KUMAR SHARMA	Bill Date	: 24/02/2023
MR No	: 672624	Reporting Date	: 24/02/2023
Age/Sex	: 35 Years 5 Months 15 Days / Male	Sample ID	: 103778
Type	: OPD	Bill/Req. No.	: 24047031
TPA/Corporate	: MEDIWHEEL PVT LTD	Ref Doctor	: Dr.RMO

Test	Result	Bio. Ref. Interval	Units	Method
<b>THYROID PROFILE</b>				
TRI-IODOTHYRONINE (T3)	1.47	0.60 - 1.81	ng/ml	Chemiluminescence
THYROXINE (T4)	9.8	5.01 - 12.45	µg/dL	Chemiluminescence
THYROID STIMULATING HORMONE	1.47	0.5-5.50 ,	µIU/ml	
SPECIMEN TYPE	SERUM			
Method : chemiluminescent immunoassay				

**Note : Clinical Significance:**

Thyroid function tests (TFTs) is a collective term for blood tests used to check the function of the thyroid. TFTs may be requested if a patient is thought to suffer from hyperthyroidism (overactive thyroid) or hypothyroidism (underactive thyroid), or to monitor the effectiveness of either thyroid-suppression or hormone replacement therapy. It is also requested routinely in conditions linked to thyroid disease, such as atrial fibrillation and anxiety disorder. A TFT panel typically includes thyroid hormones such as thyroid-stimulating hormone (TSH, thyrotropin) and thyroxine (T4), and triiodothyronine (T3) depending on local laboratory policy.

Note: Please correlate with clinical condition

\*\*\*\* END OF THE REPORT \*\*\*\*



Sample no.

**Dr. SONIA KUMARI**  
MBBS, MD (PATHOLOGY) Gold medalist

**Dr. PRADIP KUMAR**  
Consultant (Microbiology)

**Dr. NISHA TIWARI**  
MBBS, MD (Microbiology)

USER NM      DINESH



Cert. No. H-2016-0389    Cert No. MC - 4830

(This is only professional opinion and not the diagnosis, please correlate clinically)

Q Block, South City -II, Sohna Road, Sector-47, Gurgaon, Haryana  
Ph.: 0124-4900000 (100 Lines), Toll Free No. : 1800-102-6767, Mob.: 62 62 82 82 35, Email: [customercare@parkhospital.in](mailto:customercare@parkhospital.in)

**PARK GROUP OF HOSPITALS** : West Delhi - Gurugram - Faridabad - Sonapat - Panipat - Karnal - Ambala - Patiala - Behror - Jaipur



**DEPARTMENT OF PATHOLOGY**

Patient Name : Mr. ALOK KUMAR SHARMA  
 MR No : 672624  
 Age/Sex : 35 Years 5 Months 15 Days / Male  
 Type : OPD  
 TPA/Corporate : MEDIWHEEL PVT LTD

Bill Date : 24/02/2023  
 Reporting Date : 24/02/2023  
 Sample ID : 103778  
 Bill/Req. No. : 24047031  
 Ref Doctor : Dr.RMO

Test	Result	Bio. Ref. Interval	Units	Method
<b>LFT (LIVER FUNCTION TEST)</b>				
LFT				
TOTAL BILIRUBIN	0.2	0 - 1.2	mg/dL	DIAZO
DIRECT BILIRUBIN	0.1	0 - 0.4	mg/dL	DIAZO
INDIRECT BILIRUBIN	0.1	0.10 - 0.6	mg/dL	CALCULATED
SGOT (AST)	36	0 - 45	U/L	IFCC WITHOUT
SGPT (ALT)	<b>47</b>	<i>H</i> 0 - 45	U/L	IFCC WITHOUT
ALKALINE PHOSPHATASE	60	30 - 170	IU/L	MODIFIED IFCC
TOTAL PROTEINS	6.5	6.4 - 8.0	g/dL	BIURET
ALBUMIN	4.5	3.3 - 5.5	g/dL	BCG DYE
GLOBULIN	<b>2</b>	<i>L</i> 2.3 - 4.5	g/dL	CALCULATED
A/G RATIO	<b>2.25</b>	<i>H</i> 1.1 - 2.2		CALCULATED

\*\*\*\*\* END OF THE REPORT \*\*\*\*\*



Sample no.

Dr. SONIA KUMARI  
MBBS, MD (PATHOLOGY) Gold medalist

Dr. PRADIP KUMAR  
Consultant (Microbiology)

Dr. NISHA TIWARI  
MBBS, MD (Microbiology)

USER NM ARUN



(This is only professional opinion and not the diagnosis, please correlate clinically) Page 1 of 1

Q Block, South City -II, Sohna Road, Sector-47, Gurgaon, Haryana

Ph.: 0124-4900000 (100 Lines), Toll Free No. : 1800-102-6767, Mob.: 62 62 82 82 35, Email: [customercare@parkhospital.in](mailto:customercare@parkhospital.in)

PARK GROUP OF HOSPITALS : West Delhi - Gurugram - Faridabad - Sonapat - Panipat - Karnal - Ambala - Patiala - Behror - Jaipur

the **health** care providers

the **health** care providers





**DEPARTMENT OF PATHOLOGY**

<b>Patient Name</b> :	Mr. ALOK KUMAR SHARMA	<b>Bill Date</b> :	24/02/2023
<b>MR No</b> :	672624	<b>Reporting Date</b> :	24/02/2023
<b>Age/Sex</b> :	35 Years 5 Months 15 Days / Male	<b>Sample ID</b> :	103778
<b>Type</b> :	OPD	<b>Bill/Req. No.</b> :	24047031
<b>TPA/Corporate</b> :	MEDIWHEEL PVT LTD	<b>Ref Doctor</b> :	Dr.RMO

Test	Result	Bio. Ref. Interval	Units	Method
<b>PSA TOTAL</b>				
PROSTATE SPECIFIC ANTIGEN(PSA)	0.99	0.57 - 4.0	ng/ml	Chemiluminscence
SPECIMEN TYPE	SERUM			
Method : chemiluminescent immunoassay				

**Note : Clinical Use: -**

An aid in the early detection of Prostate cancer in Male. Follow up and amazement of Prostate cancer patients. Detect metastatic or persistent disease in patients following surgical or medical treatment of Prostate cancer

**Note: -**

False negative / positive results are observed in patients receiving mouse monoclonal antibodies for diagnosis or therapy. PSA levels may appear consistently elevated / depressed due to the interference by heterophilic antibodies & non-specific protein binding. PSA values regardless of levels should not be interpreted as absolute evidence of the presence or absence of disease. All values should be correlated with clinical findings and results of other investigations.

\*\*\*\*\* END OF THE REPORT \*\*\*\*\*



Sample no.

**Dr. SONIA KUMARI**  
MBBS, MD (PATHOLOGY) Gold medalist

**Dr. PRADIP KUMAR**  
Consultant (Microbiology)

**Dr. NISHA TIWARI**  
MBBS, MD (Microbiology)

USER NM DINESH



Cert. No. H-2016-0369 Cert. No. MC-4630

(This is only professional opinion and not the diagnosis, please correlate clinically) Page 1 of 1

Q Block, South City -II, Sohna Road, Sector-47, Gurgaon, Haryana

Ph.: 0124-4900000 (100 Lines), Toll Free No. : 1800-102-6767, Mob.: 62 62 82 82 35, Email: [customercare@parkhospital.in](mailto:customercare@parkhospital.in)

**PARK GROUP OF HOSPITALS** : West Delhi - Gurugram - Faridabad - Sonapat - Panipat - Karnal - Ambala - Patiala - Behror - Jaipur

the **health** care providers

the **health** care providers





**DEPARTMENT OF PATHOLOGY**

<b>Patient Name</b> :	Mr. ALOK KUMAR SHARMA	<b>Bill Date</b> :	24/02/2023
<b>MR No</b> :	672624	<b>Reporting Date</b> :	24/02/2023
<b>Age/Sex</b> :	35 Years 5 Months 15 Days / Male	<b>Sample ID</b> :	103778
<b>Type</b> :	OPD	<b>Bill/Req. No.</b> :	24047031
<b>TPA/Corporate</b> :	MEDIWHEEL PVT LTD	<b>Ref Doctor</b> :	Dr.RMO

Test	Result	Bio. Ref. Interval	Units	Method
------	--------	--------------------	-------	--------

**STOOL ROUTINE AND MICROSCOPY**

STOOL ROUTINE AND MICROSCOPY				
COLOUR	Pale Yellow	Pale Yellow		Vishal
CONSISTENCY	Semi Liquid	Formed		Manual
OCCULT BLOOD	NIL	NIL		Guaiac test
MUCUS	NIL	NIL		Microscopic
PUS CELL	4-6	0-5	cells/hpf	Microscopic
RECS	NIL	NIL		
CYSTS	NIL	NIL		Microscopic
OVA	NIL	Nil		Microscopic
FAT GLOBULE	NIL	Nil		Microscopic
PARASITES	NIL	Nil		Microscopic

\*\*\*\*\* END OF THE REPORT \*\*\*\*\*



Sample no.

**Dr. SONIA KUMARI**  
MBBS, MD (PATHOLOGY) Gold medalist

**Dr. PRADIP KUMAR**  
Consultant (Microbiology)

**Dr. NISHA TIWARI**  
MBBS, MD (Microbiology)

USER NM ARUN



Cert No. H-2015-0369 Cert No. MC - 4830

(This is only professional opinion and not the diagnosis, please correlate clinically)

Page 1 of 1

Q Block, South City -II, Sohna Road, Sector-47, Gurgaon, Haryana  
Ph.: 0124-4900000 (100 Lines), Toll Free No. : 1800-102-6767, Mob.: 62 62 82 82 35, Email: [customercare@parkhospital.in](mailto:customercare@parkhospital.in)

**PARK GROUP OF HOSPITALS** : West Delhi - Gurugram - Faridabad - Sonipat - Panipat - Karnal - Ambala - Patiala - Behror - Jaipur

the **health** care providers

the **health** care providers





## DEPARTMENT OF PATHOLOGY

Patient Name : Mr. ALOK KUMAR SHARMA  
 MR No : 672624  
 Age/Sex : 35 Years 5 Months 15 Days / Male  
 Type : OPD  
 TPA/Corporate : MEDIWHEEL PVT LTD

Bill Date : 24/02/2023  
 Reporting Date : 24/02/2023  
 Sample ID : 103778  
 Bill/Req. No. : 24047031  
 Ref Doctor : Dr.RMO

Test	Result	Bio. Ref. Interval	Units	Method
<b>KFT (RENAL PROFILE)</b>				
KFT				
SERUM UREA	22	10 - 45	mg/dL	UREASE-GLDH
SERUM CREATININE	0.9	0.4 - 1.4	mg/dL	MODIFIED JAFFES
SERUM URIC ACID	4.5	2.5 - 7.0	mg/dL	URICASE
SERUM SODIUM	138	136 - 148	mmol/L	ISE
SERUM POTASSIUM	4.1	3.5 - 5.5	meq/l	ISE
SERUM CALCIUM	8.6	8.5 - 10.5	mg/dL	ARSENazo III
SERUM PHOSPHORUS	3.2	2.5 - 4.5	mg/dL	AMMONIUM

\*\*\*\*\* END OF THE REPORT \*\*\*\*\*



Sample no.

Dr. SONIA KUMARI  
 MBBS, MD (PATHOLOGY) Gold medalist

Dr. PRADIP KUMAR  
 Consultant (Microbiology)

Dr. NISHA TIWARI  
 MBBS, MD (Microbiology)

USER NM ARUN



(This is only professional opinion and not the diagnosis, please correlate clinically)

Page 1 of 1

Cert. No. H-2016-0369 Cert. No. MC-4830

Q Block, South City-II, Sohna Road, Sector-47, Gurgaon, Haryana  
 Ph.: 0124-4900000 (100 Lines), Toll Free No. : 1800-102-6767, Mob.: 62 62 82 82 35, Email: customercare@parkhospital.in

**PARK GROUP OF HOSPITALS** : West Delhi - Gurugram - Faridabad - Sonipat - Panipat - Karnal - Ambala - Patiala - Behror - Jaipur

the health care providers

the health care providers





NAME	: MR. ALOK KUMAR SHARMA	DATE	: 24 / 02 / 2023
Age Sex	: 35 Years / Male	Inpatient No	:
PERFORMED BY	: Dr. NAVJEET SINGH	Bill No	: 24047031

## TRANS THORACIC ECHO CARDIOGRAPHY REPORT

### MITRAL VALVE

**Morphology** AML: Normal / Thickening / Calcification / Flutter / Vegetation / Non significant Prolapse / SAM  
PML: Normal / Thickening / Calcification / Prolapse / Paradoxical Motion / Fixed.  
Subvalvular deformity: Present / Absent

**Doppler** Normal / Abnormal E – 05m/sec. A- 07 m/sec. (E<A)  
Mitral Stenosis Present / Absent  
Mitral Regurgitation; Absent / Mild / Trace / Moderate / Severe.  
Velocity – 1.1m/sec

### TRICUSPID VALVE

**Morphology** Normal / Atresia / Thickening / Calcification / Prolapse / Vegetation / Doming.  
**Doppler** Normal / Abnormal  
Tricuspid Stenosis : Present / Absent.  
Tricuspid Regurgitation: Absent / Mild / Trace / Moderate  
Velocity – 1.1m/sec

### PULMONARY VALVE

**Morphology** Normal / Atresia / Thickening / Calcified / Doming / Vegetation.  
**Doppler** Normal / Abnormal.  
Pulmonary stenosis: Present / Absent  
Pulmonary regurgitation : Present / Absent

### AORTIC VALVE

**Morphology** Normal / Thickened / Mildly / Calcified / Flutter / Vegetation / Restricted / Opening  
No. of Cusps 1 / 2 / 3 / 4  
**Doppler** Normal / Abnormal  
Aortic Stenosis : Present / Absent  
Aortic regurgitation : Present / Absent / Mild / Trace



(This is only professional opinion and not the diagnosis, please correlate clinically)

Q Block, South City -II, Sohna Road, Sector-47, Gurgaon, Haryana  
Ph.: 0124-4900000 (100 Lines), Toll Free No. : 1800-102-6767, Mob.: 62 62 82 82 35, Email: [customercare@parkhospital.in](mailto:customercare@parkhospital.in)

**PARK GROUP OF HOSPITALS** : West Delhi - Gurugram - Faridabad - Sonipat - Panipat - Karnal - Ambala - Patiala - Behror - Jaipur

the **health** care providers

the **health** care providers







<u>Measurements</u>	<u>Normal Values</u>	<u>Measurements</u>	<u>Normal Value</u>
IVSD : 0.6cm	(0.6-1.1cm))	LA : 3.4cm	(1.9-4.0cm)
LVID : 5.5cm	(3.7-5.6cm)	LVOT : 1.4cm	
LVPW : 1.1cm	(0.6-1.1cm)	AORTA : 3.2cm	(2.0-3.7cm)
EF : 45-50%	(55% - 80%)	IVSmotion :	Normal / Flat / Paradoxical
Any Other			

**CHAMBERS:-**

**LV** Normal / Enlarged / Clear / Thrombus / Contraction Normal LV shows concentric LVH, no gradient across LVOT / Inetic / Intra capillary Regional wall motion abnormality: Absent/ Present

**LA** Normal / Enlarged / Clear / Thrombus / Myxoma; LAA: Clear / Thrombus

**RA** Normal / Clear / Thrombus, Dilated.

**RV** Normal / Mildly Dilated / Enlarged / Clear / Thrombus / Hypertrophied/

**PERICARDIUM** Normal / Thickening / Calcification / Effusion.

**COMMENTS & SUMMARY:-**

- MILD LV DYSFUNCTION
- GLOBAL HYPOKINESIA
- Global LVEF 45-50%
- LVDD GRADE -I (E<A)
- MILD MR / NO AR
- TRACE TR
- GOOD RV FUNCTION
- IAS/IVS. No Flow seen across IAS/IVS.
- No Thrombus/Mass in any chamber.
- No Pericardial Effusion.

Please correlate clinically

*Navjeet Singh*  
**Dr. NAVJEET SINGH**  
 M.D (Medicine) D.M (Cardiology).  
 HOD & Director Interventional Cardiology.



Cert. No. H-2016-0369 Cert. No. MC - 4830

(This is only professional opinion and not the diagnosis, please correlate clinically)

Q Block, South City -II, Sohna Road, Sector-47, Gurgaon, Haryana  
 Ph.: 0124-4900000 (100 Lines), Toll Free No. : 1800-102-6767, Mob.: 62 62 82 82 35, Email: customercare@parkhospital.in

**PARK GROUP OF HOSPITALS** : West Delhi - Gurugram - Faridabad - Sonipat - Panipat - Karnal - Ambala - Patiala - Behror - Jaipur





**DEPARTMENT OF RADIOLOGY**

Patient Name	Mr ALOK KUMAR SHARMA	Billed Date	: 24/02/2023	9.57 AM
Reg No	672624	Reported Date	: 24/02/2023	
Age/Sex	35 Years 5 Months 15Days / Male	Req. No.	: 24047031	
Type	OPD	Consultant Doctor	: Dr. RMO	

**USG WHOLE ABDOMEN**

The Real time, B mode, gray scale sonography of the abdominal organs was performed.  
**LIVER** : The liver is normal in size, 13.9cm with **fatty infiltration**. No evidence of any focal lesion. IHBR is not dilated.

**GALL BLADDER** :The gall bladder is well distended. No evidence any calculus or mass seen.No evidence of pericholecystic fluid is seen.

**BILE DUCT** :The common bile duct is normal in caliber. No evidence of calculus is noted in common bile duct.

**SPLEEN** :The spleen is normal in size 10.4 cm and shape.Its echotexture is homogeneous.No evidence of focal lesion is noted.

**PANCREAS** :The pancreas is normal in size, shape, contours and echotexture.No evidence of solid or cystic mass lesion is noted.MPD is not dilated. No evidence of peripancreatic collection.

**KIDNEYS** :The bilateral kidneys are normal in size and echotexture. Cortico-medullary differentiation is maintained.There is no evidence of obvious calculus or hydronephrosis.

**URINARY BLADDER** :The urinary bladder is well distended.Wall thickness within normal limits.No evidence of calculus is seen.No evidence of mass or diverticulum is noted.

**PROSTATE**: Prostate appears normal in shape, size and echotexture. It measures 19 CC.

No evidence of ascites or interbowel free fluid is seen.  
No evidence of obvious retroperitoneal or mesentric lymphadenopathy is seen.

**IMPRESSION-** Fatty liver grade-II

To be correlated clinically

Dr. ANSHU K. SHARMA  
MBBS, MD  
CONSULTANT RADIOLOGIST

Dr. MANJEET SEHRAWAT  
MBBS, MD, PDCC  
CONSULTANT RADIOLOGIST

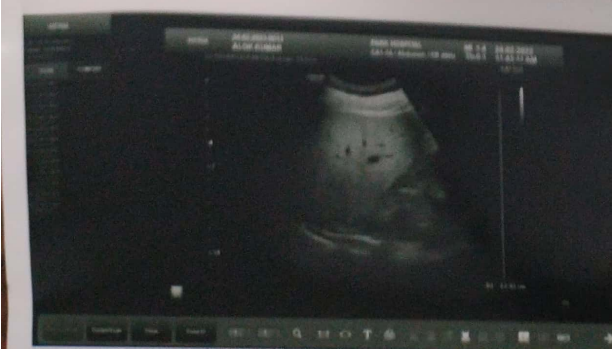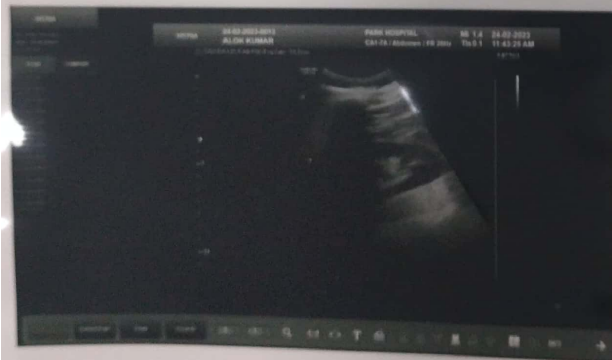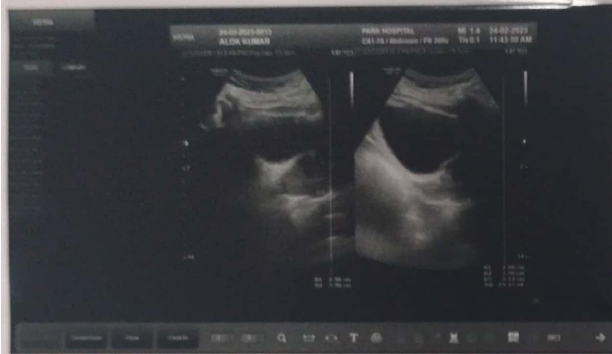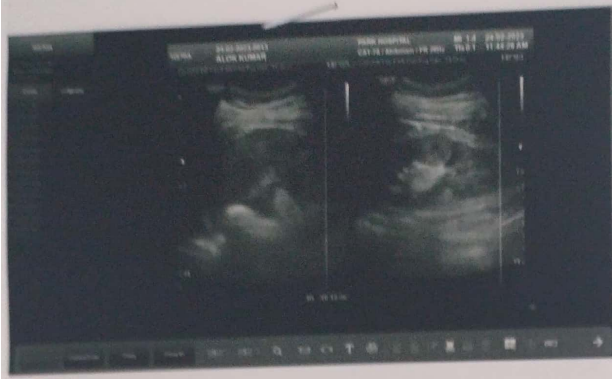Dr. NEENA SIKKA  
MBBS, DNB  
CONSULTANT RADIOLOGIST



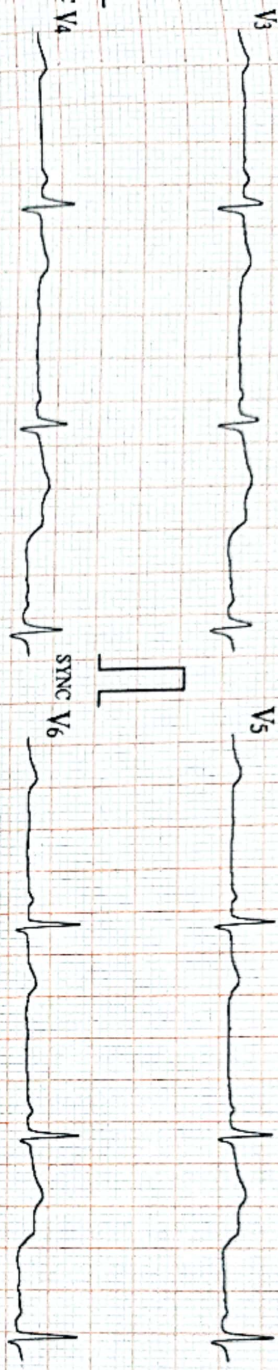(This is only professional opinion and not the diagnosis, please correlate clinically)

Q Block, South City -II, Sohna Road, Sector-47, Gurgaon, Haryana  
Ph.: 0124-4900000 (100 Lines), Toll Free No. : 1800-102-6767, Mob.: 62 62 82 82 35, Email: customercare@parkhospital.in

**PARK GROUP OF HOSPITALS** : West Delhi - Gurugram - Faridabad - Sonapat - Panipat - Karnal - Ambala - Patiala - Behror - Jaipur



10mm/mV



10mm/mV

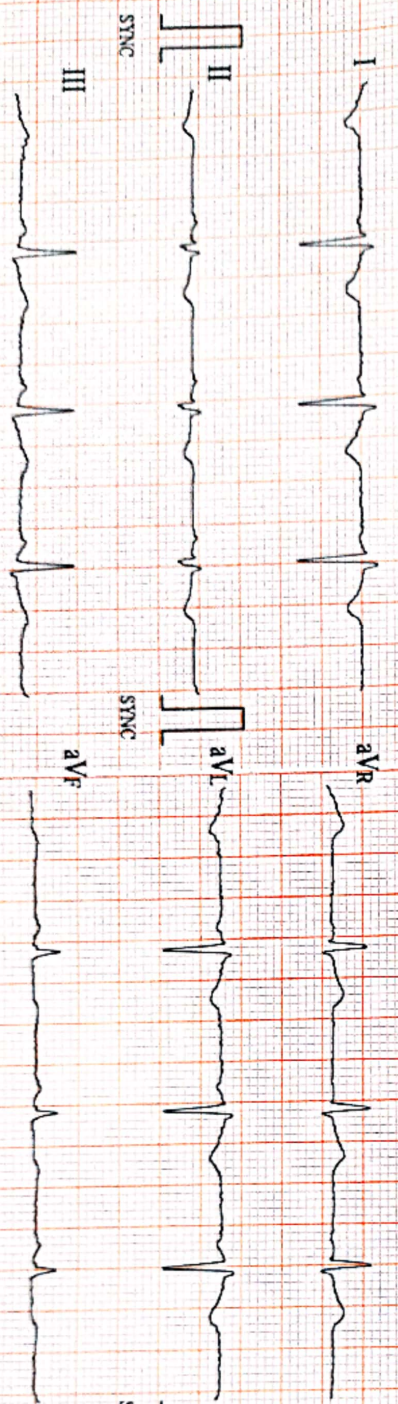
ID : 0001  
 Name: Abdik  
 Sex : Review  
 Age : Shaw  
 HR : 60 bpm  
 R-R : 988 ms  
 P-R : 142 ms  
 QRS : 91 ms  
 QT/QTc : 396/398 ms  
 P/QRS/T : 37/57-5  
 RV5/SV1 : 0.520/0.740 mV  
 RV1/SV1 : 1.260 mV

----- Sinus Rhythm  
 ----- Mild Left Axis Deviation

Unconfirmed report Verified by:

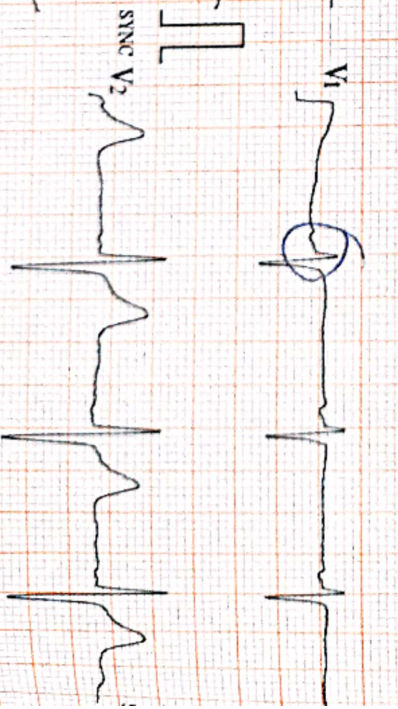
25mm/s 0.5-25Hz

10mm/mV



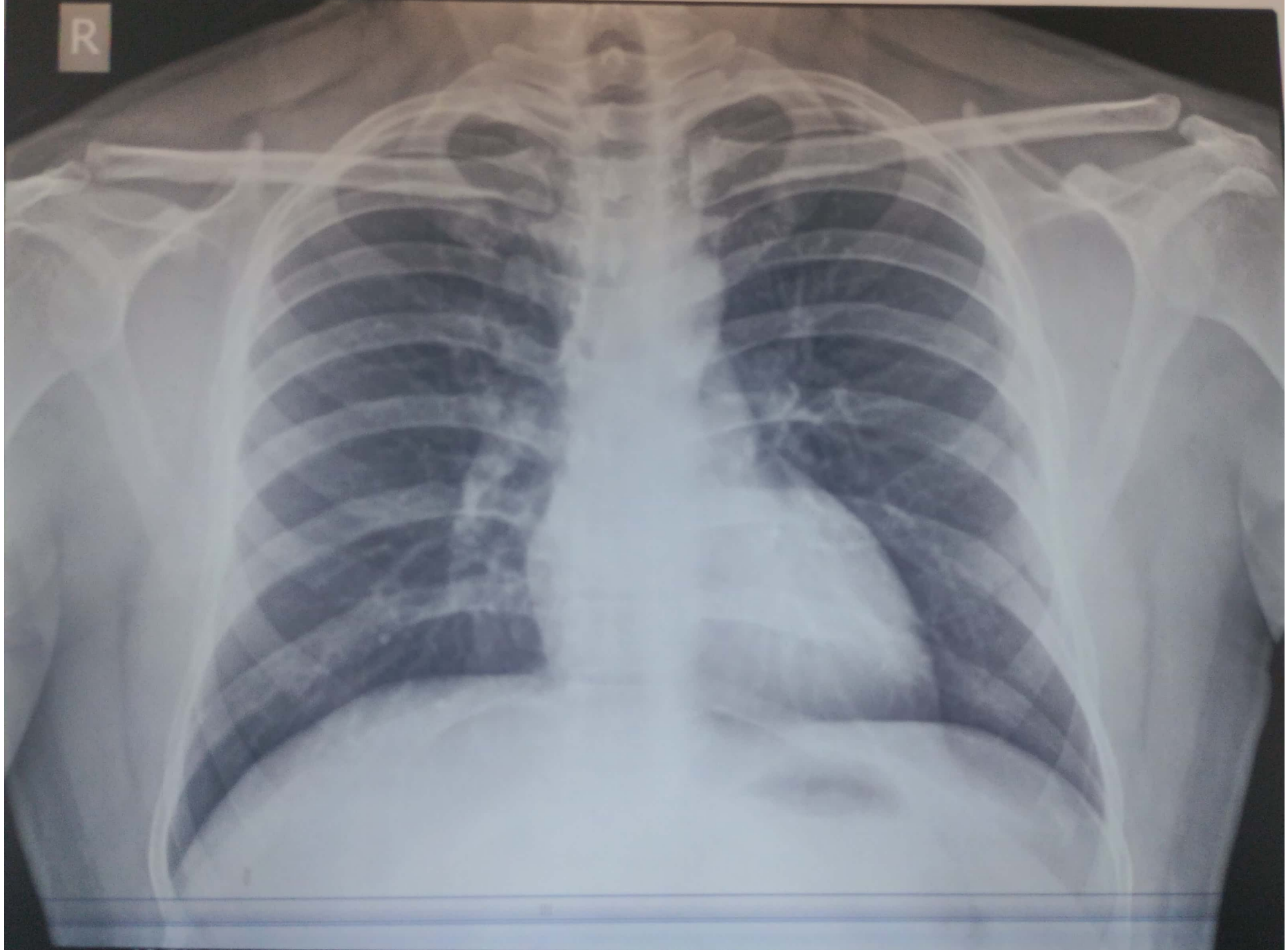
10mm/mV

10mm/mV



ECG-1203 V2-0001 (EKG: V0-0000 / AMP: V0-0000) 2016-09-09 00:00

R



**ALOK KUMAR 35Y/M**      **Chest PA**      **24047031**      **2/24/2023 11:14:29 AM**  
**PARK HOSPITAL, SOUTH CITY II, GURGAON, HARYANA**