
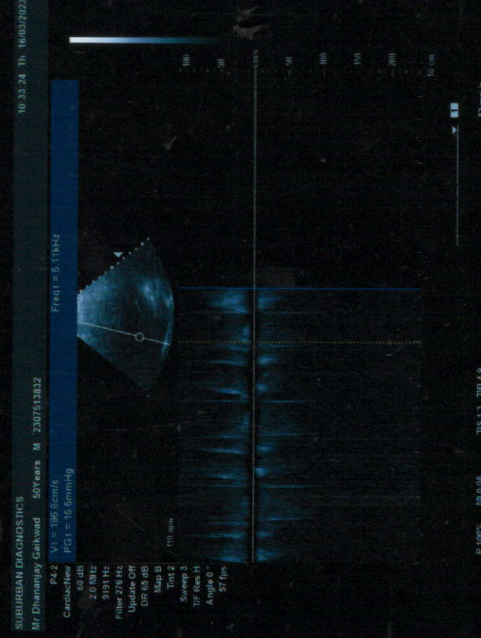
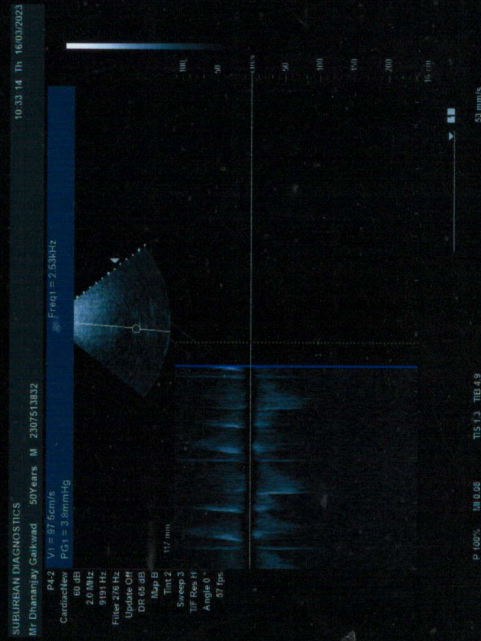
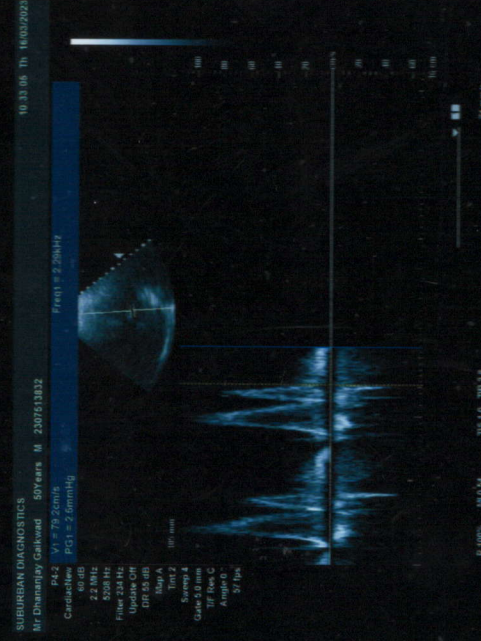
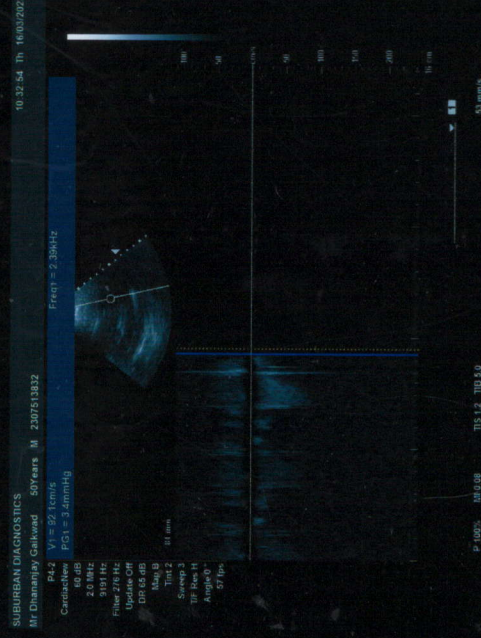
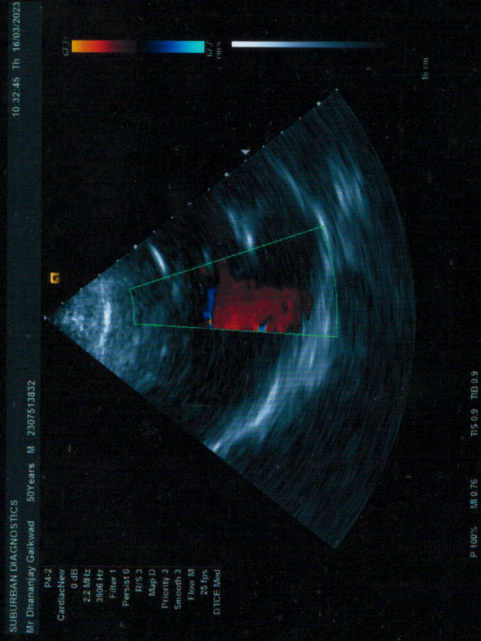
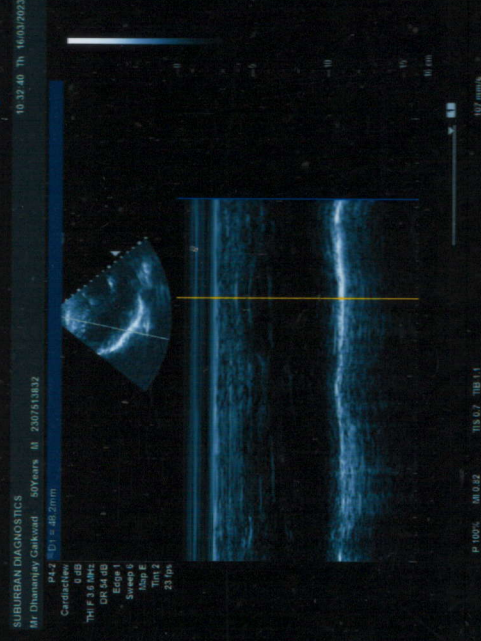
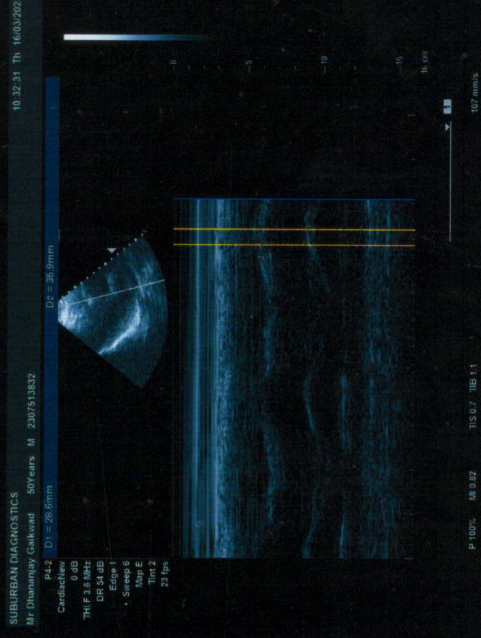
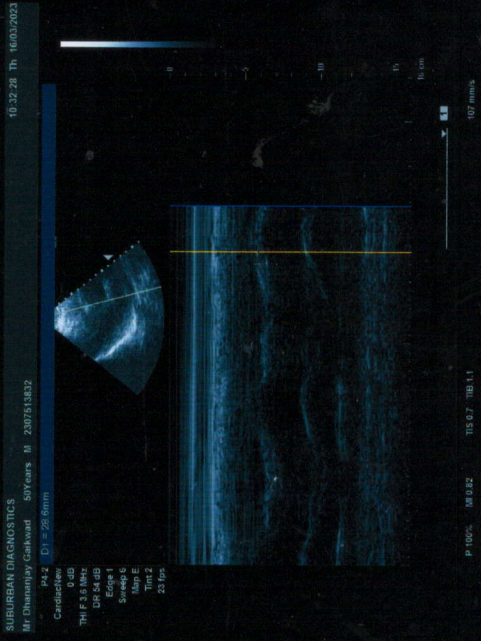


# SUBURBAN DIAGNOSTIC CENTRE

Name : Mr Dhananjay Gaikwad 050Y / M

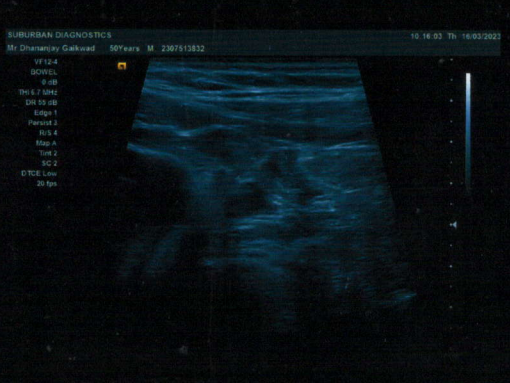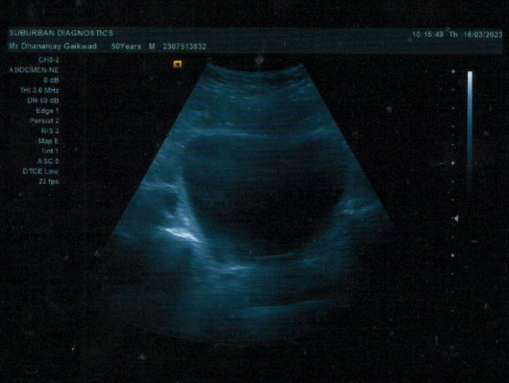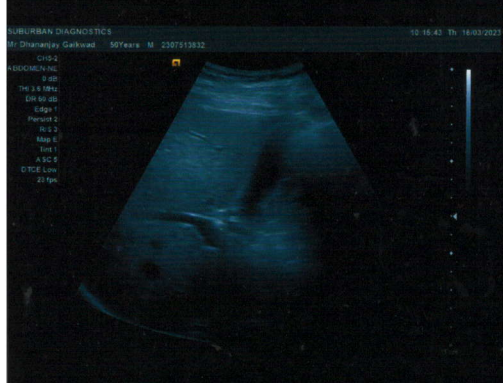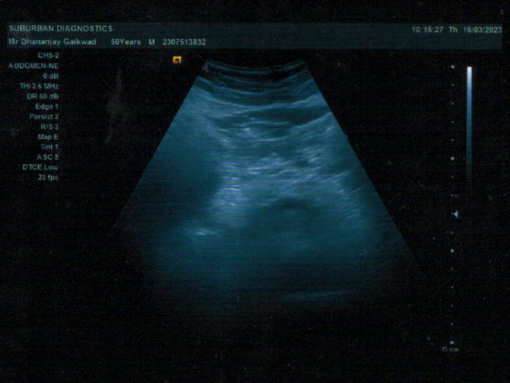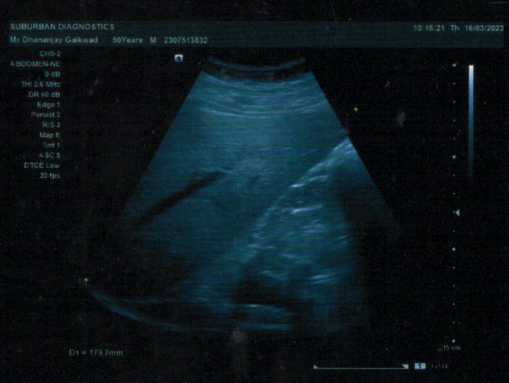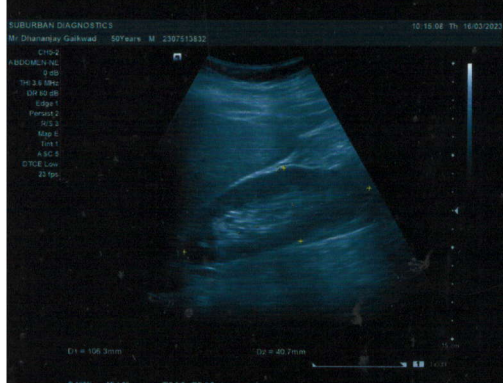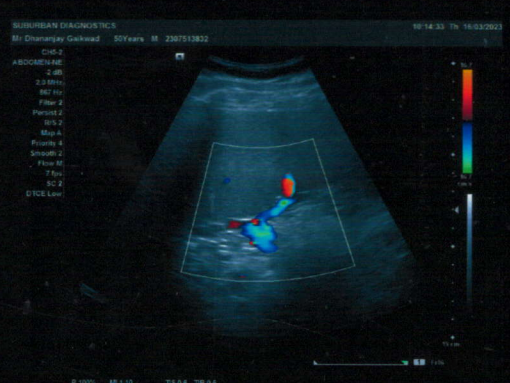
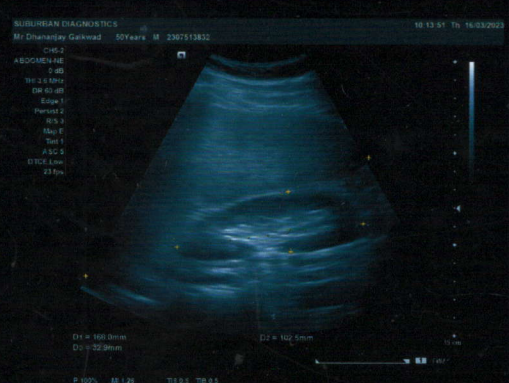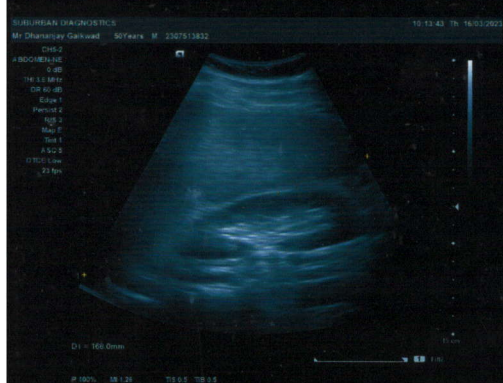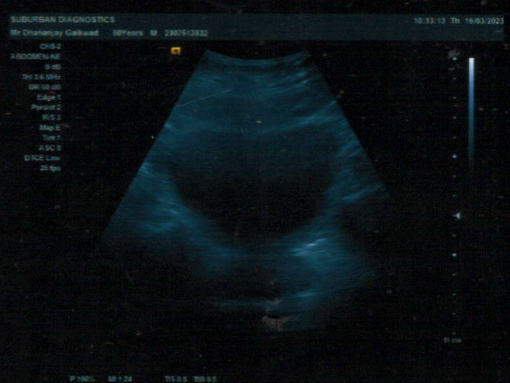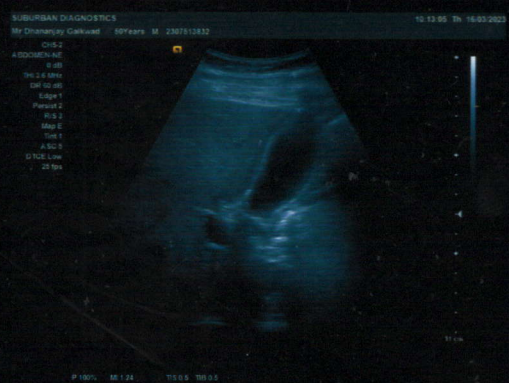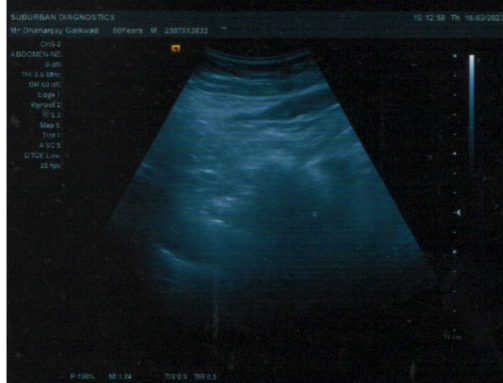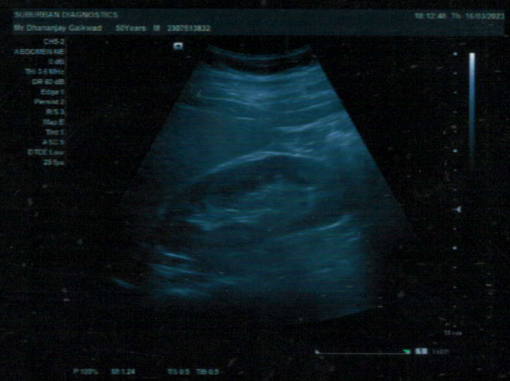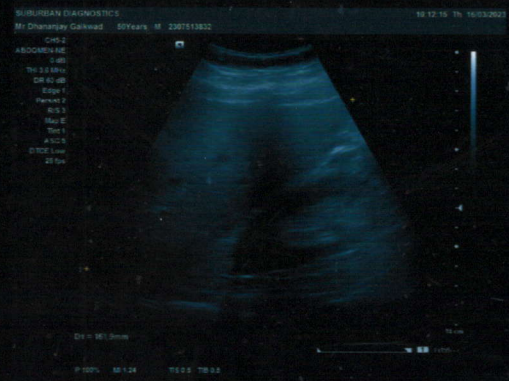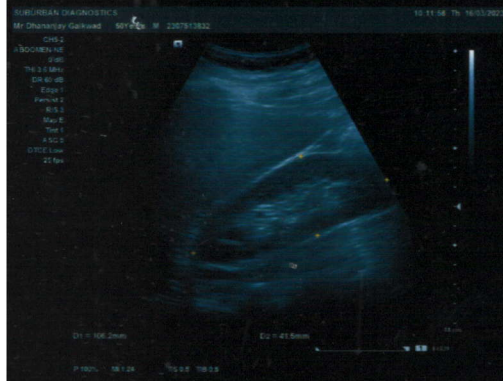16 Mar 2023 Study : Cardiac



# SUBURBAN DIAGNOSTIC CENTRE

Name : Mr Dhananjay Gaikwad 050Y / M

16 Mar 2023 Study : EM



Dhananjay Gaikwad  
50/M

20

16.3.23

PHY2.

**History and Complaints:**

Hereditary spherocytosis.

**EXAMINATION FINDINGS:**

Height (cms):	171	Weight (kg):	82	BMI
Temp (0c):	Afebrile	Skin:	Normal	] <u>MSD</u>
Blood Pressure (mm/hg):	120/80	Nails:	Healthy	
Pulse:	84	Lymph Node:	Not Palpable	

**Systems**

Cardiovascular: S1,S2 Normal No Murmurs

Respiratory: Air Entry Bilaterally Equal

Genitourinary: Normal

GI System: Soft non tender No Organomegaly

CNS: Normal

**IMPRESSION:**

FIT  
↑ Urine Acid, ↓ Calcium  
Splenomegaly / Hepatomegaly; GB stone.

**ADVICE:**

Annual correlation.

1) T. B Correl, daily, after  
breakfast x 60SS


**CHIEF COMPLAINTS:**

1)	Hypertension:	] <u>NIL</u>
2)	IHD:	
3)	Arrhythmia:	
4)	Diabetes Mellitus :	
5)	Tuberculosis :	
6)	Asthama:	
7)	Pulmonary Disease :	
8)	Thyroid/ Endocrine disorders :	

9)	Nervous disorders :	
10)	GI system :	
11)	Genital urinary disorder :	
12)	Rheumatic joint diseases or symptoms :	
13)	Blood disease or disorder :	
14)	Cancer/lump growth/cyst :	
15)	Congenital disease :	
16)	Surgeries :	

**PERSONAL HISTORY:**

1)	Alcohol	regularly x 15 years	
2)	Smoking		No.
3)	Diet		Mixed
4)	Medication		Nil.



Dr. KRUTIKA INGLE  
 MBBS, D.DM, PG in Diabetology (USA)  
 MMC Regd - 2012 103018

Preventive Health Check-up | Pathology | Digital X-Ray | Sonography | Colour Doppler | Mammography | BMD (DXA Scan) | OPG | Stress Test/TMT | 2D Echo | Spirometry | Eye Examination | Dental Examination | Diet Consultation | Audiometry | OT Sterility | Water Sterility | Clinical Res

Date:- 16.3.23

CID:

Name:- Dhananjay Gaikwad

Sex / Age 50 / M

**EYE CHECK UP**

Chief complaints:

Systemic Diseases:

DM

Past history:

Unaided Vision:

NA

Aided Vision:

Refraction:

Myopia corrected to 6/6

(Right Eye)

(Left Eye)

	Sph	Cyl	Axis	Vn	Sph	Cyl	Axis	Vn
Distance	_____			6/6	_____			6/6
Near	_____			N7	_____			N7

Colour Vision: Normal / Abnormal

Remark:

Nil

*[Signature]*

DR. KRUTIKA INGLE  
MBBS, D.DM, PG in Diabetology (USA)  
MMC Regd - 2012 103018



**DENTAL CHECK - UP**

Name: Dhananj Gaikwad

CID :

Sex / Age 50 / M

Occupation:-

Date: 16 / 3 / 23

Chief complaints:-

Medical / dental history:-

gail

**GENERAL EXAMINATION:**

**1) Extra Oral Examination:**

- a) TMJ:
- b) Facial Symmetry:

**2) Intra Oral Examination:**

- a) Soft Tissue Examination:
- b) Hard Tissue Examination:
- c) Calculus:

Stains:

gail

18	17	16	15	14	13	12	11	21	22	23	24	25	26	27	28
48	47	46	45	44	43	42	41	31	32	33	34	35	36	37	38

<input type="checkbox"/>	Missing	#	Fractured
<input type="checkbox"/>	Filled/Restored	RCT	Root Canal Treatment
<input type="checkbox"/>	Cavity/Caries	RP	Root Piece

Advised:

NIL

Provisional Diagnosis:-

*[Signature]*

**Dr. KRUTIKA INGLE**

MBBS, D.DM, PG in Diabetology (USA)  
MMC Regd - 2012 103018

Physician 2) Patient visits are as entered by the clinician and not derived from the ICD.

**2D ECHO / COLOUR DOPPLER**

NAME : MR DHANAJAY GAIKWAD      Age: 50/Y MALE  
REF BY: CORP                              DATE : 16.03.2023  
CID NO: 2307513832                      REG LOC: PIMPLE SAUDAGAR PUNE

**M - Mode values**

**Doppler Values**


AORTIC ROOT (mm)	28	PULMONARY VEL (m/sec)	0.9
LEFT ATRIUM (mm)	34	PG (mmHg)	3
RV (mm)	28	AORTIC VALVE M/SEC	0.9
IVS - D (mm)	11	PG (mmHg)	4
LVID - D (mm)	48	MITRAL E VEL (m/sec)	0.9
LVID - S (mm)	24	A VEL (m/ sec)	0.7
LVPW - D (mm)	11	TRICUSPID VEL. (m/sec)	1.9
EJECTION FRACTION (%)	60	PG (mmHg)	15

**OBSERVATION:**

All four cardiac valves are structurally normal.  
All four cardiac chambers normal in dimensions.  
Normal left ventricle size with Good ventricle systolic function .(LVEF-65%)  
No Regional wall motion abnormality.  
Left atrium, Right atrium & Right ventricle are normal in size.  
No pulmonary artery hypertension. RVSP = 25 mmHg.  
Interatrial septum & Interventricular septum are intact.  
No clot/vegetation /pericardial effusion.  
Doppler study revealed mild mitral regurgitation , mild tricuspid regurgitation.  
IVC 1.5 cm, more than 50% pulsatile.  
Left sided aortic arch, No coarctation of aorta.  
No diastolic dysfunction.

**CONCLUSION:**

**Normal left ventricle size with Good ventricle systolic function .(LVEF-65%)  
No pulmonary artery hypertension. RVSP = 25 mmHg.**

  
**DR SONAM SHAH  
MD DM CARDIOLOGY  
INTERVENTIONAL CARDIOLOGIST**

**Dr. Sonam Shah  
MBBS MD DM Cardiology  
Interventional Cardiologist  
MMC 2010 / 06 / 2218**



Use a QR Code Scanner  
Application To Scan the Code

CID : 2307513832  
Name : Mr Dhananjay Gaikwad  
Age / Sex : 50 Years/Male  
Ref. Dr :  
Reg. Location : Pimple Saudagar, Pune Main Centre  
Reg. Date : 16-Mar-2023  
Reported : 16-Mar-2023 / 10:08

**ULTRASOUND ABDOMEN AND PELVIS**

**Liver-** Enlarged in size (17.3cm) with normal shape and raised echo pattern. No focal lesion. Intrahepatic biliary and portal radicals appear normal. Visualized portion of CBD appears normal in calibre. Portal vein appears normal.

**Gall bladder-** partially distended with normal wall thickness. GB sludge seen in dependent GB neck. Echoreflexive calculi not seen. No mass lesion is visualized. No pericholecystic collection.

**Pancreas-** Head and body are visualized and appear normal in size, shape and echo pattern. No focal lesion seen. No peripancreatic collection noted.

**Spleen** – enlarged in size (16.8cm), shape & echo pattern. No focal lesion seen.

**Kidneys-** Right kidney -10.6 x 4.0 cm, Left kidney -10.2 x 3.3cm, both kidneys appear normal in size, shape, position & echo pattern with maintained corticomedullary differentiation. No hydronephrosis, hydroureter or calculus noted.

**Urinary bladder-** Is well distended & shows normal wall thickness. No calculus or mass lesion is noted.

**Prostate** - appears normal (Vol- 17.8cc) in size, shape and echo-pattern for age. No focal lesion .

No free fluid in abdomen and pelvis. Visualized bowel loops are well distended appear grossly normal and show normal peristalsis. No evidence of enlarged lymph nodes.

**IMPRESSION:**

- Mild hepatomegaly with grade I fatty liver.
- Splenomegaly.
- GB sludge seen in dependent GB neck.

*Advice – Clinical correlation and further evaluation if clinically indicated.*

-----End of Report-----

*Divya*

**Dr. Divya Chaudhary**  
MBBS, M.D. RADIODIAGNOSIS,  
DNB, RADIOLOGIST  
MMC Reg - 2016/01/0064





Use a QR Code Scanner  
Application To Scan the Code

CID : 2307513832  
Name : Mr Dhananjay Gaikwad  
Age / Sex : 50 Years/Male  
Ref. Dr :  
Reg. Location : Pimple Saudagar, Pune Main Centre  
Reg. Date : 16-Mar-2023  
Reported : 16-Mar-2023 / 10:41

**X-RAY CHEST PA VIEW**

Trachea is central.  
Slightly prominent bronchovascular markings are noted bilaterally.  
Visualized bilateral lung fields otherwise appear grossly normal.  
Both hila appear normal.  
Cardiac silhouette has grossly normal appearance for age.  
Bilateral costophrenic and cardiophrenic angles appear grossly normal.  
Visualized bony thorax and soft-tissues are grossly normal for age.

**IMPRESSION :**

- Normal CXR.

*Advice - Clinical correlation and further evaluation if clinically indicated.*

-----End of Report-----

*Divya*

Dr. Divya Chaudhary  
MBBS, M.D. RADIODIAGNOSIS,  
DNB, RADIOLOGIST  
MMC Reg - 2016/01/0064

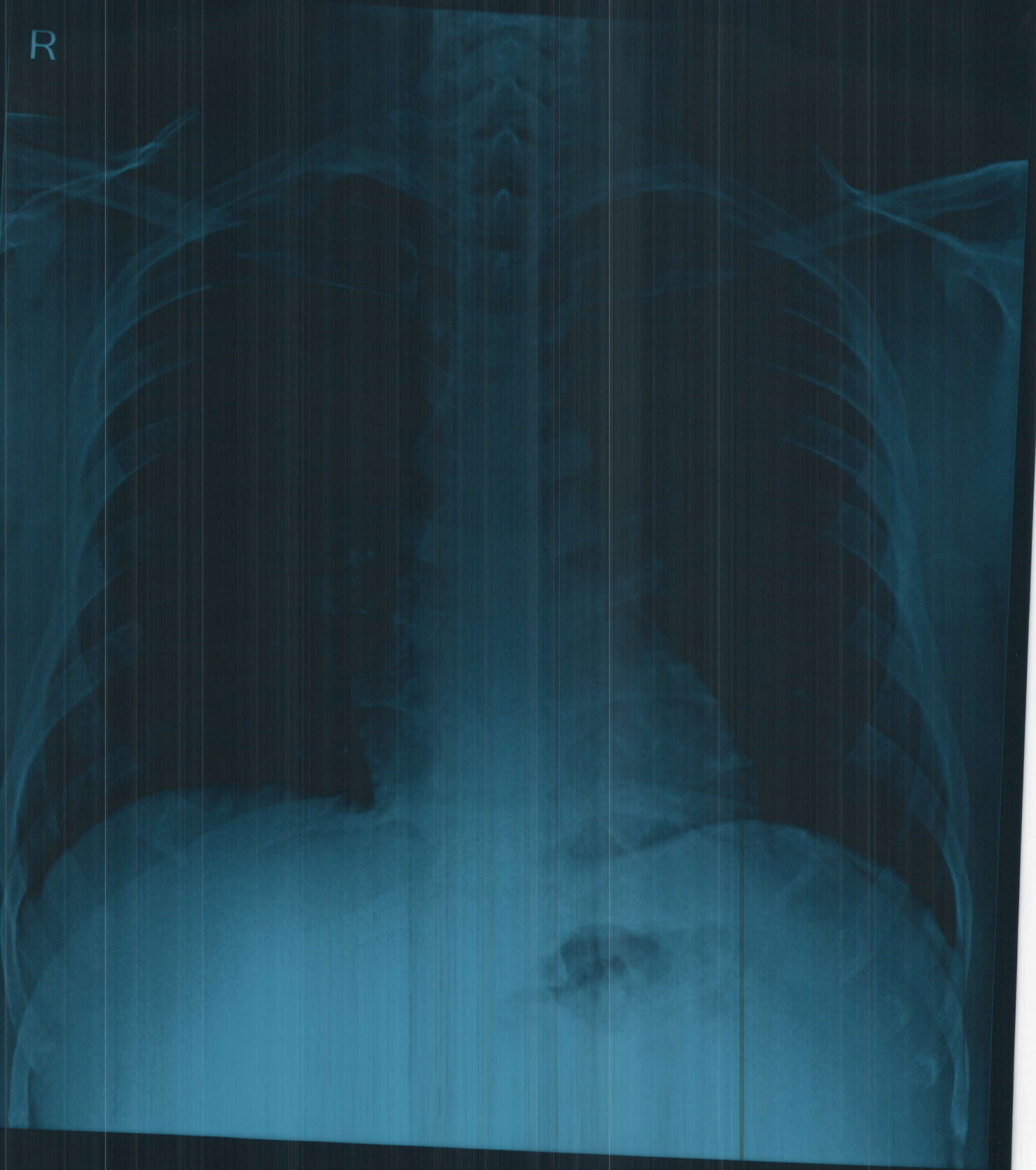
Click here to view images <http://3.111.232.119/iRISViewer/NeoradViewer?AccessionNo=2023031608291395>  
LAB ADDRESS: Seraph Centre, Opp. BSNL Exchange, Shahu College Road, Off Pune-Satara Road, Behind Panchami Hotel, Pune - 411009

CENTRAL PROCESSING LAB: 2<sup>nd</sup> Floor, Aston, Sundervan Complex, Above Mercedes Showroom, Andheri West, Mumbai Page 03 1 of 1

HEALTHLINE - MUMBAI: 022-6170-0000 | OTHER CITIES: 1800-266-4343 | For Feedback - customerservice@suburbandiagnosics.com | www.suburbandiagnosics.com

**Brief Disclaimer:** (1)Suburban Diagnostics ensures that the tests are conducted with utmost care and safety and are performed on samples received as per the sample collection guide of Suburban Diagnostics.(2)Sample may be rejected if unacceptable for the requested tests. (3)Test results may vary from laboratory to laboratory and also in some parameters from time to time for the same patient.(4)Report must not be copied in part, only in full. (5)This report is not valid for medico-legal purposes.(6)Patient information or data will not be communicated to a third party except in the case of a notifiable disease to a Public Care Unit.(7)Suburban Diagnostics reserves the right to subcontract samples to other

R



Mr Dhananjay Gaikwad M 050Y 2307513832 CHEST PA 3/16/2023  
SUBURBAN DIAGNOSTICS PIMPLE SAUDAGAR