

Patient Name : Mr.KISHORE KOLLI RAMA	Collected : 09/Nov/2024 10:23AM
Age/Gender : 35 Y 4 M 10 D/M	Received : 09/Nov/2024 12:42PM
UHID/MR No : CKOR.0000259388	Reported : 09/Nov/2024 01:37PM
Visit ID : CKOROPV431235	Status : Final Report
Ref Doctor : Self	Sponsor Name : ARCOFEMI HEALTHCARE LIMITED
Emp/Auth/TPA ID : 22E32503	

DEPARTMENT OF IMMUNOLOGY

ARCOFEMI - MEDIWHEEL - FULL BODY ANNUAL PLUS MALE - 2D ECHO - PAN INDIA - FY2324

Test Name	Result	Unit	Bio. Ref. Interval	Method
THYROID PROFILE TOTAL (T3, T4, TSH) , SERUM				
TRI-IODOTHYRONINE (T3, TOTAL)	1.96	ng/mL	0.7-2.04	CLIA
THYROXINE (T4, TOTAL)	9.46	µg/dL	5.48-14.28	CLIA
THYROID STIMULATING HORMONE (TSH)	3.421	µIU/mL	0.34-5.60	CLIA

Comment:

For pregnant females	Bio Ref Range for TSH in uIU/ml (As per American Thyroid Association)
First trimester	0.1 - 2.5
Second trimester	0.2 – 3.0
Third trimester	0.3 – 3.0

1. TSH is a glycoprotein hormone secreted by the anterior pituitary. TSH activates production of T3 (Triiodothyronine) and its prohormone T4 (Thyroxine). Increased blood level of T3 and T4 inhibit production of TSH.
2. TSH is elevated in primary hypothyroidism and will be low in primary hyperthyroidism. Elevated or low TSH in the context of normal free thyroxine is often referred to as sub-clinical hypo- or hyperthyroidism respectively.
3. Both T4 & T3 provides limited clinical information as both are highly bound to proteins in circulation and reflects mostly inactive hormone. Only a very small fraction of circulating hormone is free and biologically active.
4. Significant variations in TSH can occur with circadian rhythm, hormonal status, stress, sleep deprivation, medication & circulating antibodies.

TSH	T3	T4	FT4	Conditions
High	Low	Low	Low	Primary Hypothyroidism, Post Thyroidectomy, Chronic Autoimmune Thyroiditis
High	N	N	N	Subclinical Hypothyroidism, Autoimmune Thyroiditis, Insufficient Hormone Treatment.
N/Low	Low	Low	Low	Secondary and Tertiary Hypothyroidism
Low	High	High	High	Primary Hyperthyroidism, Goitre, Thyroiditis, Drug effects, Early Pregnancy
Low	N	N	N	Subclinical Hyperthyroidism
Low	Low	Low	Low	Central Hypothyroidism, Treatment with Hyperthyroidism
Low	N	High	High	Thyroiditis, Interfering Antibodies
N/Low	High	N	N	T3 Thyrotoxicosis, Non thyroidal causes

Dr.Govinda Raju N L
 MSc,PhD(Biochemistry)
 Consultant Biochemistry

Dr Priya Murthy
 M.B.B.S,M.D(Pathology)
 Consultant Pathologist



SIN No.KOR241100558

This test has been performed at Apollo Health & Lifestyle Ltd, RRL BANGALORE Laboratory.

Regd. Office: 10, 82nd, Anand Nagar, Bangalore 560094, Karnataka, India. Regd. Office: 10, 82nd, Anand Nagar, Bangalore 560094, Karnataka, India. Regd. Office: 10, 82nd, Anand Nagar, Bangalore 560094, Karnataka, India.

www.apolloclinics.com

Patient Name : Mr.KISHORE KOLLI RAMA	Collected : 09/Nov/2024 10:23AM
Age/Gender : 35 Y 4 M 10 D/M	Received : 09/Nov/2024 01:49PM
UHID/MR No : CKOR.0000259388	Reported : 09/Nov/2024 02:18PM
Visit ID : CKOROPV431235	Status : Final Report
Ref Doctor : Self	Sponsor Name : ARCOFEMI HEALTHCARE LIMITED
Emp/Auth/TPA ID : 22E32503	

DEPARTMENT OF CLINICAL PATHOLOGY

ARCOFEMI - MEDIWHEEL - FULL BODY ANNUAL PLUS MALE - 2D ECHO - PAN INDIA - FY2324

Test Name	Result	Unit	Bio. Ref. Interval	Method
COMPLETE URINE EXAMINATION (CUE) , URINE				
PHYSICAL EXAMINATION				
COLOUR	YELLOW		PALE YELLOW	Visual
TRANSPARENCY	CLEAR		CLEAR	Physical Measurement
pH	6.5		5-7.5	Double Indicator
SP. GRAVITY	1.005		1.002-1.030	Bromothymol Blue
BIOCHEMICAL EXAMINATION				
URINE PROTEIN	NEGATIVE		NEGATIVE	Protein Error Of Indicator
GLUCOSE	NEGATIVE		NEGATIVE	Glucose Oxidase
URINE BILIRUBIN	NEGATIVE		NEGATIVE	Azo Coupling Reaction
URINE KETONES (RANDOM)	NEGATIVE		NEGATIVE	Sodium Nitro Prusside
UROBILINOGEN	NORMAL		NORMAL	Modified Ehrlich Reaction
NITRITE	NEGATIVE		NEGATIVE	Diazotization
LEUCOCYTE ESTERASE	NEGATIVE		NEGATIVE	Leucocyte Esterase
CENTRIFUGED SEDIMENT WET MOUNT AND MICROSCOPY				
PUS CELLS	2-3	/hpf	0-5	Microscopy
EPITHELIAL CELLS	1-2	/hpf	<10	Microscopy
RBC	NIL	/hpf	0-2	Microscopy
CASTS	NIL		0-2 Hyaline Cast	Microscopy
CRYSTALS	ABSENT		ABSENT	Microscopy

Comment:

All urine samples are checked for adequacy and suitability before examination. All abnormal chemical examination are rechecked and verified by manual methods. Microscopy findings are reported as an average of 10 high power fields.

Dr. Rajalakshmi D
 M.B.B.S,M.D
 Consultant Pathologist

Dr. Vidya Aniket Gore
 M.B.B.S,M.D(Pathology)
 Consultant Pathologist



Patient Name	: Mr. KISHORE KOLLI RAMA	Age	: 35Yrs 4Mths 11Days
UHID	: CKOR.0000259388	OP Visit No.	: CKOROPV431235
Printed On	: 09-11-2024 06:03 AM	Advised/Pres Doctor	: --
Department	: Radiology	Qualification	: --
Referred By	: Self	Registration No.	: --
Employer Id	: 22E32503		

DEPARTMENT OF RADIOLOGY

ULTRASOUND ABDOMEN AND PELVIS

FINDINGS:

Liver is normal in size and shows a normal echotexture. No biliary dilatation. No focal lesion

CBD is not dilated.

Portal vein is normal in size, course and calibre.

Gall bladder 3 mm sessile polyp seen.

Pancreas to the extent visualized, appears normal in size, contour and echogenicity

Spleen is normal in size, shape, contour and echopattern. No evidence of mass or focal lesions.

Right Kidney is normal in size, position, shape and echopattern. Corticomedullary differentiation is maintained. 5 mm calculus seen, no hydronephrosis.

Left Kidney is normal in size, position, shape and echopattern. Corticomedullary differentiation is maintained. No evidence of calculi or hydronephrosis.

Retroperitoneum – Obscured by bowel gas. No significant lymphadenopathy.

Urinary Bladder well distended. wall thickness is normal. No evidence of calculi, mass or mural lesion.

Prostate: normal in size and echotexture.

There is no ascites.

IMPRESSION:

**NON OBSTRUCTIVE RIGHT RENAL CALCULUS
GALL BLADDER POLYP**

---End Of The Report---



Dr.VINOD P JOSEPH
MBBS, DNB, DMRD
25487
Radiology

Patient Name	: Mr. KISHORE KOLLI RAMA	Age	: 35Yrs 4Mths 11Days
UHID	: CKOR.0000259388	OP Visit No.	: CKOROPV431235
Printed On	: 09-11-2024 08:01 AM	Advised/Pres Doctor	: --
Department	: Radiology	Qualification	: --
Referred By	: Self	Registration No.	: --
Employer Id	: 22E32503		

DEPARTMENT OF RADIOLOGY

X RAY CHEST PA

Both lungs fields appear normal.

Both hilae are normal.

Both costophrenic and cardiophrenic angles are normal.

The cardiac and mediastinal shadows appear normal.

Bones and soft tissues appear normal.

IMPRESSION : NORMAL STUDY.

---End Of The Report---



Dr.VINOD P JOSEPH
MBBS, DNB, DMRD
25487
Radiology

Patient Name	: Mr. KISHORE KOLLI RAMA	Age	: 35Yrs 4Mths 14Days
UHID	: CKOR.0000259388	OP Visit No.	: CKOROPV431235
Printed On	: 12-11-2024 07:13 AM	Advised/Pres Doctor	: --
Department	: Cardiology	Qualification	: --
Referred By	: Self	Registration No.	: --
Employer Id	: 22E32503		

DEPARTMENT OF CARDIOLOGY

ECHO

---End Of The Report---



Dr.MOHAN MURALI
MBBS, DNB General Medicine, DrNB Cardiology
ANP2013000191IKTK
Cardiology

Patient Name	: Mr. KISHORE KOLLI RAMA	Age	: 35Yrs 4Mths 11Days
UHID	: CKOR.0000259388	OP Visit No.	: CKOROPV431235
Printed On	: 09-11-2024 06:16 AM	Advised/Pres Doctor	: --
Department	: Cardiology	Qualification	: --
Referred By	: Self	Registration No.	: --
Employer Id	: 22E32503		

DEPARTMENT OF CARDIOLOGY

Observation :-

1. Normal Sinus Rhythm.
2. Heart rate is 82 beats per minutes.
3. No pathological Q wave or ST-T changes seen.
4. Normal P,Q,R,S,T waves and axis.
5. No evidence of chamber, hypertrophy or enlargement seen.

Impression:

NORMAL RESTING ECG.

NOTE:KINDLY TAKE A PHOTOCOPY OF THE GRAPH FOR FUTURE REFERENCE IF NEEDED

---End Of The Report---



Dr.MOHAN MURALI
MBBS, DNB General Medicine, DrNB Cardiology
ANP20130001911KTK
Cardiology



Apollo Clinic

Consent Form

Patient Name: K. RAMA KISHORE Age: 35 Y

UHID Number: Company Name:

I Mr/Mrs/Miss: K. Rama Kishore Employee of Bank of Baroda

(Company) want to inform you that I am ~~not~~ getting the Consultation

Test which is a part of health check package.

Reason If any: I will be coming on wednesday

And I claim the above statement in my full consciousness.

Patient Signature:  Date: 09/11/2024



Patient Name : Mr Kishore K R

Patient ID:259388

Age : 35Year(s)

Sex: Male

Referring Doctor : H/C

Date:09.11.2024

ULTRASOUND ABDOMEN AND PELVIS

FINDINGS:

Liver is normal in size and shows a normal echotexture. No biliary dilatation. No focal lesion

CBD is not dilated.

Portal vein is normal in size, course and calibre.

Gall bladder 3 mm sessile polyp seen.

Pancreas to the extent visualized, appears normal in size, contour and echogenicity

Spleen is normal in size, shape, contour and echopattern. No evidence of mass or focal lesions.

Right Kidney is normal in size, position, shape and echopattern. Corticomedullary differentiation is maintained. 5 mm calculus seen. no hydronephrosis.

Left Kidney is normal in size, position, shape and echopattern. Corticomedullary differentiation is maintained. No evidence of calculi or hydronephrosis.

Retroperitoneum – Obscured by bowel gas. No significant lymphadenopathy.

Urinary Bladder well distended. wall thickness is normal. No evidence of calculi, mass or mural lesion.

Prostate: normal in size and echotexture.

There is no ascites.

IMPRESSION:

**NON OBSTRUCTIVE RIGHT RENAL CALCULUS
GALL BLADDER POLYP**

**DR VINOD JOSEPH DNB,DMRD
RADIOLOGIST**



DR. SHURTI CHAND KEDIA
 MBBS, MS (ENT)
 KMC REG NO: J19251



Apollo Medical Centre
 Expertise. Closer to you.

9/11/24

HEALTH CHECK - ENT

NAME: *Kishore Kumar Rama*

AGE:

EAR:

RE:

LE:

EXTERNAL EAR

MIDDLE EAR

INNER EAR (FN)

Normal

HEARING ASSESSMENT:

RE:

LE:

RHINNE

WEBER

ABC

Normal

NOSE

THROAT

AIRWAY

ORAL CAVITY

SEPTUM

OROPHARYNX

TURBINATES

PHARYNX

OTHERS

LARYNX

Normal

Normal

NECK

NECK NODES

OTHER

Normal

AUDIOMETRY

IMPRESSION

Normal

[Signature]
SIGNATURE

Apollo Health and Lifestyle Limited

(CIN - U85110TG2000PLC046089) Regd. Office: #7-1-617/A, 615 & 616, Imperial Towers, 7th Floor; Ameerpet, Hyderabad, Telangana - 500 038 | Email ID: enquiry@apollohl.com

APOLLO CLINICS NETWORK KARNATAKA

Bangalore (Basavanagudi | Bellandur | Electronics City | HSR Layout | Indira Nagar | JP Nagar | Kundalahalli | Koramangala | Sarjapur Road) **Mysore** (Kallidasa Road)

Online appointments: www.apolloclinic.com

TO BOOK AN APPOINTMENT

1860 500 7788

OPHTHAL REPORT

NAME: Mr. Kishore Kolli Rama
AGE: 35... GENDER: MALE/FEMALE

RIGHT EYE

	SPH	CYL	AXIS	VA
DV	<u>0</u>			<u>6/6</u>
NV				<u>NS</u>

LEFT EYE

	SPH	CYL	AXIS	VA
DV	<u>0</u>			<u>6/6</u>
NV				<u>NS</u>

REMARK:

Colour Vn: Normal.

DATE: 09.11.2024


OPTOMETRIST

BRING THIS PRESCRIPTION IN YOUR NEXT VISIT

NAME: Mr. KISHORE KOLLI RAMA

AGE: 35Y

SEX: MALE

DATE: 09/11/2024

ECHOCARDIOGRAPHY REPORT

MEASUREMENT

AO - 25 (20 - 35) mm	LIVD d 40 (36-52) mm	IVS - 10 (06 - 11) mm
LA - 28 (19- 40) mm	LVID s 28 (23- 39) mm	PWD - 10 (06- 11) mm
EF - 60 (> 50%)	RVID-20	

VALVES

Mitral Valve : NORMAL
Aortic Valve : NORMAL
Tricuspid Valve : Normal,
Pulmonary Valve : Normal,

CHAMBERS

Left Atrium : Normal
Right Atrium : Normal
Left Ventricle : Normal
Right Ventricle : Normal

SEPTAE

IVS : Intact
IAS : Intact



GREAT ARTERIES

Aorta : Normal
Pulmonary Artery : Normal

DOPPLER DATA

Mitral : E > A , 0.8 / 0.5
Aortic : Normal , 1.0 m/s
Tricuspid : Normal , 0.4 / 0.6
Pulmonary : Normal, 1.10

WALL MOTION ABNORMALITIES : No RWMA

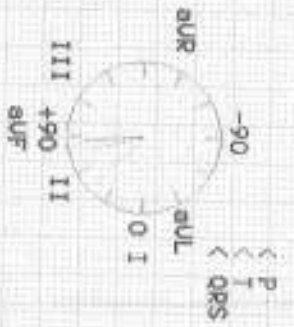
Pericardium : Normal

FINAL DIAGNOSIS

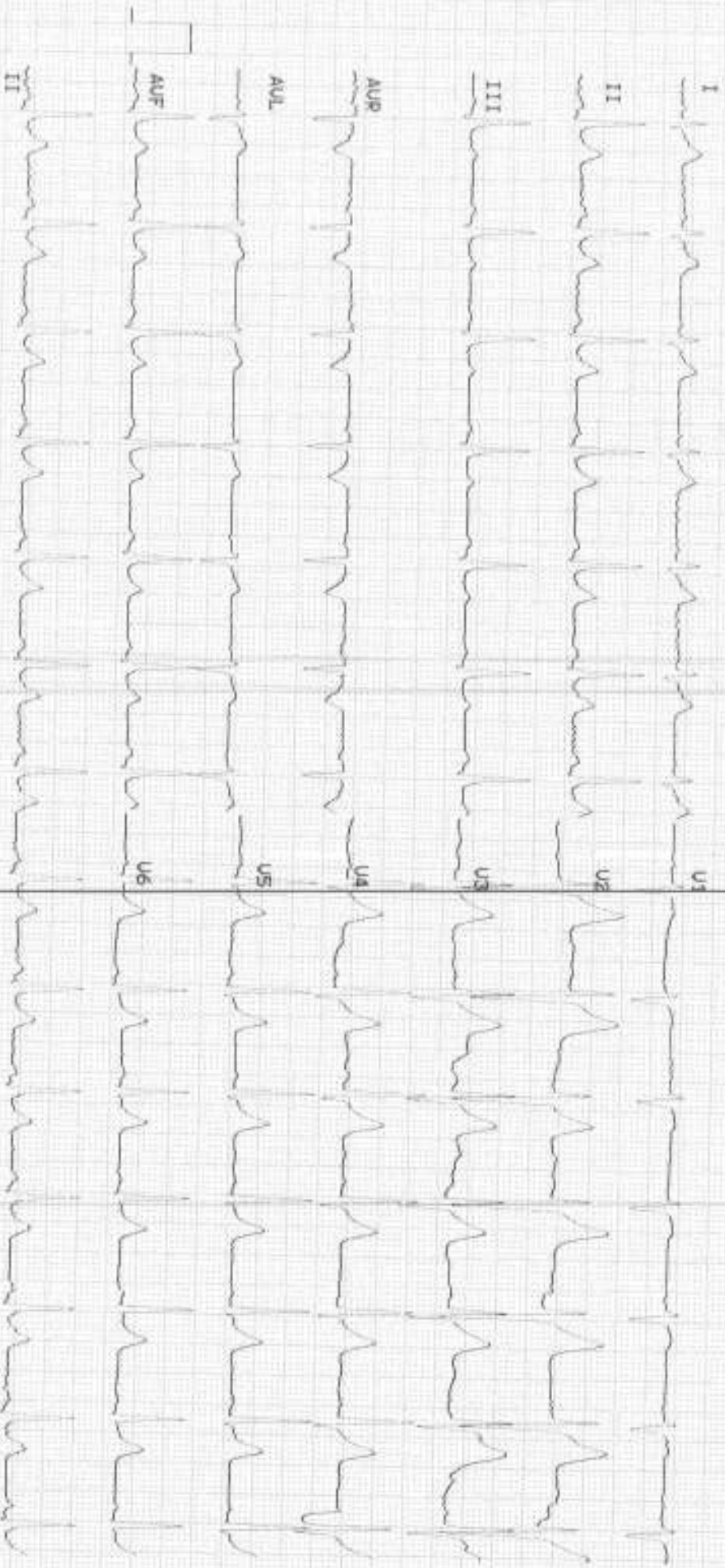**NORMAL CHAMBERS AND DIMENSION
NO RWMA AT REST, NORMAL LV EF - 60%
NORMAL DIASTOLIC FUNCTION
NO OBVIOUS CLOTS/ EFFUSION/ VEGETATION**


**DR. MOHAN MURALI
DNB(MED), DrNB(CARDIOLOGY)
CONSULTANT CARDIOLOGIST**

AGE: 35
 Measurement Results:
 QRS : 106 ms
 QT/QTcB : 346 / 406 ms
 PR : 134 ms
 P : 104 ms
 RR/pp : 726 / 735 ms
 P/ORS/T : 75 / 85 / 45 degrees
 QTd/QTcBd : 38 / 45 ms
 Sokolow : 1.9 mV
 NK : 12



Interpretation:



Unconfirmed report.

[Handwritten Signature]

Patient Name	: Mr. KISHORE KOLLI RAMA	Age	: 35Yrs 4Mths 10Days
UHID	: CKOR.0000259388	OP Visit No.	: CKOROPV431235
Printed On	: 09-11-2024 11:46 AM	Advised/Pres Doctor	: --
Department	: Cardiology	Qualification	: --
Referred By	: Self	Registration No.	: --
Employer Id	: 22E32503		

DEPARTMENT OF CARDIOLOGY

Observation :-

1. Normal Sinus Rhythm.
2. Heart rate is 82 beats per minutes.
3. No pathological Q wave or ST-T changes seen.
4. Normal P,Q,R,S,T waves and axis.
5. No evidence of chamber, hypertrophy or enlargement seen.

Impression:

NORMAL RESTING ECG.

NOTE:KINDLY TAKE A PHOTOCOPY OF THE GRAPH FOR FUTURE REFERENCE IF NEEDED

---End Of The Report---



Dr.MOHAN MURALI
MBBS, DNB General Medicine, DrNB Cardiology
ANP20130001911KTK
Cardiology



Apollo Medical
Centre

Patient Name : Mr. KISHORE KOLLI RAMA • Age : 35Yrs 4Mths 10Days *Expertise. Closer to you*
UHID : CKOR.0000259388 OP Visit No. : CKOROPV431235
Printed On : 09-11-2024 01:31 PM Advised/Pres Doctor :
Department : Radiology Qualification :
Referred By : Self Registration No. :
Employer Id : 22E32503

DEPARTMENT OF RADIOLOGY

X RAY CHEST PA

Both lungs fields appear normal.

Both hilae are normal.

Both costophrenic and cardiophrenic angles are normal.

The cardiac and mediastinal shadows appear normal.

Bones and soft tissues appear normal.

IMPRESSION : NORMAL STUDY.

---End Of The Report---

PJ Vinod

Dr.VINOD P JOSEPH
MBBS, DNB, DMRD
25487
Radiology

Apollo Health and Lifestyle Limited

(CIN - U85110TG2000PLC046089) Regd. Office: #7-1-617/A, 615 & 616, Imperial Towers, 7th Floor, Ameerpet, Hyderabad, Telangana 500 038 | Email ID: enquiry@apollohospitals.com

APOLLO CLINICS NETWORK KARNATAKA

Bangalore (Basavanagudi | Bellandur | Electronics City | HSR Layout | Indira Nagar | JP Nagar | Kundalahalli | Koramangala | Sarjapur Road) **Mysore** (Kallidasa Road)

Online appointments: www.apollohospitals.com

TO BOOK AN APPOINTMENT

1860 500 7788

Outlook

Fw: Health Check up Booking Confirmed Request(22E32503),Package Code-PKG10000366, Beneficiary Code-300059

From KOLLI RAMA KISHORE <KOLLI.KISHORE@bankofbaroda.com>
Date Sat 09-11-2024 09:53

To Koramangala Apolloclinic <koramangala@apolloclinic.com>

Get Outlook for Android

From: Mediwheel <wellness@mediwheel.in>

Sent: Thursday, November 7, 2024 3:36:32 PM

To: KOLLI RAMA KISHORE <KOLLI.KISHORE@bankofbaroda.com>

Cc: customercare@mediwheel.in <customercare@mediwheel.in>

Subject: Health Check up Booking Confirmed Request(22E32503),Package Code-PKG10000366, Beneficiary Code-300059

Hi लिंक पर क्लिक ना करें या अटैचमेंट ना खोलें.

NOT CLICK ON LINKS OR OPEN ATTACHMENTS UNLESS YOU KNOW THE SENDER.

011-41195959

Dear K Rama Kishore ,

We are pleased to confirm your health checkup booking request with the following details.

Hospital Package Name : Mediwheel Full Body Annual Plus

Name of Diagnostic/Hospital : Apollo Medical Centre - Koramangala

Address of Diagnostic/Hospital : Apollo Medical centre, Plot 51, 5th Block, Opp. Jyothi Nivas College, Koramangala - 560095

City : Bangalore

State : Karnataka

Pincode : 560095

Appointment Date : 09-11-2024

Confirmation Status : Booking Confirmed

Preferred Time : 08:00 AM - 08:30 AM

Booking Status : Booking Confirmed

Member Information		
Booked Member Name	Age	Gender
MR. KISHORE KOLLI RAMA	35 year	Male

Note - Please note to not



बैंक ऑफ बरोडा
Bank of Baroda

नाम
Name के राम किशोर
Kishore Koli Rana

E.C. No. 167082




जारीकर्ता प्राधिकारी
Issuing Authority


धारक के हस्ताक्षर
Signature of Holder