



✓ mediwheel


L
Promita Sen


DR. HARI CHHABLANI
M.B.B.S., D. (RESP. MEDICINE) PGDH-M, PGDMLS
FELLOW INTENSIVE CARE
MMC REG. NO. - 91702

**'DR. PLUS HEALTHCARE CENTRE'
NATHANI HEIGHTS', B-WING,
42, MUMBAI CENTRAL (EAST)**


भारत सरकार
GOVERNMENT OF INDIA


प्रोमिता सेन
Promita Sen
जन्म तिथि / DOB: 30/09/1989
महिना / FEMALE
Mobile No.: 8130740986
7496 7637 2434
VID : 9155 7649 0734 0071



मेरा आधार, मेरी पहचान

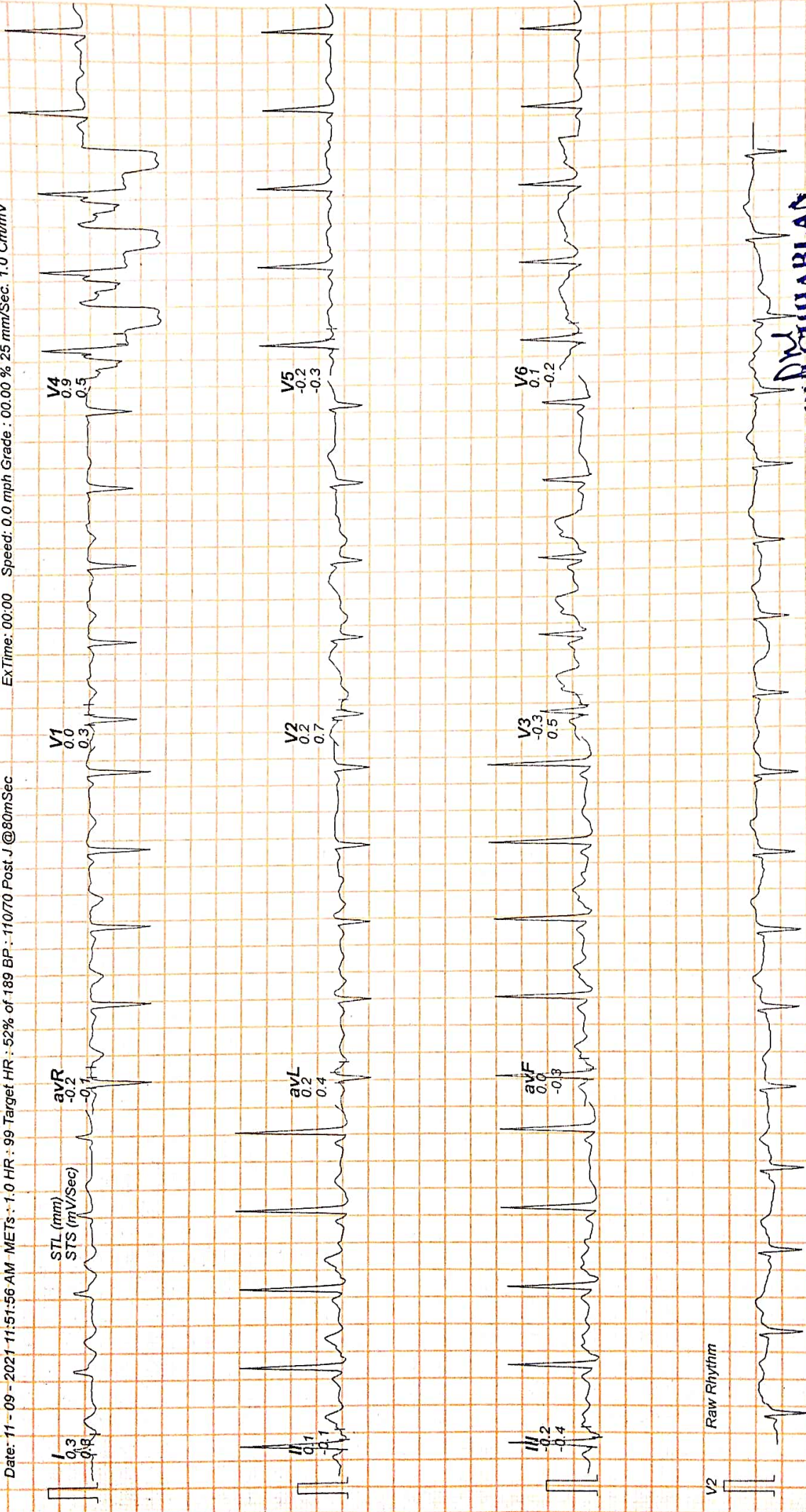
"DR- PLUS HEALTHCARE CENTRE"

MUMBAI CENTRAL
15078 / PROMITA SEN / 31-Yrs / Female / 0 Cm / 0 Kg

Linked Medians Report
BRUCE:Supine(0:28)



Date: 11 - 09 - 2021 11:51:56 AM METs : 1.0 HR : 99 Target HR : 52% of 189 BP : 110/70 Post J @80mSec
ExTime: 00:00 Speed: 0.0 mph Grade : 00.00 % 25 mm/Sec. 1.0 Cm/mV



STL (mm)
STS (mV/Sec)

I
0.3
0.0
0.3

aVR
-0.2
-0.1

aVL
0.2
0.4

V1
0.0
0.3

V2
0.2
0.7

II
-0.2
-0.4

aVF
0.0
-0.3

V3
-0.3
0.5

V4
0.9
0.5

V5
-0.2
-0.3

V6
0.1
-0.2

V2 Raw Rhythm

WNL

DR. PURVI CHABLAN
MBBS, DNB, (Medicine)
Consultant Physician Anesthesiology
Reg No 7769f

**"DR- PLUS HEALTHCARE CENTRE"
MUMBAI CENTRAL**



Report

15078 / PROMITA SEN / 31 Yrs / F / 0 Cms / 0 Kg Date: 11-Sep-2021 Refd By : DR.PURVI CHHABLANI Examined By: DR. HARI CHHABLANI

Stage	Time	Duration	Speed(mph)	Elevation	METS	Rate	% THR	BP	RPP	PVC	Comments
Supine	00:28	0:28	00.0	00.0	01.0	099	52 %	110/70	108	00	
Standing	00:32	0:04	00.0	00.0	01.0	099	52 %	110/70	108	00	
HV	00:36	0:04	00.0	00.0	01.0	097	51 %	110/70	106	00	
Warm Up	01:09	0:33	00.0	00.0	01.0	098	52 %	110/70	107	00	
ExStart	01:20	0:11	01.0	00.0	01.0	101	53 %	110/70	111	00	
BRUCE Stage 1	04:20	3:00	01.7	10.0	04.7	144	76 %	122/70	175	00	
BRUCE Stage 2	07:20	3:00	02.5	12.0	07.1	171	90 %	136/70	232	00	
PeakEx	07:29	0:09	03.4	14.0	07.3	169	89 %	148/70	250	00	
Recovery	08:29	1:00	01.1	00.0	01.2	150	79 %	136/70	204	00	
Recovery	09:12	1:43	00.0	00.0	01.0	145	77 %	122/70	176	00	

FINDINGS :

- Exercise Time : 06:09
- Max HR Attained : 171 bpm 90% of Target 189
- Max BP Attained : 148/70
- Max WorkLoad Attained : 7.3 Fair response to induced stress
- Test End Reasons : Test Complete

M.C.
DR. PURVI CHHABLANI
MBBS DNB (Medicine)
Consultant Physician And Intensivists
Reg No 77696

Doctor : DR.PURVI CHHABLANI

"DR-PLUS HEALTHCARE CENTRE"
MUMBAI CENTRAL

15078 / PROMITA SEN / 31 Yrs / F / 0 Cms / 0 Kg Date: 11-Sep-2021 Refd By : DR.PURVI CHHABLANI

REPORT :

TEST OBJECTIVE : ROUTINE CHECK UP
RISK FACTOR : AGE
ACTIVITY : GOOD
MEDICATION : NIL
BRIEF HISTORY : NIL
OTHER INVESTIGATION : NIL
REASON FOR TERMINATION : TARGET HEART RATE ACHIEVED
EXERCISE TOLERANCE : GOOD
EXERCISE INDUCED ARRHYTHMIAS : INSIGNIFICANT
HAEMODYNAMIC RESPONSE : NORMAL
CHRONOTROPIC RESPONSE : NORMAL
FINAL IMPRESSION : STRESS TEST IS NEGATIVE FOR EXERCISE INDUCED ISCHAEMIC HEART DISEASE

REPORT



DR. PURVI CHHABLANI
MBBS, DNB, (Medicine)
Consultant Physician And Intensivist
Reg No 77696

Doctor : DR.PURVI CHHABLANI



Dr-Plus Healthcare Centre

NATHANI HEIGHTS, B-Wing, Shop No. 42, Ground Floor, Opp. Mumbai Central Station (East), Mumbai - 400 008.

Patient Name	:	PROMITA SEN	Sex:	FEMALE
Doctor's Name	:	DR. HARI CHHABLANI	Age:	31
Date	:	11/09/2021		

ULTRASONOGRAPHY OF THE ABDOMEN AND THE PELVIS:

The relevant sonographic findings include the following:

HEPATOBIILIARY APPARATUS

The liver is normal in size and echogenicity. No obvious focal parenchymal lesion is seen. Intrahepatic biliary radicals are not dilated.

The portal vein and the common bile duct are normal.

GALL BLADDER

The gall bladder is adequately distended. The wall thickness is normal.

No echogenic contents are noted in its lumen. There is no pericholecystic collection noted.

PANCREAS

The pancreas shows normal echogenicity and size.

No focal or diffuse lesions are noted. No evidence of calcification is noted.

SPLEEN

The spleen appears normal in size and echogenicity.

No focal or diffuse lesions are noted. No evidence of calcification is noted.

KIDNEYS

Right kidney measures : 10.5 x 4.2 cm , Left kidney measures : 10.1 x 3.9cm.

Both the kidneys appear normal in size, shape and echogenicity. Both the pelvicalyceal system is normal and

both corticomedullary differentiations are well maintained. There is no obvious focal or diffuse lesion noted.

No evidence of any calculus seen in either kidney.

URINARY BLADDER

The urinary bladder shows anechoic contents. Its wall thickness appears normal.

UTERUS

Uterus measures = 6.8 x 2.6 x 3. cms.

The uterus is anteverted and anteflexed and normal in size. There are no focal or diffuse lesions noted.

The endometrium appears normal (7.9 mm).

OVARIES


Both the ovaries appear normal in size.

Right ovary measures :3.8 x 4.0 Cm , Left ovary measures :3.9 x 4.1 cm

There is no obvious evidence of abdominal or pelvic lymphadenopathy or ascites noted.

No other obvious pelvic mass is seen. No probe-tenderness is noted.

IMPRESSION: No significant abnormality is detected.

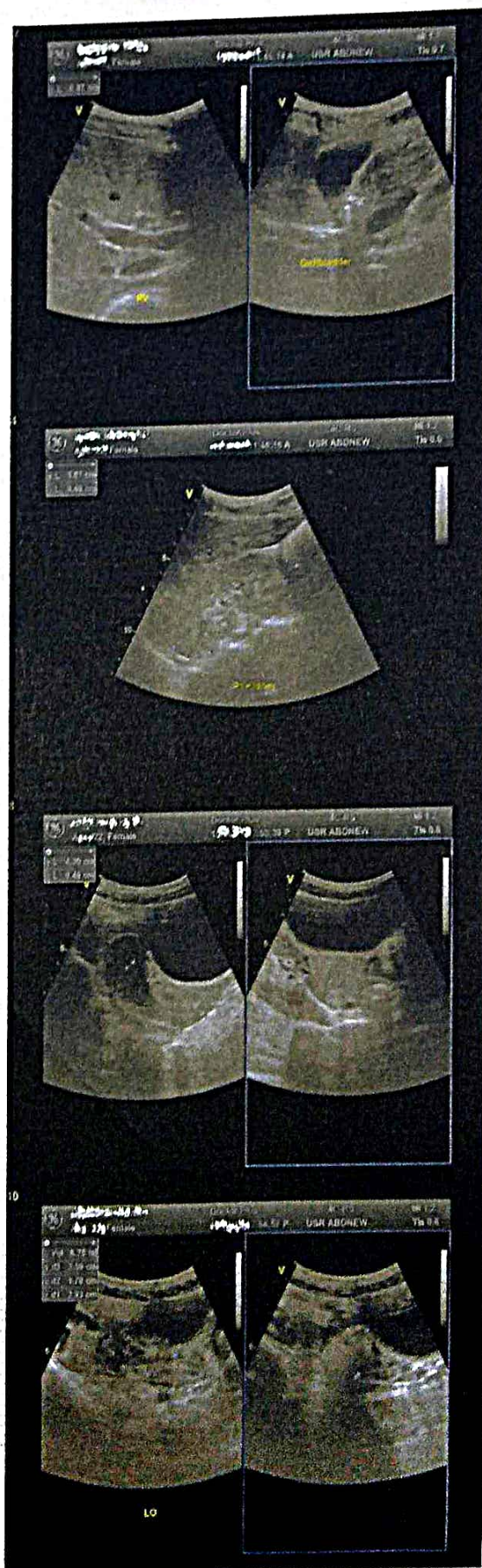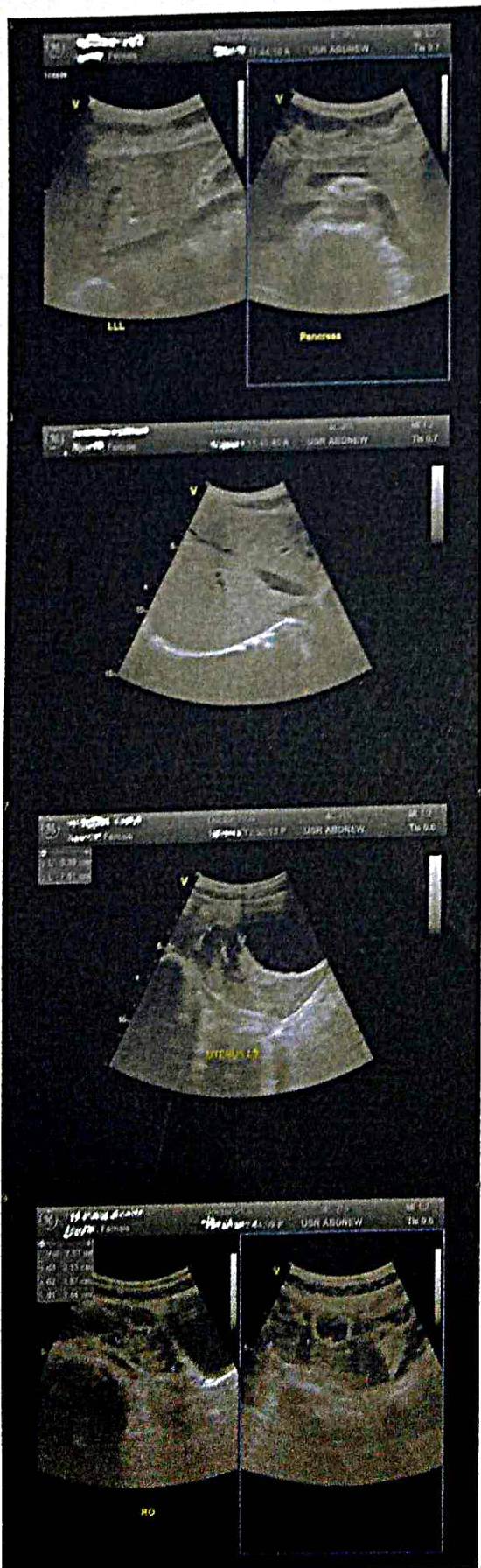

Dr. Parag Jhaveri
MBBS (BOM), DMRE (BOM)
Radio-Sonologist

'DR. PLUS HEALTHCARE CENTRE'
NATHANI HEIGHTS, B-WING,
42, MUMBAI CENTRAL (EAST)

Name PROMITA SEN

Sex Female

Age 31





Dr-Plus Healthcare Centre

NATHANI HEIGHTS, B-Wing, Shop No. 42, Ground Floor, Opp. Mumbai Central Station (East), Mumbai - 400 008.

Patient's Name : PROMITA SEN

Report Date : 11/09/2021

Referred By Dr. : DR. HARI CHHABLANI

Age : 31 Years

Sex : FEMALE

X- RAY CHEST PA

BOTH THE LUNG FIELDS ARE CLEAR .

THE HILAR SHADOWS APPEAR NORMAL.

THE COSTO -PHRENIC ANGLES ARE CLEAR.

THE CARDIAC SHADOWS APPEAR NORMAL.

THE TRACHIA IS CENTRAL IN POSITION.

THE BONY CAGE APPEARS NORMAL.



Radiologist

DR. A. J. MAZUMDAR

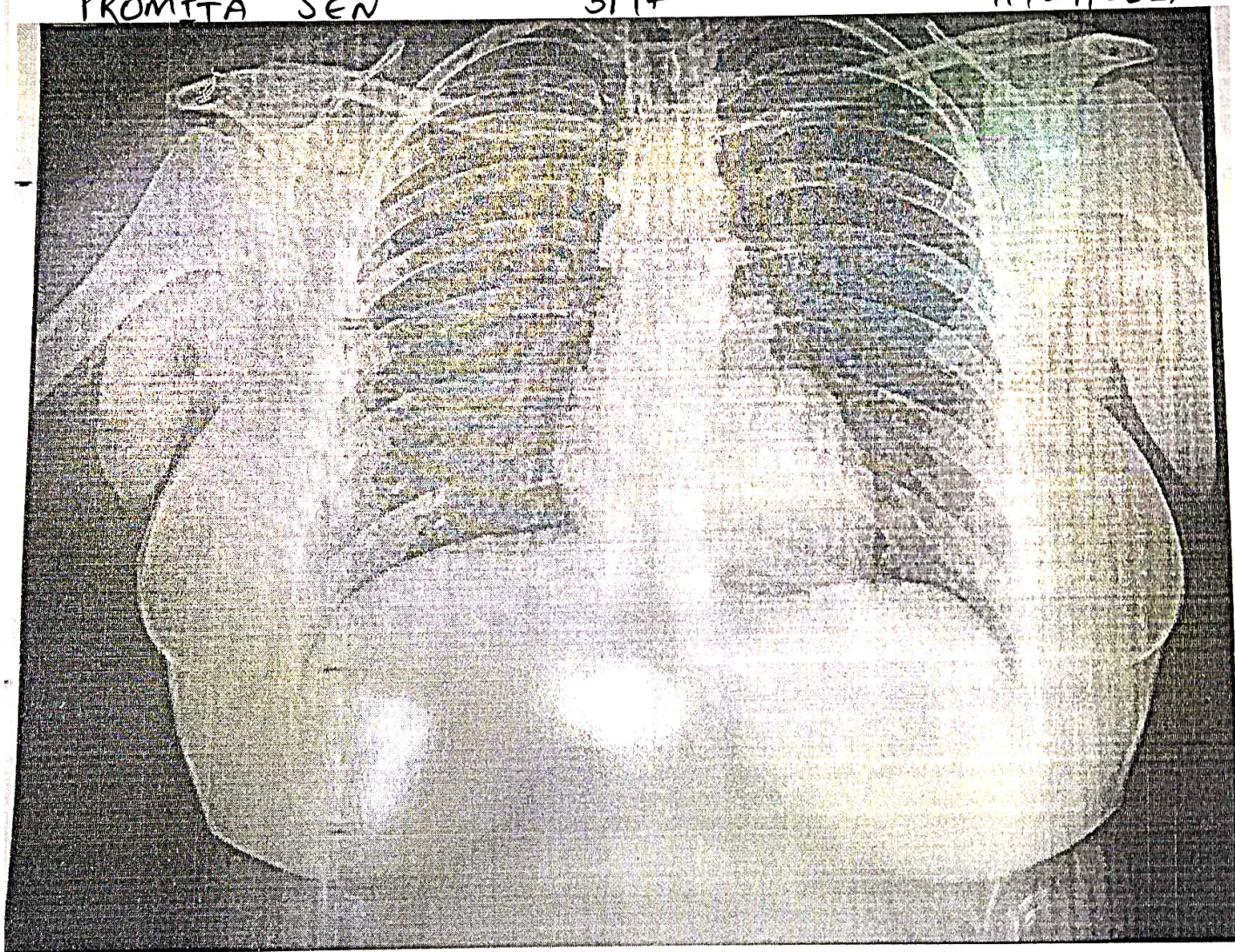
MD. DMRE, MDRD

'DR. PLUS HEALTHCARE CENTRE'
NATHANI HEIGHTS', B-WING,
42, MUMBAI CENTRAL (EAST)

PROMITA SEN

31/F

11/09/2021





Dr-Plus Healthcare Centre

NATHANI HEIGHTS, B-Wing, Shop.No. 42, Ground Floor, Opp. Mumbai Central Station (East), Mumbai - 400 008.

Full Name of life to be assured:

PROMITA SEN

31/F

DATE:11/09/2021

HAEMOGRAM

Normal Range

1.	Red Blood Cell Count	3.8	[M : 4.5 - 5.6 / F : 3.5 - 5.5/cu.mm]
2.	Hb%	11.3	[M: 14-18 / F : 11-16%]
3.	Hematocrit	40	[M : 40-53 / F : 30-47 %]
4.	Indices:		
(a)	MCV(Mean Corpuscular Volume)	88	[79-101 cu.mi.]
(b)	MCH(Mean Corpuscular Hb)	32	[27-32 pg]
(c)	MCHC(Mean Corpuscular Hb Concentration)	33	[32-38%]
5.	Morphology		
	Macrocytes :	--	Microcytes: -- Hypochromia: --
	Poikilocytosis:	--	Anisocytosis: --
6.	Target cells:	--	
	Spherocytes:	--	Elliptocytes: --
7.	TOTAL W.B.C.Count	8,100	{4000-11000/cu.mm}
Differential Count 0			
a)	Neutrophils :	61	[45 -70%] c) Eosinophils: 05 [01 - 06%]
b)	Lymphocytes :	29	[20 - 45%] d) Monocytes: 05 [00 - 08%]
e)	Basophils :	00	[00 - 01%]
8.	Platelets : 2.69		1.5-4.5 Lacks/cu.mm
9.	Erythrocyte Sedimentation Rate:12		20 mm at end of 1 hour Method : Westergrens

ROUTINE URINE EXAMINATION (RUA)

1. Physical Examination:

(i)	Colour:	PLAN YELLOW	(ii)	Sediment:	CLEAR
(iii)	Transparency:	ABSENT	(iv)	Reaction:	ACIDIC
(v)	Specific gravity	1.015			

2. Chemical Examination:

(i)	Protein :	ABSENT	(ii)	Sugar:	ABSENT
(iii)	Bile salt:	ABSENT	(iv)	Bile pigment:	ABSENT

3. Microscopic Examination:

(i)	Red Blood Cells:	ABSENT	(ii)	Epithelial Cells:	ABSENT
(iii)	Crystals:	ABSENT	(iv)	Pus Cells:	02 TO 03/HPF
(v)	Casts:	ABSENT	(vi)	Deposits:	ABSENT
(vii)	Bacteria's :	ABSENT			

DR. RAJESH PATKAR
M.D., P.N.B. (Pathology)
Reg. No. 2013/05/1660



Dr-Plus Healthcare Centre

NATHANI HEIGHTS, B-Wing, Shop No. 42, Ground Floor, Opp. Mumbai Central Station (East), Mumbai - 400 008.

Full Name

PROMITA SEN

31/F

DATE:11/09/202

	Type of Test	Actual Reading	Normal Range
1	Fasting Blood Sugar	79.9	70-100 mg%
2	PPBS	127	110 TO 140 mg%
3	Total Cholesterol	175	120-200 mg%
4	VERY LOW DENSINTY LEVEL(VLDL)	20	10-30 mg/dl
5	High Density Lipid (HDL)	55	40-60 mg%
6	Low Density Lipid (LDL)	100	Upto 150
7	S. Triglycerides	134.0	50-150 mg%
8	CHOL/HDL	3.1	Upto 5
9	HDL/LDL	0.55	
10	S. Creatinine	1.0	0.5-1.2 mg%
11	Blood Urea Nitrogen (BUN)	14.9	7-21 mg%
12	BUN/CREAT RATIO	14.9	
13	S. Proteins	6.8	6.0-7.9 mg%
14	(a) Albumin	3.5	3.5-5.5 mg%
15	(b) Globulin	3.3	2.0-3.5 mg%
16	A/G RATIO	1.06	
17	S. Bilirubin	0.9	0.3-1.3mg%
18	(a) Direct	0.6	0.0-0.8 mg%
19	(b) Indirect	0.3	0.0-0.5 mg%
20	SGOT (AST)	23.2	05-34 IU
21	SGPT (ALT)	29.5	05-40 IU
22	GGTP (GGT)	32.3	05-50 IU
23	SGOT/SGPT	0.7	
24	HBA1C	5.3	UPTO 6.5
25	S. Alkaline Phosphatase	81.2	30-115 IU
26	T3	139.8	80-180ng/dl
27	T4	7.4	4.6-12 ug/dl
28	TSH	3.12	0.4-4.0 mIU/L
29	SERUM URIC ACID	6.14	2.5-7.2mg/dl
30	URINE SUGAR PP	ABSENT	
31	URINE SUGAR FASTING	ABSENT	
32	BLOOD GROUP	"AB"POSITIVE"	

DR. RAKESH PATKAR
M.D., D.N.B. (Pathology)
Reg. No. 2013/05/1660



Dr. Hari Chhablani

Cardiometabolic Physician & Intensivist
M.B.B.S., F.C.C.P. (RESP. MED.), PGDHHM,
PGDMLS, FELLOW INTENSIVE CARE MED.

ATTACHED TO: Wockhardt Hospital • Saifee Hospital • Apollo Spectra Hospital

NATHANI HEIGHTS, B-Wing, Shop No. 42, Ground Floor, Opp. Mumbai Central Station (East),
Mumbai - 400 008. • Cell : 98206 46163 • E : drharichhablani@gmail.com

PHYSICIAN REPORT

11/09/2021

NAME : PROMITA SEN

AGE/SEX: 31/F

PRESENTING COMPLAINTS: NIL

PAST HISTORY: COVID -19 POSITIVE

TREATMENT HISTORY : NIL

FAMILY HISTORY: NOT SIGNIFICANT

ADDICTION: ALCOHOL

P: 96/MIN

BP: 120/82

RS: CLEAR

CVS: S1,S2 REGULAR

PA: SOFT

CNS: CLINICALLY NAD

ECG: WNL

CXR: WNL

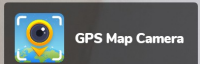
LABS: ATTACHED

EYE EXAMINATION B/E: NEAR VISION - BL N6 DISTANT VISION - 6/6 COLOUR VISION - NORMAL

IMPRESSION : FIT ON CLINICAL MEDICAL EXAMINATION .

DR. HARI CHHABLANI

DR. HARI CHHABLANI
M.B.B.S. F.C.C.P. (RESP. MEDICINE) PGDHHM, PGDMLS
FELLOW INTENSIVE CARE
MMC REG. NO. - 91702



Mumbai, Maharashtra, India

Shop No. - 3, Akhil Bhartiya Bhavan, Belasis Road, Tardeo, Mumbai -
400034, Marzban Parsi Colony, Dalal Estate, Mumbai Central, Mumbai,
Maharashtra 400008, India

Lat 18.968769°

Long 72.819979°

11/09/21 09:39 AM

