

Pt. Name - Yogender Kumar
Age - 38 y/male

Ht - 169 cm
Wt - 78 kg
BP - 125/79 mmHg
SpO₂ - 98%
PR - 81/min
Temp - 97.6°f

Ch:- Constipation
no other Complaint

H/o: No significant Medical/Surgical
History.

Investigations:- Total Cholesterol and Triglycerides
raised.
Slight increase in unconjugated
Bilirubin and GGT

Adv

- Dietary changes for dyslipidemia.
add raw vegetables to diet, oil
free diet.
- Exercise (Moderate intensity) for
30 minutes, 5 days a week.
- Maintain hydration.
- patient is fit to continue work.

Dr. Neha Sharma
General Physician
Reg No. DMC/R/32801



ECG CARDIOPRINT

ID: 1382 CASE: 3765 YOGENDER KUMAR
AGE: 38Y M D MALE

09/11/2024 10:10:25
HEALIC MULTISPECIALITY CLINIC
INDRAPURAM

CM9 K9

HR: 69 bpm SINUS RHYTHM

PR: 136 ms

QRS: 82 ms

QT: 350 ms

QTc: 366 ms

AXIS: -

P: 31°

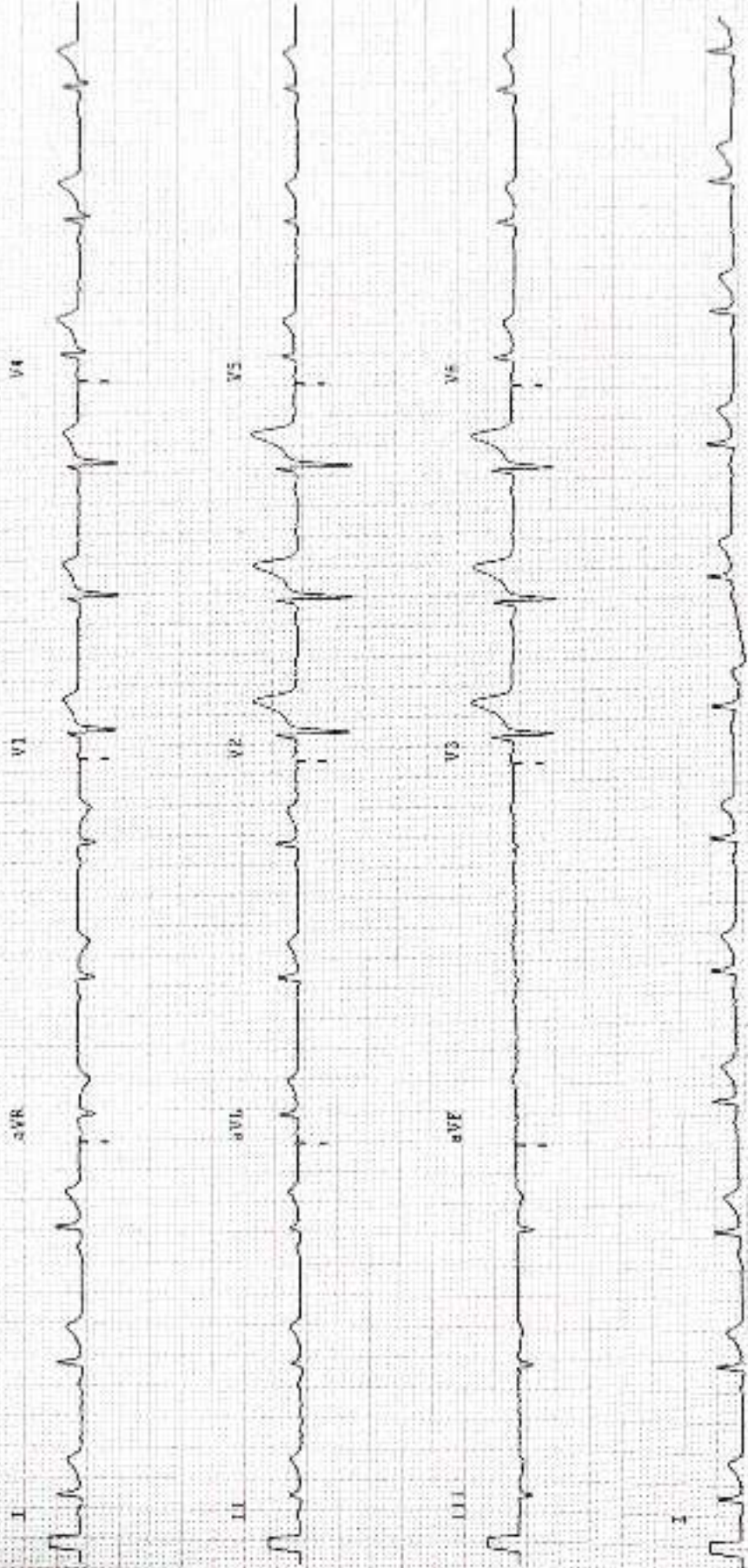
QRS: 03°

T: 11°

12 LEAD ECG PRINT FORMAT: 3x4+14 SM

REF:

DL:



Dr. Sanchit Singh
Cardiologist, Pulmonologist
& Thoracic Endocrinologist
MBBS, MD (Gen Med), MCh (CC),
DIPLOMA IN ENDOCRINOLOGY
Senior Consultant
Sri Chaitanya Hospital



Our Latest Ho

₹10,000

₹20,000

ke health

Health

₹1,999

FREE Visit

₹2,000/-

FREE 3 Full Body Checkup

1 Full Body Checkup at 50% OFF

1 FREE

1 Consult

10% OFF

10% OFF

10% OFF

100+ Doctors

20+ Specialties

90+

Sur

Sur

GPS Map Camera



Ghaziabad, Uttar Pradesh, India
Tower-a, Saya Zenith, Indirapuram, Ghaziabad,
Uttar Pradesh 201014, India
Lat 28.637853° Long 77.378861°
09/11/24 10:08 AM GMT +05:30



भारत सरकार
GOVERNMENT OF INDIA



Aadhaar no. issued: 15/11/2011



योगेंद्र कुमार
Yogender Kumar
जन्म तिथि/DOB: 03/07/1986
पुरुष/ MALE
Mobile No: 9811445335

Details as on: 30/03/2014

6427 2237 0983
VID : 9134 0662 1179 8332

मेरा आधार , मेरी पहचान

NAME	YOGENDER KUMAR	AGE/SEX	38 YRS/ MALE
REFD BY.	SELF	DATE	09/11/2024
ULTRASOUND WHOLE ABDOMEN			

LIVER: Liver is normal in size (13.3 cm) and shows mildly increased echogenicity. No focal intra-hepatic lesion is detected. Intra-hepatic biliary radicals are not dilated. Portal vein is normal in calibre.

GALL BLADDER: Gall bladder appears echofree with normal wall thickness. Common bile duct is normal in calibre.

PANCREAS: Visualised head of pancreas appears normal in size and echopattern. Rest is obscured due to excessive bowel gases.

SPLEEN: Spleen is normal in size (10.9 cm) and echopattern.

KIDNEYS: Both kidneys are normal in outline. Lower poles of both kidneys appear to be fused forming an isthmus in midline—may represent horseshoe kidney. Cortico-medullary differentiation of both kidneys is maintained. Central sinus echoes are compact. No focal lesion or calculus seen. Bilateral pelvicalyceal systems are not dilated.

URINARY BLADDER: Urinary bladder is normal in wall thickness with clear contents. No significant intra or extraluminal mass is seen.

PROSTATE: Prostate is normal in size (14.2 cc) and echopattern.

No significant free fluid is detected.

Note is made of excessive bowel gases.

IMPRESSION:

- Grade I fatty liver.
- Lower poles of both kidneys appear to be fused forming an isthmus in midline—may represent horseshoe kidney. Suggest NCCT KUB correlation.

Adv: Clinical correlation

DR. REMA ARORA
MBBS, DNB (Radio diagnosis)
CONSULTANT RADIOLOGIST

Disclaimer- The science of radiology is based upon interpretation of shadows of normal and abnormal tissue. This is neither complete nor accurate. Hence, finding should always be interpreted in the light of clinic-pathological correlation. This is a professional opinion. Not a diagnosis. Not meant for medicolegal purposes.



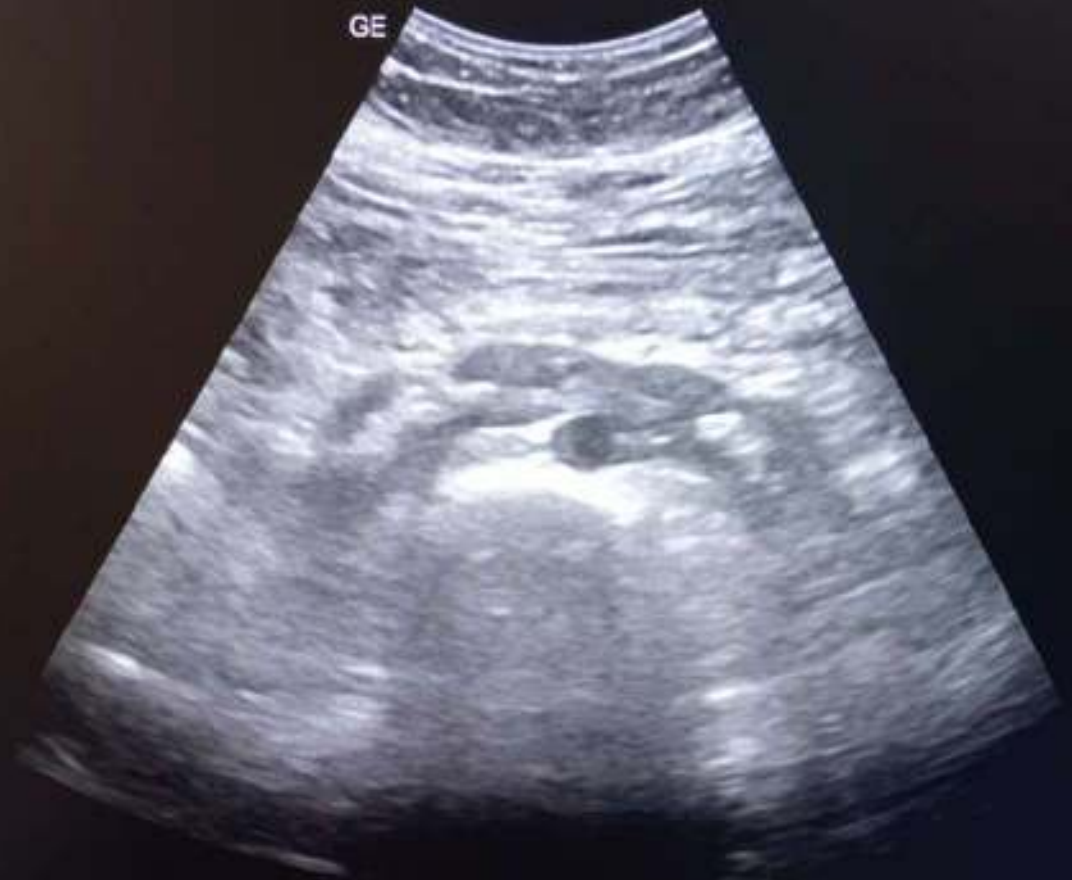HEALIC MULTISPECIALTY CLINIC
09/11/2024 11:37:18 amADM

YOGENDER KUMAR,
091124-110624AM

MI 0.8
T1a 0.2

4C
Abdomen

GE



0 -

5 -

10 -

15 -



HEALIC MULTISPECIALTY CLINIC

09/11/2024 11:14:20 amADM

YOGENDER KUMAR,

091124-110624AM

MI 0.5

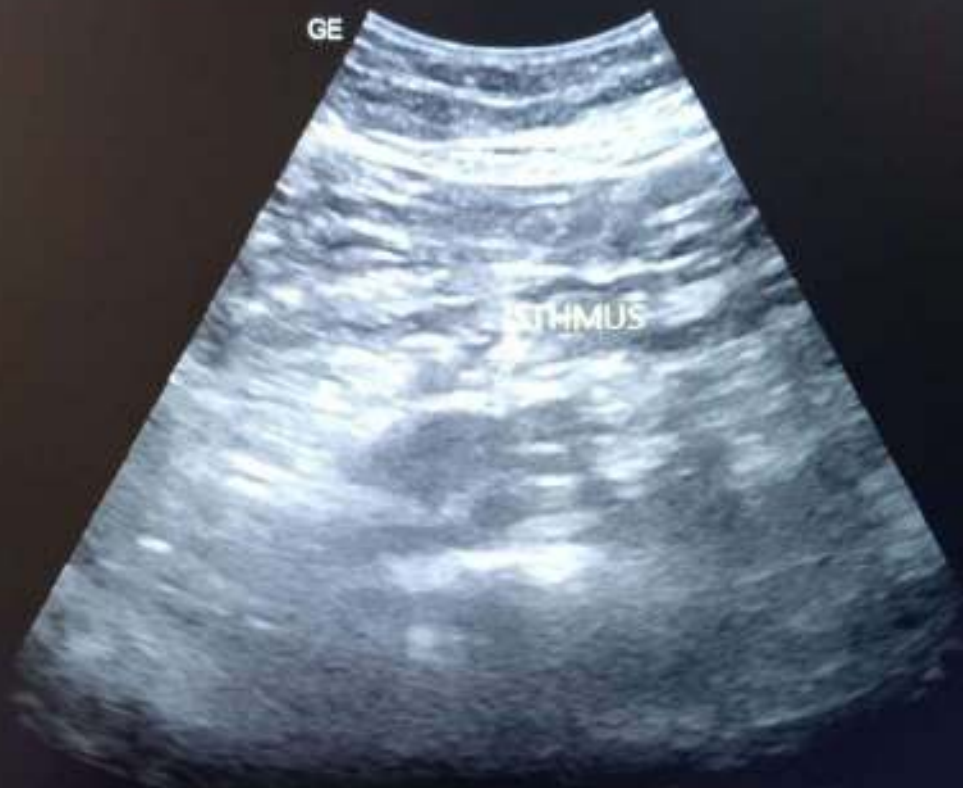TIs 0.1

4C

Renal



GE



- 0 - FR
- AO%
- CHI
- Frq
- Gn
- S/A
- Map
- D
- DR
- Whizz

10

15

0.0




HEALIC MULTISPECIALTY CLINIC
09/11/2024 11:07:52 amADM

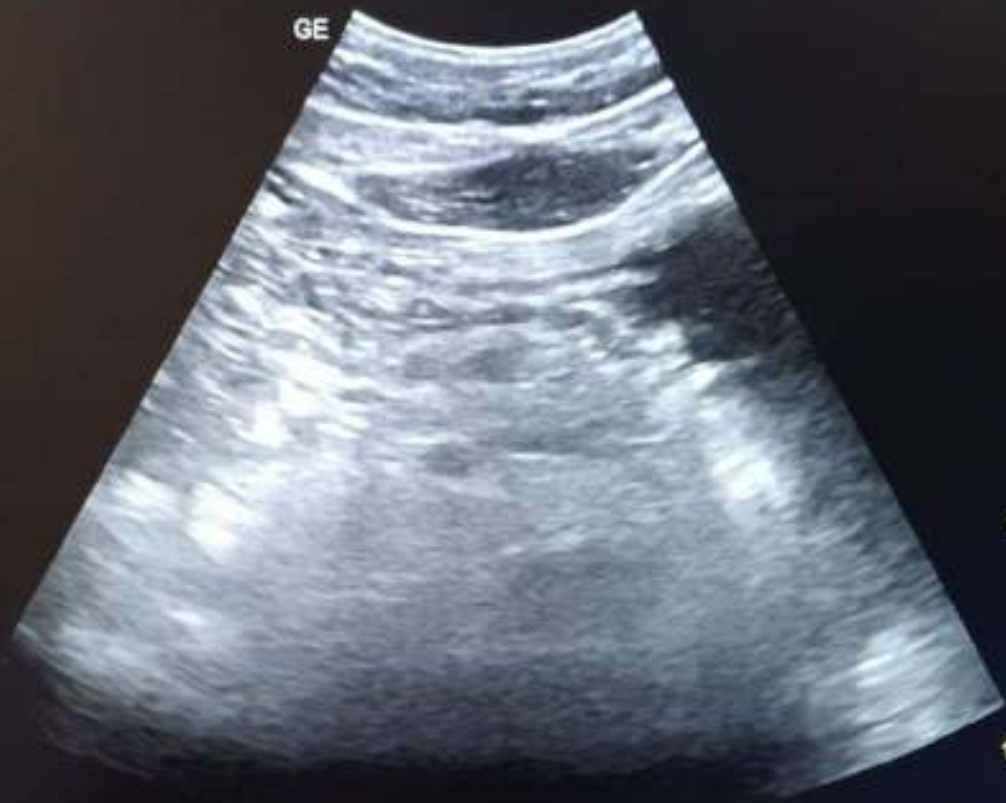YOGENDER KUMAR,
091124-110624AM

MI 0.8
TIs 0.2

4C
Abdomen



GE



- 0 - FR
- AO%
- CHI
- Frq
- Gn
- S/A
- Map
- D
- DR
- Whlzz
- 5 -
- 10 -
- 15 -



HEALIC MULTISPECIALTY CLINIC
09/11/2024 11:08:57 amADM

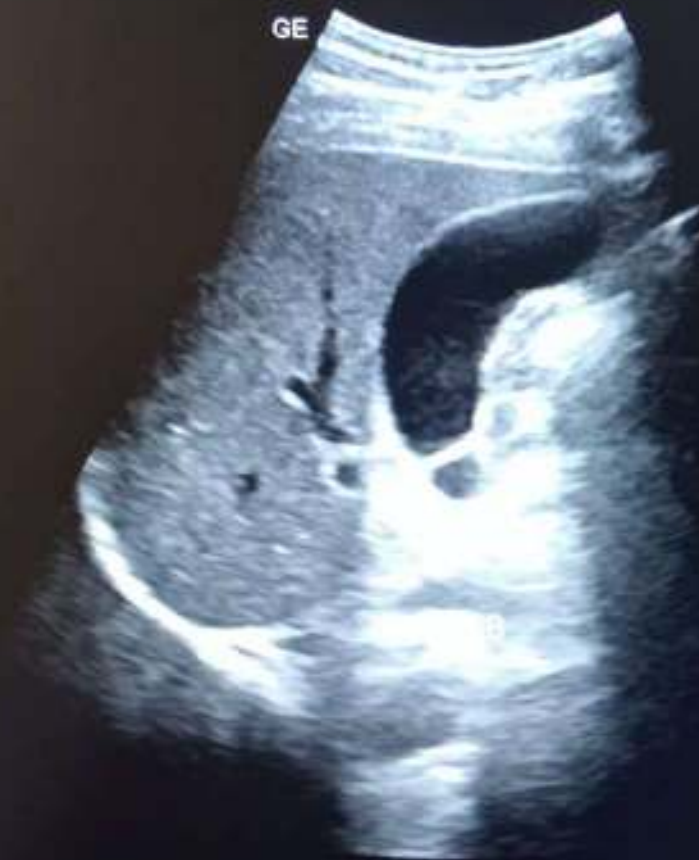YOGENDER KUMAR,
091124-110624AM

MI 0.8
Tis 0.2

4C
Abdomen



GE



0 -
5 -
10 -
15 -

FR
AD%
CHI
Frq
Gn
S/A
Map
D
DR
Whizz

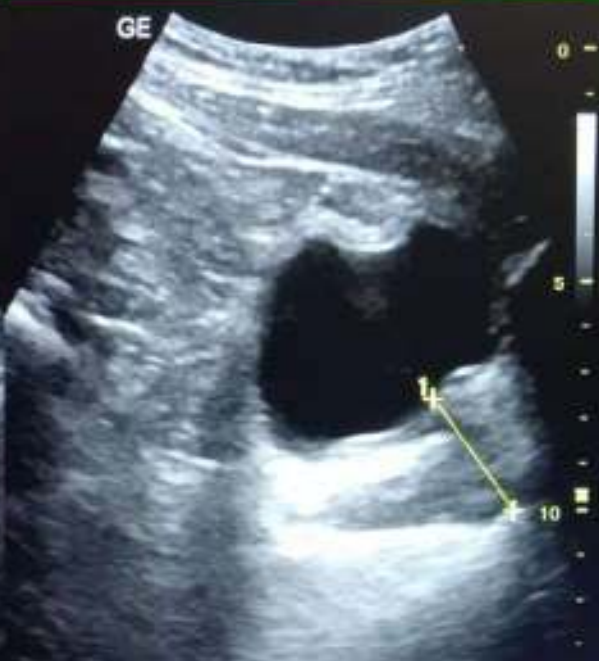
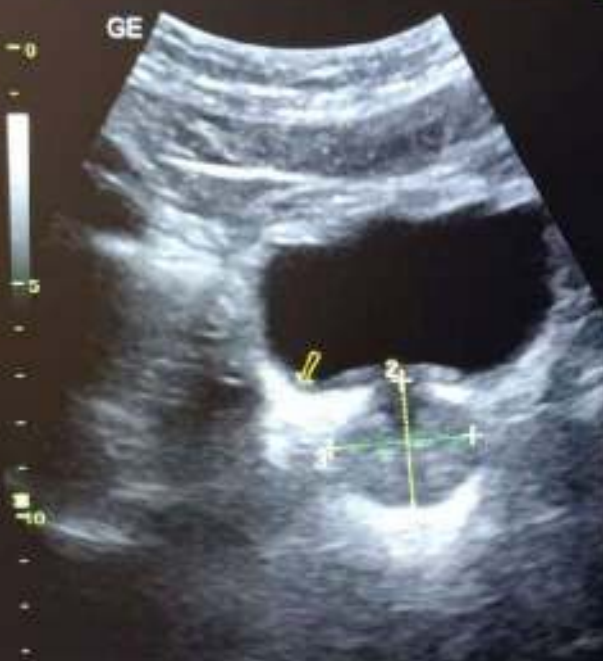
HEALIC MULTISPECIALTY CLINIC
09/11/2024 11:16:17 amADM

YOGENDER KUMAR,
091124-110624AM

MI 0.5
Tis 0.1

4C
Renal



FR
AC%
CHI
Frq
Gn
S/A
Map
D
DR
Whizz

1 L	3.06 cm
2 H	2.85 cm
3 W	3.13 cm
Vol	14.29 ml
d	8.72 cm
L	0.00 cm

Place the first point

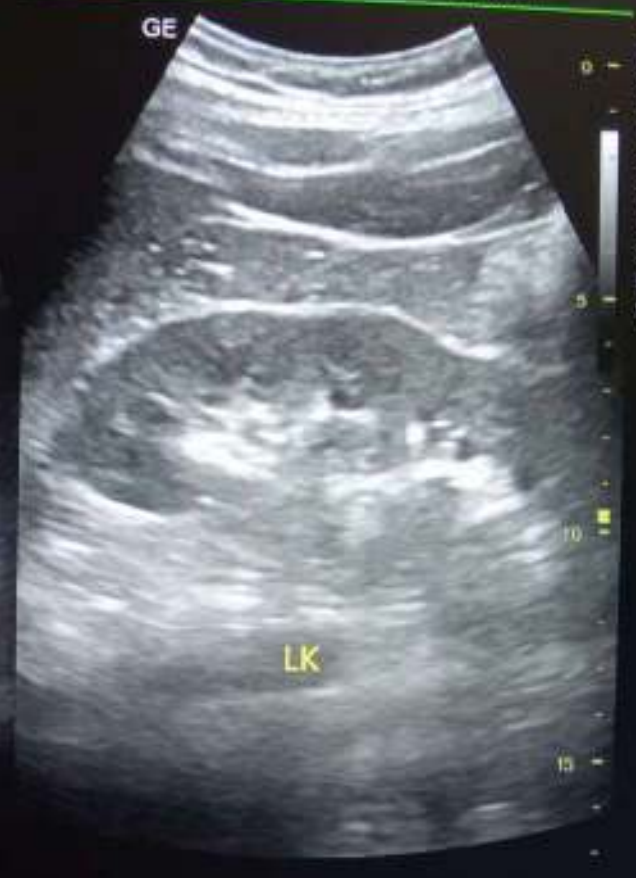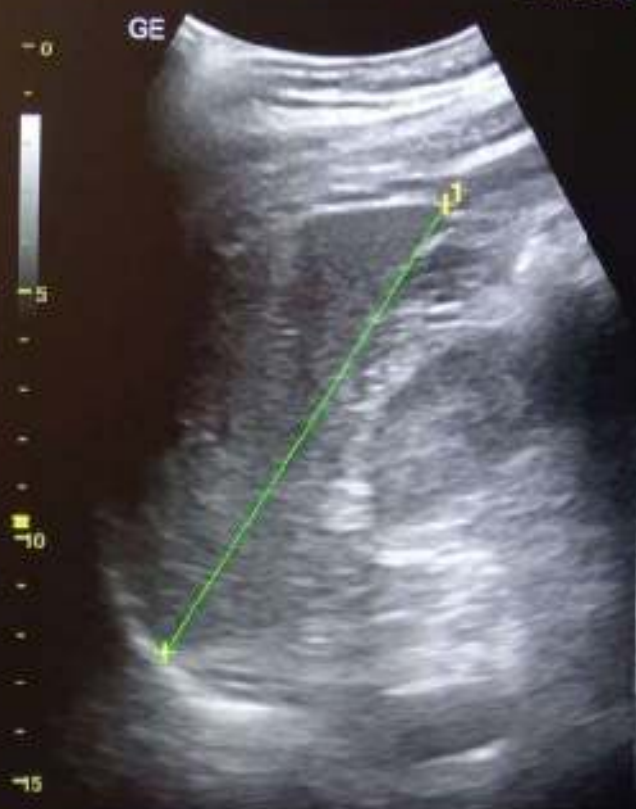0.0



HEALIC MULTISPECIALTY CLINIC
09/11/2024 11:09:40 amADM

YOGENDER KUMAR,
091124-110624AM

MI 0.8
TIs 0.2
4C
Abdomen



FR
AO%
CHI
Frq
Gn
S/A
Map
D
DR
Whizz

1 L	109.13 mm
d	12.58 cm
L	0.00 mm

Place the first point

0.0



HEALIC MULTISPECIALTY CLINIC

09/11/2024 11:16:48 amADM

YOGENDER KUMAR,

091124-110624AM

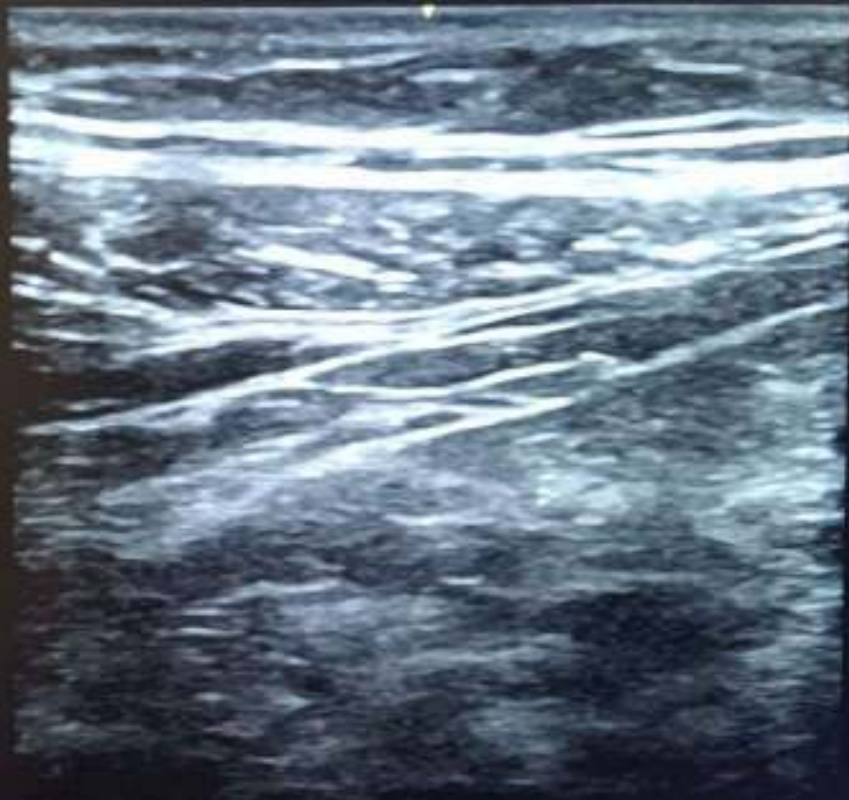
MI 1.2

TIs 0.1

L6-12

Carotid

GE



0 -

-

-

-

-

1 -

-

-

-

II

2 -

-

-

-

3 -

-

-

-

-

-

4 -



HEALIC MULTISPECIALTY CLINIC
09/11/2024 11:08:32 amADM

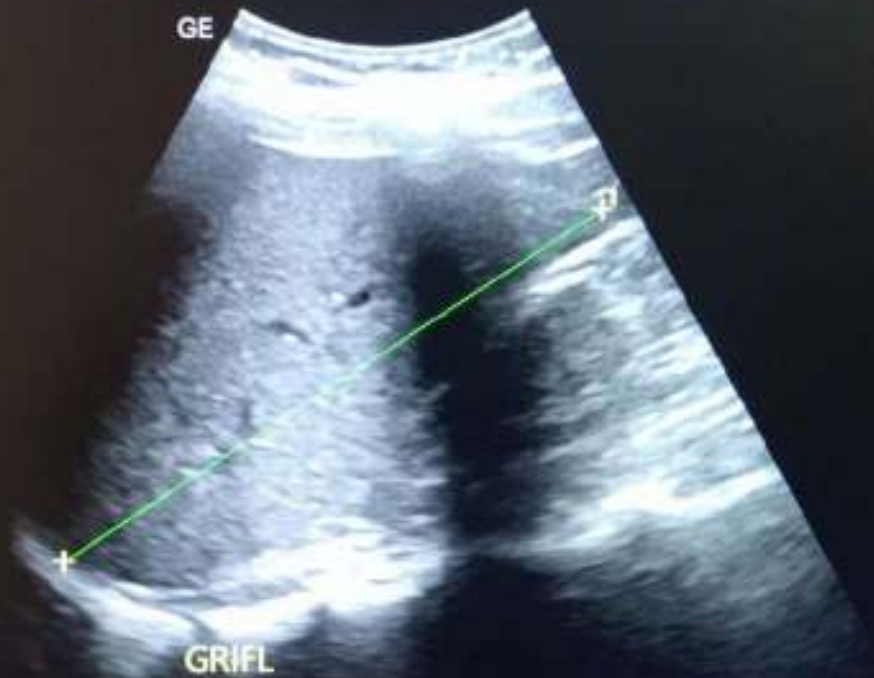YOGENDER KUMAR,
091124-110824AM

MI 0.8
Tie 0.2

4C
Abdomen



GE



GRIFL

- 0 - FR
- AO%
- CHI
- Frq
- Gn
- S/A
- Map
- D
- DR
- Whizz
- 5 -
- 10 -
- 15 -

1 L 133.89 mm



NAME	YOGENDER KUMAR	AGE/SEX	38 YRS/ MALE
REFD BY.	SELF	DATE	09/11/2024
<u>X-RAY CHEST PA VIEW</u>			

Findings:

Visualized lung fields appear clear.

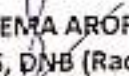
Both hilar shadows appear normal.

Cardiothoracic ratio is within normal limits.

Both hemidiaphragmatic outlines appear normal.

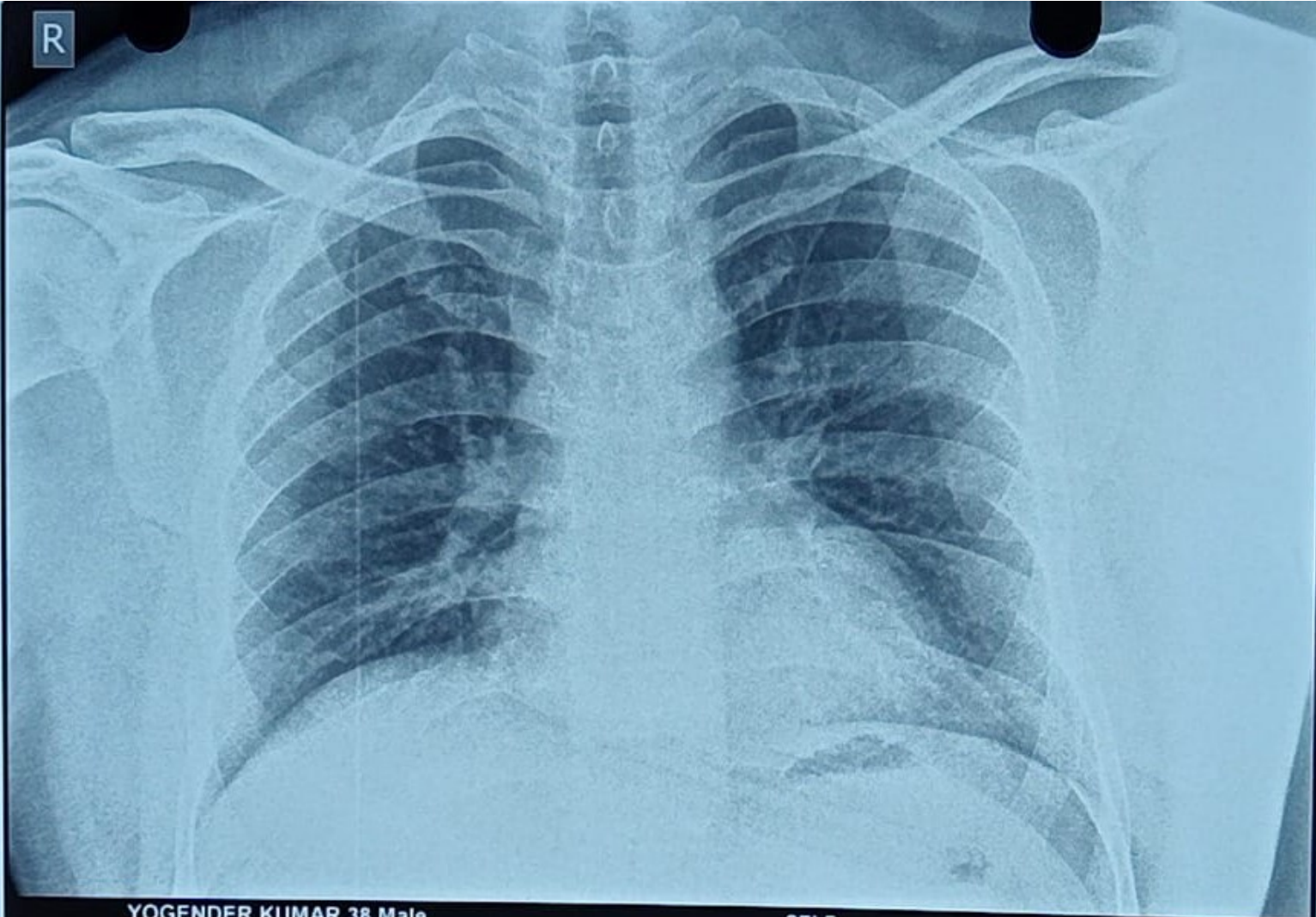
Both costophrenic angles are clear.

IMPRESSION: No significant abnormality seen.


DR. REMA ARORA
MBBS, DNB (Radiodiagnosis)
CONSULTANT RADIOLOGIST

Disclaimer- The science of radiology is based upon interpretation of shadows of normal and abnormal tissue. This is neither complete nor accurate. Hence, finding should always be interpreted in the light of clinic-pathological correlation. This is a professional opinion. Not a diagnosis. Not meant for medicolegal purposes.

R



YOGENDER KUMAR 38 Male

Chest PA

62.5 % 02

SELF

09/11/2024 10:44:30 AM

HEALIC MULTISPECIALTY CLINIC- INDIRAPURAM