

CID#	: 2204331989	SID#	: 177801968126
Name	: MRS.NIDHI ASTHANA	Registered	: 12-Feb-2022 / 09:28
Age / Gender	: 39 Years/Female	Collected	: 12-Feb-2022 / 09:28
Consulting Dr.	: -	Reported	: 13-Feb-2022 / 10:09
Reg.Location	: Kandivali East (Main Centre)	Printed	: 13-Feb-2022 / 15:27

PHYSICAL EXAMINATION REPORT

History and Complaints:

Prediabetic since 1 yrs.

EXAMINATION FINDINGS:

Height (cms):	155 cms	Weight (kg):	67 kgs
Temp (0c):	Afebrile	Skin:	Normal
Blood Pressure (mm/hg):	120/80	Nails:	Normal
Pulse:	72/min	Lymph Node:	Not palpable

Systems

Cardiovascular: Normal
Respiratory: Normal
Genitourinary: Normal
GI System: Normal
CNS: Normal

IMPRESSION:

*↑ Fasting B1-sugar
 - HbA1c 5.9%
 Wbc - 10-12 pus cells
 - Dyslipidemia
 - USG - fatty liver*

ADVICE:

*low fat / diet
 " carbs
 Lots of liquids
 Diastabgl-ospinon*

ADDRESS: 2nd Floor, Aston, Sundervan Complex, Above Mercedes Showroom, Andheri West - 400053

HEALTHLINE - MUMBAI: 022-6170-0000 | **OTHER CITIES:** 1800-266-4343

Page:1 of 2

For Feedback - customerservice@suburbandiagnosics.com | **www.suburbandiagnosics.com**

CID# : 2204331989 SID# : 177801968126
Name : MRS.NIDHI ASTHANA Registered : 12-Feb-2022 / 09:28
Age / Gender : 39 Years/Female Collected : 12-Feb-2022 / 09:28
Consulting Dr. :- Reported : 13-Feb-2022 / 10:09
Reg.Location : Kandivali East (Main Centre) Printed : 13-Feb-2022 / 15:27

CHIEF COMPLAINTS:

- | | |
|--|----------------|
| 1) Hypertension: | No |
| 2) IHD | No |
| 3) Arrhythmia | No |
| 4) Diabetes Mellitus | Prediabetic |
| 5) Tuberculosis | No |
| 6) Asthama | No |
| 7) Pulmonary Disease | No |
| 8) Thyroid/ Endocrine disorders | No |
| 9) Nervous disorders | No |
| 10) GI system | No |
| 11) Genital urinary disorder | No |
| 12) Rheumatic joint diseases or symptoms | No |
| 13) Blood disease or disorder | No |
| 14) Cancer/lump growth/cyst | No |
| 15) Congenital disease | No |
| 16) Surgeries | LSCS 2018,2016 |
| 17) Musculoskeletal System | No |

PERSONAL HISTORY:

- | | |
|---------------|-------|
| 1) Alcohol | No |
| 2) Smoking | No |
| 3) Diet | Mixed |
| 4) Medication | No |

*** End Of Report ***



SUBURBAN DIAGNOSTICS (INDIA) PVT. LTD.
Row House No. 3, Aangan,
Thakur Village, Kandivali (east),
Mumbai - 400101.
Tel : 61700000


Dr. Jagruti Dhale
MBBS
Consultant Physician
Reg. No. 69548

ADDRESS: 2nd Floor, Aston, Sundervan Complex, Above Mercedes Showroom, Andheri West - 400053

HEALTHLINE - MUMBAI: 022-6170-0000 | OTHER CITIES: 1800-266-4343

Page:2 of 2

For Feedback - customerservice@suburbandiagnosics.com | www.suburbandiagnosics.com

Date:- 12/12/22

CID:
2204331989

Name:- Mrs. Nidhi Ashthana

Sex/Age: F/40

EYE CHECK UP

Chief complaints: Routine checkup

Systemic Diseases: No H/O DM/HT

Past history: No H/O Ocular surgery

h/o
< +1.25 to +0.50 x 90
+1.25

Unaided Vision: 6/6 blr

6/6 blr

Aided Vision: N/G

N/G

Refraction: Goms! Normal

(Right Eye)

(Left Eye)

	Sph	Cyl	Axis	Vn	Sph	Cyl	Axis	Vn
Distance	±	+0.50	90°	6/6	±	+0.50	55	6/6
Near	+1.25	+0.50	90°	N/G	+1.25	+0.50	55	N/G

Colour Vision: Normal / Abnormal

Remark: Vn within normal limit
Adv. Progressive gl = ARE

KAJAL NAGRECHA
OPTOMETRIST

SUBURBAN DIAGNOSTICS (INDIA) PVT. LTD.
Row House No. 3, Aangan,
Thakur Village, Kandivali (east),
Mumbai - 406101.
Tel : 61700000

ADDRESS: 2nd Floor, Aston, Sundervan Complex, Above Mercedes Showroom, Andheri West - 400053
HEALTHLINE - MUMBAI: 022-6170-0000 | OTHER CITIES: 1800-266-4343
For Feedback - customerservice@suburbandiagnosics.com | www.suburbandiagnosics.com

Brief Disclaimer: (1)Suburban Diagnostics ensures that the tests are conducted with utmost care and safety and are performed on samples received as per the sample collection guide of Suburban Diagnostics.(2)Sample may be rejected if unacceptable for the requested tests. (3)Test results may vary from laboratory to laboratory and also in some parameters from time to time for the same patient.(4)Report must not be copied in part, only in full. (5)This report is not valid for medico-legal purposes.(6)Patient information or data will not be communicated to a third party except in the case of a notifiable disease to a Public Care Unit.(7)Suburban Diagnostics reserves the right to subcontract samples to other laboratories as required.(8)Suburban Diagnostics is not liable for any penalties or liabilities arising out of or relating in any way to these services and/or content or information provided herein.(9) For the elaborated disclaimer, please turn over the page or visit our website.



CID : 2204331989
Name : Mrs NIDHI ASTHANA
Age / Sex : 39 Years/F
Ref. Dr :
Reg. Location : Kandivali East Main Centre

Reg. Date : 12-Feb-2022 / 09:29
Reported : 12-Feb-2022 / 13:55

X-RAY CHEST PA VIEW

Both lung fields are clear.
Both costo-phrenic angles are clear.
The cardiac size and shape are within normal limits.
The domes of diaphragm are normal in position and outlines.
The skeleton under review appears normal.

IMPRESSION:
NO SIGNIFICANT ABNORMALITY IS DETECTED.

-----End of Report-----

This report is prepared and physically checked by DR.KHILJI before dispatch.

Khilji Faizur

Dr.FAIZUR KHILJI
MBBS,RADIO DIAGNOSIS
Reg No-74850
Consultant Radiologist

Click here to view images <http://202.143.96.162/Suburban/Viewer?ViewerType=3&AccessionNo=2022021209290680>



CID : 2204331989
Name : Mrs NIDHI ASTHANA
Age / Sex : 39 Years/F
Ref. Dr :
Reg. Location : Kandivali East Main Centre

Reg. Date : 12-Feb-2022 / 09:29
Reported : 12-Feb-2022 / 12:06

USG WHOLE ABDOMEN

LIVER:

The liver is normal in size (14.6 cm) shape and smooth margins. It shows **bright** parenchymal echo pattern. The intra hepatic biliary and portal radical appear normal. No evidence of any intra hepatic cystic or solid lesion seen. The main portal vein measures 12 mm and CBD appears measures 3.2 mm .The main portal vein and CBD appears normal.

GALL BLADDER:

The gall bladder is physiologically distended and appears normal.No evidence of gall stones or mass lesions seen

PANCREAS:

The pancreas is well visualised and appears normal. No evidence of solid or cystic mass lesion.

KIDNEYS:

Right kidney measures 9.4 x 4.1 cm. Left kidney measures 10.8 x 5.8 cm.

Both the kidneys are normal in size shape and echotexture.

No evidence of any calculus, hydronephrosis or mass lesion seen.

SPLEEN:

The spleen is normal in size (10.7 cm) and echotexture.No evidence of focal lesion is noted.

There is no evidence of any lymphadenopathy or ascites.

URINARY BLADDER:

The urinary bladder is well distended and reveal no intraluminal abnormality.

UTERUS:

The uterus is anteverted and appears normal.It measures 7.4 x 5.3 x 3.3 cm in size.

The endometrial thickness is 5.1 mm.

OVARIES:

Both the ovaries are well visualised and appears normal.

There is no evidence of any ovarian or adnexal mass seen.

Right ovary = 2.9 x 1.8 cm Left ovary = 2.9 x 1.7 cm

Click here to view images <http://202.143.96.162/Suburban/Viewer?ViewerType=3&AccessionNo=2022021209290664>



CID : 2204331989
Name : Mrs NIDHI ASTHANA
Age / Sex : 39 Years/F
Ref. Dr :
Reg. Location : Kandivali East Main Centre

Reg. Date : 12-Feb-2022 / 09:29
Reported : 12-Feb-2022 / 12:06

IMPRESSION:-
Grade I fatty liver.

-----End of Report-----

This report is prepared and physically checked by Dr Akash Chhari before dispatch.

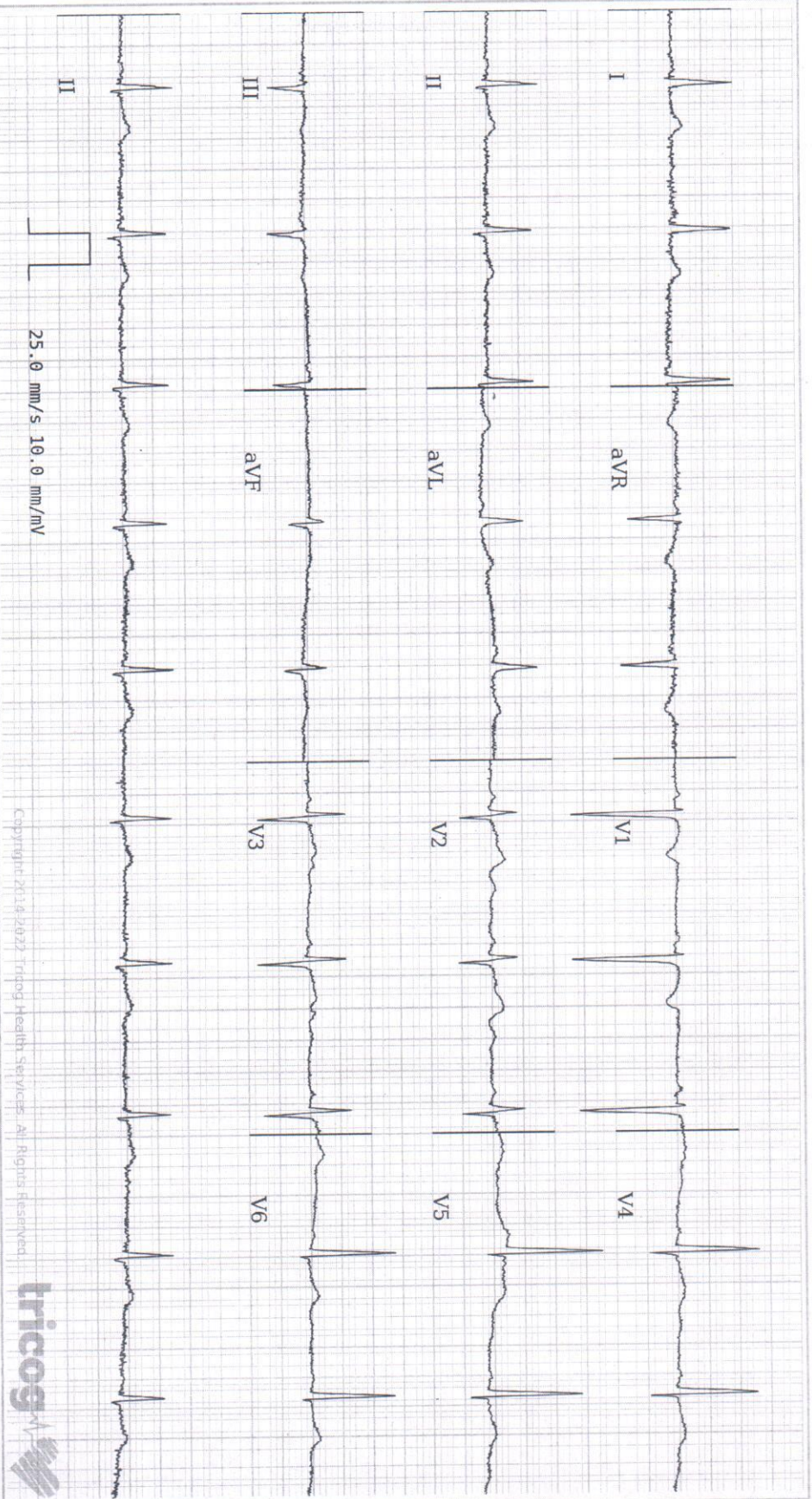
DR. Akash Chhari
MBBS. MD. Radio-Diagnosis Mumbai
MMC REG NO - 2011/08/2862

Click here to view images <http://202.143.96.162/Suburban/Viewer?ViewerType=3&AccessionNo=2022021209290664>

SUBURBAN DIAGNOSTICS - KANDIVALI EAST

Patient Name: NIDHI ASTHANA
Patient ID: 2204331989

Date and Time: 12th Feb 22 10:35 AM



Copyright © 2014-2022 Tricog Health Services. All Rights Reserved.



Age **39** 10 20
years months days

Gender **Female**

Heart Rate **64 bpm**

Patient Vitals

BP: 120/80 mmHg

Weight: 67 kg

Height: 155 cm

Pulse: NA

Spo2: NA

Resp: NA

Others:

Measurements

QSRD: 74 ms

QT: 418 ms

QTc: 431 ms

PR: 112 ms

P-R-T: 54° NA 15°

REPORTED BY

Dr. Akhil Parulekar

DR AKHIL PARULEKAR

MBBS, MD, MEDICINE, DNB Cardiology
Cardiologist
2012082483

ECG Within Normal Limits: Sinus Rhythm, Normal Axis. Please correlate clinically. **SUBURBAN DIAGNOSTICS (INDIA) PVT. LTD.**

Row House No. 3, Aarjagan,
Thakur Village, Kandivali (east),
Mumbai - 400101.

Tel : 61700000

Disclaimer: 1) Analysis in this report is based on ECG alone and should be used as an adjunct to clinical history, symptoms, and results of other invasive and non-invasive tests and must be interpreted by a qualified physician. 2) Patient vitals are as entered by the clinician and not derived from the ECG.