



Reg. No.- 815

PARASHAR HOSPITAL

(A Unit of Vijayesh Kumar & Sons Pvt Ltd.)

MURLI MANOHAR COMPLEX, KHADI BHANDAR CHOWK, MUZAFFARPUR-842002 (BIHAR)

Mob.: 6200471018, 7992247583 E-mail: parashar.hospital@gmail.com

Name :- Sumit Anand / Age - 35/M Date : 24/08/21.....

Add :- Aghoriya Bazaar

L/C :- Dirty teeth

O/E :- Carious $\frac{7}{68}$; T/P :- Restn. wt $\frac{7}{68}$

Rx :-

- Chlorhex ASD M/W - Rinse twice daily
- Stim Unique M/B T/B
-



Reg. No.- 815

PARASHAR HOSPITAL

(A Unit of Vijayesh Kumar & Sons Pvt Ltd.)

MURLI MANOHAR COMPLEX, KHADI BHANDAR CHOWK, MUZAFFARPUR-842002 (BIHAR)

Mob.: 6200471018, 7992247583 E-mail : parashar.hospital@gmail.com

Date :

PATIENT NAME : SUMIT ANAND

AGE/SEX : 0Y/Adult-M

REF. BY DR. : DR. PARASAR HOSPITAL

REF. NO : 23/08/21CP/49

TEST. DATE : 23/08/2021

RPT. DATE : 23/08/2021

INVESTIGATIONS	VALUE	REF. RANGE	UNIT
HAEMATOLOGY			
CBC (COMPLETE BLOOD COUNT)			
RBC (Red Blood Cells)	4.80	3.8-6.5	M/uL
Hb (Haemoglobin)	15.1	12-16	gm/dl
HCT (Haematocrit)	42.3	37-54	%
MCV	88.1	76-96	fl
MCH	31.5	27-32	pg
MCHC	35.7	31-36	gm%
TC of WBC	5,500	4500-10500	/cumm
DC of WBC			
Neutrophil (seg)	57	50 - 70	%
Lymphocyte	33	20 - 40	%
Eosinophil	08	1 - 6	%
Monocyte	02	2 - 8	%
Basophil	00	0 - 2	%
Platelets	1.22	1.5-3.5	lakh/cumm
Red Cell Distribution Width (RDW)	11.9	11.5-14.5	fL
ESR (DONE BY AUTO ANALYZER)	08	0-20	mm/hr

IMMUNOLOGY


Blood Group

ABORH

"B" POSITIVE

BIOCHEMISTRY

Plasma Glucose (Fasting)	85	70-110	mg/dl
Plasma Glucose (Post Prandial)	156	100-140	mg/dl
LIPID PROFILE			
Serum Total Cholesterol	152	50-230	mg/dl
Serum HDL Cholesterol Direct	38	30-65	mg/dl


Dr. Sima Kumari

Ph.D (Micro)

M.Sc. (Micro)

Ex. Project Trainee

AIIMS New Delhi (Lab. Medicine Dept.)


Dr. R.K. Narayan

M.D. (Path.)

Regd. No. 14962



Reg. No.- 815

PARASHAR HOSPITAL

(A Unit of Vijayesh Kumar & Sons Pvt Ltd.)

MURLI MANOHAR COMPLEX, KHADI BHANDAR CHOWK, MUZAFFARPUR-842002 (BIHAR)

Mob.: 6200471018, 7992247583 E-mail : parashar.hospital@gmail.com

Date :

PATIENT NAME : SUMIT ANAND

AGE/SEX : 0Y/Adult-M


REF. BY DR. : DR. PARASAR HOSPITAL

REF. NO : 23/08/21CP/49

TEST. DATE : 23/08/2021

RPT. DATE : 23/08/2021

INVESTIGATIONS	VALUE	REF. RANGE	UNIT
Serum Triglycerides	144	25-200	mg/dl
Serum LDL Cholesterol	85.20	85-130	mg/dl
Serum VLDL Cholesterol	28.80	7-32	mg/dl
TC/HDL Cholesterol Ratio	4.00	3.0-5.0	Ratio
LDL/HDL Ratio	2.24:1	1.5-3.5	Ratio
LIVER PROFILE			
Serum Bilirubin			
Total			
Direct	0.8	0.1-1.2	mg%
Indirect	0.4	0-0.3	mg%
Serum SGPT (ALAT)	0.40	0-0.6	mg%
Serum SGOT (ASAT)	46	9-38	IU/L
Alkaline Phosphatase	39	10-40	IU/L
Total Protien	202	80-306	U/L
Protein			
Albumin	7.2	6.0-8.0	g/dl
Globulin	4.0	3.7-5.3	g/dl
A:G Ratio	3.20	2.3-3.6	g/dl
Gamma Glutamyl transferase (GGT)	1.25:1	1.0-2.3	Ratio
RENAL FUNCTION TEST (RFT)	29	9-58	U/L
Serum Creatinine	0.9	0.7-1.4	mg/dl
Blood Urea Nitrogen (Bun)	13.08	7-21	mg/dl
Serum Uric Acid	6.3	3.6-7.7	mg/dl
Serum Calcium (Total)	9.0	8.7-11.0	mg/dl
Blood Urea	28	13-45	mg/dl


Dr. Sima Kumari

Ph.D (Micro)

M.Sc. (Micro)

Ex. Project Trainee

AIIMS New Delhi (Lab. Medicine Dept.)


Dr. R.K. Narayan

M.D. (Path.)

Regd. No. 14962



Reg. No.- 81

PARASHAR HOSPITAL

(A Unit of Vijayesh Kumar & Sons Pvt Ltd.)

MURLI MANOHAR COMPLEX, KHADI BHANDAR CHOWK, MUZAFFARPUR-842002 (BIHAR)

Mob.: 6200471018, 7992247583 E-mail : parashar.hospital@gmail.com

Date :


PATIENT NAME : SUMIT ANAND
AGE/SEX : 0Y/Adult-M
REF. BY DR. : DR. PARASAR HOSPITAL

REF. NO : 23/08/21CP/4

TEST. DATE : 23/08/2021

RPT. DATE : 23/08/2021

INVESTIGATIONS	VALUE	REF. RANGE	UNIT
SERUM ELECTROLYTE			
Sodium (Na)+	142.3	135-150	m mol/L
Potassium (K)+	3.9	3.5-5.1	m mol/L
Chloride (Cl)-	100.9	97-111	m mol/L



Dr. Sima Kumari

Ph.D (Micro)
M.Sc.(Micro)
Ex. Project Trainee
AIIMS New Delhi(Lab. Medicine Dept.)



Dr. R.K. Narayan

M.D.(Path.)
Regd.No.14962



PARASHAR HOSPITAL

(A Unit of Vijayesh Kumar & Sons Pvt Ltd.)

MURLI MANOHAR COMPLEX, KHADI BHANDAR CHOWK, MUZAFFARPUR-842002 (BIHAR)

Mob.: 6200471018, 7992247583 E-mail : parashar.hospital@gmail.com

Date :

PATIENT NAME : SUMIT ANAND

AGE/SEX : 0Y/Adult-M

REF. BY DR. : DR. PARASAR HOSPITAL

REF. NO : 23/08/21CP/49

TEST. DATE : 23/08/2021

RPT. DATE : 23/08/2021


INVESTIGATIONS	VALUE	REF. RANGE	UNIT
----------------	-------	------------	------

HbA1c

5.3

4.2-6.0

Good Diabetic Control 5.5 - 6.8 Fair Control 6.8 - 7.6 Poor Control Above 7.6



Dr. Sima Kumari

Ph.D (Micro)

M.Sc (Micro)

Ex. Project Trainee

AIIMS New Delhi (Lab. Medicine Dept.)


Dr. R.K. Narayan

M.D. (Path.)

Regd. No. 14962



PARASHAR HOSPITAL

Reg. No.- 815

(A Unit of Vijayesh Kumar & Sons Pvt Ltd.)

MURLI MANOHAR COMPLEX, KHADI BHANDAR CHOWK, MUZAFFARPUR-842002 (BIHAR)

Mob.: 6200471018, 7992247583

E-mail: parashar.hospital@gmail.com

Date :

PATIENT NAME : SUMIT ANAND

AGE/SEX : 0Y/Adult-M

REF. BY DR. : DR. PARASAR HOSPITAL

REF. NO : 23/08/21CP/49

TEST. DATE : 23/08/2021

RPT. DATE : 23/08/2021

INVESTIGATIONS	VALUE	REF. RANGE	UNIT
----------------	-------	------------	------

URINE ROUTINE

Physical Examination


Colour	Pale Straw
Appearance	Clear

Chemical Examination

PH	Acidic
Specific Gravity	1.030
Sugar	Negative
Albumin	Negative

Microscopic Examination

Crystal	Nil
RBC	Nil
WBC	6-8/HPF
Epithelial Cells	A Few
Granular Cast	Absent
Bacteria	Absent
Cast	Absent
Other	NIL


Dr. Sima Kumari

Ph.D (Micro)

M.Sc.(Micro)

Ex. Project Trainee

AIIMS New Delhi(Lab.Medicine Dept.)


Dr. R.K. Narayan

M.D.(Path.)

Regd.No. 14962



Reg. No.- 815

PARASHAR HOSPITAL

(A Unit of Vijayesh Kumar & Sons Pvt Ltd.)

MURLI MANOHAR COMPLEX, KHADI BHANDAR CHOWK, MUZAFFARPUR-842002 (BIHAR)

Mob.: 6200471018, 7992247583 E-mail : parashar.hospital@gmail.com

Date :

PATIENT NAME : SUMIT ANAND
AGE/SEX : 35Y/Adult-M
REF. BY DR. : DR. PARASAR HOSPITAL


REF. NO : 24/08/21CP/53
TEST. DATE : 24/08/2021
RPT. DATE : 24/08/2021

INVESTIGATIONS	VALUE	REF. RANGE	UNIT
----------------	-------	------------	------

ROUTINE

Stool Examination.

Colour	Yellow
Consistency	Semi Solid
Reducing Sugar	Nil
Mucus	Nil
Epithelial Cells	NIL
* Occult Blood	Negative
Parasites	Not Found
RBC	Nil
Undigested Food Particles	Absent
WBC	Nil
CYSTS	NIL


Dr. Sima Kumari

Ph.D (Micro)
M.Sc. (Micro)
Ex. Project Trainee
AllMS New Delhi (Lab. Medicine Dept.)


Dr. R.K. Narayan

M.D. (Path.)
Regd. No. 14962



Om

Reg. No.- 815

PARASHAR HOSPITAL

(A Unit of Vijayesh Kumar & Sons Pvt Ltd.)

MURLI MANOHAR COMPLEX, KHADI BHANDAR CHOWK, MUZAFFARPUR-842002 (BIHAR)

Mob.: 6200471018, 7992247583

E-mail : parashar.hospital@gmail.com

Sumit Anand
35/M

Date : 24/08/2021

BP - 130/82

Go: RCL

Chest - clear

HR - ✓

By Montel L
with breath/mms
@ 1

29 A to 2 Cap - 15
1 2/3

[Signature]

2021-08-19 12H-01M

ID: 20210819120159

Name: sumit amand

Age: 35

Sex: Male

Hospital:

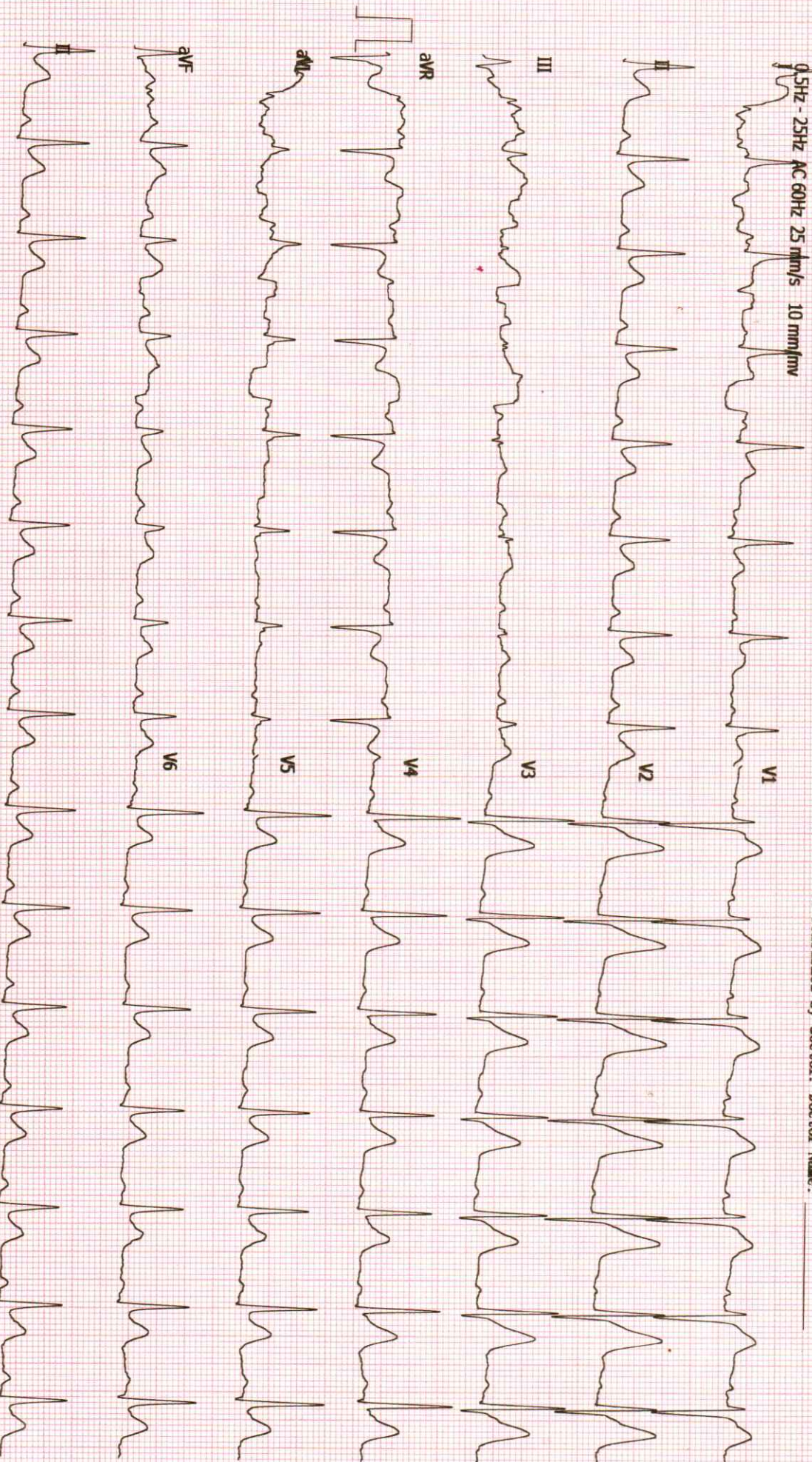
Department:

HR	:	87 bpm
PR	:	150 ms
QRS	:	110 ms
QT/QTc	:	328/394 ms
P/QRS/T:		66/37/56 °
RV5/SV1:		1.320/-1.379 mV
RV5-SV1:		2.699 mV

《 Analysis Result 》
 ** normal ECG **
 Sinus rhythm
 ST elevation

Need to be confirmed by doctor. Doctor Name: _____

0.5Hz - 25Hz AC 60Hz 25 mm/s 10 mm/mv





ANUPAM

ULTRASOUND & COLOR DOPPLER CENTRE

ROAD NO. 1, JURAN CHAPRA, MUZAFFARPUR - 842
Phones : 0621 - 2224133, 9525971756, E-mail : anupct1@gmail.com

Dr. Ajay Jaiswal
MBBS, MRSH

Dr. A. K. S
PGDM (Sono

Thanks for referral

U/S Reg. No- 07/2001 Reg. No- BMR- 16156

Name	: Mr. Sumit Anad	Age/ Sex	: Y/M
Part scanned	: Echocardiography	ID No -	: 397
Refd. by Dr.	: Parashar Hospital Muz.	Date -	: 23.08.2021

ECHOCARDIOGRAM REPORT

2D echo / color doppler studies done in parasternal long and short axis, apical and subcostal view.

The aortic valves are thick. There is no aortic regurgitation. The aorta appears normal and the dimension is 3.15cm. Aortic valve opening dimension 1.98cm in begning and 1.81cm at end. The doppler velocity of aortic valve is 0.71m/sec. The mitral valves are thick. There is no mitral regurgitation, the velocity of mitral valve is 0.56m/sec and valve leaflets excursion (D - DE - 2.04cm, and V - EF - 0.19m/sec).

Tricuspid valve are normal and open fully. There is no tricuspid regurgitation. The doppler velocity of TV is 0.46m/sec.

Pulmonary valve is normal and open fully.

The left atrium is normal and its dimension is 3.42cm. There is no atrial fibrillation seen.

Left ventricle shows hypertrophy of its anterior wall. The dimation of LVC is 4.30cm at the end of diastole.

Left ventricular E/F at rest is about 56%.

Right ventricle is normal and its dimation is 2.73cm. Right atrium is also normal. There is no VSD or ASD seen.

No segemental wall motion abnormality are seen at rest.

There is no intracardiac thrombi or clot seen.

There is no pericardial effusion seen.

On TVI the mean velocity of early systole S early diastole E and Late diastole A wave at basal ant and basal lat wall appears normal.

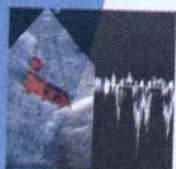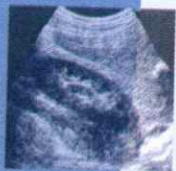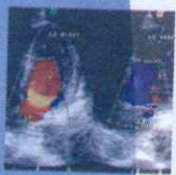
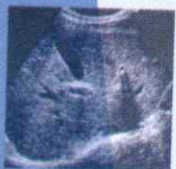M mode measurement : IVSD - 1.33cm, LVIDd - 4.30cm, LVPWd - 1.02cm, IVSs - 1.50 cm, LVIDs - 3.05cm, LVPWs - 1.27m, EDV- 82.91ml, SV - 46.41ml, ESV -36.30ml, EF - 56.22%.

OPINION -- Features of Asymmetrical L.V.H

Sonologist

On request

MRI • ULTRASOUND • COLOR DOPPLER • ELASTOGRAPHY FOR BREAST • ECHO CARDIOGRAPHY • WHOLE BODY CT SCAN



ANUPAM

ULTRASOUND & COLOR DOPPLER CENTRE

ROAD NO. 1, JURAN CHAPRA, MUZAFFARPUR - 842 001

Phones : 0621 - 2224133, 9525971756, E-mail : anupct1@gmail.com

Dr. Ajay Jaiswal
MBBS, MRSH

Dr. A. K. Shahi
PGDM (Sonologist)

Thanks for referral

U/S Reg. No- 07/2001

Reg. No- BMR- 16156

Name : Mr. Sumit Anand
Part scanned : Whole Abdomen
Refd. by Dr. : Parashar Hospital
Muz.

Age/ Sex : Y/M
ID No - : 398
Date/ Time : 23.08.2021

USG OF WHOLE ABDOMEN REPORT

Liver is mild enlarged in size (14 cm), shows fatty infiltration echotexture. There is no focal lesion or dilatation of intrahepatic biliary radicles, portal vein is normal.

Gall bladder shows normal wall thickness and echofree lumen.

C.B.D. is normal in caliber.

Pancreas is normal in size, shape and echotexture.

Spleen is normal in size .

There is no abdominal lymphadenopathy seen.

Both kidneys are normal in size , shape and position. The C.M. differentiation is well maintained and there is no hydronephrosis.

No evidence of ascites/ pleural effusion.

Urinary bladder is smooth in outlined. There is no calculus within.

No collection or mass lesion seen in RIF.

OPINION: Mild Hepatomegaly with Fatty Liver.

On request
Not valid for medico-legal purpose.

Sonologist

Name	: Sumit Anand	Age/ Sex	: Y/M
Part scanned	: X-Ray Chest PA View	Date/Time	: 23.08.2021
Refd.by Dr.	: Parashar Hospital Muz.	ID No-	: 1508

X - RAY REPORT

Lung fields appear clear on both side.

Both CP angles is clear.

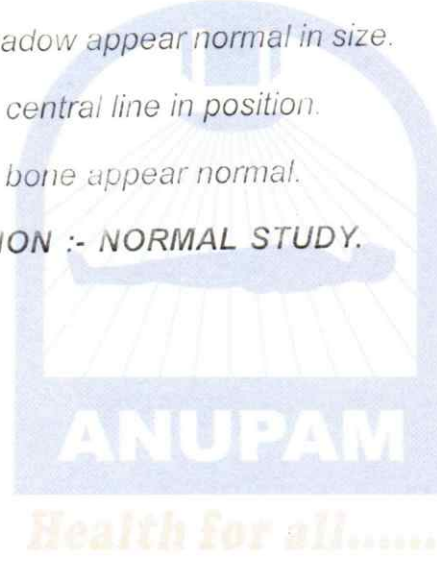
Both hila appear normal.

Cardiac shadow appear normal in size.

Trachea is central line in position.

Visualized bone appear normal.

IMPRESSION :- NORMAL STUDY.



Please correlate clinically.

On request
Not valid for medico-legal purpose.


Dr. Abhitesh Kumar
MBBS, DMRD.
Radiologist.

