

Medical

H
DR. HARI CHHABLANI
M.B.D.S., F.C.C.P. (RESPIRATORY MEDICINE) & D.M. (PCCML)
FELLOW INTENSIVE CARE
MMC REG. NO. - 87702

Neha Gupta

DR. PLUS HEALTHCARE CENTRE
'NATHANI HEIGHTS', B-1
42, MUMBAI CENTRAL (EAST)


29/F



भारत निर्वाचन आयोग
पहचान पत्र

ELECTION COMMISSION OF INDIA
IDENTITY CARD

ZMR1255959

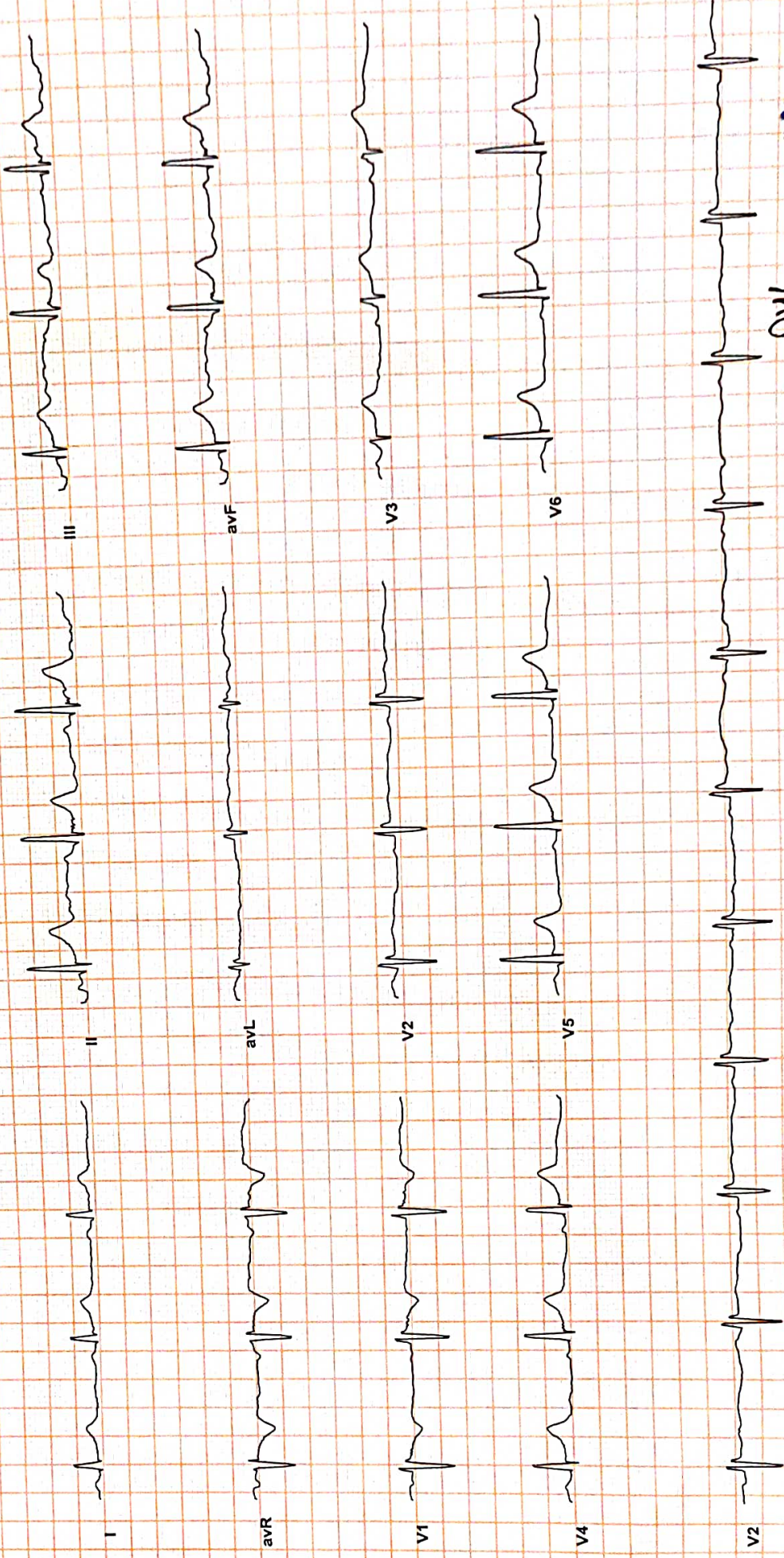


निर्वाचक का नाम : नेहा गुप्ता
Elector's Name : Neha Gupta
पिता का नाम : सुरेश प्रसाद गुप्ता
Father's Name : Suresh Prasad Gupta
लिंग/ Sex : महिला / Female
जन्म की तारीख : 16/07/1992
Date Of Birth :

ECG

DR PLUS HEALTHCARE CENTRE- MUMBAI CENTRAL

1897 / NEHA GUPTA / 29 Yrs / F
Heart Rate : 65 bpm / Tested On : 11-Jun-22 15:15:14 / HF 0.05 Hz - LF 100 Hz / Notch 50 Hz / Sn 1.00 Cm/mV / Sw 25 mm/s



WHL

DR PURVI CHHABLAN
General Medicine
Reported By: DR. PURVI CHHABLAN
General Physician



Dr-Plus Healthcare Centre

NATHANI HEIGHTS, B-Wing, Shop No. 42, Ground Floor, Opp. Mumbai Central Station (East), Mumbai - 400 008.

NAME : NEHA GUPTA

29/F

DATE:11/06/2022

REF BY : SLEF

2D-ECHO. AND COLOR DOPPLER REPORT

- NORMAL CARDIAC VALVES WITH TRIVIAL TR.
- NORMAL CARDIAC CHAMBERS
- NO E/O REGIONAL WALL MOTION ABNORMALITY. WITH NORMAL LVEF OF 62 %.
- NO E/O PULMONARY HYPERTENSION .PASP 32 mmHg by TR jet.
- NO E/O LEFT VENTRICULAR HYPERTROPHY.
- NO E/O DIASTOLIC DYSFUNCTION.
- NO E/O PERICARDIAL EFFUSION.
- NO E/O INTRACARDIAC CLOT OR VEGETATION
- INTACT IAS / IVS
- **CONVENTIONL DOPPLER :**

E TO A RATIO IS MORE THAN ONE IN LV INFLOW.

THERE IS NO GRADIENT ACROSS AV,LVOT OR RVOT

PASP FROM TR JET IS 32 mm OF Hg.

- **COLOUR DOPPLER:**

TRIVIAL TR

EF Slope	102	85-120 mm/sec		
Opening Amplitude	18			
Posterior leaflet				
E.P.S.S	02	mm		
Mitral valve prolapse				
Vegetations				
TRICUSPID VALVE	OBSERVED	NORMAL VALUES		
PULMONARY VALVE	OBSERVED	NORMAL VALUES		
EF Slope				
'A' Wave				
Midsystolic notch				
Flutter				
Other Findings				
AORTIC VALVE	OBSERVE	NORMAL VALUES		
Cuspal opening	16	mm		
Closure line	Central			
Eccentricity index	1			
Other Findings				
DIMENSIONS	OBSERVED	NORMAL VALUES		
1. Lvd (Diastolic)	43	26-52		
2. Lvd (Systolic)	29	24-42mm		
3. RVD (Diastolic)	17	7-23mm		
4. IVST (Diastolic)	07	6-11mm		
5. IVST (Systolic)	14			
6. LVPWT (Diastolic)	08	6-11mm		
7. LVPWT (Systolic)	15			
8. Aortic root	32	22-37mm		
9. left Atrium	26	19-40mm		
	STRUCTURE	REGURGRADING	VELOCITY m/sec	STENOSIS GRADIENT mm/Hg
			Max mean	Peak mean
MITRAL VALVE	NORMAL	0/3	/	/
TRICUSPID VELVE	NORMAL	TRIVIAL	/	/
PULMONARY VELVE	NORMAL	0/4	/	/
AORTIV VALVE	NORMAL	0/4	/	/

Dr.
DR.P.H.CHHABLANI
M.B.B.S, DNB.(MEDICINE)
CONSULTANT PHYSICIAN AND CARDIOLOGIST.

DR. PURVI CHHABLANI

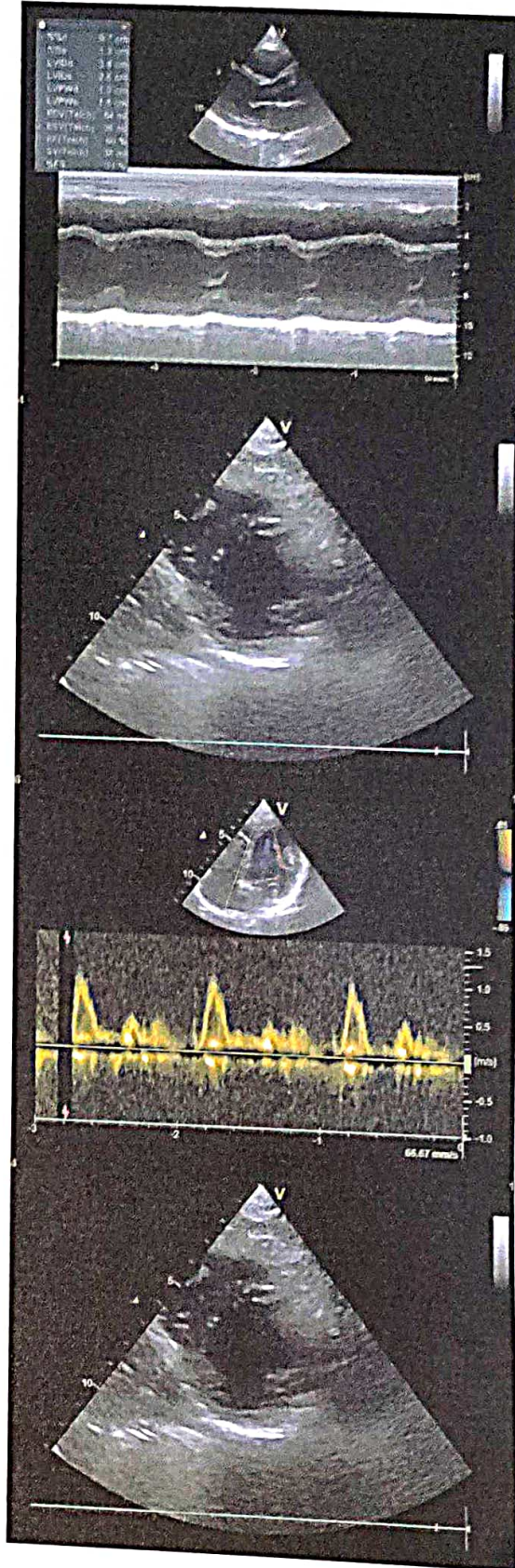
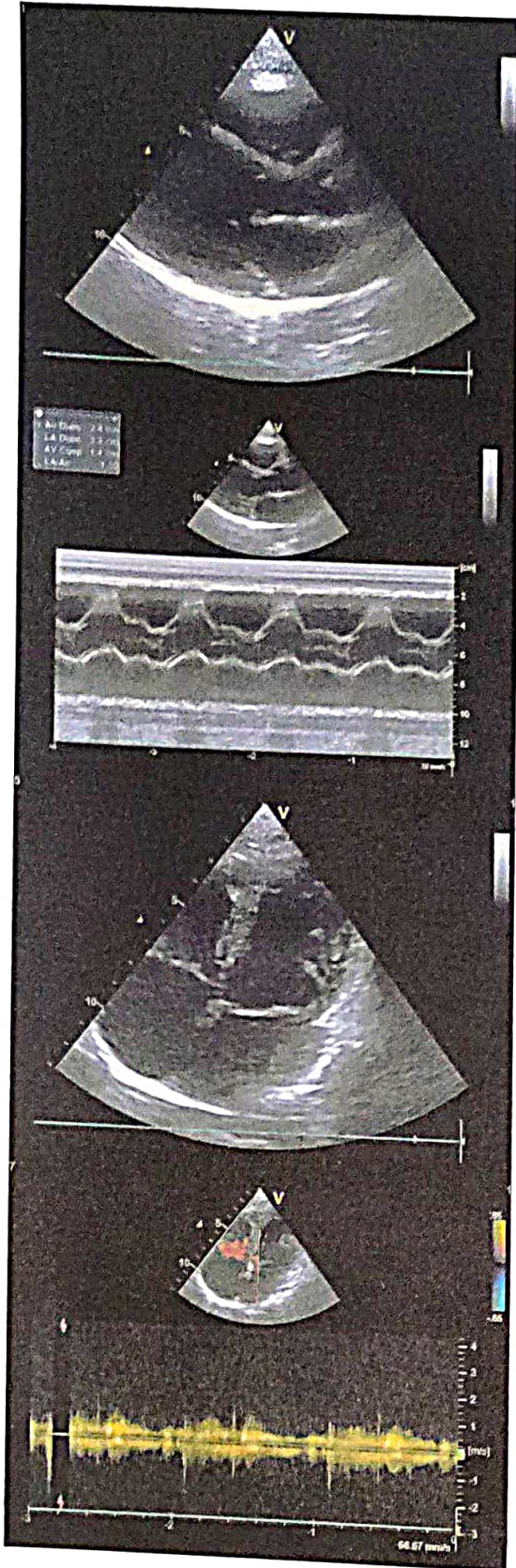
M.B.B.S, DNB (Medicine)
Consultant Physician And Intensive
Reg No 77696

Name NEHA GUPTA

Sex Female

Age 29

[127]





Dr-Plus Healthcare Centre

NATHANI HEIGHTS, B-Wing, Shop No. 42, Ground Floor, Opp. Mumbai Central Station (East), Mumbai - 400 008.

Patient Name	:	NEHA GUPTA	Sex:	FEMALE
Doctor's Name	:	DR. HARI CHHABLANI	Age:	29
Date	:	11/06/2022		

ULTRASONOGRAPHY OF THE ABDOMEN AND THE PELVIS:

The relevant sonographic findings include the following:

HEPATOBIILIARY APPARATUS

The liver is normal in size and echogenicity. No obvious focal parenchymal lesion is seen. Intrahepatic biliary radicals are not dilated.

The portal vein and the common bile duct are normal.

GALL BLADDER

The gall bladder is adequately distended. The wall thickness is normal.

No echogenic contents are noted in its lumen. There is no pericholecystic collection noted.

PANCREAS

The pancreas shows normal echogenicity and size.

No focal or diffuse lesions are noted. No evidence of calcification is noted.

SPLEEN

The spleen appears normal in size and echogenicity.

No focal or diffuse lesions are noted. No evidence of calcification is noted.

KIDNEYS

Right kidney measures 9.7 x 4.6 cm, Left kidney measures : 10.1 x 5.0 cm.

Both the kidneys appear normal in size, shape and echogenicity. Both the pelvicalyceal system is normal and both corticomedullary differentiations are well maintained. There is no obvious focal or diffuse lesion noted.

No evidence of any calculus seen in either kidney.

URINARY BLADDER

The urinary bladder shows anechoic contents. Its wall thickness appears normal.

UTERUS

Uterus measures = 5.9 x 2.4 x 3.52 cms.

The uterus is anteverted and normal in size. There are no focal or diffuse lesions noted.

The endometrium appears normal (6.2 mm).

OVARIES

Both the ovaries appear normal in size.

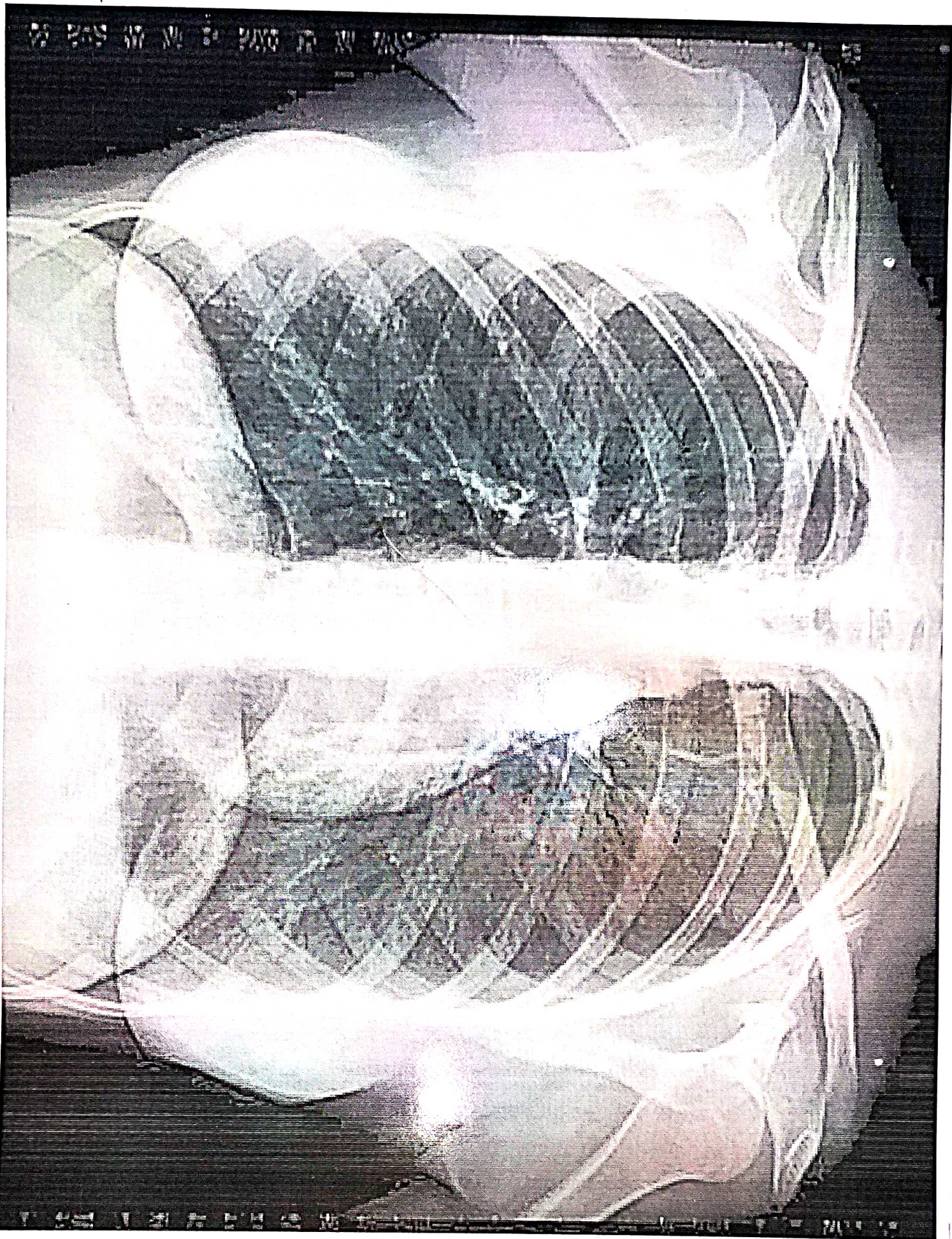
Right ovary measures :4.9 x 3.4 Cm, Left ovary measures :4.3 x 3.2 cm

There is no obvious evidence of abdominal or pelvic lymphadenopathy or ascites.
No other obvious pelvic mass is seen. No probe-tenderness is noted.

IMPRESSION: No significant abnormality is detected.


Dr. Parag Jhaveri
MBBS (BOM), DMRE(BOM)
Radio-Sonologist

DR. PLUS HEALTHCARE CENTRE
NATHANI HEIGHTS, B-WING
42, MUMBAI CENTRAL (EAST)



NEHA GUPTA

29/F

11/08/22



Patient's Name : NEHA GUPTA

Report Date : 11/06/2022

Referred By : SELF

Age : 29 Years

Sex : FEMALE

X- RAY CHEST

BOTH THE LUNG FIELED ARE CLEAR.

THE HILAR SHADOWS APPEAR NORMAL.

THE COSTO-PHRENIC ANGELS ARE CLEAR.

THE CARDIAC SHADOWS APPEAR NORMAL.

THE TRACHEAL IS CENTRAL IN POSITION.

THE BONY CAGE APPEARS NORMAL.


DR. A. J. MAZUMDAR

MD. DMRE, MDRD

'DR. PLUS HEALTHCARE CENTRE'
NATHANI HEIGHTS, B-WING.
42, MUMBAI CENTRAL (EAST)



Dr-Plus Healthcare Centre

NATHANI HEIGHTS, B-Wing, Shop No. 42, Ground Floor, Opp. Mumbai Central Station (East), Mumbai - 400 008.

Full Name **NEHA GUPTA** 29/F 11/06/2022
Life to be assured:

	Type of Test	Actual Reading	Normal Range
1	Fasting Blood Sugar	8762	70-100 mg%
2	PPBS	121.4	110 TO 140 mg%
3	Total Cholesterol	184.5	120-200 mg%
4	VERY LOW DENSINTY LEVEL(VLDL)	14.6	10-30 mg/dl
5	High Density Lipid (HDL)	47.6	40-60 mg%
6	Low Density Lipid (LDL)	122.3	Upto 150
7	S. Triglycerides	115.1	50-150 mg%
8	CHOL/HDL	3.8	Upto 5
9	HDL/LDL	0.3	
10	S. Creatinine	0.7	0.5-1.2 mg%
11	Blood Urea Nitrogen (BUN)	18.6	7-21 mg%
12	BUN/CREAT RATIO	26.5	
13	S. Proteins	6.7	6.0-7.9 mg%
14	(a) Albumin	3.5	3.5-5.5 mg%
15	(b) Globulin	3.2	2.0-3.5 mg%
16	A/G RATIO	1.0	
17	S. Bilirubin	0.9	0.3-1.3mg%
18	(a) Direct	0.5	0.0-0.8 mg%
19	(b) Indirect	0.4	0.0-0.5 mg%
20	SGOT (AST)	24.8	05-34 IU
21	SGPT (ALT)	30.5	05-40 IU
22	GGTP (GGT)	44.6	05-50 IU
23	SGOT/SGPT	0.8	
24	HBA1C	5.2	UPTO 6.5
25	S. Alkaline Phosphatase	108.3	30-115 IU
26	T3	123.8	80-180ng/dl
27	T4	4.8	4.6-12 ug/dl
28	TSH	2.4	0.4-4.0 mIU/L
29	SERUM URIC ACID	4.5	2.5-7.2mg/dl
30	URINE SUGAR PP	ABSENT	
31	URINE SUGAR FASTING	ABSENT	
32	BLOOD GROUP	"A POSITIVE "	

DR. RAKESH PATKAR
M.B.B.S. (Pathology)
2013/15/1060



Dr-Plus Healthcare Centre

NATHANI HEIGHTS, B-Wing, Shop No. 42, Ground Floor, Opp. Mumbai Central Station (East), Mumbai - 400 008.

Full Name

NEHA GUPTA

29/F

11/06/2022

Life to be assured:

HAEMOGRAM

Normal Range

1.	Red Blood Cell Count	3.7	[M : 4.5 - 5.6 / F : 3.5 - 5.5/cu.mm]
2.	Hb%	11.8	[M: 14-18 / F : 11-16%]
3.	Hematocrit	39.8	[M : 40-53 / F : 30-47 %]
4.	Indices:		
(a)	MCV(Mean Corpuscular Volume)	92.5	[79-101 cu.mi.]
(b)	MCH(Mean Corpuscular Hb)	31.3	[27-32 pg]
(c)	MCHC(Mean Corpuscular Hb Concentration)	32.3	[32-38%]
5.	Morphology		
	Macrocytes : --	Microcytes: --	Hypochromia: --
	Piokilocytosis: --	Anisocytosis: --	
6.	Target cells: --		
	Spherocytes: --	Elliptocytes: --	
7.	TOTALW.B.C.Count	6,200	{4000-11000/cu.mm}
Differential Count0			
a)	Neutrophils :	56	[45 -70%]
b)	Lymphocytes :	37	[20 - 45%
c)	Eosinophils:	04	[01 - 06%]
d)	Monocytes:	02	[00 - 08%]
e)	Basophils :	01	[00 - 01%]
8.	Platelets :2.9	1.5-4.5 Lacks/cu.mm	
9.	Erythrocyte Sedimentation Rate:14	20 mm at end of 1 hour	
		Method : Westergrens	

ROUTINE URINE EXAMINATION (RUA)

1. Physical Examination:


(i)	Colour:	YELLOW	(ii)	Sediment:	CLEAR
(iii)	Transparency:	ABSENT	(iv)	Reaction:	ACIDIC
(v)	Specific gravity	1.015			

2. Chemical Examination:

(i)	Protein :	ABSENT	(ii)	Sugar:	ABSENT
(iii)	Bile salt:	ABSENT	(iv)	Bile pigment:	ABSENT

3. Microscopic Examination:

(i)	Red Blood Cells:	ABSENT	(ii)	Epithelial Cells:	ABSENT
(iii)	Crystals:	ABSENT	(iv)	Pus Cells:	01TO 02/HPF
(v)	Casts:	ABSENT	(vi)	Deposits:	ABSENT
(vii)	Bacteria's :	ABSENT			

DR.  PATKAR
M.D., N.B. (Pathology)
Reg. No. 2913/05/1669



Dr. Hari Chhablani

Cardiometabolic Physician & Intensivist
M.B.B.S., F.C.C.P. (RESP. MED.), PGDHHM,
PGDMLS, FELLOW INTENSIVE CARE MED.

ATTACHED TO : Wockhardt Hospital • Saifee Hospital • Apollo Spectra Hospital

NATHANI HEIGHTS, B-Wing, Shop No. 42, Ground Floor, Opp. Mumbai Central Station (East),
Mumbai - 400 008. • Cell : 98206 46163 • E : drharichhablani@gmail.com

PHYSICIAN REPORT

DATE : 11/06/2022

NAME : NEHA GUPTA 29/F

PRESENTING COMPLAINS : K/C/O- ULCERATIVE COLITIS SINCE -2018 .
- GETS SEVERE ALLERGIC REACTIONS TO HEAT

TREATMENT : NIL

PAST HISTORY : COVID POSITIVE MAY - 2021 .
BOTH EYE LASIK DONE .

FAMILY HISTORY: NOT SIGNIFICANT

HABITS : NIL.

DENTAL EXAMINATION: NAD

HT.- 156 CM. WT.-70 Kg.

P: 66/MIN ., REGULAR

BP: 110/74

RS: CLEAR CVS: S1,S2 REGULAR

PA: SOFT

CNS: CLINICALLY NAD

EYE EXAMINATION : NEAR VISION -B/E 86 , DISTANT VISION -BE-- 6/12 , COLOUR VISION - NORMAL

LABS: ATTACHED

ECG: WNL

CHEST X-RAY :WNL

SONOGRAPHY : ATTACHED

2-D- ECHO : ATTACHED

IMPRESSION : REFER TO GASTROENTROLOGIST .


DR.HARI CHHABLANI

DR HARI CHHABLANI
M.B.B.S., F.C.C.P. (RESP. MED.), PGDHHM,
PGDMLS, FELLOW INTENSIVE CARE
MMC REG. NO. - 91702