

**DAKSH HOSPITAL**

396 - 397, Gandhi Nagar, Scheme No. 8, ALWAR -301001

Ref. No.

Date.....

MEDICAL EXAMINATION REPORT  
Mediwheel (BOB)

Name: Mrs. Priyanka Jain Age: 31 yrs Sex: Female Date: 25/12/2023

General Physical Examination

Height	: 157 cm	Weight	: 70 kg
Pulse	: 94 /mt	BP	: 100/60 mm/hg
Respiration	: 18 /mt	BMI	: 28.4 kg/m <sup>2</sup>

Systemic Exam:- NORMALDental Check up :- NORMALEye check-up :- NORMALSkin Check up:- NORMALENT Check up:- NORMALGynae Check up:-Omenline 7days -  
MC - SkynAn - P, Fch es  
LP 3 TynUSG Jorh 15  
JhImpression:- Ref to Gynae for ProgessDr. MONIKA GUPTA  
M.S. (GYANE & OBST)  
DAKSH HOSPITAL, ALWAR  
REG. No. 5519/17472Recommendation:-Dr. Mukesh Kumar Gupta  
MD Gen. Medicine  
Reg. No 5423/16262डॉ० मुकेश गुप्ता  
M.D.F.C.C.S.फिजिशियन एवं मधुमेह रोग विशेषज्ञ  
दक्ष हॉस्पिटल, अलवर  
रजि० नं०-5423/16262

## Results

Run Date 25/12/2023 09:32:57 AM

Operator DAKSH

Last Name

Sample ID 3

First Name MRS PRIYANKA JAIN

Department

Gender Female Age

Physician DR. MUKESH GUPTA M.D

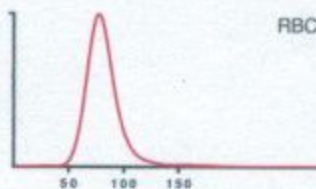
Patient ID AUTO\_PID18488

Type Woman

Date of birth

Sample comments

			Range
RBC	5.09	10 <sup>6</sup> /μL	3.80 - 5.50
HGB	13.7	g/dL	11.5 - 15.2
HCT	41.8	%	35.0 - 46.0
MCV	82.2	μm <sup>3</sup>	77.0 - 97.0
MCH	26.9	pg	26.0 - 34.0
MCHC	32.7	g/dL	32.0 - 35.0
RDW-CV	15.7	%	11.0 - 17.0
RDW-SD	50.0 h	μm <sup>3</sup>	37.0 - 49.0



RBC

### Recommended actions

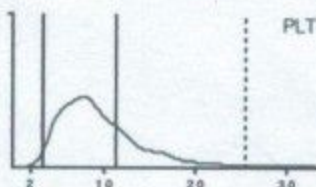
Slide review

### Susp. Pathologies

Leukocytosis

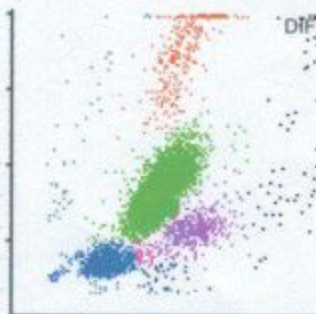
Neutrophilia

			Range
PLT	274	10 <sup>3</sup> /μL	150 - 450
PCT	0.25	%	0.15 - 0.40
MPV	9.3	μm <sup>3</sup>	8.0 - 11.0
PDW	14.0	μm <sup>3</sup>	11.0 - 22.0
P-LCC	71	10 <sup>3</sup> /μL	44 - 140
P-LCR	25.9	%	18.0 - 50.0



PLT

			Range
WBC	14.55 H	10 <sup>3</sup> /μL	3.50 - 10.00
	#	Range	%
NEU	10.29 H	1.60 - 7.00	71.3
LYM	3.22 h	1.00 - 3.00	22.3
MON	0.28	0.20 - 0.80	1.9 l
EOS	0.54 h	0.00 - 0.50	3.7
BAS	0.12	0.00 - 0.15	0.8
LIC	0.10	0.00 - 0.10	0.7



DIFF

Dr. R.S. GUPTA  
MD (Pathology) (MAHE)  
RMC No. 7924/19778



Date :-25/12/2023

Name :- MRS PRIYANKA JAIN

Age &amp; Sex :- 31 Yrs/female

Refd. :- Dr Mukesh Gupta M.D.

	TEST NAME	RESULT	REFERENCE RANGE	
	ESR		12 00 -20 mm/hrs	
	Blood Group & Rh Factor	A POSITIVE		
	HbA1C	4.6	4 - 5.6%	
	Blood Sugar (F)	89.1	< 70 - 100 mg/dl	
	Blood Sugar (PP)	101.1	< 140 mg/dl	
	Urine Sugar (F)	NIL	-	
	Urine Sugar (PP)	NIL	-	
<b>LIVER</b>	S.Bilirubin Total	0.90	0.30 - 1.20 mg/dl	
	S.Bilirubin Direct	0.20	0.10 - 0.30 mg/dl	
	S.Bilirubin Indirect	0.70	0.30 - 0.90 mg/dl	
	S.G.O.T.	24	> 37 u/l	
	S.G.P.T.	35	> 40 u/l	
	S.Alk. Phosp.	180	80 - 306 u/l	
	G.G.T.	25.1	5 -40 u/l	
	Total Protein	6.8	6.5 - 8.5 gm/dl	
	Albumin	3.7	3.8 - 5.4 gm/dl	
	Globulin	3.1	2.3 - 3.5 gm/dl	
	A/G Ratio	1.2	-	
	AST/ALT Ratio	0.7	-	
<b>KIDNEY</b>	Blood Urea	27.1	15 -45 mg/dl	
	S.Creatinine	0.95	0.60 - 1.30 mg/dl	
	BUN	17.0	6 -24 mg/dl	
	S.Uric Acid	5.2	M 3.1 - 7.0, F 2.5 - 5.6 mg/dl	
	BUN/Creatinine Ratio	17.01	-	
<b>LIPID PROFILE</b>	Total Cholesterol	155.1	Up to 200 mg/dl	
	S.HDL	41.1	30 - 70 mg/dl	
	S.LDL	82.1	Up to 170 mg/dl	
	S.VLDL	32.1	5.0 - 40 mg/dl	
	S. Triglycerides	160.1	Up to 170 mg/dl	
	LDL/HDL Ratio	2	-	
	Total Cholesterol/ HDL Ratio	3.7	-	
<b>THYROID</b>	T3	129.1	40 - 181 ng/dl	
	T4	7.5	4.6 - 10.5 µg/dl	
	TSH	1.48	0.30 - 5.0 mIU/L	
		<b>URINE EXAMINATION</b>	<b>Microscopic Examination :</b>	
<b>General/Chemical Examination:</b>	Colour	Pale Yellow	RBC	Absent
	Reaction	Acidic	WBC	1 -2
	Specific Gravity	QNS	Epithelial Cells	0- 1
	Appearance	S.TURBID	Cast	Absent
	Albumin	Nil	Crystal	Absent
	Sugar	Nil	Spermatozoa	Absent
			Amorphous Sediments	Absent
		Other	Absent	
<b>X-RAY CHEST</b>	NORMAL STUDY			
		<b>STOOL EXAMINATION</b>	<b>Microscopic Examination :</b>	
<b>General/ Chemical Examination:</b>	Colour	-	RBC	-
	Consistency	-	WBC	-
	PH	-	Ova & Parasites	-
	Reducing Substances	-		

Dr. R.S. GUPTA  
MD (Pathology) (MAHE)  
RMC No. 7924/19778

TECHNOLOGIST

All investigation have their own limitations regarding the sensitivity & specificity of individual assay procedures, Isolated laboratory investigations never confirm the final diagnosis of the disease. They only help in arriving at a diagnosis in conjunction with clinical presentation and other related investigations. Report is not valid for medico-legal purpose subject to ALWAR jurisdiction only.



Date :- 25/12/2023

Name :- Mrs. Priyanka Jain

Refd. :- Dr Mukesh Gupta MD

Age &amp; Sex :- 31Yrs/ Female

## CYTO-PATHOLOGY

### PAP SMEAR

1. Specimen type	Received two conventional smears.
2. Specimen adequacy	Smears are satisfactory for evaluation.
3. Microscopic finding	Smears are moderately cellular comprises of predominantly intermediate with mature superficial squamous epithelial cells arranged in clusters & scattered singly.
4. Inflammation	Not seen
5. Bacilli	Not seen
6. Endocervical cells	Not seen
7. Koilocytic changes	Not seen
8. Trichomonas	Not seen
9. Dysplasia	Nil
10. Neoplasia	Nil
11. Endometrial cells	Nil

**Impression:-** Negative for intraepithelial lesion or malignancy



Dr. R.S. GUPTA  
MD (Pathology) (MAHE)  
RMC No. 7924/19778

Doctor

  
TECHNOLOGIST

All investigation have their own limitations regarding the sensitivity & specificity of individual assay procedures. Isolated laboratory investigations never confirm the final diagnosis of the disease. They only help in arriving at a diagnosis in conjunction with clinical presentation and other related investigations. Report is not valid for medico-legal purpose subject to ALWAR jurisdiction only.



# दक्ष हॉस्पिटल

396, गाँधी नगर स्कीम नं.8, अलवर (राज०) ☎ 0144-2703340

## Sonography / 2D Echo Cardiography / Doppler Report

NAME :- MRS PRIYANKA/F/31 YRS

25-Dec-23

BOB HEALTH CHECKUP

### U.S.G. OF ABDOMEN (up Abdomen)

#### LIVER

Liver is 14.7 cm vertically with normal echo-texture. Intra hepatic biliary radicals Are not dilated. No evidence of focal or diffuse lesion.

#### GALL BLADDER

Gall bladder is normal.

#### PANCREAS

Pancreas is normal in size, shape & echo-texture. No evidence of focal or diffuse lesion. MPD not dilated.

#### SPLEEN

8.9 cm in size with normal shape & echo- texture. Spleen vein is normal. No evidence of focal or diffuse lesion

#### KIDNEY

Both kidneys are normal.

Advice- follow up/ hormonal study review at higher center for confirmation

Please correlate clinically. USG accuracy is 95 % due to technical limitations as well as inaccuracies inherent in the laboratory and statistical analysis biological process. This report is not valid for medico-legal cases

  
DR. MUKESH GUPTA  
SONOLOGIST

Dr. Mukesh Kumar Gupta  
Physician & Sonologist  
RM 5423/16262



"भ्रूण लिंग परीक्षण की शिकायत  
104 टोल फ्री सेवा पर भी की  
जा सकती है"

भ्रूण लिंग परीक्षण की शिकायत 104 टोल फ्री सेवा पर भी की जा सकती है।





# दक्ष हॉस्पिटल

396, गाँधी नगर स्कीम नं.8, अलवर (राज०) ☎ 0144-2703340

## Sonography / 2D Echo Cardiography / Doppler Report

### 2D/ ECHO REPORT

Name: - Mrs PRIYANKA

Age: - 31 Yrs

Date: - 25-Dec-23

Reg. No.: - Alw/2009/04

BOB health checkup

PROCEDURES:

M-MODE/2D/DOPPLER/COLOR/CONTRASTB.A.S. M<sup>2</sup>

MEASUREMENT:		DOPPLER:	
AOD	20.7	NORMAL (20- 37mm)	MV 0.6 (0.8- 1.3)
LA	23.9	(19- 40mm)	AV 1.4 (1.2- 1.8)
AVO	14.9	(12- 25mm)	TV 0.6 (0.3- 0.8)
RVDd.	11.6	(03- 09mm)	PV 0.8 (0.7- 1.1)
LVDd	44	(37- 56mm)	MITRAL VALVE-
LVDs	25.9	(22- 40mm)	AML Normal
IVS d	5.8	(06- 12mm)	PML Normal
IVS s	12.9		
PWd	3.9	(05- 10mm)	AORTIC VALVE Normal
LV FUNCTION		TV & PV are normal.	
M- E- S Separation		<0.9cm	
Minor		24.42%	
LV Ejection Fraction	72%	65 +/- 12%	

LV WALL MOTION: NO RWMA  
ALL CARDIAC CHAMBERS ARE NORMAL  
ALL VALVES ARE NORMAL  
NO CLOT, VEGETATION, PERICARDIAL EFFUSION

FINAL DIAGNOSIS: NORMAL STUDY

Adv: - Follow up/ review at higher center for confirmation

Note:- Please Correlate clinically. Due to technical limitations as well as inaccuracies inherent in the laboratory and statistical analysis of biological process. Diagnostic accuracy of ECHO is up to 95% only.  
Report is not valid for medico-legal purpose.

  
DR. MUKESH GUPTA Gupta  
PHYSICIAN  
Physician & Sonologist  
RM 5423/16262



"भ्रूण लिंग परीक्षण की शिकायत  
104 टोल फ्री सेवा पर भी की  
जा सकती है"

भ्रूण लिंग परीक्षण की शिकायत 104 टोल फ्री सेवा पर भी की जा सकती है।



ID: 208

25-12-2023 12:02:02

Male      Years

Req. No. :

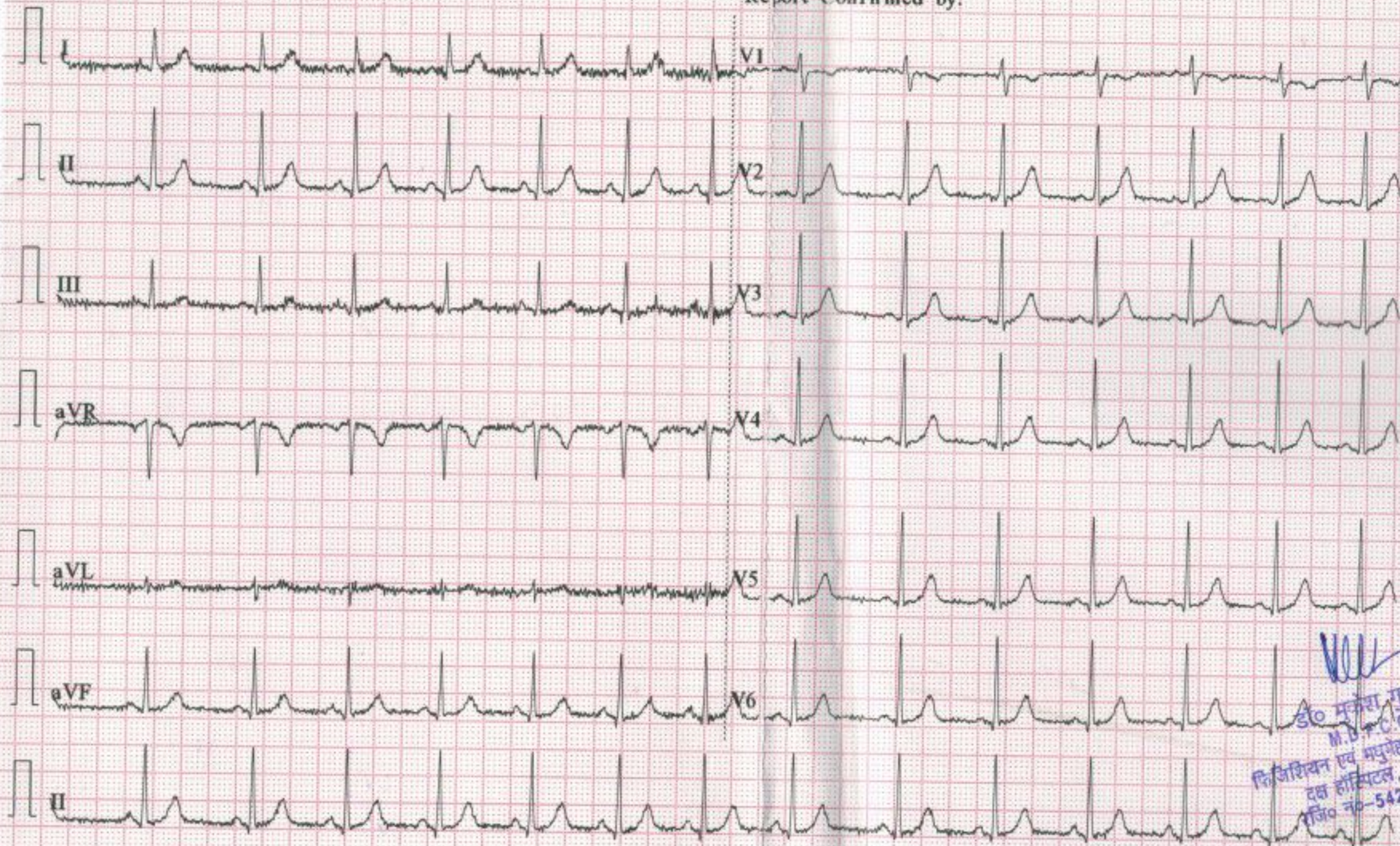
HR : 86 bpm  
 P : 92 ms  
 PR : 124 ms  
 QRS : 78 ms  
 QT/QTcBz : 344/412 ms  
 P/QRS/T : 63/62/48 °  
 RV5/SV1 : 1.591/0.352 mV

Diagnosis Information:

Sinus arrhythmia

Normal ECG

Report Confirmed by:



*[Signature]*  
 डॉ० मनीषा गुप्ता  
 M.D. P.C.C.S.  
 कि.जि.शिवन एंव मधुमेह रोग विशेषज्ञ  
 दक्ष हॉस्पिटल, अलवर  
 फ़ोन नं०-5423/16262



2191

R

