

Patient Name : Mrs.PANTHANGI SRIJA	Collected : 26/Oct/2024 10:15AM
Age/Gender : 30 Y 6 M 10 D/F	Received : 26/Oct/2024 12:35PM
UHID/MR No : CJPN.0000098730	Reported : 26/Oct/2024 02:46PM
Visit ID : CJPNOPV210669	Status : Final Report
Ref Doctor : Self	Sponsor Name : ARCOFEMI HEALTHCARE LIMITED
Emp/Auth/TPA ID : 22S33466	

DEPARTMENT OF HAEMATOLOGY

ARCOFEMI - MEDIWHEEL - FULL BODY HEALTH ANNUAL PLUS CHECK - FEMALE - 2D ECHO - PAN INDIA - FY2324

Test Name	Result	Unit	Bio. Ref. Interval	Method
HEMOGRAM , WHOLE BLOOD EDTA				
HAEMOGLOBIN	9.6	g/dL	12-15	Spectrophotometer
PCV	30.20	%	36-46	Electronic pulse & Calculation
RBC COUNT	4.28	Million/cu.mm	3.8-4.8	Electrical Impedance
MCV	71	fL	83-101	Calculated
MCH	22.4	pg	27-32	Calculated
MCHC	31.7	g/dL	31.5-34.5	Calculated
R.D.W	17.5	%	11.6-14	Calculated
TOTAL LEUCOCYTE COUNT (TLC)	9,100	cells/cu.mm	4000-10000	Electrical Impedance
DIFFERENTIAL LEUCOCYTIC COUNT (DLC)				
NEUTROPHILS	55.8	%	40-80	Electrical Impedance
LYMPHOCYTES	34.4	%	20-40	Electrical Impedance
EOSINOPHILS	6.3	%	1-6	Electrical Impedance
MONOCYTES	3.4	%	2-10	Electrical Impedance
BASOPHILS	0.1	%	<1-2	Electrical Impedance
ABSOLUTE LEUCOCYTE COUNT				
NEUTROPHILS	5077.8	Cells/cu.mm	2000-7000	Calculated
LYMPHOCYTES	3130.4	Cells/cu.mm	1000-3000	Calculated
EOSINOPHILS	573.3	Cells/cu.mm	20-500	Calculated
MONOCYTES	309.4	Cells/cu.mm	200-1000	Calculated
BASOPHILS	9.1	Cells/cu.mm	0-100	Calculated
Neutrophil lymphocyte ratio (NLR)	1.62		0.78- 3.53	Calculated
PLATELET COUNT	538000	cells/cu.mm	150000-410000	Electrical impedance
ERYTHROCYTE SEDIMENTATION RATE (ESR)	34	mm at the end of 1 hour	0-20	Modified Westergren
PERIPHERAL SMEAR				

RBCs: are predominantly normocytic normochromic with good proportion of microcytic hypochromic RBCs. Few elliptocytes seen. No nucleated RBCs or inclusions.

WBCs: are normal in total number with normal distribution and morphology.

Dr. Vidya Aniket Gore
M.B.B.S,M.D(Pathology)
Consultant Pathologist

Dr Priya Murthy
M.B.B.S,M.D(Pathology)
Consultant Pathologist



Patient Name : Mrs.PANTHANGI SRIJA	Collected : 26/Oct/2024 10:15AM
Age/Gender : 30 Y 6 M 10 D/F	Received : 26/Oct/2024 12:35PM
UHID/MR No : CJPN.0000098730	Reported : 26/Oct/2024 02:46PM
Visit ID : CJPNOPV210669	Status : Final Report
Ref Doctor : Self	Sponsor Name : ARCOFEMI HEALTHCARE LIMITED
Emp/Auth/TPA ID : 22S33466	

DEPARTMENT OF HAEMATOLOGY

ARCOFEMI - MEDIWHEEL - FULL BODY HEALTH ANNUAL PLUS CHECK - FEMALE - 2D ECHO - PAN INDIA - FY2324

PLATELETS: appear adequate in number.


HEMOPARASITES: negative

IMPRESSION: DIMORPHIC ANEMIA (NORMOCYTIC NORMOCHROMIC + MICROCYTIC HYPOCHROMIC).

Note: Kindly evaluate for incipient iron deficiency.



Dr. Vidya Aniket Gore
M.B.B.S,M.D(Pathology)
Consultant Pathologist



Dr Priya Murthy
M.B.B.S,M.D(Pathology)
Consultant Pathologist



Patient Name : Mrs.PANTHANGI SRIJA	Collected : 26/Oct/2024 10:15AM
Age/Gender : 30 Y 6 M 10 D/F	Received : 26/Oct/2024 02:08PM
UHID/MR No : CJPN.0000098730	Reported : 26/Oct/2024 03:28PM
Visit ID : CJPNOPV210669	Status : Final Report
Ref Doctor : Self	Sponsor Name : ARCOFEMI HEALTHCARE LIMITED
Emp/Auth/TPA ID : 22S33466	

DEPARTMENT OF BIOCHEMISTRY

ARCOFEMI - MEDIWHEEL - FULL BODY HEALTH ANNUAL PLUS CHECK - FEMALE - 2D ECHO - PAN INDIA - FY2324

Test Name	Result	Unit	Bio. Ref. Interval	Method
HBA1C (GLYCATED HEMOGLOBIN) , WHOLE BLOOD EDTA				
HBA1C, GLYCATED HEMOGLOBIN	5.6	%		HPLC
ESTIMATED AVERAGE GLUCOSE (eAG)	114	mg/dL		Calculated

Comment:

Reference Range as per American Diabetes Association (ADA) 2023 Guidelines:

REFERENCE GROUP	HBA1C %
NON DIABETIC	<5.7
PREDIABETES	5.7 – 6.4
DIABETES	≥ 6.5
DIABETICS	
EXCELLENT CONTROL	6 – 7
FAIR TO GOOD CONTROL	7 – 8
UNSATISFACTORY CONTROL	8 – 10
POOR CONTROL	>10

Note: Dietary preparation or fasting is not required.

1. HbA1c is recommended by American Diabetes Association for Diagnosing Diabetes and monitoring Glycemic Control by American Diabetes Association guidelines 2023.

2. Trends in HbA1c values is a better indicator of Glycemic control than a single test.

3. Low HbA1c in Non-Diabetic patients are associated with Anemia (Iron Deficiency/Hemolytic), Liver Disorders, Chronic Kidney Disease. Clinical Correlation is advised in interpretation of low Values.

4. Falsely low HbA1c (below 4%) may be observed in patients with clinical conditions that shorten erythrocyte life span or decrease mean erythrocyte age. HbA1c may not accurately reflect glycemic control when clinical conditions that affect erythrocyte survival are present.

5. In cases of Interference of Hemoglobin variants in HbA1c, alternative methods (Fructosamine) estimation is recommended for Glycemic Control

A: HbF >25%

B: Homozygous Hemoglobinopathy.

(Hb Electrophoresis is recommended method for detection of Hemoglobinopathy)

Dr.Govinda Raju N L
MSc,PhD(Biochemistry)
Consultant Biochemistry

Dr Priya Murthy
M.B.B.S,M.D(Pathology)
Consultant Pathologist



SIN No: JPR241003052

This test has been performed at Apollo Health & Lifestyle Ltd, RRL BANGALORE Laboratory.

APOLLO HEALTH AND LIFESTYLE LIMITED | APOLLO HEALTH AND LIFESTYLE LIMITED - RRL BANGALORE

APOLLO Health and Lifestyle Limited | Apollo Health and Lifestyle Limited - RRL BANGALORE

Regd. Office: 10/22/20, Anand Nagar, 4th Cross, 4th Stage, 4th Cross, Anand Nagar, Hyderabad, Telangana - 500016 |

www.apolloclinics.com | Email ID: enquiry@apolloclinics.com, Ph: No: 043-9664 7777, Fax No: 4664 7766

APOLLO CLINICS NETWORK

Telangana: Hyderabad | Andhra Pradesh: Vizag | Karnataka: Bangalore | Kerala: Kochi | Maharashtra: Mumbai | Odisha: Bhubaneswar | West Bengal: Kolkata |

Patient Name : Mrs.PANTHANGI SRIJA	Collected : 26/Oct/2024 10:15AM
Age/Gender : 30 Y 6 M 10 D/F	Received : 26/Oct/2024 12:42PM
UHID/MR No : CJPN.0000098730	Reported : 26/Oct/2024 02:29PM
Visit ID : CJPNOPV210669	Status : Final Report
Ref Doctor : Self	Sponsor Name : ARCOFEMI HEALTHCARE LIMITED
Emp/Auth/TPA ID : 22S33466	

DEPARTMENT OF BIOCHEMISTRY

ARCOFEMI - MEDIWHEEL - FULL BODY HEALTH ANNUAL PLUS CHECK - FEMALE - 2D ECHO - PAN INDIA - FY2324

Test Name	Result	Unit	Bio. Ref. Interval	Method
LIPID PROFILE , SERUM				
TOTAL CHOLESTEROL	174	mg/dL	<200	CHO-POD
TRIGLYCERIDES	105	mg/dL	<150	GPO-POD
HDL CHOLESTEROL	32	mg/dL	40-60	Enzymatic Immunoinhibition
NON-HDL CHOLESTEROL	142	mg/dL	<130	Calculated
LDL CHOLESTEROL	121.2	mg/dL	<100	Calculated
VLDL CHOLESTEROL	21	mg/dL	<30	Calculated
CHOL / HDL RATIO	5.44		0-4.97	Calculated
ATHEROGENIC INDEX (AIP)	0.16		<0.11	Calculated

Comment:

Reference Interval as per National Cholesterol Education Program (NCEP) Adult Treatment Panel III Report.

	Desirable	Borderline High	High	Very High
TOTAL CHOLESTEROL	< 200	200 - 239	≥ 240	
TRIGLYCERIDES	<150	150 - 199	200 - 499	≥ 500
LDL	Optimal < 100 Near Optimal 100-129	130 - 159	160 - 189	≥ 190
HDL	≥ 60			
NON-HDL CHOLESTEROL	Optimal <130; Above Optimal 130-159	160-189	190-219	>220

Dr.Govinda Raju N L
MSc,PhD(Biochemistry)
Consultant Biochemistry

Dr Priya Murthy
M.B.B.S,M.D(Pathology)
Consultant Pathologist



SIN No: JPR241003047

This test has been performed at Apollo Health & Lifestyle Ltd, RRL BANGALORE Laboratory.

APOLLO HEALTH AND LIFESTYLE LIMITED - RRL BANGALORE

APOLLO Health and Lifestyle Limited, 100 Feet Road, 100 Feet Road, Bangalore, Karnataka, India. | 100 Feet Road, Bangalore, Karnataka, India. | 100 Feet Road, Bangalore, Karnataka, India.

APOLLO Health and Lifestyle Limited, 100 Feet Road, Bangalore, Karnataka, India. | 100 Feet Road, Bangalore, Karnataka, India. | 100 Feet Road, Bangalore, Karnataka, India.

APOLLO Health and Lifestyle Limited, 100 Feet Road, Bangalore, Karnataka, India. | 100 Feet Road, Bangalore, Karnataka, India. | 100 Feet Road, Bangalore, Karnataka, India.

Patient Name : Mrs.PANTHANGI SRIJA
Age/Gender : 30 Y 6 M 10 D/F
UHID/MR No : CJPN.000098730
Visit ID : CJPNOPV210669
Ref Doctor : Self
Emp/Auth/TPA ID : 22S33466

Collected : 26/Oct/2024 10:15AM
Received : 26/Oct/2024 12:42PM
Reported : 26/Oct/2024 02:29PM
Status : Final Report
Sponsor Name : ARCOFEMI HEALTHCARE LIMITED

DEPARTMENT OF BIOCHEMISTRY

ARCOFEMI - MEDIWHEEL - FULL BODY HEALTH ANNUAL PLUS CHECK - FEMALE - 2D ECHO - PAN INDIA - FY2324

Test Name	Result	Unit	Bio. Ref. Interval	Method
RENAL PROFILE/KIDNEY FUNCTION TEST (RFT/KFT) , SERUM				
CREATININE	0.49	mg/dL	0.66 - 1.09	Modified Jaffe, Kinetic
UREA	12.60	mg/dL	17-43	GLDH, Kinetic Assay
BLOOD UREA NITROGEN	5.9	mg/dL	8.0 - 23.0	Calculated
URIC ACID	5.58	mg/dL	2.6-6.0	Uricase PAP
CALCIUM	9.80	mg/dL	8.8-10.6	Arsenazo III
PHOSPHORUS, INORGANIC	3.71	mg/dL	2.5-4.5	Phosphomolybdate Complex
SODIUM	136	mmol/L	136-146	ISE (Indirect)
POTASSIUM	4.2	mmol/L	3.5-5.1	ISE (Indirect)
CHLORIDE	102	mmol/L	101-109	ISE (Indirect)
PROTEIN, TOTAL	8.07	g/dL	6.6-8.3	Biuret
ALBUMIN	4.38	g/dL	3.5-5.2	BROMO CRESOL GREEN
GLOBULIN	3.69	g/dL	2.0-3.5	Calculated
A/G RATIO	1.19		0.9-2.0	Calculated

Page 8 of 16

Dr.Govinda Raju N L
MSc,PhD(Biochemistry)
Consultant Biochemistry

Dr Priya Murthy
M.B.B.S,M.D(Pathology)
Consultant Pathologist



SIN No: JPR241003047

This test has been performed at Apollo Health & Lifestyle Ltd, RRL BANGALORE Laboratory.

Apollo Health and Lifestyle Limited
Regd. Office: 10, 82nd Cross, 4th Main, 4th Stage, Old Channarayana Temple, 4th Cross, Bengaluru, Karnataka, Bangalore-560075
www.apolloclinic.com | Email ID: enquiry@apolloclinic.com, Ph.No: 043-6664 7777, Fax No: 4664 7766Apollo
Regd. Office: 10, 82nd Cross, 4th Main, 4th Stage, Old Channarayana Temple, 4th Cross, Bengaluru, Karnataka, Bangalore-560075
www.apolloclinic.com | Email ID: enquiry@apolloclinic.com, Ph.No: 043-6664 7777, Fax No: 4664 7766 1860 500 7788
www.apolloclinic.com

Patient Name : Mrs.PANTHANGI SRIJA	Collected : 26/Oct/2024 10:15AM
Age/Gender : 30 Y 6 M 10 D/F	Received : 26/Oct/2024 12:42PM
UHID/MR No : CJPN.0000098730	Reported : 26/Oct/2024 02:14PM
Visit ID : CJPNOPV210669	Status : Final Report
Ref Doctor : Self	Sponsor Name : ARCOFEMI HEALTHCARE LIMITED
Emp/Auth/TPA ID : 22S33466	

DEPARTMENT OF BIOCHEMISTRY

ARCOFEMI - MEDIWHEEL - FULL BODY HEALTH ANNUAL PLUS CHECK - FEMALE - 2D ECHO - PAN INDIA - FY2324

Test Name	Result	Unit	Bio. Ref. Interval	Method
GAMMA GLUTAMYL TRANSPEPTIDASE (GGT) , SERUM	20.00	U/L	<38	IFCC

Priya Murthy

Dr Priya Murthy
M.B.B.S.,M.D(Pathology)
Consultant Pathologist



Patient Name : Mrs.PANTHANGI SRIJA	Collected : 26/Oct/2024 10:15AM
Age/Gender : 30 Y 6 M 10 D/F	Received : 26/Oct/2024 12:43PM
UHID/MR No : CJPN.0000098730	Reported : 26/Oct/2024 01:40PM
Visit ID : CJPNOPV210669	Status : Final Report
Ref Doctor : Self	Sponsor Name : ARCOFEMI HEALTHCARE LIMITED
Emp/Auth/TPA ID : 22S33466	

DEPARTMENT OF IMMUNOLOGY**ARCOFEMI - MEDIWHEEL - FULL BODY HEALTH ANNUAL PLUS CHECK - FEMALE - 2D ECHO - PAN INDIA - FY2324**

High	High	High	High	Pituitary Adenoma; TSHoma/Thyrotropinoma
------	------	------	------	--

Dr.Govinda Raju N L
MSc,PhD(Biochemistry)
Consultant Biochemistry**Dr Priya Murthy**
M.B.B.S.,M.D(Pathology)
Consultant PathologistSIN No: JPR241003051
THIS TEST HAS BEEN PERFORMED AT APOLLO HEALTH AND LIFESTYLE LIMITED - RRL BANGALORE.**Apollo Health and Lifestyle Limited**
Regd. Office: 102/2/102, 4th Floor, Bangalore Road, Bangalore, Karnataka, India
www.apolloclinic.com | Email ID: enquiry@apolloclinic.com | Ph No: 844-8664 7777, Fax No: 8664 7755**APOLLO**
Kalyani Nagar, Bangalore
Kalyani Nagar, Bangalore**1860 500 7788**
www.apolloclinic.com

Patient Name : Mrs.PANTHANGI SRIJA	Collected : 26/Oct/2024 10:15AM
Age/Gender : 30 Y 6 M 10 D/F	Received : 26/Oct/2024 09:04PM
UHID/MR No : CJPN.0000098730	Reported : 26/Oct/2024 09:27PM
Visit ID : CJPNOPV210669	Status : Final Report
Ref Doctor : Self	Sponsor Name : ARCOFEMI HEALTHCARE LIMITED
Emp/Auth/TPA ID : 22S33466	

DEPARTMENT OF CLINICAL PATHOLOGY

ARCOFEMI - MEDIWHEEL - FULL BODY HEALTH ANNUAL PLUS CHECK - FEMALE - 2D ECHO - PAN INDIA - FY2324

Dr. Rajalakshmi D
M.B.B.S,M.D
Consultant Pathologist

Dr. Vidya Aniket Gore
M.B.B.S,M.D(Pathology)
Consultant Pathologist



Patient Name : Mrs.PANTHANGI SRIJA	Collected : 26/Oct/2024 10:15AM
Age/Gender : 30 Y 6 M 10 D/F	Received : 26/Oct/2024 09:04PM
UHID/MR No : CJPN.0000098730	Reported : 26/Oct/2024 09:27PM
Visit ID : CJPNOPV210669	Status : Final Report
Ref Doctor : Self	Sponsor Name : ARCOFEMI HEALTHCARE LIMITED
Emp/Auth/TPA ID : 22S33466	

DEPARTMENT OF CLINICAL PATHOLOGY

ARCOFEMI - MEDIWHEEL - FULL BODY HEALTH ANNUAL PLUS CHECK - FEMALE - 2D ECHO - PAN INDIA - FY2324

Test Name	Result	Unit	Bio. Ref. Interval	Method
URINE GLUCOSE(POST PRANDIAL)	NEGATIVE		NEGATIVE	GOD-POD

Dr. Rajalakshmi D
M.B.B.S,M.D
Consultant Pathologist

Dr. Vidya Aniket Gore
M.B.B.S,M.D(Pathology)
Consultant Pathologist



Patient Name : Mrs.PANTHANGI SRIJA
 Age/Gender : 30 Y 6 M 10 D/F
 UHID/MR No : CJPN.0000098730
 Visit ID : CJPNOPV210669
 Ref Doctor : Self
 Emp/Auth/TPA ID : 22S33466

Collected : 26/Oct/2024 10:15AM
 Received : 26/Oct/2024 05:05PM
 Reported : 26/Oct/2024 05:39PM
 Status : Final Report
 Sponsor Name : ARCOFEMI HEALTHCARE LIMITED

DEPARTMENT OF CLINICAL PATHOLOGY

ARCOFEMI - MEDIWHEEL - FULL BODY HEALTH ANNUAL PLUS CHECK - FEMALE - 2D ECHO - PAN INDIA - FY2324

Test Name	Result	Unit	Bio. Ref. Interval	Method
URINE GLUCOSE(FASTING)	NEGATIVE		NEGATIVE	GOD-POD

Dr. Vidya Aniket Gore
 M.B.B.S,M.D(Pathology)
 Consultant Pathologist

Dr Priya Murthy
 M.B.B.S,M.D(Pathology)
 Consultant Pathologist



Patient Name : Mrs.PANTHANGI SRIJA	Collected : 26/Oct/2024 01:28PM
Age/Gender : 30 Y 6 M 10 D/F	Received : 27/Oct/2024 12:33PM
UHID/MR No : CJPN.0000098730	Reported : 28/Oct/2024 04:45PM
Visit ID : CJPNOPV210669	Status : Final Report
Ref Doctor : Self	Sponsor Name : ARCOFEMI HEALTHCARE LIMITED
Emp/Auth/TPA ID : 22S33466	

DEPARTMENT OF CYTOLOGY

LBC PAP SMEAR , CERVICAL BRUSH SAMPLE

	CYTOLOGY NO.	23697/24
I	SPECIMEN	
a	SPECIMEN ADEQUACY	ADEQUATE
b	SPECIMEN TYPE	LIQUID-BASED PREPARATION (LBC)
	SPECIMEN NATURE/SOURCE	CERVICAL SMEAR
c	ENDOCERVICAL-TRANSFORMATION ZONE	ABSENT
d	COMMENTS	SATISFACTORY FOR EVALUATION
II	MICROSCOPY	Superficial and intermediate squamous epithelial cells with benign morphology. Negative for intraepithelial lesion/malignancy
III	RESULT	
a	EPITHELIAL CELL	
	SQUAMOUS CELL ABNORMALITIES	NOT SEEN
	GLANDULAR CELL ABNORMALITIES	NOT SEEN
b	ORGANISM	NIL
IV	INTERPRETATION	NEGATIVE FOR INTRAEPITHELIAL LESION OR MALIGNANCY

Pap Test is a screening test for cervical cancer with inherent false negative results. Regular screening and follow-up is recommended (Bethesda-TBS-2014) revised

*** End Of Report ***

Result/s to Follow:
PERIPHERAL SMEAR

Dr. Reshma Stanly
M.B.B.S, DNB(Pathology)
Consultant Pathologist



SIN No: JPR241003154

This test has been performed at Apollo Health & Lifestyle Ltd, Global Reference Laboratory, Hyderabad

Regd. Office: 102/202, A Block, Rajgurunagar 4th Cross, Rajgurunagar, Hyderabad, Telangana - 500116
www.apolloclinic.com | Email ID: enquiry@apolloclinic.com, Ph No: 040-6661 7777, Fax No: 040-6661 7766

APOLLO CLINIC'S NETWORK

Telangana: Hyderabad | AS Rao Nagar | Charlapalli | Kondapur | Malakpet | Madhapur | Meenivaram | Uppal | Andhra Pradesh: Vijaya Vittala | Karnataka: Bangalore | Chittoor | Kerala: Kollam | Odisha: Bhubaneswar | West Bengal: Kolkata | Maharashtra: Pune | Gujarat: Gandhinagar | Rajasthan: Jaipur | Karnataka: Bangalore | Kerala: Kollam | Odisha: Bhubaneswar | West Bengal: Kolkata | Maharashtra: Pune | Gujarat: Gandhinagar | Rajasthan: Jaipur



Patient Name	: Mrs. panthangi srija	Age	: 30Yrs 6Mths 11Days
UHID	: C.JPN.0000098730	OP Visit No.	: CJPNOPV210669
Printed On	: 26-10-2024 10:48 AM	Advised/Pres Doctor	: --
Department	: Radiology	Qualification	: --
Referred By	: Self	Registration No.	: --
Employer Id	: 22S33466		

DEPARTMENT OF RADIOLOGY

ULTRASOUND WHOLE ABDOMEN

LIVER : Normal in size (13.6cm)and echotexture. No focal lesion seen.
No intra hepatic biliary / venous radicular dilation.
CBD and Main Portal vein appear normal.

GALL BLADDER : Well distended. Normal in internal contents. Wall Thickness is normal.

SPLEEN : Normal in size (10.4cm)and echotexture. No focal lesion was seen.

PANCREAS : Normal to the visualized extent.

KIDNEYS : Both kidneys are normal in size, shape and outlines Cortico medullary delineation is maintained. No Hydronephrosis / No calculi.

Right kidney measures: 9.3 X 1.1cm.

Left kidney measures : 11.4 X 1.2cm.

URINARY BLADDER : Well distended. Normal in internal contents. Wall thickness is normal.

UTERUS : Normal in size and echotexture. It measures : 5.6 X 4.8 X 5.0cm. Uniform myometrial echoes are normal. Endometrial thickness measuring- 5mm.

No focal lesion was noted.

OVARIES : Both ovaries are normal in size.

Right ovary measures : 2.0 X 2.5cm.

Left ovary measures : 2.5 X 2.8cm.

No free fluid is seen in the peritoneum. No lymphadenopathy.

IMPRESSION : NORMAL STUDY.

Please Note :No preparation done before scanning.

---End Of The Report---



Dr. ABID HUSSAIN GULLENPET
MBBS, DMRD, FRCR
26066
Radiology

Patient Name	: Mrs. panthangi srija	Age	: 30Yrs 6Mths 13Days
UHID	: CJPN.0000098730	OP Visit No.	: CJPNOPV210669
Printed On	: 28-10-2024 07:56 AM	Advised/Pres Doctor	: --
Department	: Cardiology	Qualification	: --
Referred By	: Self	Registration No.	: --
Employeer Id	: 22S33466		

DEPARTMENT OF CARDIOLOGY

ECG

Observation :-

1. Normal Sinus Rhythm.
2. Heart rate is 72 beats per minutes.
3. No pathological Q wave or ST-T changes seen.
4. Normal P,QRS,T waves and axis.
5. No evidence of chamber, hypertrophy or enlargement seen.

Impression:

NORMAL RESTING ECG.

---End Of The Report---

Dr. SHIVAKUMAR M P
MBBS MD
24348
Cardiology

Patient Name	: Mrs. panthangi srija	Age	: 30Yrs 6Mths 11Days
UHID	: CJPN.0000098730	OP Visit No.	: CJPNOPV210669
Printed On	: 26-10-2024 12:18 PM	Advised/Pres Doctor	: --
Department	: Cardiology	Qualification	: --
Referred By	: Self	Registration No.	: --
Employeer Id	: 22S33466		

DEPARTMENT OF CARDIOLOGY

2D ECHO WITH COLOR DOPPLER

DIMENSIONS:

AO (ed) 2.7 CM
LA (es) 2.6 CM
LVID (ed) 4.0 CM
LVID (es) 2.1 CM
IVS (Ed) 0.8 CM
IVS (Es) 1.2 CM
LVPWd 0.8 CM
LVPWs 1.2 CM
EF 65%
FD 38%
RVIDd 1.8 CM

2DVALVES

MITRAL VALVE -----: NORMAL
TRICUSPID VALVE-----: NORMAL
AORTIC VALVE-----: NORMAL
PULMONARY VALVE-----: NORMAL

CHAMBERS

LEFT ATRIUM-----: NORMAL.
RIGHT ATRIUM-----: NORMAL
LEFT VENTRICULAR-----: NORMAL

RIGHT VENTRICULAR---: NORMAL

DOPPLER

MV E Vel 1.2M/S

MV A Vel 0.6M/S

TRICUSPID VALVE-----: NORMAL

PERICARDIUM-----: NORMAL

CLOT/VEGETATION-----: NIL

IMPRESSION

NORMAL VALVES AND CHAMBERS

NORMAL LV SYSTOLIC FUNCTION

NO CLOT /VEGETATION/EFFUSION/PAH

NO REGIONAL WALL MOTION ABNORMALITIES

---End Of The Report---

Dr.NAGARAJA MOORTHY
MBBS, MD, DM (CARDIOLOGY)
64485
Cardiology

Patient Name	: Mrs. panthangi srija	Age	: 30Yrs 6Mths 13Days
UHID	: C.JPN.0000098730	OP Visit No.	: CJPNOPV210669
Printed On	: 28-10-2024 07:36 AM	Advised/Pres Doctor	: --
Department	: Radiology	Qualification	: --
Referred By	: Self	Registration No.	: --
Employeer Id	: 22S33466		

DEPARTMENT OF RADIOLOGY

X-RAY CHEST PA VIEW

Lung fields are clear.

Cardio thoracic ratio is normal.

Apices, costo and cardio phrenic angles are free.

Cardio vascular shadow and hila show no abnormal feature.

Bony thorax shows no significant abnormality.

Domes of diaphragm are well delineated.

IMPRESSION: NO SIGNIFICANT ABNORMALITY DETECTED.

---End Of The Report---



Dr. ABID HUSSAIN GULLENPET
MBBS, DMRD, FRCR
26066
Radiology

Name : Mrs. Panthangi Srija

Age : 30Y 6M 10D

UHID : CJPN.0000098730

Address : J P Nagar Bangalore Karnataka INDIA 560078

sex : Female



CJPN.0000098730

Plan : ARCOFEMI MEDIWHEEL FEMALE AHC
CREDIT PAN INDIA OP AGREEMENT

OP No: CJPNOPV210669

Bill No: CJPN-OCR-75715

Date: Oct 26th, 2024, 10:10 AM

Sno.	Service Type/Service Name	Department	
1	ARCOFEMI - MEDIWHEEL - FULL BODY HEALTH ANNUAL PLUS CHECK - FEMALE - 2D ECHO - PAN INDIA - FY2324		
1	ULTRASOUND - WHOLE ABDOMEN	Ultrasound Radiology	<input type="checkbox"/>
2	OPHTHAL BY GENERAL PHYSICIAN	Consultation	<input type="checkbox"/>
3	URINE GLUCOSE(POST PRANDIAL)	Clinical Pathology	<input type="checkbox"/>
4	GAMMA GLUTAMYL TRANSFERASE (GGT)	Biochemistry	<input type="checkbox"/>
5	HbA1c, GLYCATED HEMOGLOBIN	Biochemistry	<input type="checkbox"/>
6	GYNAECOLOGY CONSULTATION	Consultation	<input type="checkbox"/>
7	DIET CONSULTATION	General	<input type="checkbox"/>
8	BODY MASS INDEX (BMI)	General	<input type="checkbox"/>
9	ECG	Cardiology	<input type="checkbox"/>
10	THYROID PROFILE (TOTAL T3, TOTAL T4, TSH)	Biochemistry	<input type="checkbox"/>
11	2 D ECHO	Cardiology	<input type="checkbox"/>
12	BLOOD GROUP ABO AND RH FACTOR	Blood Bank	<input type="checkbox"/>
13	X-RAY CHEST PA 19	X Ray Radiology	<input type="checkbox"/>
14	URINE GLUCOSE(FASTING)	Clinical Pathology	<input type="checkbox"/>
15	LBC PAP TEST- PAPSURE - (11)	Histopathology	<input type="checkbox"/>
16	FITNESS BY GENERAL PHYSICIAN	Consultation	<input type="checkbox"/>
17	GLUCOSE, POST PRANDIAL (PP), 2 HOURS (POST MEAL)	Biochemistry	<input type="checkbox"/>
18	GLUCOSE, FASTING	Biochemistry	<input type="checkbox"/>
19	ENT CONSULTATION	Consultation	<input type="checkbox"/>
20	LIPID PROFILE	Biochemistry	<input type="checkbox"/>
21	DENTAL CONSULTATION	Consultation	<input type="checkbox"/>
22	HEMOGRAM + PERIPHERAL SMEAR	Haematology	<input type="checkbox"/>
23	PERIPHERAL SMEAR	Haematology	<input type="checkbox"/>
24	COMPLETE URINE EXAMINATION	Clinical Pathology	<input type="checkbox"/>
25	RENAL PROFILE/RENAL FUNCTION TEST (RFT/KFT)	Biochemistry	<input type="checkbox"/>
26	LIVER FUNCTION TEST (LFT)	Biochemistry	<input type="checkbox"/>

wt. 84.6 kg

Height. 153 cm

BP - 124/78 mmHg

PR. 90 bpm

~~XXXXXXXXXXXX~~
~~XXXXXXXXXXXX~~






పేరు **Parthangi Srija**
 పుట్టిన తేదీ/DOB: 16/04/1994
 లింగం **FEMALE**

పేరు తేదీ: 20/09/2011

~~XXXXXXXXXXXX~~
~~XXXXXXXXXXXX~~






పేరు **Parthangi Srija**
 పుట్టిన తేదీ/DOB: 16/04/1994
 లింగం **FEMALE**

పేరు తేదీ: 20/09/2011

8598 8155 0134
 VID : 9122 1775 0840 2462

నా ఆధార్, నా సుర్తింపు

Mrs. Parthasari Srinivas Srinivas

Height :	Weight :	BMI :	Waist Circum :
Temp :	Pulse :	Resp :	B.P :

General Examination / Allergies
History

Clinical Diagnosis & Management Plan

No family H/O DM/HT
or Malignancy.
Mother is Diabetic m/h

for Routine Screening.

GC Swab

PA: Abundant +
LSCS Scar

AC: Est. Genitohiatal
Cervix + Vagina Healthy

LBC done + sent for HPV

Age: 49 yrs.

P2 L2

Gyn hist / LSCS
Fyn G. str. / CTO
@ Retention

Menarche: 11 yrs

MC: 3-6/38-50 yrs

LMP: One Month
Back

Adv: ① To Reduce weight

Follow up date: Sep

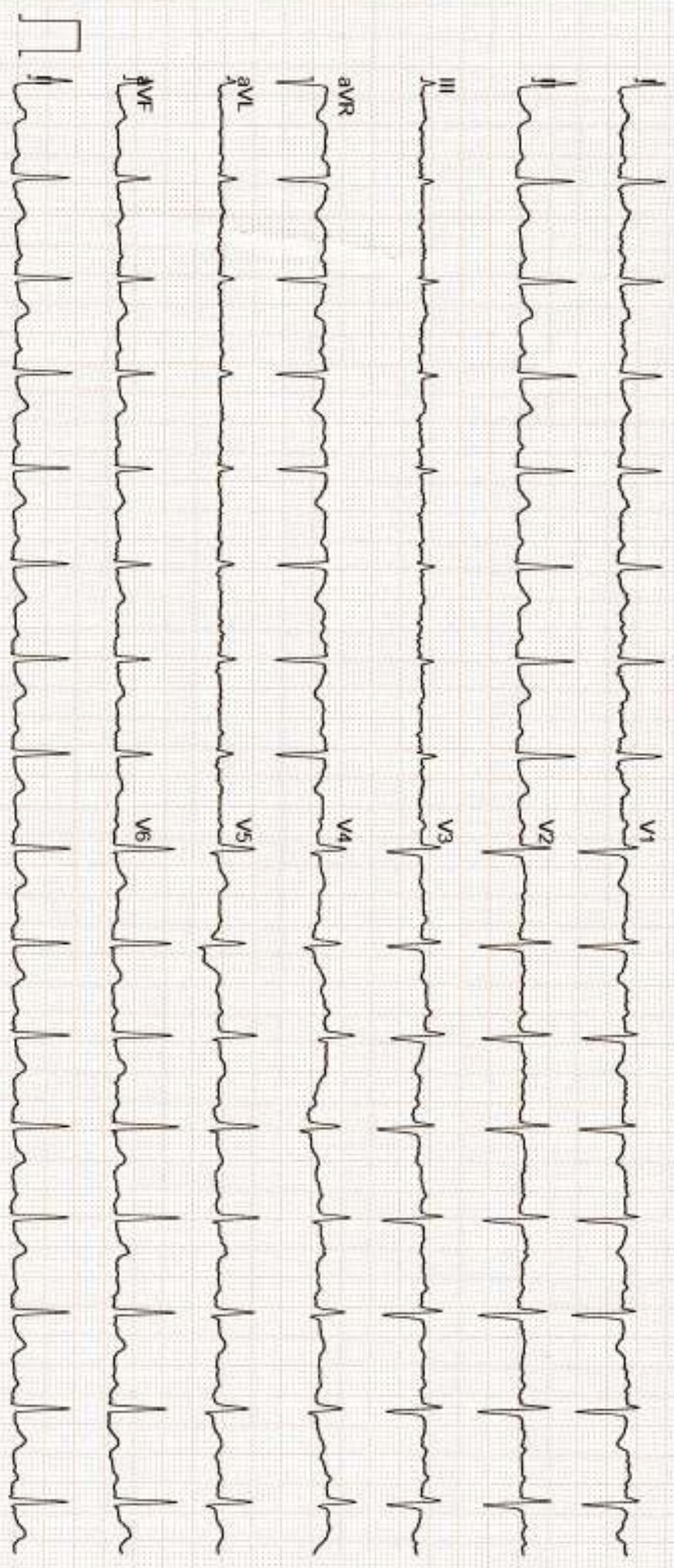
K. S. Nishu
Doctor Signature

30 Years 153 in Female
84.0 lb

Apollo Clinic
J.P. Nagar
Bangalore

Normal sinus rhythm
Normal ECG

QRS	76 ms
QT / QTcBaz	358 / 447 ms
PR	154 ms
P	74 ms
RR / PP	638 / 638 ms
P / QRS / T	29 / 40 / 45 degrees



Unconfirmed